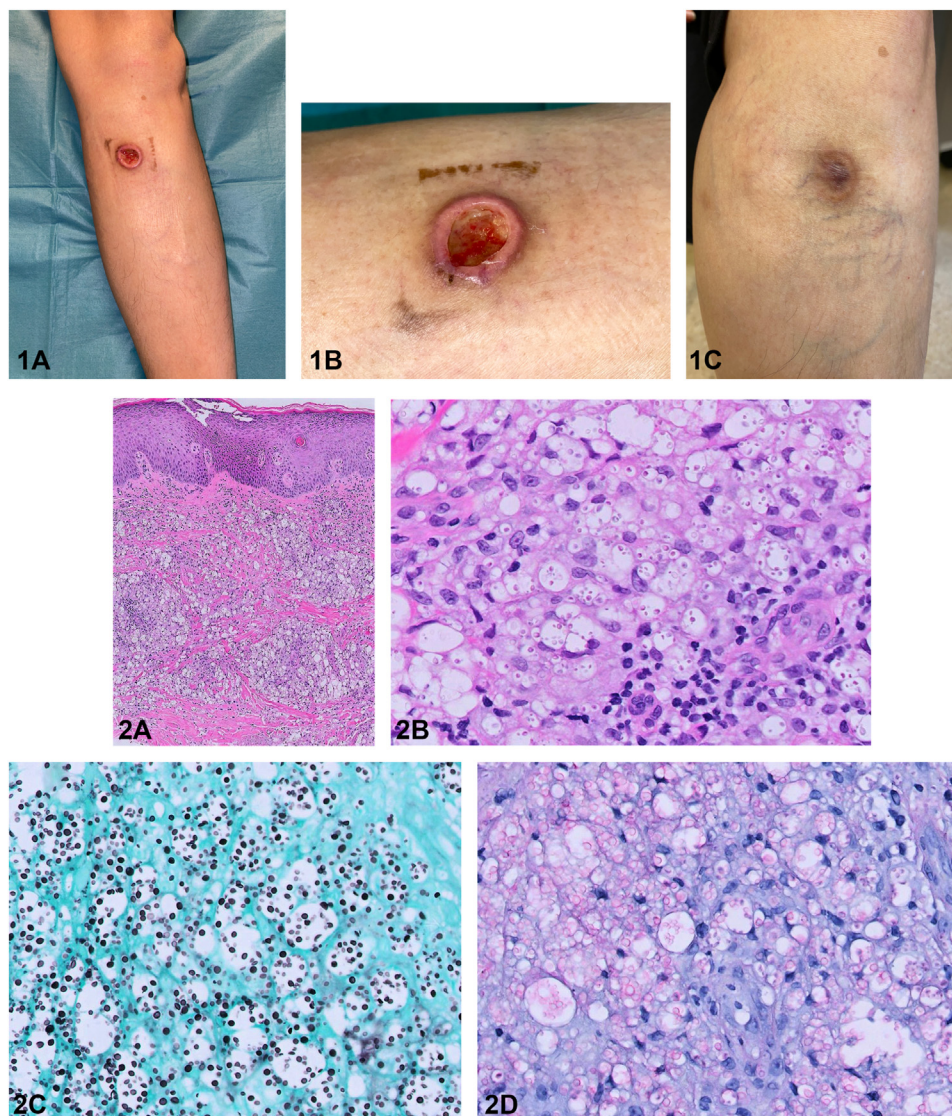


Solitary leg ulcer in a renal transplant recipient



Wen Hao Tan, MRCP,^a Riece Koniman, MRCP,^b Ai Ling Tan, FRCPA,^c Limin Wijaya, MRCP,^d Kok Hing Lim, FRCPath,^c and Choon Chiat Oh, MRCP^a
Singapore City, Singapore

Key words: cutaneous cryptococcus; disseminated cryptococcosis; leg ulcer; renal transplant.



From the Department of Dermatology,^a Department of Renal Medicine,^b Division of Pathology,^c and Department of Infectious Diseases,^d Singapore General Hospital, Singapore City.

Funding sources: None.

IRB approval status: Not applicable.

Correspondence to: Choon Chiat Oh, MRCP, Department of Dermatology, Singapore General Hospital, 20 College Road, Singapore City, Singapore 168856. E-mail: oh.choon.chiat@singhealth.com.sg.

JAAD Case Reports 2022;23:93-5.
2352-5126

© 2022 by the American Academy of Dermatology, Inc. Published by Elsevier, Inc. This is an open access article under the CC BY-NC-ND license (<http://creativecommons.org/licenses/by-nc-nd/4.0/>).

<https://doi.org/10.1016/j.jidcr.2021.12.046>

CASE HISTORY

A 44-year-old Asian woman presented 3 years after a kidney transplant with a 1-month history of a painful and enlarging lesion on the left shin. She was on 6.5 mg tacrolimus once daily, 360 mg mycophenolic acid twice a day, and 5 mg prednisolone once daily for posttransplant immunosuppression. A systemic review revealed a nonproductive cough without associated fever or neurologic symptoms. A physical examination showed a nodule on the left shin with central crateriform depression. The left shin lesion progressed to ulcerate (Fig 1, A and B), leaving a 1.5-cm shallow ulcer with a sloughy base. There was no purulent discharge. Histopathology revealed a diffuse dermal infiltrate of clear-to-foamy macrophages containing engulfed, small fungal yeast forms (Fig 2).

Question 1: What other common sites of systemic involvement would you likely expect?

- A. Kidney and lymph node
- B. Lung and spine
- C. Kidney and central nervous system (CNS)
- D. Eye and spine
- E. Lung and CNS

Answers:

A. Kidney and lymph node — Incorrect. The dissemination of cryptococcosis occurs via the hematogenous route; however, the kidneys are less frequently involved. The lymph nodes are also not commonly involved in disseminated cryptococcosis.

B. Lung and spine — Incorrect. While approximately 25% to 54% of organ transplant recipients with cryptococcosis have pulmonary infections, osteoarticular involvement is less likely, with an estimated prevalence of 5%.¹ Cryptococcal osteomyelitis occurs as a result of hematogenous dissemination following pulmonary infection.²

C. Kidney and CNS — Incorrect. Cryptococcus has a predilection for the CNS, but kidney involvement is less commonly seen.

D. Eye and spine — Incorrect. While the eye may be involved as part of the CNS, the spinal vertebrae are not common sites of cryptococcal involvement.

E. Lung and CNS — Correct. Cutaneous cryptococcosis is the third-most common manifestation of disseminated cryptococcosis, after the CNS and pulmonary, but the incidence remains uncommon. In a review of 146 solid organ transplant recipients (half of whom were renal transplant recipients) with cryptococcosis, Sun et al³ reported that cutaneous manifestations occurred in 26 (17.8%) cases.

Question 2: Which type of stain would best help detect the pathology?

- A. Gomori methenamine silver

- B. Fite
- C. Warthin-Starry
- D. Giemsa
- E. Mucicarmin

Answers:

A. Gomori methenamine silver — Incorrect. Gomori methenamine silver is a special stain to detect fungi by outlining stained polysaccharides in the fungi cell walls. However, it is usually not specific enough to identify definitive species based on fungal morphology.

B. Fite — Incorrect. Fite stain is used to detect the acid-fast bacillus *Mycobacterium leprae* and other bacterial infections, including nocardiosis. This stain uses peanut oil mixed with xylene in the deparaffinization, protecting the waxy cell walls of the bacteria from organic solvents.

C. Warthin-Starry — Incorrect. This silver stain identifies spirochetes and *Helicobacter pylori* and *Bartonella henselae* in cat-scratch disease.

D. Giemsa — Incorrect. Giemsa stain, a type of Romanowsky stain, is a gold-standard staining technique used for thin and thick smears to examine blood for malaria parasites. It is also used as a differential stain for diagnosing *Chlamydia trachomatis*, *Borrelia* species, *Yersinia pestis*, *Histoplasma* species, and *Pneumocystis jiroveci* cysts.

E. Mucicarmin — Correct. Blastomycosis and histoplasmosis can mimic cryptococcosis both clinically and histopathologically. Mucicarmin stain highlights both the capsular and yeast forms of cryptococcus. Conversely, this stain is usually negative or focally positive in blastomycosis and histoplasmosis.

Question 3: What is the most appropriate initial treatment?

- A. Benzylpenicillin
- B. Amphotericin B

- C. Amikacin
- D. Terbinafine
- E. Caspofungin

Answers:

A. Benzylpenicillin — Incorrect. Benzylpenicillin is an antibiotic that is highly active against *Streptococcus pneumoniae* and the Lancefield group A β -hemolytic streptococcus.

B. Amphotericin B — Correct. According to the Infectious Diseases Society of America guidelines, the recommended therapy for disseminated cryptococcosis in organ transplant recipients is liposomal amphotericin B (3-4 mg/kg/day, intravenously) plus flucytosine (100 mg/kg/day in 4 divided doses) for at least 2 weeks, followed by fluconazole (400-800 mg [6-12 mg/kg] per day, orally) for 8 weeks, with a tapered lower dose of fluconazole (200-400 mg/day, orally) for 6 to 12 months.⁴ Flucytosine targets pyrimidine biosynthesis and is not used as a sole therapy because strains frequently become resistant. The risk of amphotericin B-related nephrotoxicity warrants the close monitoring of renal function to detect early signs of renal allograft loss.

C. Amikacin — Incorrect. This is a semisynthetic, broad-spectrum aminoglycoside antibiotic with bactericidal activity and is usually given in association with β -lactams for the treatment of severe gram-negative infections.

D. Terbinafine — Incorrect. Oral terbinafine is not the recommended antifungal therapy for

disseminated cryptococcosis. In resource-limited environments, patients with CNS or disseminated disease should receive induction therapy with fluconazole (at least 800 mg per day; 1200 mg per day is preferred) for at least 10 weeks or until cerebrospinal fluid culture results are negative.⁴

E. Caspofungin — Incorrect. Caspofungin is a member of the echinocandin class of (1,3) β -glucan synthase inhibitors that are effective against many species of fungi. However, *Cryptococcus* species are intrinsically resistant, both *in vitro* and *in vivo*, to caspofungin and other echinocandins and, hence, would not be a suitable option here.

Abbreviation used:

CNS: central nervous system

Conflicts of interest

None disclosed.

REFERENCES

1. Behrman RE, Masci JR, Nicholas P. Cryptococcal skeletal infections: case report and review. *Rev Infect Dis.* 1990;12(2):181-190. <https://doi.org/10.1093/clinids/12.2.181>
2. Wood L, Miedzinski L. Skeletal cryptococcosis: case report and review of the literature. *Can J Infect Dis.* 1996;7(2):125-132. <https://doi.org/10.1155/1996/102103>
3. Sun HY, Alexander BD, Lortholary O, et al. Cutaneous cryptococcosis in solid organ transplant recipients. *Med Mycol.* 2010;48(6):785-791. <https://doi.org/10.3109/13693780903496617>
4. Perfect JR, Dismukes WE, Dromer F, et al. Clinical practice guidelines for the management of cryptococcal disease: 2010 update by the Infectious Diseases Society of America. *Clin Infect Dis.* 2010;50(3):291-322. <https://doi.org/10.1086/649858>