

Ramsay Hunt Syndrome: A diagnostic dilemma

ABSTRACT

Ramsay Hunt Syndrome is not just a syndrome but rather an engrossing infectious disease that is difficult to rationalize owing to unpredictable onset. Reactivation of the varicella-zoster virus remains the etiological factor. The clinical depiction remains the cornerstone of diagnosis. Characteristic feature of the disease includes acute lower motor neuron facial palsy, otalgia, and mucosal and cutaneous rashes. A 37-year-old male reported to our department with pain and difficulty in closing the eye. At follow-up, the lesions got healed, but facial nerve deficit persisted. It is vital to establish an early diagnosis which aids in distinguishing the syndrome from other severe neurological illnesses, and early initiation of treatment is of prime importance to improve the impaired nerve function; hence, precise knowledge of the disease is crucial. Audiometric analysis must be performed since it can lead to permanent hearing loss.

Keywords: Facial palsy, herpes zoster, Ramsay Hunt syndrome, varicella-zoster virus

INTRODUCTION

Ramsay Hunt Syndrome (RHS) comprises an infectious cranial polyneuropathy with symptoms including peripheral facial nerve palsy and erythematous vesicular rash on the ear (zoster oticus) or in the mouth, but lesions are known to involve all the cranial nerves.^[1] James Ramsay Hunt (1872–1937) described three discrete syndromes, the best acknowledged of which is zoster oticus with peripheral facial palsy. He first defined RHS in the year 1907 in a patient who had otalgia associated with cutaneous and mucosal rashes.^[2] Primary exposure to varicella-zoster virus (VZV), also known as human herpesvirus 3, causes chickenpox, following which virus remains quiescent in the dorsal ganglion cells of the spinal and cranial nerves. The reactivation and replication of latent VZV leads to herpetic inflammatory lesions through ganglion to dermatomes associated with the involved ganglia causing a transient disease known as herpes zoster (herpes from herpein to creep, zoster a sword belt) or shingles.^[3] It involves the thoracic segment in approximately 59.2% of cases. Head-and-neck incidence is reported in up to 35% of cases.^[3] RHS develops in 0.2% of the patients with positive history of primary VZV infection and is the second most common cause of atraumatic peripheral facial

paralysis first being the Bell's palsy.^[2,4] The frequency of herpes zoster in patients with peripheral facial paralysis has been estimated to be 12%.^[3] Compared with Bell's palsy, patients with this syndrome often have more severe paralysis and have poor prognosis.^[1] The disease is thought to be self-limiting, and the usual presentation is from 3 months of age to 82 years.^[5] RHS mimics various other vesiculobullous lesions, thus creating a dilemma in diagnosis, and hence is of particular importance to oral physicians and pathologists. A permanent neurological damage may result in a delay in the treatment. Clinical picture of the disease remains the foundation stone of diagnosis.

NAROTAM KUMAR GHEZTA, YOGESH BHARDWAJ, RANGILA RAM, ROWENA NAVJYOT BASI

Department of Oral and Maxillofacial Surgery, Himachal Pradesh Government Dental College and Hospital, Shimla, Himachal Pradesh, India


Address for correspondence: Dr. Rowena Navjyot Basi, Room No. 506, Himachal Pradesh Government Dental College and Hospital, Shimla, Himachal Pradesh, India.
E-mail: basirowena28@gmail.com

Received: 28 November 2020, **Revised:** 21 January 2021, **Accepted:** 12 March 2021, **Published:** 20 August 2022

This is an open access journal, and articles are distributed under the terms of the Creative Commons Attribution-NonCommercial-ShareAlike 4.0 License, which allows others to remix, tweak, and build upon the work non-commercially, as long as appropriate credit is given and the new creations are licensed under the identical terms.

For reprints contact: WKHLRPMedknow_reprints@wolterskluwer.com

How to cite this article: Ghezta NK, Bhardwaj Y, Ram R, Basi RN. Ramsay hunt syndrome: A diagnostic dilemma. *Natl J Maxillofac Surg* 2022;13:S179-82.

| Access this article online | |
|---|---|
| Website: www.njms.in | Quick Response Code  |
| DOI: 10.4103/njms.NJMS_259_20 | |

CASE REPORT

A 37-year-old male patient reported to the outpatient care center with a chief complaint of pain over the left side of the face for 4–5 days and difficulty in closure of the left eye. History revealed pain over the left side of the face and left ear followed by ulceration in the oral cavity. Temperature, pulse rate, and blood pressure were within normal limits. On extraoral examination, slight facial asymmetry was observed without any vesicular eruption on the face or ears. Neurological examination revealed that all the ipsilateral peripheral branches of the seventh cranial nerve were involved. The patient was unable to close his left eyelid with positive Bell’s phenomenon, furrowing was absent on the left side of the forehead, and if asked to smile or show his teeth and puff out his cheeks, these actions were absent on the affected side [Figure 1]. In addition, loss of motor control of facial muscles leads to reduction in the flow of tears and saliva on the affected side. On examination, extraocular movements were found intact. The patient had a partial loss of touch sensation over the left side of his face. No herpetic rash was

found over the left ear as would occur in the classic zoster appearance, but inspection of the oral cavity revealed lesions present over left half of the tongue, left side of the hard and soft palate with adjacent erythematous mucosal rashes [Figure 2]. The patient had altered taste sensation along with burning sensation in the involved mucosal areas. There was no regional lymphadenopathy. The patient had bilateral equal strength of the extremities with no sensory deficits on examination. Pure-tone audiometry [Figure 3] was done to rule out any sign of deafness which revealed normal hearing sensitivity, i.e., 11.6 dB in both the ears. Tzanck smear was performed on the oral vesicles [Figure 4]. These lesions also tested positive on KOH mounts indicating secondary infection with *Candida albicans*. Based on history, clinical findings, and histological examination, the diagnosis of RHS with secondary oral candidiasis was given. He was treated without delay and prescribed tablet acyclovir 800 mg QID × 7 days, tablet prednisolone 60 mg in morning × 7 days, tablet aceclofenac

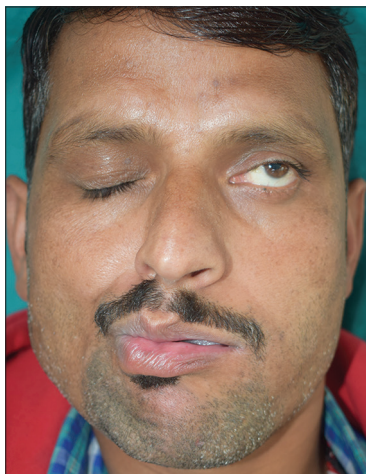

Figure 1: Ramsay Hunt syndrome: Facial palsy of the left side with inability to close the left eye and puff the cheek

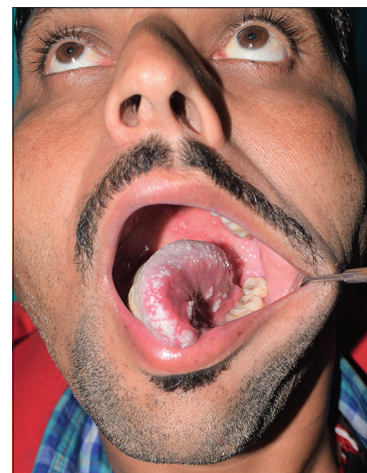


Figure 2: Herpetic vesicles and erythema over the left side of tongue and left soft palate with secondary candidiasis

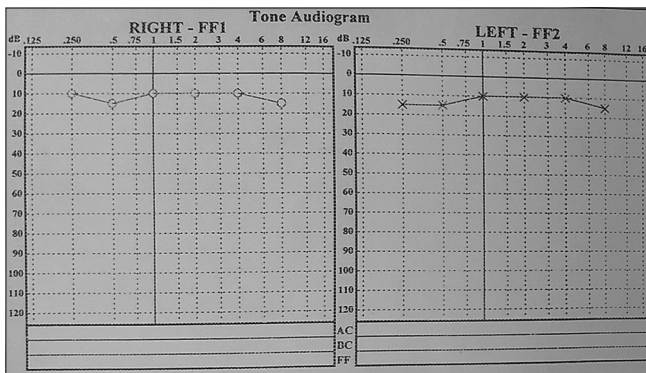


Figure 3: Pure-tone audiogram showing normal hearing sensitivity of both the ears

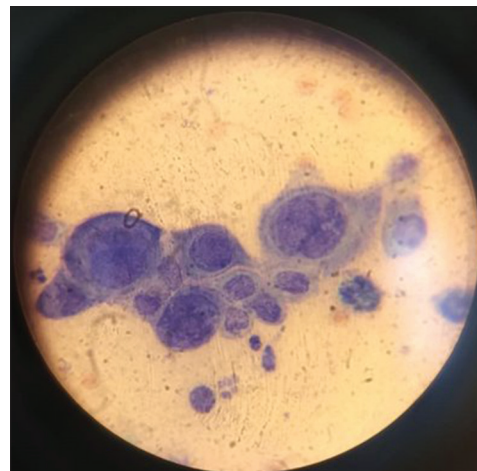


Figure 4: Tzanck smear showing acantholysis with numerous free-floating Tzanck cells

with paracetamol B.D. × 7 days, tablet fluconazole 150 mg OD × 7 days (for secondary oral candidiasis), multivitamins, local application of chlorhexidine gluconate gel 1.0% w/w, benzocaine gel 20% w/w thrice daily and candid mouth paint twice daily for intraoral lesions, benzydamine hydrochloride 0.15% w/v oral rinse thrice daily, artificial tears with padding of the eye, and physiotherapy for facial paralysis. At follow-up of 2 weeks, eruptions got healed, but facial paralysis persisted.

DISCUSSION

The initial cases of herpes zoster associated with facial paralysis were described in 1872 by Tryde.^[3] The nomenclature “herpes zoster oticus” was described by Korner.^[6] However, the rare involvement of the oropalatine region was pointed out by Spillane.^[6] Ramsay Hunt classified the syndrome based on the clinical types and the subgroups in the year 1908^[6] [Table 1]. In our case study, facial nerve palsy developed along with simultaneous vesicular eruption in the oral cavity which appeared 5 days after the initiation of pain over the left side of the face and in the left ear followed by loss of taste sensation. Usually, the emergence of facial paralysis follows the eruption of herpetic vesicles although, may occur simultaneously but it seldom precedes the eruption. Facial nerve is the most vulnerable cranial nerve in herpes zoster of the head and neck as stated by Spillane.^[5]

Diagnosis and treatment

Triad of severe ear pain, small vesicles on the pinna or oral mucosa, and facial palsy forms the backbone of diagnosis. Diagnosis of a case with acute facial weakness requires a high level of suspicion. Initially, it may be indistinguishable from Bell’s palsy as facial weakness may be clinically evident before the appearance of the vesicles, although the vesicular eruption usually precedes or presents simultaneously with facial paralysis. Signs and symptoms of vestibulocochlear dysfunction may not always be evident.^[1] Tzanck smear is a simple, rapid, and inexpensive test that aids in establishing the clinical diagnosis of herpetic lesions with ease, although histological examination is of limited value in diagnosing

Table 1: Ramsay Hunt syndrome classification

| |
|---|
| Ramsay Hunt 1908 classification |
| Herpes oticus |
| Herpes oticus, with facial paralysis |
| Herpes oticus, with facial paralysis and hyperacusis |
| Herpes oticus, with facial paralysis and Meniere’s complex |
| In the subgroups, herpes oticus is not present but it involves |
| Herpes facialis, with facial paralysis and auditory symptoms |
| Herpes occipitocollaris, with facial paralysis and acoustic symptoms |
| Herpes zoster of the cephalic extremity, with auditory nerve problems |
| In 1910, Hunt added further divisions: Herpes zoster pharyngis and herpes zoster laryngis |

RHS. RHS usually may not be responsive to therapy leading to severe dysfunction. Its recovery is indirectly proportional to the severity of nerve damage; the more severe the damage, the longer it will take to recover and lower the chance to completely regain normal function. Initiating the treatment within 72 h of onset of disease leads to better prognosis, i.e., recovery occurs in up to 75% of patients.^[3,7] If the treatment is delayed for more than 3 days, the chances of a complete recovery drop to about 50%, and prognosis is much worse than that for Bell’s palsy^[4] with few reported cases of permanent complete unilateral paralysis. As compared to adults, children are more likely to have a complete recovery. Aggressive and early treatment lowers the grave outcome risk. The standard first-line treatment for infections at sites in the body other than the ear is the antiviral agent acyclovir, given either intravenously or orally.^[3] Acyclovir and prednisone enhance the recovery rate by preventing the degeneration of nerves. Despite the lack of randomized, controlled prospective treatment trials, data from the collective case reports and retrospective reviews suggest that combination therapy with prednisone and acyclovir, if initiated early, improves the overall prognosis and minimizes the risk of permanent neuronal damage. Although there are no evidence-based dosing recommendations, published trials typically administered acyclovir: 800 mg orally 4–5 times/day for 7–10 days and prednisone at 1 mg/kg/day orally for 5 days followed by a taper.^[2] RHS resistant to medical therapy may be managed by surgical decompression,^[8] whereas resistant neuralgic syndrome cases may be managed by microvascular decompression and rhizotomy.^[11]

CONCLUSION

RHS is a rare, diverse, and challenging disease as it mimics other neurological diseases leading to problematic early diagnosis. Prompt diagnosis and treatment ideally within 72 h are crucial to secure the best outcomes and to prevent complications. Antecedent otalgia may be misunderstood before the vesicular eruption appears and the buccal cavity should always be examined for the presence of vesicles on the palate and anterior two-thirds of the tongue. The ideal approach for treatment is still debated, and a multidisciplinary approach is crucial for the follow-up and recovery of these patients.

Declaration of patient consent

The authors certify that they have obtained all appropriate patient consent forms. In the form, the legal guardian has given his consent for images and other clinical information to be reported in the journal. The guardian understands that names and initials will not be published and due efforts

will be made to conceal identity, but anonymity cannot be guaranteed.

Financial support and sponsorship

Nil.

Conflicts of interest

There are no conflicts of interest.

REFERENCES

1. Sweeney CJ, Gilden DH. Ramsay Hunt syndrome. *J Neurol Neurosurg Psychiatry* 2001;71:149-54.
2. Arya S, Vengal M, Anitha B, Rao A. Lower motor neuron lesion secondary to Ramsay Hunt syndrome: A case report with review of literature. *BBB* 2015;3:433-9.
3. Jeon Y, Lee H. Ramsay Hunt syndrome. *J Dent Anesth Pain Med* 2018;18:333-7.
4. Kim SH, Jung J, Jung SY, Dong SH, Byun JY, Park MS, *et al.* Comparative prognosis in patients with Ramsay-Hunt syndrome and Bell's palsy. *Eur Arch Otorhinolaryngol* 2019;276:1011-6.
5. Devriese PP, Moesker WH. The natural history of facial paralysis in herpes zoster. *Clin Otolaryngol Allied Sci* 1988;13:289-98.
6. Devriese PP. Facial paralysis in cephalic herpes zoster. *Ann Otol Rhinol Lar* 1968;11:1101-19.
7. Singh G, Subhalakshmi V, Balasubramanian S, Patidar M, Ealla KK. Ramsay Hunt Syndrome: A diagnostic challenge for general dental practitioners. *Contemp Clin Dent* 2017;8:337-9.
8. Uscategui T, Doree C, Chamberlain IJ, Burton MJ. Corticosteroids as adjuvant to antiviral treatment in Ramsay Hunt syndrome (herpes zoster oticus with facial palsy) in adults. *Cochrane Database Syst Rev* 2008;(3):CD006852.