

Computed tomography imaging features of hepatic perivascular epithelioid cell tumor

A case report and literature review

Xu Han, MD^a, Mei-Yu Sun, PhD^{a,*}, Jing-Hong Liu, MD^a, Xiao-Yan Zhang, PhD^b, Meng-Yao Wang, MD^a, Rui Fan, MD^a, Sahrish Qamar, PhD^c

Abstract

Rationale: Perivascular epithelioid cell tumor (PEComa) is a rare tumor which is most frequently found in uterus. The tumor arising from liver is extremely uncommon.

Patient concerns: A 36-year-old female with abdominal distention, cramps, and low-grade fever for over 15 days. The patient had a history of gastric adenocarcinoma with ovarian, celiac lymph nodes, and retroperitoneal lymph nodes metastases.

Diagnoses: Computed tomography (CT) imaging demonstrated an ill-defined heterogeneous hypo-dense mass in segment 8 (S8) of the liver. Contrast-enhanced CT imaging showed marked enhancement in arterial phase, mild-to-moderate enhancement in portal and equilibrium phases. Tumor-feeding artery was demonstrated from the right hepatic artery by the three-dimensional reconstruction images. Biopsy was performed, and a diagnosis of PEComa was rendered.

Interventions: No intervention for this tumor before liver biopsy.

Lessons: We present a rare case of hepatic PEComa. The information we provided is useful for summarizing the CT features of this kind of tumors. It should be included in differential diagnoses from common hypervascular neoplasms of liver. The final diagnosis is established on histopathological and immunohistochemical studies that are the “gold standard.”

Abbreviations: 3D = three-dimensional, AFP = alpha-feto-protein, CA-125 = carbohydrate antigen125, CPR = curved planar reconstruction, CT = computed tomography, FNH = focal nodular hyperplasia, HCA = hepatocellular adenoma, HCC = hepatocellular carcinoma, HCH = hepatic cavernous hemangioma, HMB45 = human melanoma black 45, MIP = maximum intensity projection, PEComa = perivascular epithelioid cell tumor, SMA = smooth muscle actin, VRT = volume rendering technique.

Keywords: computed tomography, hepatic, imaging, PEComa, perivascular epithelioid cell tumor

1. Introduction

Perivascular epithelioid cell tumor (PEComa) is a rare tumor, comprising a group of mesenchymal neoplasms, including angiolipomas, lymphangioliomyomatosis, clear cell “sugar”

tumors, clear cell myomelanocytic tumors, sarcoma of perivascular cells, and pigmented melanotic tumors.^[1,2] In our case report, we follow the criterion proposed by Martignoni et al^[2] that hepatic PEComa is a true neoplasm without adipocytes and abnormal vessels. Computed tomography (CT) imaging typically demonstrates a heterogeneous hypo-dense mass with either well or ill-defined margin.^[3–6] Contrast-enhanced CT in almost all hepatic PEComas shows marked enhancement in arterial phase, while mild-to-moderate enhancement in equilibrium phase.^[7] The final diagnosis of PEComa is established on its histopathological characteristics, including epithelioid cells without adipocytes or abnormal blood vessels, and on immunohistochemical evidence, including positive human melanoma black 45 (HMB-45), melanocytic, and smooth muscle markers.^[4]

2. Case report

A 36-year-old female was admitted to the First Affiliated Hospital of Dalian Medical University with abdominal distention, cramps, and low-grade fever for over 15 days. She had previously experienced gastric adenocarcinoma with ovarian, celiac lymph nodes, and retroperitoneal lymph nodes metastases. Laboratory investigation revealed alpha-feto-protein (AFP) level of 10.44 IU/mL (normal ranges of AFP 0–5.8 IU/mL) and carbohydrate antigen125 (CA-125) of 202.90 U/mL (normal ranges of CA-125 0–35 U/mL).

The patient subsequently had a noncontrast CT scan of abdomen and demonstrated a 3.7 cm × 2.4 cm ill-defined hypodense lesion with an average CT value of 55 HU in S8 of the liver (Fig. 1). On the

Editor: N/A.

Drafting of the manuscript: XH; images interpretation: XH, M-YS, and M-YW; images collection: J-HL, X-YZ, and RF; English writing revision: SQ.

This article does not contain any studies with human participants performed by any of the authors.

All of us certify that this manuscript is a unique submission and is not being considered for publication by any other source in any medium.

The authors have no conflicts of interest to disclose.

^a The First Affiliated Hospital of Dalian Medical University, Dalian, Liaoning,

^b Cancer Hospital of Peking University, Beijing, ^c The Chinese University of Hong Kong, Shatin, Hong Kong, China.

* Correspondence: Mei-Yu Sun, The First Affiliated Hospital of Dalian Medical University, Dalian, Liaoning 116011, China (e-mail: sunmy828@126.com).

Copyright © 2017 the Author(s). Published by Wolters Kluwer Health, Inc. This is an open access article distributed under the terms of the Creative Commons Attribution-Non Commercial License 4.0 (CCBY-NC), where it is permissible to download, share, remix, transform, and buildup the work provided it is properly cited. The work cannot be used commercially without permission from the journal.

Medicine (2017) 96:49(e9046)

Received: 25 October 2017 / Received in final form: 12 November 2017 /

Accepted: 13 November 2017

<http://dx.doi.org/10.1097/MD.0000000000009046>

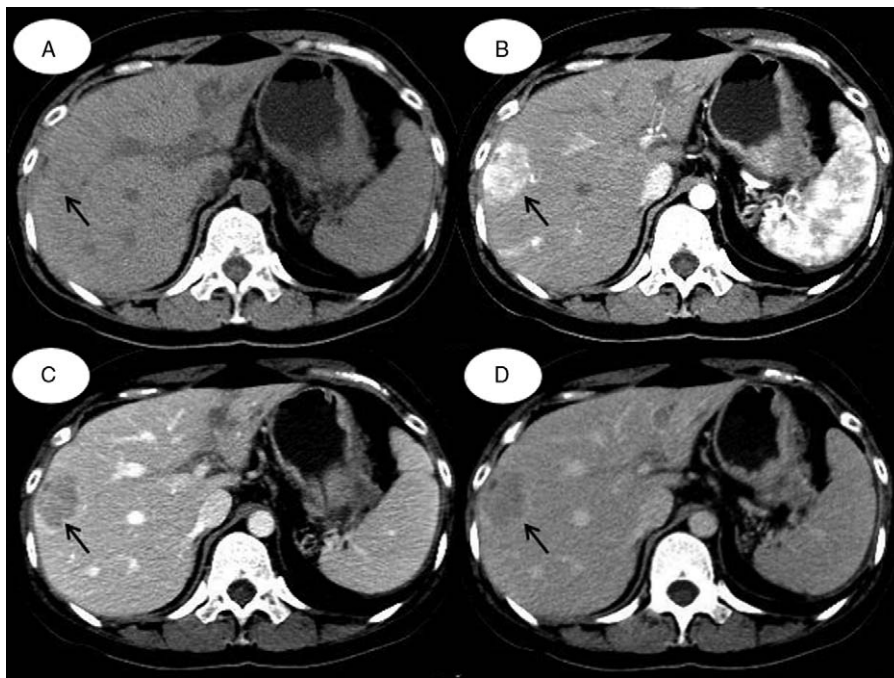


Figure 1. CT image of hepatic PEComa. A, Noncontrast CT image reveals a slightly hypodense lesion in the right lobe of liver. B, Contrast-enhanced CT image demonstrates marked and heterogeneous enhancement during the arterial phase (arrow). C and D, The contrast agent is washout during the portal and equilibrium phase (arrows). CT = computed tomography, PEComa = perivascular epithelioid cell tumor.

dynamic contrast-enhanced CT images, the CT values of this lesion were 118 HU, 110 HU, and 88 HU in arterial, portal, and equilibrium phases. It showed marked heterogeneous enhancement in arterial phase, with a tortuous vessel arising from right hepatic artery feeding the tumor (Fig. 2). The images in the portal phase showed slightly washout of partial areas inside the tumor. In the equilibrium phase, the contrast agent was persistent washout. Based on clinical history and CT features, a probability of liver metastasis was rendered.

The patient underwent biopsy for the lesion. Pathological finding revealed a neoplasm with sheets and nests of pleomorphic round epithelioid cells, infiltrating adjacent liver and there was no fatty component (Fig. 3A). Immunohistochemical results revealed the tumor cells were positive for HMB-45 (Fig. 3B), smooth muscle actin (SMA), and melan-A. The pathological and immunohistochemical findings confirmed hepatic PEComa.

3. Discussion

PEComas are neoplasms of mesenchymal origin, and relatively rarer, malignant variants even more so.^[8,9] They have been documented in various anatomical sites, most frequently in the uterus whereas particularly uncommon in liver.^[2] Almost all the PEComas were identified to be strongly positive for HMB-45, SAM, and Melan-A, which are helpful for confirming the diagnosis.^[1-3]

We summarize literature published in English after researching PubMed online database and inclusion terms are “hepatic” and “PEComa.” Twenty-nine cases (31 lesions) were found with primary hepatic PEComas, including our present patient, from 24 articles (Table 1).

The patients’ median age is 51 years (range 25–72 years). The maximum diameter of the tumors ranged from 0.8 to 19 cm (mean 5.96 cm). Male-to-female ratio is 6:23. Nine lesions are arising from the left lobe of the liver while rest lesions are from the

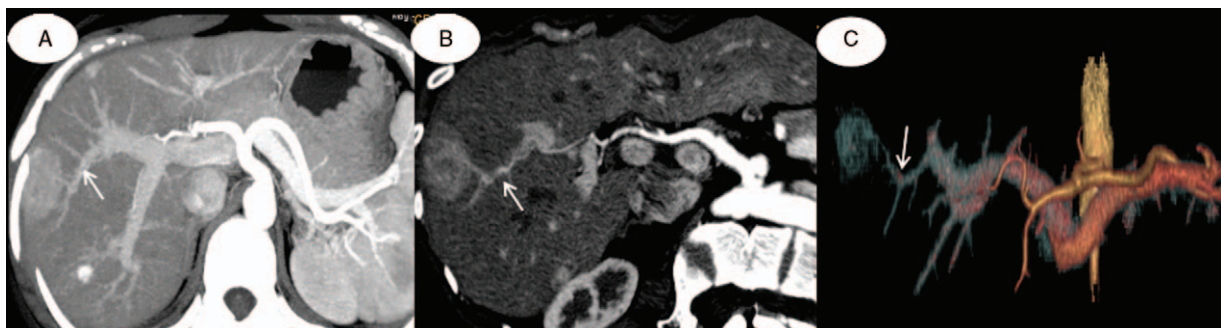


Figure 2. Post procedure processing with (A) maximum intensity projection, (B) curved planar reconstruction, and (C) volume rendering technique algorithm. It shows the feeding vessel from the right hepatic artery (arrows).

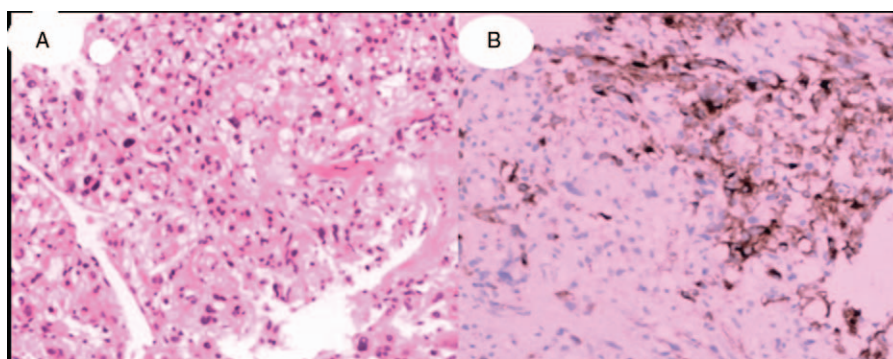


Figure 3. A, Histology (×100). Sheets and nests of pleomorphic round epithelioid cells, infiltrating adjacent liver and there is no fatty component. B, Immunohistochemistry (×100). Tumor cells show strong expression of HMB-45. HMB-45 = human melanoma black 45.

right lobe (22/31). The vast majority of PEComas are solitary lesions (28/29), and only 1 case reported to have 3 lesions at initial diagnosis.^[2]

The iso or hypodensity lesions with or without patchy lower density areas are described on noncontrast CT images. Only 3 cases (3/29) are reported as malignant PEComas.^[9–11] The malignant ones are heterogeneous lesions with obvious central necroses^[9] or with minute calcifications.^[10] Twenty-three lesions

have detailed description of contrast-enhanced CT imaging characteristics. After contrast administration, 18 lesions show marked and heterogeneous enhancement in the arterial phase and slightly hypodense in the portal phase or equilibrium phase, including our case. The patchy lower density areas in the tumor are seen with no contrast uptake on contrast-enhanced CT images. There are 4 lesions with heterogeneous enhancement in the arterial phase and persistent enhancement in equilibrium

Table 1

The authors, age, gender, location, size, enhanced CT imaging features, immunohistochemistry and preoperative diagnosis of 29 cases of hepatic perivascular epithelioid cell tumor.

Authors	Age	Gender	Location	Size (cm)	Contrast-enhanced CT imaging feature	HMB-45	SAM	Melan-A	PD
Xu Han ^(our case)	36	F	S8	3.7	washout pattern	+	+	+	Metastasis
Yin et al ^[3]	40	F	S4	9.4	persistent enhancement	+	–	–	UN
			S5	5	UN	+	–	–	UN
			S6	2.5	UN	+	–	–	UN
Liu et al ^[4]	25	F	S7	1.8	washout pattern	+	+	–	UN
Maebayashi et al ^[5]	58	M	S3	4.5	washout pattern	+	+	+	Inflammatory
Ameurtesse et al ^[6]	63	F	S4	8	UN	+	+	+	UN
Yu et al ^[7]	41	F	S6	1.9	washout pattern	+	–	+	HCC
CHEN et al ^[8]	44	F	RL	2.9	unenancement	+	+	+	Cyst
	37	F	LL	1.7	washout pattern	+	+	+	HCC
	43	M	LL	5	washout pattern	+	+	+	HCH
	57	F	S1	5	washout pattern	+	+	+	HCC
Abhirup et al ^[9]	72	F	S8	10	UN	+	+	+	UN
Selvaggi et al ^[10]	42	M	between S5 and S8	7	UN	+	+	+	UN
Parfitt et al ^[11]	60	F	RL	14	UN	+	–	+	HCC
Paiva et al ^[12]	51	F	RL	0.8	UN	+	–	–	UN
Tang et al ^[13]	32	F	S5	6.5	persistent enhancement	+	+	–	HCC
Hao et al ^[14]	51	F	S6	8	washout pattern	+	+	+	FNH
	30	F	S8	2.5	washout pattern	+	+	+	HCC
	25	M	S6	8	washout pattern	+	+	+	HCH
Wang et al ^[15]	29	F	S5	19	persistent enhancement	+	+	+	HCA
Khan et al ^[16]	61	M	S7	4.5	washout pattern	+	–	–	UN
Zhang et al ^[17]	63	F	RL	3.5	washout pattern	+	+	–	HCC
Khaja et al ^[18]	51	F	RL	UN	washout pattern	+	–	+	UN
Zhao et al ^[19]	58	M	RL	6	washout pattern	+	+	–	UN
Priola et al ^[20]	36	F	LL	UN	persistent enhancement	+	+	+	UN
Paiva et al ^[21]	51	F	LL	0.8	UN	+	–	–	Metastasis
Guan et al ^[22]	40	F	S8	7.5	washout pattern	+	+	–	HCA
Son et al ^[23]	56	F	S5	4.5	washout pattern	+	+	+	HCC
Tay et al ^[24]	51	F	between S2 and S3	9	washout pattern	+	+	–	HCC
Cheung et al ^[25]	53	F	RL	10	washout pattern	+	–	+	UN

FNH = focal nodular hyperplasia, HC = hepatic cyst, HCA = hepatocellular adenoma, HCC = hepatocellular carcinoma, HCH = hepatic cavernous hemangioma, LL = left lobe, PD = preoperative diagnosis, RL = right lobe, UN = unavailable

phase. One lesion is unenhanced.^[8] In our case, maximum intensity projection (MIP), curved planar reconstruction (CPR), and volume rendering technique (VRT) algorithm are created for three-dimensional (3D) reconstruction and it is able to precisely show the supplying vessel for the tumor. This is the first paper that demonstrates the characteristic of tumor-feeding artery.

Immunohistochemical staining results show that all lesions are positive for human melanoma black 45 (HMB45) stain. Other positive immunostains are also reported including smooth muscle actin (SMA) (21/31) and melan-A (19/31).

The differential diagnoses of PEComas at imaging are wide; therefore, it is difficult to reach definite diagnosis preoperatively. Eighteen cases had mentioned imaging diagnosis was misleading to other diseases. Hence radiologists should promote cognition.

The differential diagnoses with imaging features similar to PEComas are as follows: hepatocellular carcinoma (HCC). To differentiate a HCC from a PEComa, we should consider the background of viral hepatitis or cirrhosis and the AFP level needs to be taken into account. Typical manifestation of HCC on contrast-enhanced CT is a hypodense tumor which is markedly enhanced in the arterial phase with the contrast reagent drain out in the portal and equilibrium phases. Pseudocapsule can also be seen in most cases. Metastasis. The patient with metastasis usually has a history of primary neoplasm. Necrosis, cystoid degeneration, and calcification were seen frequently. Ring enhancement is common on the contrast-enhanced CT image. Some metastases are surrounded by low-density edema. Our case represented a hepatic PEComa coexisting with a gastric adenocarcinoma. Combined with imaging features and the “monist” view, we make it a priority to metastasis. Hepatic cavernous hemangioma (HCH). The mass displays the nodosity enhancement in arterial phase, contrast medium fills gradually in portal phase, and prolonged enhancement during the equilibrium phase. Hepatocellular adenoma (HCA). It mainly occurs in young women who had an oral contraceptives history. Typical imaging findings suggest homogeneous enhancement in arterial phase and prolonged mild enhancement with well-defined margin. Moreover, rupture and bleeding may occur for a larger HCA. Some of HCA are surrounded by a low-density ring due to fatty infiltration. Focal nodular hyperplasia (FNH). CT imaging shows an ill-delineated, heterogeneously enhanced mass with a central star-like scar. The tumor has an early mild enhancement in arterial phase whereas marked enhancement in portal and equilibrium phases. The central scar appears hypodense in noncontrast CT and slightly delayed enhancement in equilibrium phase.

4. Conclusion

In summary, we can draw a conclusion that hepatic PEComa has a marked female predominance. The right lobe of the liver is the most common site and the lesion is usually solitary. It is most common that a heterogeneous hypodense lesion with marked enhancement in arterial phase and washout in portal or equilibrium phases. Persistent enhancement is observed in a few cases. When the CT features appear as explained above, PEComas should be taken into account as a rare differential diagnosis in addition to those common liver neoplasms. The lesions with obvious central necrosis or with minute calcification may be characteristics of the malignant ones. A wide immunohistochemical panel is necessary to approach this dilemma. If the lesion is positive for HMB-45, SAM, and melan-A additionally, there is a high likelihood of a PEComa. The diagnostic criteria of PEComa depend on histopathological findings.

References

- Martignoni G, Pea M, Reghellin D, et al. Molecular pathology of lymphangiomyomatosis and other perivascular epithelioid cell tumors. *Arch Pathol Lab Med* 2010;134:33–40.
- Martignoni G, Pea M, Reghellin D, et al. PEComas: the past, the present and the future. *Virchows Arch* 2008;452:119–32.
- Lan YZ, Hua XE. Hepatic multiple perivascular epithelioid cell neoplasm: a case report and literature review. *Mol Clin Oncol* 2016; 4:619–21.
- Liu D, Shi D, Xu Y, et al. Management of perivascular epithelioid cell tumor of the liver: a case report and review of the literature. *Oncol Lett* 2014;7:148–52.
- Maebayashi T, Abe K, Aizawa T, et al. Improving recognition of hepatic perivascular epithelioid cell tumor: case report and literature review. *World J Gastroenterol* 2015;21:5432–41.
- Ameurtesse H, Chbani L, Bennani A, et al. Primary perivascular epithelioid cell tumor of the liver: new case report and literature review. *Diagn Pathol* 2014;9:149.
- Yu D, Tang S. Hepatic perivascular epithelioid cell tumor: a case report and review of the literature. *Intern Med* 2013;52:1333–6.
- Chen W, Liu Y, Zhuang Y, et al. Hepatic perivascular epithelioid cell neoplasm: a clinical and pathological experience indistinguishable and treatment. *Mol Clin Oncol* 2017;6:487–93.
- Abhirup B, Kaushal K, Sanket M, et al. Malignant hepatic perivascular epithelioid cell tumor (PEComa)—case report and a brief review. *J Egypt Natl Canc Inst* 2015;27:239–42.
- Selvaggi F, Risio D, Claudi R, et al. Malignant PEComa: a case report with emphasis on clinical and morphological criteria. *BMC Surg* 2011;11:3.
- Parfitt JR, Bella AJ, Izawa JI, et al. Malignant neoplasm of perivascular epithelioid cells of the liver. *Arch Pathol Lab Med* 2006;130:1219–22.
- Paiva CE, Moraes Neto FA, Agaimy A, et al. Perivascular epithelioid cell tumor of the liver coexisting with a gastrointestinal stromal tumor. *World J Gastroenterol* 2008;14:800–2.
- Tang D, Wang J, Tian Y, et al. Hepatic perivascular epithelioid cell tumor: case report and brief literature review. *Medicine (Baltimore)* 2016;95:e5572.
- Hao BB, Rao JH, Fan Y, et al. Hepatic perivascular epithelioid cell tumor in three patients. *Hepatobiliary Pancreat Dis Int* 2016;15: 660–4.
- Wang ZS, Xu L, Ma L, et al. Hepatic falciform ligament clear cell myomelanocytic tumor: a case report and a comprehensive review of the literature on perivascular epithelioid cell tumors. *BMC Cancer* 2015;15:1004.
- Khan HM, Katz SC, Libbey NP, et al. Hepatic PEComa: a potential pitfall in the evaluation of hepatic neoplasms. *BMJ Case Rep* 2014;pii: bcr2014204122.
- Zhang X, Wang L, Jiang Y, et al. Hepatic perivascular epithelioid cell tumors-not otherwise specified: a case report. *Nan Fang Yi Ke Da Xue XueBao* 2014;34:1–4.
- Khaja F, Carilli A, Baidas S, et al. PEComa: a perivascular epithelioid cell tumor in the liver—a case report and review of the literature. *Case Rep Med* 2013;2013:904126.
- Zhao LJ, Yang YJ, Wu H, et al. Perivascular epithelioid cell tumor of the liver: a case report and literature review. *Eur Rev Med Pharmacol Sci* 2013;17:1665–8.
- Priola AM, Priola SM, Cataldi A, et al. Acute abdomen as an unusual presentation of hepatic PEComa. A case report. *Tumori* 2009;95:123–8.
- Paiva CE, Moraes Neto FA, Agaimy A, et al. Perivascular epithelioid cell tumor of the liver coexisting with a gastrointestinal stromal tumor. *World J Gastroenterol* 2008;14:800–2.
- Guan H, Zou Y, Lv Y, et al. Hepatic perivascular epithelioid cell tumor treated by transarterial embolization plus radiofrequency ablation: a case report and literature review. *Medicine (Baltimore)* 2017;96:e6969.
- Son HJ, Kang DW, Kim JH, et al. Hepatic perivascular epithelioid cell tumor (PEComa): a case report with a review of literatures. *Clin Mol Hepatol* 2017;23:80–6.
- Tay ShY, Lao WT, Chen ChL, et al. Contrast-enhanced CT and angiographic findings in hepatic perivascular epithelioid cell tumor. *JBR-BTR* 2013;96:308–10.
- Cheung TT, Trendell-Smith N, Poon RT. Primary perivascular epithelioid cell tumour (PEComa) of the liver. *BMJ Case Rep* 2013; pii: bcr2013008706.