

Case Report

Laparoscopic approach to the management of penetrating traumatic diaphragmatic injury

Teo Li Tserng*, Maria Benita Gatmaitan

Department of Surgery, Trauma and Acute Care Surgery Service, Tan Tock Seng Hospital, Singapore

ARTICLE INFO

Article history:

Accepted 21 May 2017

Available online 5 August 2017

Keywords:

Laparoscopy

Diaphragmatic injury

Thoracoabdominal injury

Traumatic diaphragmatic injury

ABSTRACT

Background: Traditionally, laparotomy/thoracotomy is the standard approach for thoracoabdominal injuries. However, it has a non-therapeutic rate of 12–40% and 40% morbidity. Laparoscopy, as a diagnostic and therapeutic modality, has evolved to be integral to general and subspecialty surgeons in the management of patients. However, its use in the field of trauma surgery has been limited. We present a case of traumatic diaphragmatic injury from a low velocity penetrating wound successfully repaired through laparoscopic approach.

Case presentation: A 20 year old male, presented with a traumatic diaphragmatic injury secondary to a low velocity penetrating injury. A computed tomographic scan revealed a tear on the left diaphragm with the superior pole of the spleen and omentum eviscerating through. He subsequently underwent diagnostic laparoscopy and primary repair of the diaphragmatic injury. His recovery was uneventful and he was discharged on the third postoperative day.

Conclusion: A review of current literature and our case suggest that the use of laparoscopy for the management of penetrating thoracoabdominal injuries is continually evolving and has shown to be a promising approach compared to traditional laparotomy in carefully selected patients. Laparoscopic repair of penetrating traumatic diaphragmatic injuries is a safe and expedient option for hemodynamically stable patients.

© 2017 Published by Elsevier Ltd. This is an open access article under the CC BY-NC-ND license (<http://creativecommons.org/licenses/by-nc-nd/4.0/>).

Introduction

Traumatic injuries to the diaphragm were previously diagnosed in autopsies, first of which was in 1541 by Sennertus, it was only in 1800s that diaphragmatic injuries were diagnosed antemortem [1]. Diaphragmatic injury as a result of penetrating trauma ranges from 0.8% to 15% [2]. This was traditionally managed by mandatory exploration on the premise that it was the only way to ensure that no associated intraabdominal injuries have been missed. However, studies have shown that 12–40% of these were nontherapeutic explorations, for which, prompted the need for alternative approach to the management of traumatic diaphragmatic injury (TDI).

The first reported laparoscopy for TDI was in 1984 by Adamthwaite, when he performed laparoscopy for 10 suspected TDI patients. Of the ten, 2 did not show any injury to the diaphragm, thus avoiding a non therapeutic laparotomy [3]. Ten years later the first therapeutic laparoscopy for TDI was done, saving the patient a laparotomy.

* Corresponding author.

E-mail address: li_tserng_teo@ttsh.com.sg (T.L. Tserng).

We describe hereinto, the application of primary repair for a penetrating TDI successfully done through the laparoscopic approach. This is followed by a review of current existing literature on laparoscopic approaches to TDI.

Case

A 20 year old male, with unremarkable past medical history, presented to the emergency department(ED) with penetrating abdominal injuries. On primary survey, he was not in respiratory distress, not tachycardiac and normotensive. He sustained multiple stab wounds, 1×2 cm at level of T12, at the right flank, and a 1×2 cm at 7th intercostal space mid axillary line on the left. On auscultation there was decreased air entry in the left lung field with basal crackles. He was resuscitated according to ATLS protocols. Supine chest X-ray was negative for pneumothorax and hemothorax. (Fig. 1) Focused Abdominal Sonography for Trauma (FAST) showed no evidence of free fluid in all four compartments. He remained stable while in emergency department.

A computed tomography (CT) scan of abdomen with IV contrast was performed. It revealed two stab wounds. One over the right flank extending to subcutaneous layer at the inferior edge of right latissimus dorsi with hematoma, without peritoneal breach. (Fig. 2). The other was over the left posterolateral inferior chest wall. A small left pneumothorax with minimal atelectasis was noted. A focal defect of 1.5 cm was seen over the lateral aspect of the left diaphragm with protrusion of a small amount of peritoneal fat and a nub of the spleen through the defect. Minimal amount of hemoperitoneum was noted.

Surgical technique

A 32F chest tube was inserted on the left thoracic cavity prior to surgery. He subsequently counselled and consented for a diagnostic laparoscopy and, keep in view open, repair of the diaphragmatic injury. An indwelling Foley catheter and Nasogastric tube were inserted post induction.

A 10 mm infraumbilical laparoscopic port was inserted and the CO₂ pneumoperitoneum was created. Under direct visualization, three 5 mm ports were inserted, one in epigastrium and two in the left subcostal area. A diagnostic laparoscopic assessment of the intra-abdominal organs was performed. A 2 cm left diaphragmatic laceration with an omental plug was noted. Manual reduction was performed by gently pulling on the omentum. (Figs. 3 and 4). A grade 1 splenic laceration was also noted on the superior pole with no active bleeding. A minimal amount of blood was noted in the pelvis. The left thoracic cavity was noted to be clean with no contamination. Both the left subdiaphragmatic space and left thoracic cavity were irrigated copiously. The diaphragmatic laceration was repaired incontinuity using V-loc 3/0 suture, a hemolock clip was placed at end of suture. (Fig. 5) During the operation, the left chest tube was intermittently clamped and released as needed to prevent the loss of pneumoperitoneum and also to avoid a tension pneumothorax.

The patient was extubated prior to transfer to Post Anesthesia Care Unit (PACU), and was subsequently sent to high dependency unit with adequate pain control and respiratory support. A chest X ray on post-operative day 3 showed good expansion without residual hemothorax. The left chest tube was removed and he was discharged the next morning.

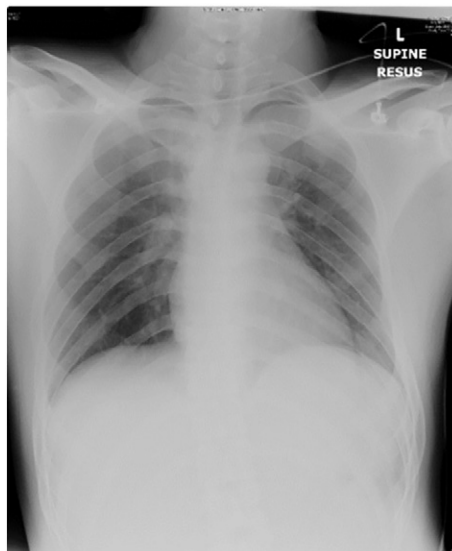


Fig. 1. Chest X ray on arrival.

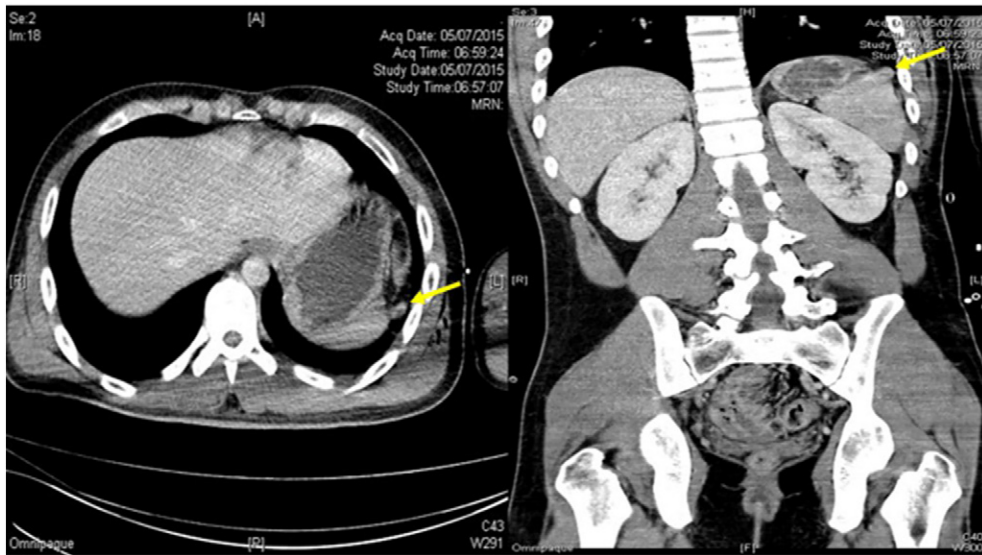


Fig. 2. CT scan showing a focal defect over lateral aspect of left diaphragm with protrusion of a small amount of peritoneal fat and nubbing of spleen through the defect (arrow).

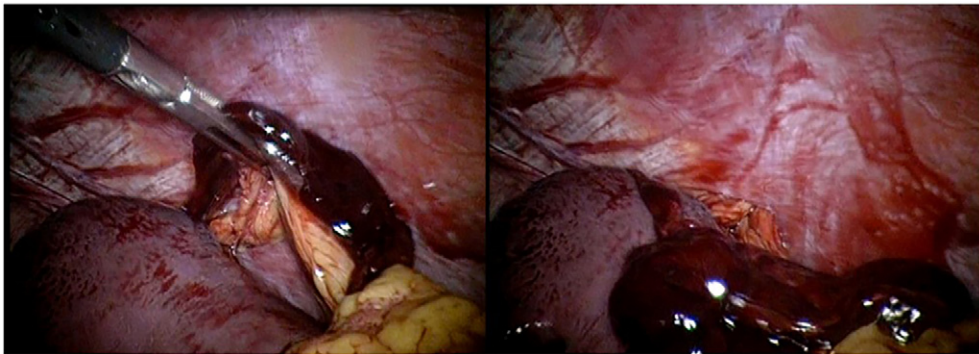


Fig. 3. Intraoperative view showing the omentum herniating into the diaphragmatic defect.

Discussion

During the initial assessment of any trauma patient, chest and pelvic radiographs are done as dictated by ATLS protocol. Hard signs for diaphragmatic injury, such as coiled nasogastric tube (in the chest) and a supradiaphragmatic air-fluid level are not

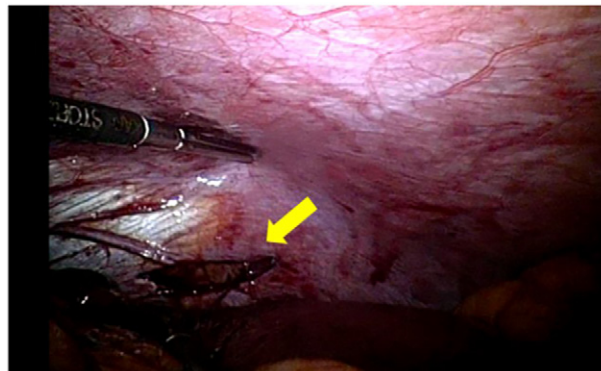


Fig. 4. Intraoperative findings, shows the diaphragmatic defect (arrow).

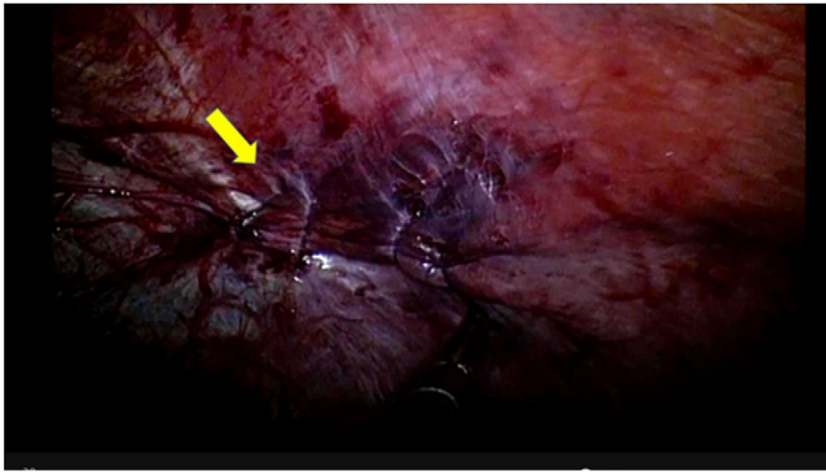


Fig. 5. Intraoperative finding, shows the defect repaired laparoscopically using V-loc nonabsorbable suture, continuous (arrow).

always seen in plain supine CXR. Such CXRs have a sensitivity of only 22.8% when read and interpreted by a trauma leader in the trauma bay [4]. Defects on the diaphragm usually do not manifest on initial plain films unless the intrathoracic and abdominal pressures equalize causing the visceral organs to herniate into the defect.

The advent of multi-slice detector CT scans have increased the yield of diagnosing diaphragmatic injuries with a sensitivity and specificity of 87% and 72% respectively for penetrating trauma. CT signs have been used to describe injuries to the diaphragm, such as 'collar sign', which is constriction of herniated viscus into the defect [5]. However, this modality should be used for patients who are hemodynamically stable, with no obvious peritonitis or visceration. Its indiscriminate use should be avoided in view of risks such as unnecessary radiation exposure and most importantly, possible delays in management.

The surgical management of TDI was conventionally done through exploratory laparotomy mainly to prevent missed associated injuries. This necessitates extensive upper midline laparotomy incision, which usually is complicated by postoperative pain, reduced respiratory efforts and wound infections. The use of laparoscopy in trauma patients has reduced the need for non-therapeutic laparotomy by a median of 57% (range 17–89%) [6]. The length of stay (LOS) for non-therapeutic laparoscopies was 1.5 days compared to 5.2 days for non-therapeutic laparotomies [7]. In a cost analysis study, it showed that laparoscopy, including costs incurred for patients who were converted to laparotomy, had significantly lower costs than laparotomy, with a total savings of US\$1059 per laparoscopy performed [8].

Table 1

Recommended repair of traumatic diaphragmatic injury according to grade of injury.

AAST grade of injury	Description	Recommended repair
Grade I	Contusion or hematoma without perforation	No surgical intervention
Grade II	Laceration <2 cm	2–0 or 1–0 absorbable suture
Grade III	Laceration 2 to 9 cm	First layer: 1–0 absorbable suture; interrupted, along irregular borders Second layer: 1–0 absorbable running
Grade IV	Laceration 10 to 25 cm	2–0 non-absorbable suture or 1–0 monofilament/braided suture; interrupted in two layers
Grade V	Laceration >25 cm	Use of fascia lata or an allogenic materials Use of PTFE mesh or advancement flap

(From Lucas CE, Ledgerwood AM: *Diaphragmatic Injury*. Current Therapy of Trauma and Surgical Critical Care. 2nd Edition, 2016.)

Table 2

Recommended indications for laparoscopy in penetrating trauma.

Penetrating trauma to the abdomen with documented or equivocal penetration of the anterior fascia
Penetrating thoracoabdominal trauma
Abdominal gunshot wounds with doubtful intraperitoneal trajectory (tangential gunshot wounds)
Suspected diaphragmatic injury
Nonoperative management with a progressive worsening of clinical, laboratory and imaging data, but always in hemodynamic stability

(From Mandala, et al., The Role of Laparoscopy in Emergency Abdominal Surgery'. Springer 2012).

Table 3

List of references for literature review on Laparoscopy in Traumatic Diaphragmatic Injury

Authors/studies	Journal and year published	Outcome/conclusion
Salvino, C., Esposito, T. et al.	J. Trauma; 1993	Diagnostic laparoscopy has a role in redefining DPL criteria for laparotomy and, in selected patients, as an adjunct to DPL, allowing further diagnosis and potentially the treatment of injuries without laparotomy.
Guth, A., Pachter, H.L., et al.	Journal of the Society of Laparoendoscopic Surgeons; 1998	While other authors have demonstrated its sensitivity in the detection of diaphragmatic injuries, we urge caution in its use as the primary diagnostic study in penetrating thoracoabdominal trauma based on our experience with missed major intrathoracic injuries, and are currently investigating the complementary role of thoracoscopy in penetrating lower thoracic injuries.
Leppaniemi A., Haapiainen R.	J Trauma; Feb 2003	Overall, diagnostic laparoscopy cannot be recommended as a routine diagnostic tool in anterolateral abdominal and thoracoabdominal stab wounds.
Leppaniemi A., Haapiainen R.	J Trauma; Jun 2003	Exclusion of an occult diaphragmatic injury with invasive diagnostic methods, such as laparoscopy or thoracoscopy, should be considered at least in left-sided stab wounds of the lower chest.
Friese, R., Coln, E., et al.	J Trauma; Jan 2005	In asymptomatic hemodynamically normal patients with penetrating thoracoabdominal injury, laparoscopy alone is sufficient to exclude diaphragmatic injury.
Warren, O., Kinross, J., et al.	World Journal of Emergency Surgery; Aug 2006	Laparoscopy in trauma provides direct visualization of the left diaphragm and more limited visualization of the right diaphragm, and if found intact, laparotomy may be avoided.
Hanna, W., Ferri, L., et al.	Ann of Thorac Surg; 2008	The high association of intraabdominal injuries, irrespective of the location of penetrating wounds, mandates that traumatic diaphragmatic injuries be approached from the abdomen in patients who require exploration. Stable patients with suspicion of diaphragmatic injury may be evaluated by thoracoscopy.
Hanna, W., Ferri, L., et al.	Thorac Surg Clin; 2009	In hemodynamically stable patients with penetrating left thoracoabdominal trauma, the incidence of injury to the diaphragm is very high, thoracoscopy or laparoscopy is recommended for the diagnosis and repair of a missed diaphragmatic injury.
Como, J., Bokhari, F., et al.	J. Trauma; Mar 2010	Diagnostic laparoscopy may be considered as a tool to evaluate diaphragmatic lacerations and peritoneal penetration in an effort to avoid unnecessary

Table 3 (continued)

Authors/studies	Journal and year published	Outcome/conclusion
Barzana, D., Kotwall, C., et al.	Journal of the Society of Laparoendoscopic Surgeons; 2011	laparotomy. Although our small series shows laparoscopy to be a safe and effective diagnostic and therapeutic tool, particularly in patients with isolated bowel and diaphragm injuries, it must be used judiciously and by surgeons with expertise in advanced laparoscopic techniques.
Ahmed, A.	World Journal of Laparoscopic Surgery; Jan 2011	Repair of traumatic diaphragmatic ruptures and tears are treated laparoscopically using suture, stapler or properly sized synthetic mesh.
Wiewiora, M., Sosada, K., et al.	Videosurgery and other miniinvasive techniques; 2011	Diagnostic laparoscopy should be used with caution only in selected cases due to the limited amount of reliable data confirming the effectiveness of such treatment.
Mandala, V., Mirabella, A., et al.	Springer; 2012	Laparoscopy offers best diagnostic accuracy in suspected diaphragmatic injury, in which imaging occult injury rates are significant.
O'Malley, E., Boyle, E., et al.	World Journal of Surgery; Jan 2013	Laparoscopy has screening, diagnostic and therapeutic roles, particularly where diaphragm injury is suspected.
Ties, J., Peschman, J., et al.	J. Trauma Acute Care Surg.; 2014	While the majority of injuries were repaired with laparotomy, minimally invasive repairs were used more frequently in the recent period.
Berg, R., Karamanos, E., et al.	J Trauma Acute Care Surg; 2014	High incidence of hollow viscus injury and diaphragmatic injuries ultimately limits nonoperative management. Laparoscopy is necessary to exclude occult diaphragmatic injuries.
Chestovich, P., Browder, T., et al.	J Trauma Acute Care Surg; 2015	Laparoscopy is safe and accurate in penetrating abdominal injuries.
Society of American Gastrointestinal and Endo- scopic Sur- geons	http://www.sagescms.org	Diagnostic laparoscopy has been proposed for trauma patients to prevent unnecessary exploratory laparotomies with their associated higher morbidity and cost. One of its indications is for the diagnosis of diaphragmatic injury from penetrating trauma to the thoracoabdominal area.
Bendinelli, C., Balogh, Z., et al.	http://www.intechopen.com/books/advances-in-laparoscopic-surgery/laparoscopy-in-trauma-patients	In trauma patients laparoscopy may avoid unnecessary (non-therapeutic) laparotomy, may improve operative visualization of diaphragm, and may allow laparoscopic repair of these injuries
Ransom, K., Smith, S., et al.	http://laparoscopy.blogs.com/prevention_management_3/2011/01/laparoscopy-for-trauma.html	The most established role for laparoscopy in trauma is the diagnosis of abdominal injuries. Laparoscopy is the most reliable diagnostic technique to identify, and in many cases repair, diaphragmatic injuries.

The use of laparoscopy in the field of trauma is limited by concerns regarding missed injuries as demonstrated by a study which showed 18% sensitivity of laparoscopy for hollow viscus injuries [9]. Laparoscopy for these types of injuries may be of limited value at this time but has good potential to improve with more experience with this technique. However, the most beneficial role of laparoscopy for trauma is for hemodynamically stable patients with penetrating wounds to the thoracoabdominal area. Injuries to the diaphragm is the most frequently missed but has complications of potential herniation and even strangulation of abdominal organs through the diaphragmatic defect which may manifest itself months after the incident. Laparoscopy has a sensitivity, specificity and negative predictive value of 100%, 87.5% and 96.8% for diaphragmatic injuries after penetrating trauma [10]. The Eastern Association for the Surgery of Trauma (EAST) has recently established the role of laparoscopy for these patients and recommended that diagnostic laparoscopy should be strongly considered in patients with penetrating trauma to the left thoracoabdominal area who have no other indications for laparotomy to rule out and to potentially repair diaphragmatic injuries [11]. In a study by Mandala, et al., he mentioned several indications for the use of laparoscopy for penetrating trauma as shown in Table 2 [12].

Prior to induction, a decision was made to place a 32F chest tube on the affected side where the diaphragmatic defect was. This is to prevent the exacerbation of pneumothorax, a difficulty in maintaining pneumoperitoneum without compromising ventilation and retention of carbon dioxide into the thoracic cavity once the pneumoperitoneum is created on abdominal insufflation. The thoracostomy tube was intermittently clamped and released to allow escape of carbon dioxide and minimize changes in hemodynamic and respiratory variables, such as airway pressure and end-tidal CO₂, which will ultimately affect ventilation [11]. Intermittent clamping of the tube also minimizes the loss of pneumoperitoneum, allowing laparoscopy to proceed with adequate visualization. Studies have shown that flow rate of 10 mm Hg is adequate to have good visualization and a tension-free closure of the diaphragmatic defect.

For small diaphragmatic rents, some surgeons prefer not to insert a chest tube prior to surgery. If this is the preferred method, a rubber catheter is placed through the laceration in the diaphragm and into the thoracic cavity, via one of the port sites and then connected to suction. Air and fluid are then evacuated as closure of defect is done. With the lungs in maximal inspiration, the last stitch is drawn and the catheter pulled out of the chest. Postoperatively, chest radiograph is mandatory to ensure absence of pneumothorax.

Repair of any diaphragmatic injury depends on the severity of injury and the associated amount of tissue loss. Table 1 summarizes the recommended repair of diaphragmatic injury based on injury grade [13]. (Refer to Table 1.) However, majority of surgeons still prefer interrupted in two layers using non-absorbable 2–0 or 1–0 monofilament or braided suture. The basic principles of a tension-free repair still apply for laparoscopically sutured defects. A figure-of-eight or horizontal mattress, either with single layer repair or two-layer closure can be done. If it appears that tension cannot be avoided, pledgets can be used to prevent tearing of the diaphragmatic muscle. Larger defects would require either a use of PTFE mesh or an advancement flap if significant tissue loss is present.

The author used the V-lock® 3–0, non-absorbable suture for the repair of the diaphragmatic rent. V-lock® is an endo stitch that has barb and loop design that eliminates the need for knot tying. The barbs grasp the tissue at different points to spread the tension across the wound providing closure [14]. Choice of suture and technique of suturing is highly dependent on the surgeon's experience with the material being used (Table 3).

Conclusion

Published studies on the use of laparoscopy for diaphragmatic injuries are limited and results varied. In this study, we demonstrated the use of laparoscopy in the diagnosis and definitive care of a patient with TDI from a low velocity wound. The peri-operative insertion of a chest tube is dependent on the open communication between the surgeon and anesthesiologist. We have presented a case of penetrating TDI successfully and safely managed with diagnostic laparoscopy and laparoscopic repair of the diaphragmatic injury.

There is a shift in the current standard of care for penetrating thoraco-abdominal injuries in hemodynamically stable patients towards a minimally invasive technique. Laparoscopy is slowly becoming a surgical alternative to the traditional laparotomy. It is becoming a promising, better and practical therapeutic option, for carefully selected patients. Therefore, we recommend that a laparoscopic approach to penetrating thoraco-abdominal TDIs be an option in managing such patients.

Acknowledgement

The authors are grateful to the support provided by the Department Chair, Mr. Chiu Ming Terk, and the rest of the Trauma and Acute Care Surgery Service of our institution.

References

- [1] Reid J. Diaphragmatic hernia. *Edin Med Surg J.* 1840;53:104–7.
- [2] M. Neal, *Abdominal trauma, The Trauma Manual: Trauma and Acute Care Surgery*, fourth ed. 2013, pp. 365–367.
- [3] D.N. Adamthwaite, Traumatic diaphragmatic hernia: a new indication for laparoscopy, *Br. J. Surg.* 71 (1984) 315.
- [4] W.C. Hanna, L.E. Ferri, The current status of traumatic diaphragmatic injury: lessons learned from 105 patients over 13 years, *Ann. Thorac. Surg.* 85 (2008) 1044–1048.
- [5] U.K. Bodanapally, K. Shanmuganathan, MDCT diagnosis of penetrating diaphragmatic injury, *Eur. Radiol.* 19 (2009) 1875–1881.

- [6] D. Stefandi, W.S. Richardson, The role of diagnostic laparoscopy for acute abdominal conditions: an evidence-based review, *Surg. Endosc.* 23 (2009) 16–23.
- [7] A.A. Guth, H.L. Pachter, Laparoscopy for penetrating Thoracoabdominal trauma: pitfalls and promises, *J. Soc. Laparoendosc. Surg.* 2 (1998) 123–127.
- [8] J.M. Marks, D.F. Youngelman, Cost analysis of diagnostic laparoscopy versus laparotomy in evaluation of penetrating abdominal trauma, *Surg. Endosc.* 11 (3) (1997) 272–276.
- [9] R.R. Ivatury, R.J. Simon, W.M. Stahl, A critical evaluation of laparoscopy in penetrating abdominal trauma, *J. Trauma* 34 (1993) 822–828.
- [10] R.S. Friese, C.E. Coln, L.M. Gentilello, Laparoscopy is sufficient to exclude occult diaphragm injury after penetrating abdominal trauma, *J. Trauma* 58 (2005) 789–792.
- [11] M.F. Martin-Cancho, D. Celdran, Anesthetic considerations during laparoscopic surger, *Advanced Gynecologic Endoscopy* 2011.
- [12] V. Mandala, A. Mirabella, The role of laparoscopy in emergency abdominal surgery, *Spring* 23 (2012) 190–191.
- [13] C.E. Lucas, A.M. Ledgerwood, Diaphragmatic injury, *Current Therapy of Trauma and Surgical Critical Care*, second ed. 2016, pp. 307–316.
- [14] D. Porteinier, Laparoscopic suturing using the covidien V-Loc wound closure reload for endo stitch and sils stitch suturing device, *Procedural Breakthrough, General Surgery News*, November 2013.