

Fibrosis in Chronic Hepatitis C: Correlation between Immunohistochemically-Assessed Virus Load with Steatosis and Cellular Iron Content

Maha Akl¹, Ali EL Hindawi², Maha Mosaad², Ahmed Montasser^{1*}, Ahmed El Ray³, Heba Khalil¹, Amgad Anas³, Raffat Atta³, Valerie Paradis⁴, Ahmed Abdel Hadi¹, Olfat Hammam¹

¹Department of Pathology, Theodor Bilharz Research Institute, Imbaba, Giza, Egypt; ²Department of Pathology, Faculty of Medicine Cairo University, Cairo, Egypt; ³Department of Gastroenterology, Theodor Bilharz Research Institute, Imbaba, Giza, Egypt; ⁴Department of Pathology, Beaujon Hospital, Clichy, France

Abstract

Citation: Akl M, EL Hindawi A, Mosaad M, Montasser A, El Ray A, Khalil H, Anas A, Atta R, Paradis V, Abdel Hadi A, Hammam O. Fibrosis in Chronic Hepatitis C: Correlation between Immunohistochemically-Assessed Virus Load with Steatosis and Cellular Iron Content. Open Access Maced J Med Sci. 2016 Dec 15; 4(4):578-584. <https://doi.org/10.3889/oamjms.2016.122>

Keywords: Fibrosis; HCV; HCC; NS3/NS4; VEGF; VEGFR2; FISH.

***Correspondence:** Ahmed Montasser. Theodor Bilharz Research Institute - Pathology, Warraq Al Hadar Embaba Giza, Cairo, Giza 12411, Egypt. E-mail: ahmed_montasser@yahoo.com

Received: 19-Sep-2016; **Revised:** 25-Oct-2016; **Accepted:** 27-Oct-2016; **Online first:** 15-Nov-2016

Copyright: © 2016 Maha Akl, Ali EL Hindawi, Maha Mosaad, Ahmed Montasser, Ahmed El Ray, Heba Khalil, Amgad Anas, Raffat Atta, Valerie Paradis, Ahmed Abdel Hadi, Olfat Hammam. This is an open-access article distributed under the terms of the Creative Commons Attribution-NonCommercial 4.0 International License (CC BY-NC 4.0).

Funding: Internal project 95T of TBRI, Principal Investigators Professor Dr Maha Akl and Ahmed EL Ray, Pathology Department of Beaujon Hospital, Clichy, France.

Competing Interests: The authors have declared that no competing interests exist.

AIM: We aimed study impact of hepatocytic viral load, steatosis, and iron load on fibrosis in chronic hepatitis C and role of VEGF and VEGFR overexpression in cirrhotic cases in evolving HCC.

MATERIAL AND METHODS: Total of 120 cases were included from TBRI and Beaujon Hospital as chronic hepatitis C (CHC), post-hepatitis C cirrhosis, and HCC. Cases of CHC were stained for Sirius red, Prussian blue and immunohistochemically (IHC) for HCV-NS3/NS4. HCC were stained IHC for VEGF and by FISH.

RESULTS: Stage of fibrosis was significantly correlated with inflammation in CHC ($P < 0.01$). Noticed iron load did not correlate with fibrosis. Steatosis was associated with higher inflammation and fibrosis. The cellular viral load did not correlate with inflammation, steatosis or fibrosis. VEGF by IHC was significantly higher in cases of HCC when compared to cirrhotic group ($P < 0.001$). Amplification of VEGFR2 was confirmed in 40% of cases of HCC. Scoring of VEGF by IHC was the good indicator of VEGFR2 amplification by FISH ($P < 0.005$).

CONCLUSION: Grade of inflammation is the factor affecting fibrosis in CHC. The degree of liver damage is not related to cellular viral load or iron load. Steatosis is associated with higher inflammation and fibrosis. VEGF by IHC is correlated with overexpression of VEGFR2 by FISH.

Introduction

Hepatitis C virus (HCV) is a global epidemic affecting approximately 3% of the world's population. Egypt has the highest prevalence of hepatitis C virus (HCV) in the world, estimated nationally at 14.7%. Our study's objective was to delineate the evidence on the epidemiology of HCV infection among the different population groups in Egypt and to draw analytical inferences about the nature of HCV transmission in this country [1]. In the 15–59 year age groups, the prevalence of HCV antibody was found to be 10.0% (95% CI = 9.5–10.5) and that of HCV RNA to be 7.0% (95% CI = 6.6–7.4). In children, 1–14 years old, the

prevalence of HCV antibody and HCV RNA were 0.4% (95% CI = 0.3–0.5) and 0.2% (95% CI = 0.1–0.3) respectively. Approximately, 3.7 million persons have chronic HCV infection in the age group 15–59 in 2015. An estimated 29% reduction in HCV RNA prevalence has been seen since 2008, which is largely attributable to the ageing of the group infected 40–50 years ago during the mass schistosomiasis treatment campaigns. Prevention efforts may have also contributed to this decline, with an estimated 75% (95% CI = 6–45) decrease in HCV incidence in the 0–19 year age groups over the past 20 years [2].

Steatosis is a complication of HCV infection and the mechanisms of its development are complex, involving viral and host factors. Steatosis that is

prevalently viral is associated with HCV genotype 3, and steatosis that is prevalently metabolic is associated with non-3 genotypes. Viral steatosis is correlated with the level of HCV replication, whereas metabolic steatosis is related to insulin resistance. The two types of steatosis have a different impact on HCV disease and may have an additive effect [3].

It has been generally accepted that either steatosis by itself aggravates fibrosis or the factors that are causing steatosis may be aggravating fibrosis. Overall, steatosis, whether metabolic or HCV induced, worsens the sequence of events leading to advanced fibrosis in patients with HCV and needs to be addressed when managing patients with HCV [4].

Syed and Sadiq [5] have found a positive association between HCV-NS3 immunopositivity and the histological parameters of grading and staging, suggesting that greater amounts of virus are present in more advanced chronic liver disease.

Iron overload in the liver induces oxidative stress leading to cell membrane damage, DNA instability and mutagenesis [6]. Due to these effects, iron can be considered a proinflammatory, profibrogenic factor and a potential carcinogen. Since the implementation of serological diagnostic tests for HCV identification, elevated serum iron-overload indices or appearance of iron deposits in liver cells have been observed in 10-40% of patients with chronic hepatitis C and 50% of patients suffering from both chronic hepatitis C (CHC) and HCC [7].

There is evidence that iron overload leads to an increased risk of HCC, failure of antiviral treatment and significantly worsens clinical outcomes in patients suffering from chronic HCV infection [8]. Clinically, HCC tends to be hypervascular and, for that reason, transarterial chemoembolization has proven to be effective in managing many patients with localised disease. More recently, angiogenesis has been targeted effectively with pharmacologic strategies, including monoclonal antibodies against vascular endothelial growth factor (VEGF) and VEGF receptors, as well as small-molecule kinase inhibitors of the VEGF receptor [9].

The aim of this paper was to study the impact of the hepatocytic viral load, hepatocytic steatosis, and hepatic iron and copper load on fibrosis in a sample of chronic hepatitis C and to study the role of VEGF and VEGFR overexpression in a sample of cirrhotic cases in evolving HCC.

Material and Methods

The material of this study is retrieved from the archives of Pathology Departments of Theodor Bilharz Research Institute – Giza, Egypt and Beaujon

Hospital – Clichy, France during the years 2013 and 2014. For each case, personal, medical and clinical data were obtained from the records of Pathology Departments of both centers and cases that match the following criteria were included: Positive HCV mRNA by PCR, no history of treatment or previous transplantation, no evidence of concomitant hepatitis B virus (HBV) infection, no evidence of parasitic liver disease, no diabetes mellitus and no malignancy other than HCC.

Ninety-four cases met the selection criteria. For each case:

A. Four- μm sections were cut from each paraffin block and stained with Hematoxylin and Eosin (H&E), Sirius red stain and Perl's Prussian blue stain.

B. Detailed histopathological assessment was done regarding:

- 1) the grade of inflammation and stage of fibrosis according to METAVIR scoring system [10];
- 2) the degree of steatosis according to the SAF algorithm [11]; and
- 3) the presence of ferric iron as blue or purple deposits [12] in Perl's Prussian blue-stained sections. We expressed the results of an iron load as positive or negative.

Immunohistochemical procedure

Immunohistochemistry for NS3/NS4 was performed on sections cut from the paraffin blocks with a commercially available mouse monoclonal Anti-Hepatitis C Virus NS3/NS4 antibody (ab113612, Abcam, USA). Briefly, 4 μm -thick sections are put onto positively charged slides (Superfrost plus, Menzel-Glaser, Germany) and the slides were stained by an automated platform—the Dako autostainer Link 48. Heat-induced antigen retrieval was used for 30 min at 97°C in the manufacturer's high-PH EnVision™ FLEX Target Retrieval Solution and the primary antibody was used at a dilution of 1 in 50. Sections from wedge liver biopsy obtained during open cholecystectomy operation performed to a patient with no serological evidence of HCV infection were added in each run, and the antibody was omitted to serve as negative control.

Interpretation of IHC

Immunohistochemical assessment of hepatocyte viral content was performed according to Rullier et al. (2001) [13]. Cells with powder-like brown cytoplasmic granules were considered positive and were semi-quantitated: Score 0: 0% positive cells; +1: <10% positive cells; +2: 10%-50 % positive cells; +3: >50% positive cells.

Photomicrography

Photomicrographs included in this study were captured for significant results and data by AxioCam MRc5 camera mounted to Zeiss Scope A1 Microscope (Hamburg, Germany).

FISH procedure

VEGFR2 FISH probe labelled in Orange 5-TAMRA dUTP was ordered from Empire Genomics (Buffalo, New York, USA) and preparation of slides was carried out according to their manual; *Probe details*: Gene: VEGFR2 (Orange 5-TAMRA dUTP), Loci: 4q12 and we use Spotlight FISH Tissue implementation kit (ZytoVision GmbH, Bremerhaven, Germany).

Slides were deparaffinized in Xylene for 15 min and repeated 1 more time. Then dehydrated in 100%, 100%, 90%, +80% ethanol each for 5 min. Washed 2 times, each 2 min in deionized water, Pretreatment by incubating slides with heat pretreatment solution for 15 min at 98°C, transfer slides immediately to deionized water for 2 min two times. Apply pepsin solution and incubate for 15min at 37°C. Then wash for 5 min in wash buffer SSC and 1 min in deionized water then dehydrate in 70%, 90% and 100% ethanol, each for 1 min. Air dry slides. Denaturation and Hybridization by pipetting 15 µl of VEGF probe each onto individual samples. Denature the slides at 75°C for 10min (on the hot plate), transfer the slides to a humidity chamber and hybridise overnight at 37°C in a hybridization oven. Post-hybridization and detection, remove the rubber cement by submerging in wash buffer for 3 min, and then incubate the slides in 70%, 90% and 100% ethanol. Each for 1 min. Air dry the samples while protected from light. Pipette 40 µl DAPI /DuraTect Solution on to the slides.

Interpretation of FISH

We used fluorescence microscope (Olympus X51) [using 2 filters red (FITC) and DAPI] using a × 100 oil immersion objective lens; the microscope is attached to high-resolution video camera (Jale) and monitor. We captured and interpreted photos using hardware (Cytovision 2.3, USA).

Statistical analysis

SPSS software version 18 was used for data management and analysis. Quantitative data were presented as mean ± SD. Qualitative data were presented as frequencies and percentages. To study the relationship between variables, Spearman's correlation coefficient was calculated. Tests were considered statistically significant when $P < 0.05$

Results

VEGF by immunohistochemistry in HCC and Cirrhotic groups

Cases of HCC (20 cases) were tested for expression of VEGF by immunohistochemistry, against cirrhotic cases (6 cases). Immunohistochemical expression of VEGF was found in 26%-50% of malignant hepatocytes (score 2) in 11 cases of HCC, while 5 cirrhotic cases showed the immunohistochemical reaction in 51%-75% of hepatocytes (score 3).

Table 1: Activity, iron load, steatosis and HCV-NS3/NS4 IHC expression in different studied groups

	Group 1 Number (%)	Group 2 Number (%)	Group 3 Number (%)	Group 4 Number (%)	Total Number (%)	P value
Activity						
A0	2 (4.4%)	0 (0%)	0 (0%)	0 (0%)	2 (2.1%)	0.7
A1	32 (71.1%)	7 (28%)	13 (72.2%)	2 (33.3%)	54 (57.4%)	
A2	11 (24.4%)	17 (68%)	5 (27.8%)	4 (66.7%)	37 (39.4%)	
A3	0 (0%)	1 (4%)	0 (0%)	0 (0%)	1 (1.1%)	
Total	45 (100%)	25 (100%)	18 (100%)	6 (100%)	94 (100%)	
Iron						
Positive	8 (17.8%)	3 (12%)	2 (11.1%)	0 (0%)	13 (13.8%)	0.6
Negative	37 (82.2%)	22 (88%)	16 (88.9%)	6 (100%)	81 (86.2%)	
Total	45 (100%)	25 (100%)	18 (100%)	6 (100%)	94 (100%)	
Steatosis						
S0	28 (62.2%)	8 (32%)	10 (55.6%)	2 (33.3%)	48 (51.1%)	0.2
S1	9 (20%)	11 (44%)	6 (33.3%)	2 (33.3%)	28 (29.8%)	
S2	5 (11.1%)	2 (8%)	1 (5.6%)	2 (33.3%)	10 (10.6%)	
S3	3 (6.7%)	4 (16%)	1 (5.6%)	0 (0%)	8 (8.5%)	
Total	45 (100%)	(100%)	18 (100%)	6 (100%)	94 (100%)	
HCV-NS3/NS4						
Negative (0)	13 (28.9%)	9 (36%)	8 (44.4%)	1 (16.7%)	31 (33%)	0.6
Score +1	15 (33.3%)	11 (44%)	8 (44.4%)	2 (33.3%)	37 (39.4%)	
Score +2	14 (31.1%)	4 (16%)	2 (11.1%)	2 (33.3%)	22 (23.4%)	
Score +3	3 (6.7%)	1 (4%)	0 (0%)	0 (0%)	4 (4.3%)	
Total	45 (100%)	25 (100%)	18 (100%)	6 (100%)	94 (100%)	

However, no expression in more than 75% (score 4) of hepatocytes was found in cirrhotic cases, in contrast to 6 cases (30%) of HCC with score 4 expressions (Table 1-2, Figures 1-2).

Table 2: VEGF IHC overexpression in different grades of HCC

VEGF- IHC Score	HCC Grade			Total	P value
	Grade I Number (%)	Grade II Number (%)	Grade III Number (%)		
VEGF (IHC)					
0 (< 5%)	0 (0%)	0 (0%)	0 (0%)	0 (0%)	<0.005
1(6% - 25%)	0 (0%)	0 (0%)	0 (0%)	0 (0%)	
2(26% -50%)	8 (40%)	3 (15%)	0 (0%)	11 (55%)	
3 (51% - 75%)	0 (0%)	2 (10%)	1 (5%)	3 (15%)	
4 (> 75%)	0 (0%)	1 (5%)	5 (25%)	6 (30%)	
Total	8 (100%)	6 (100%)	6 (100%)	20 (100%)	
VEGFR2 (FISH)					
Normal	8 (40%)	4 (20%)	0 (0%)	12 (60%)	<0.001
Overexpression	0 (0%)	2 (10%)	6 (30%)	8 (40%)	
Total	8 (100%)	6 (100%)	6 (100%)	20 (100%)	

Our study showed that the immunoreactivity to VEGF in HCC is correlated with the degree of tumour differentiation. All poorly differentiated HCCs showed VEGF expression in more than 50% of hepatocytes while all well-differentiated tumours showed expression in less than 50% of hepatocytes.

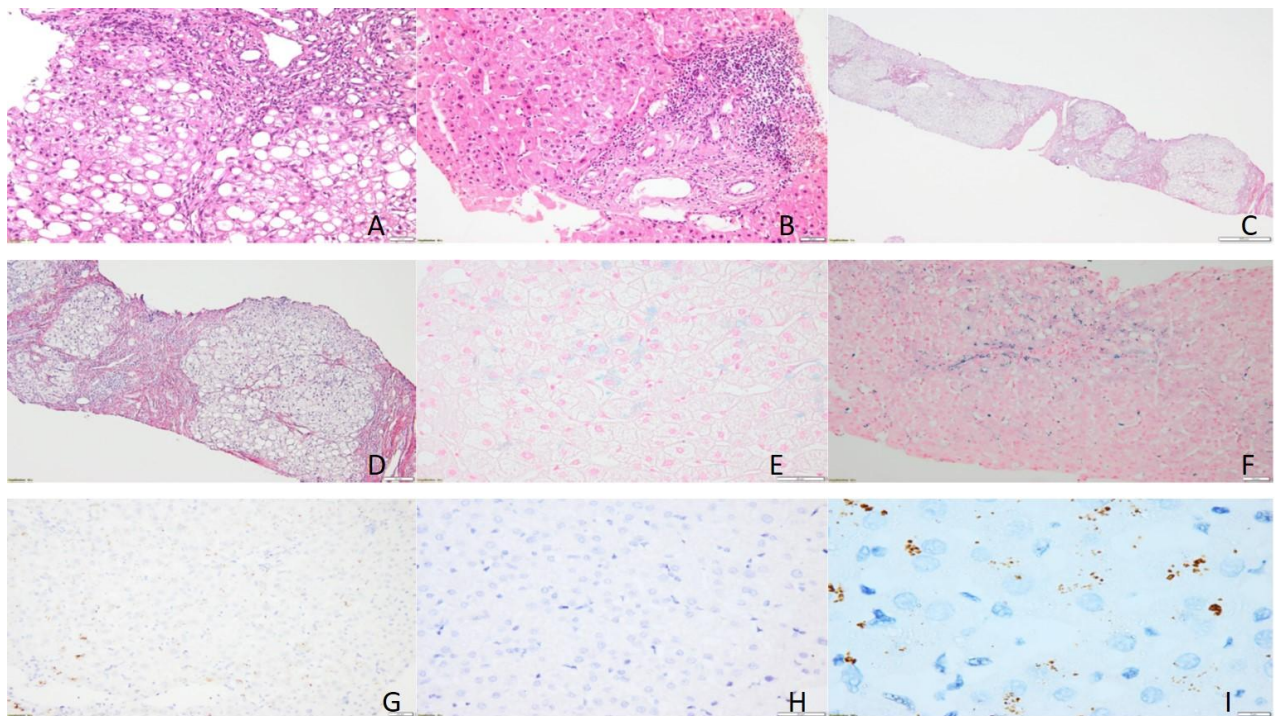


Figure 1: Liver sections: A and B showing marked steatosis and moderate portal inflammation respectively (H&E, 200x and 100x), C and D showing complete liver cirrhosis (Sirius red, 50x and 100x), E and F showing mild and moderate iron deposits (Prussian blue, 200x and 100x), G, H and I showing Negative, score 1 and score 3 viral load (IHC, NS3/NS4, 50x, 100x and 1000x)

VEGFR2 by FISH in different grades of HCC

Overexpression of VEGFR2 correlated with the degree of differentiation in cases of HCC. Well-differentiated HCCs showed normal expression of

VEGFR2, while poorly differentiated tumours showed overexpression of the gene (Table 3; Figure 3). Our study has detected a strong correlation between the degree of immunoreactivity to VEGF and the amplification of VEGFR2 recorded by FISH technique.

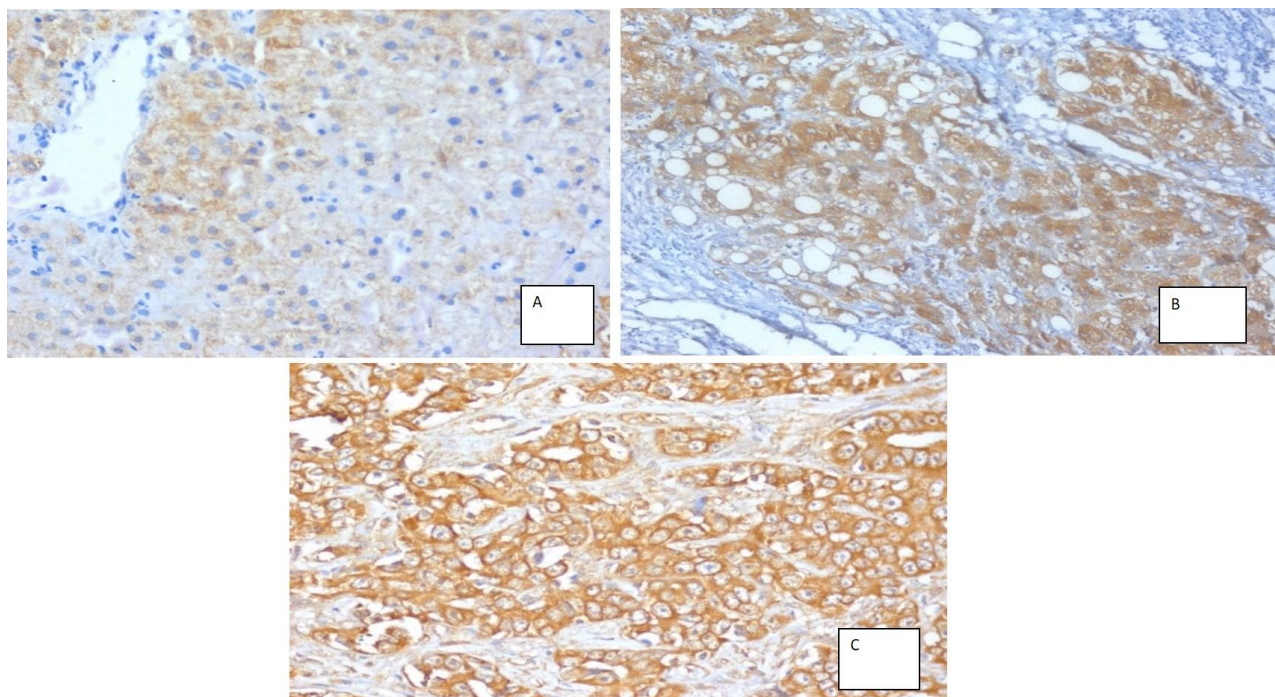


Figure 2: A) Case of CHC showing immunoreactivity to VEGF \pm 10%, IHC 100x. B) Liver biopsy from a cirrhotic case showing immunoreactivity to VEGF in about 60% of hepatocytes (Score 3); IHC 400x. C) Case of HCC showing immunoreactivity to VEGF in >75% of malignant hepatocytes (Score 4); IHC 400x

Discussion

In the current study, a correlation between the stage of fibrosis and the grade of inflammation in cases of CHC was found ($P < 0.01$). These data are supported by the results of a study which included 3068 patients with histologically confirmed CHC obtained from 10 clinical centres in Italy, Switzerland, France, Australia, and the United States. Leandro et al. [14] concluded that hepatic fibrosis, when considered as the dependent variable, was associated with a greater histologic activity, male sex, the presence of steatosis and older age. Also, in a study that included 346 CHC patients, Cua et al. [15] have linked hepatic fibrosis to the grade of portal/peripoortal inflammation and male gender. However, our study did not link male gender to higher grades of fibrosis ($P = 0.3$).

Table 3: VEGFR2 FISH amplification in different cases of HCC

VEGF- IHC Score	VEGFR2- FISH				Total Number (%)	P value
	Normal Number (%)	Amplified Number (%)				
0 (< 5%)	0 (0%)	0 (0%)	0 (0%)	0 (0%)	0 (0%)	
1 (6% - 25%)	0 (0%)	0 (0%)	0 (0%)	0 (0%)	0 (0%)	
2 (26%-50%)	11 (91.7%)	0 (0%)	0 (0%)	11 (55%)	11 (55%)	< 0.001
3 (51%- 75%)	1 (8.3%)	2 (25%)	2 (25%)	3 (15%)	3 (15%)	
4 (> 75%)	0 (0%)	6 (75%)	6 (75%)	6 (30%)	6 (30%)	
Total	12 (100%)	8 (100%)	8 (100%)	20 (100%)	20 (100%)	

Iron overload in our study was present in 13.8% of CHC liver biopsies, and it was not correlated with the stage of fibrosis ($P = 0.6$) or the grade of inflammation ($P = 0.9$). These data are consistent with Lin et al. [16]; where they have identified iron in 12.5% of studied liver biopsies and they have concluded that both serum iron and hepatic iron correlate with serum indices of chronic liver disease but are not related to grade and stage of liver histology. However, Missiha et al. [17] have found that iron overload has been associated with accelerated fibrosis. A study conducted on 58 Egyptian CHC patients has found that hepatic iron density is an independent predictor of advanced fibrosis [18].

In the current study, the immunoreactivity against HCV-NS3/NS4 was found in 67% of CHC cases. However, this finding did not correlate with the stage of inflammation ($P = 0.4$) or the grade of fibrosis ($P = 0.6$) in cases of CHC. In accordance, Liao et al [19], after studying 214 retrospectively collected cases, stated that hepatocyte expression of HCV - NS3 was not correlated with the serum viral load, a severity of the hepatic injury, or treatment response. On the other hand, in a study including 50 cases, Syed and Sadiq [5] have found a positive association

between HCV-NS3 immunopositivity and the histological parameters of grading and staging. This discrepancy can be attributed to the variation in a number of studied cases as well as different HCV genotypes.

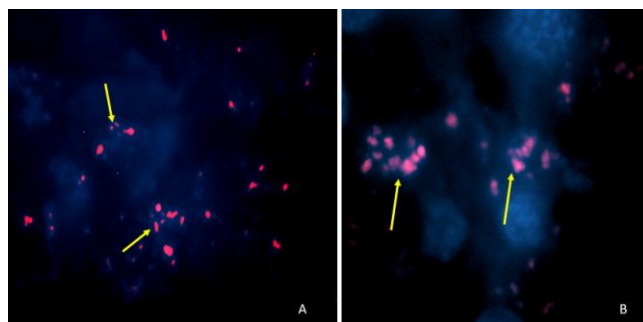


Figure 3: A) Case of HCC, G III, showing amplification of VEGFR2; more than two red signals in the nucleus; FISH X1000 B) from HCC grade II case showed high expression of VEGFR2 more than two red signals in the nucleus (FISH, magnification 1,000x)

Steatosis in our study was present in 48.9% of cases with varying degrees. This percentage is slightly lower than that of another study (54%) including 92 CHC Egyptian patients [20]. It was also consistent with the percentage reported by Wyatt et al. [21] who studied 233 cases, 50.2% of which showed steatosis.

Although steatosis was more prominent in groups with advanced fibrosis, no statistical correlation could be found between the steatosis and the stage of fibrosis in CHC patients ($P = 0.2$) in our study. This is consistent with a retrospective study performed on liver biopsies from 494 CHC patients by Perumalswami and colleagues [22]. They found that steatosis was associated with older age, higher BMI, and higher serum ALT levels but not with the presence of or subsequent progression of fibrosis. Our data are also consistent with Khokhar et al. [23]; in a study including 109 CHC patients, with no significant correlation could be found between steatosis and fibrosis.

However, our data contradict what Leandro et al. [24] have found in large and geographically different group of CHC patients; whereas steatosis was confirmed as significantly and independently associated with fibrosis in CHC. Ahmed et al., [12] also have found that fibrosis was associated with high AST level, age ≥ 40 years, and steatosis. Gordon et al. [24] conducted a study including 74 CHC patients and reported that steatosis grade appears to relate to hepatic fibrosis progression rate in chronic hepatitis C genotype non-3.

We have observed that the grade of inflammation increases with increasing steatosis. This observation, which couldn't be proven statistically ($P = 0.2$), is consistent with data from studying 221 liver

biopsy-proven CHC patients by Adinolfi et al. [3]; steatosis is an important cofactor in increasing liver necroinflammatory activity. Morosan et al. [25] have studied liver biopsies from 1206 patients (including 1021 CHC patients) and have concluded that steatotic lesions associated with liver pathology increase the severity of the disease, regardless of the type of virus involved. Leandro et al. [14] have also found that steatosis was associated with higher BMI, older age and histologic activity.

Most CHC cases with detectable iron, showed positive immunoreactivity to HCV-NS3/NS4 (11 out of 13 cases), but no correlation could be found between the cellular viral load and the cellular iron content ($P = 0.1$). Also, no significant correlation could be found between the cellular viral load and the degree of steatosis in CHC patients of this study ($P = 0.7$). Unfortunately, we did not record studies correlating the hepatic viral load (as detected by immunohistochemistry) with steatosis or hepatic iron content.

We found that the expression of VEGF by IHC is more in HCC cases when compared to cirrhotic cases ($P < 0.001$). This is compatible with a study including 90 Egyptian patients with CHC and HCC which has demonstrated that the highest value of VEGF expression by IHC was mostly encountered among HCC patients [26]. Another study that involved 16 patients with HCC, has reported that VEGF protein expression was higher in HCC as compared to the surrounding liver tissue [27]. Iavarone and colleagues [28] have measured the serum levels of VEGF in patients with CHC (with or without cirrhosis) and HCC. They have reported that serum levels of VEGF protein were significantly higher in HCC patients than in cirrhotic patients. Our study has also found a strong correlation between the expression of VEGF and the degree of HCC differentiation ($P < 0.001$). This is consistent with Mi et al. [29]. They have found a positive relationship between the expression of VEGF in HCC tissue and the pathological differentiation and invasion of the tumour. Another study performed on 54 Egyptian HCC patients has found a statistically significant correlation between expression of VEGF and histopathological grading of HCC [30].

We conclude that the grade of inflammation is a factor affecting the stage of fibrosis in CHC. The degree of liver damage is not related to cellular viral load, iron load or copper load. Steatosis is associated with higher grades of inflammation and stages of fibrosis. VEGF by immunohistochemistry is correlated with the overexpression of VEGFR2 by FISH technique.

Acknowledgment

Internal project 95T of TBRI, Principal investigators Professor Dr Maha Akl and Ahmed EL

Ray, Pathology Department of Beaujon Hospital, Clichy, France.

References

1. Yousra A Mohamoud, Ghina R Mumtaz, Suzanne Riome, DeWolfe Miller and Laith J Abu-Raddad : The epidemiology of hepatitis C virus in Egypt: a systematic review and data synthesis. *BMC Infectious Diseases*. 2013; 13:288. <http://dx.doi.org/10.1186/1471-2334-13-288> PMID:23799878 PMCid:PMC3702438
2. Kandeel A, Genedy M, El-Refai S, Funk AL, Fontanet A, Talaat M. The prevalence of HCV infection in Egypt 2015: Implications for future policy on prevention and treatment. *Liver International*. 2016 Jun 1. <http://dx.doi.org/10.1111/liv.13186> PMID:27275625
3. Adinolfi LE, Restivo L, Marrone A. The predictive Value of Steatosis in Hepatitis C Virus Infection. *Expert Rev Gastroenterol Hepatol*. 2013; 7:205-213. <http://dx.doi.org/10.1586/eqh.13.7> PMID:23445230
4. Yoon EJ, Hu KQ. Hepatitis C Virus Infection and Hepatic Steatosis. *Int J Med Sci*. 2006; 3:53-56. <http://dx.doi.org/10.7150/ijms.3.53> PMID:16614743 PMCid:PMC1415843
5. Syed SI, Sadiq S. Immunohistochemical detection of hepatitis C virus (HCV) in liver biopsies of hepatitis C patients. *J Pak Med Assoc*. 2011; 61:1198–1201. PMID:22355966
6. Isom HC, McDevitt EI, Moon MS. Elevated Hepatic Iron: A Confounding Factor in Chronic Hepatitis C. *Biochim Biophys Acta*. 2009; 1790:650-662. <http://dx.doi.org/10.1016/j.bbagen.2009.04.009> PMID:19393721
7. Sikorska K, Romanowski T, Bielawski KP. Pathogenesis and Clinical Consequences of Iron Overload in Chronic Hepatitis C - Impact of Host and Viral Factors Related to Iron Metabolism. *Biotechnol*. 2011; 92:54-65. <http://dx.doi.org/10.5114/bta.2011.46517>
8. Fujita N, Sugimoto R, Takeo M, Urawa N, Mifuji R, Tanaka H, Kobayashi Y, Iwasa M, Watanabe S, Adachi Y, Kaito M. Hepcidin Expression in the Liver: Relatively Low Level in Patients with Chronic Hepatitis C. *Mol Med*. 2007; 13:97-104. <http://dx.doi.org/10.2119/2006-00057.Fujita> PMID:17515961 PMCid:PMC1869620
9. Finn RS, Zhu AX. Targeting Angiogenesis in Hepatocellular Carcinoma: Focus on VEGF and Bevacizumab. *Exp Rev Anticancer Ther*. 2009; 9:503-509. <http://dx.doi.org/10.1586/era.09.6> PMID:19374603
10. Bedossa P, Poynard T. An Algorithm for the Grading of Activity in Chronic Hepatitis C. The METAVIR Cooperative Study Group. *Hepatology*. 1996; 24:289– 293. <http://dx.doi.org/10.1002/hep.510240201> PMID:8690394
11. Bedossa P, Poitou C, Veyrie N, Bouillot JL, Basdevant A, Paradis V, Tordjman J, Clement K. Histopathological Algorithm and Scoring System for Evaluation of Liver Lesions in Morbidly Obese Patients. *Hepatology*. 2012; 56:1751-1759. <http://dx.doi.org/10.1002/hep.25889> PMID:22707395
12. Perls M. Nachweis von Eisenoxyd in gewissen Pigmentation. *Virchows Archiv für Pathologische Anatomie und Physiologie und für Klinische Medizin*. 1867; 39:42. <http://dx.doi.org/10.1007/BF01878983>
13. Rullier A, Trimoulet P, Urbaniak R, Winnock M, Zauli D, Ballardini G, Rosenbaum J, Balabaud C, Bioulac-Sage P, Le Bail B. Immunohistochemical detection of hcv in cirrhosis, dysplastic nodules, and hepatocellular carcinomas with parallel-tissue quantitative RT-PCR. *Mod Pathol*. 2001; 14(5):496-505. <http://dx.doi.org/10.1038/modpathol.3880338> PMID:11353061
14. Leandro G, Mangia A, Hui J, Fabris P, Rubbia-Brandt L, Colloredo G, Adinolfi L, Asselah T, Jonsson J, Smedile A, Terrault

- N, Paziienza V, Giordani MT, Giostra E, Sonzogni A, Ruggiero G, Marcellin P, Powell E, George J, Negro F. Relationship Between Steatosis, Inflammation, and Fibrosis in Chronic Hepatitis C: A Meta-Analysis of Individual Patient Data. *J Gastroenterol.* 2006; 130:1636-1642. <http://dx.doi.org/10.1053/j.gastro.2006.03.014> PMID:16697727
15. Cua IH, Hui JM, Kench JG, George J. Genotype-Specific Interactions of Insulin Resistance, Steatosis, and Fibrosis in Chronic Hepatitis C. *Hepatology.* 2008; 48:723-731. <http://dx.doi.org/10.1002/hep.22392> PMID:18688878
16. Lin TJ, Liao LY, Lin SY, Lin CL, Chang TA. Influence of Iron on the Severity of Hepatic Fibrosis in Patients with CHC. *W J Gastroenterol.* 2006; 12:4897-4901.
17. Missiha SB, Ostrowski M, Heathcote EJ. Disease Progression in CHC: Modifiable and Nonmodifiable Factors. *Gastroenterol.* 2008; 134:1699-1714. <http://dx.doi.org/10.1053/j.gastro.2008.02.069> PMID:18471548
18. Galal GM, Muhammad EMS, Salah Eldeen FEZ, Amin NF, Abdel-Aal AM. Serum Prohepcidin, Iron and Hepatic Iron Status in Chronic Hepatitis C in Egyptian Patients. *J Arab Soc Med Res.* 2011; 6:91-101.
19. Liao W, Tung S, Shen C, Lee K, Wu C. Tissue expression of the Hepatitis C Virus NS3 Protein Does Not Correlate with Histological or Clinical Features in Patients with Chronic Hepatitis C. *Chang Gung Medical.* 2011; 34:260-267.
20. Ahmed AM, Hassan MS, Abd-Elsayed A, Hassan H, Hasanain AF, Helmy A. Insulin Resistance, Steatosis, and Fibrosis in Egyptian Patients with Chronic Hepatitis C Virus Infection. *Sa J Gastroenterol.* 2011; 17:245-251. <http://dx.doi.org/10.4103/1319-3767.82578> PMID:21727730 PMCid:PMC3133981
21. Wyatt J, Baker H, Prasad P, Gong YY, Milson C. Steatosis and Fibrosis in Patients with CHC. *J Clin Pathol.* 2004; 57:402-406. <http://dx.doi.org/10.1136/jcp.2003.009357> PMID:15047745 PMCid:PMC1770262
22. Perumalswami P, Kleiner DE, Lutchman G, Heller T, Borg B, Park Y, Liang TJ, Hoofnagle JH, GhanyMG. Steatosis and Progression of Fibrosis in Untreated Patients with Chronic Hepatitis C Infection. *Hepatology.* 2006; 43:780-787. <http://dx.doi.org/10.1002/hep.21078> PMID:16557550
23. Khokhar N, Mushtaq M, Mukhtar AS, Ilahi F. Steatosis and Hepatitis C Virus Infection. *J Pak Med Assoc.* 2004; 54:110-112. PMID:15129866
24. Gordon A, McLean CA, Pedersen JS, Bailey MJ, Roberts SK. Hepatic Steatosis in Chronic Hepatitis B and C: Predictors, Distribution and Effect on Fibrosis. *J Hepatol.* 2001; 43:38-44. <http://dx.doi.org/10.1016/j.jhep.2005.01.031> PMID:15876468
25. Morosan E, Mihailovici MS, Guisca SE, Cojocaru E, Avadanei ER, Caruntu ID, Teleman S. Hepatic Steatosis Background in Chronic Hepatitis B and C – Significance of Similarities and Differences. *Rom J Morphol Embryol.* 2014; 55:1041-1047. PMID:25607383
26. Hammam O, Mahmoud O, Zahran M, Sayyed A, Hosny K, Farghaly A, Salama R. Tissue Expression of TNF α and VEGF in Chronic Liver Disease and Hepatocellular Carcinoma. *Med J Cairo Univ.* 2013; 81:191-199.
27. Basa N, Cornianu M, Lazar E, Dema A, Taban S, Lazar D, Lazureanu C, Faur A, Tudor A, Mos L, Pribac GC. Immunohistochemical Expression of VEGF in Hepatocellular Carcinoma and Surrounding Liver Tissue. *Seria Științele Vieții.* 2011; 21:479-486.
28. Iavarone M, Lampertico P, Iannuzzi F, Manenti E, Donato MF, Arosio E, Bertolini F, Primignani M, Sangiovanni A, Colombo M. Increased Expression of VEGF in small Hepatocellular Carcinoma. *J Vir Hep.* 2007; 14:133-139. <http://dx.doi.org/10.1111/j.1365-2893.2006.00782.x> PMID:17244253
29. Mi D, Yi J, Liu E, Li X. Relationship between PTEN and VEGF Expression and Clinicopathological Characteristics in HCC. *J Huazhong Univ Sci Technolog Med Sci.* 2006; 26:682-682. <http://dx.doi.org/10.1007/s11596-006-0614-4> PMID:17357488
30. Shamloula MM, El-Torky WA, Saied EM, El-Fert AA. Immunohistochemical Study of Some Biological Markers Which Can Be Targeted by New Anticancer Therapies in Hepatocellular Carcinoma. *Tanta Med Sci J.* 2012; 7:19-29.