

Comparison of the Anchorage Value of the First Molars Supported with Implant and First Molars Supported with Second Molar during En Masse Retraction

M. Kaladhar Naik¹, Garadappagari Dharmadeep², Yellampalli Muralidhar Reddy¹, Sreekanth Cherukur², Kranthi Praveen Raj², Vishnuvardhan Reddy²

¹Department of Orthodontics and Dentofacial Orthopedics, Government Dental College and Hospital, Rajiv Gandhi Institute of Medical Sciences, Kadapa, ²Department of Orthodontics and Dentofacial Orthopaedics, G. Pulla Reddy Dental College and Hospital, Kurnool, Andhra Pradesh, India

Received : 14-06-19.
Accepted : 17-09-19.
Published : 05-02-20.

ABSTRACT

Aims and Objectives: The aim of this study was to determine the efficacy of mini-implants as adjuncts for intraoral anchorage units for en masse retraction of maxillary anterior teeth in bimaxillary dentoalveolar protrusion cases. **Materials and Methods:** The study sample consisted of 15 patients (10 females and 5 males). The samples were compared for anchorage loss with the implant-supported molar and conventional molar contralaterally in both the maxilla and mandible after six months of retraction period. The mini-implants used were 1.5 mm in diameter and 8 mm in length and were inserted in the first and third quadrant between the roots of second premolar and first molar under local anesthesia at an angle of 45°. For en masse retraction, active tiebacks with ligating (100 g) were used bilaterally extending from molar hooks to J-hook on a 0.019" × 0.025" stainless steel arch wire. Lateral cephalograms were taken before and after retraction for assessing the loss of anchorage in maxillary and mandibular first molars. **Results:** Anchorage loss of 1.46 mm in the maxilla and 1.36 mm in mandible was found with conventional molar anchorage, whereas no statistically significant anchorage loss was found in the implant-supported molar side. **Conclusion:** Implant-supported molar side showed better anchorage compared with the conventional molar side. Hence, implant-supported molar can be used as an absolute anchorage unit in the en masse retraction of anterior teeth.

KEYWORDS: Anchorage, mini-implants, molar, retraction, temporary anchorage devices

INTRODUCTION

Anchorage control is considered as one of the major factors in determining the success of orthodontic treatment. After the introduction of temporary anchorage devices (TADs), application of skeletal anchorage for orthodontic treatment has increased as orthodontists have a choice to choose from many new systems to attain absolute anchorage.^[1,2]

Recently, mini-implants, as a source of rigid anchorage unit, are being used for space closure with en masse retraction, and studies have shown superior treatment outcome. A variety of small

titanium screws (mini-implants), palatal implants, and mini-plates with screws have been used as abutments for tooth replacements, and this type of anchorage is very effectual in treating patients with congenitally missing teeth, hypodontia, or periodontal disease. Mini-implants made of titanium can be used in

Address for correspondence: Dr. M. Kaladhar Naik, Department of Orthodontics and Dentofacial Orthopedics, Government Dental College and Hospital, Rajiv Gandhi Institute of Medical Sciences, Kadapa, Andhra Pradesh, India. E-mail: marvelpub4@gmail.com

This is an open access journal, and articles are distributed under the terms of the Creative Commons Attribution-NonCommercial-ShareAlike 4.0 License, which allows others to remix, tweak, and build upon the work non-commercially, as long as appropriate credit is given and the new creations are licensed under the identical terms.

For reprints contact: reprints@medknow.com

How to cite this article: Naik MK, Dharmadeep G, Muralidhar Reddy Y, Cherukuri S, Praveen Raj K, Reddy V. Comparison of the anchorage value of the first molars supported with implant and first molars supported with second molar during en masse retraction. J Int Soc Prevent Communit Dent 2020;10:9-15.

Access this article online	
Quick Response Code: 	Website: www.jispcd.org
	DOI: 10.4103/jispcd.JISPCD_262_19

combination with different orthodontic systems such as edgewise, self-ligation, and expansion devices etc.^[3-7]

Linkow *et al.* (1970)^[4] were among the first to recommend the usage of blade implant as anchorage with class-II elastics.^[5] Kanomi *et al.* (1997)^[5] reported using the mini-screw for anchorage.^[6] Umemori *et al.* (1999)^[6] reported using titanium mini-plates for the correction of open bite.^[7]

The most commonly used system is screw-type mini-implant, and mini-implant anchorage has been shown to be efficient for adjunctive tooth movement, en masse retraction, molar mesialization or distalization, molar extrusion or intrusion, correction of occlusal planes, and for vertical control.^[8-10]

The advantages of mini-implants are smaller diameter, available in different lengths, can be inserted in any desired location, including interradicular space, ability to withstand typical orthodontic forces for the entire length of treatment, not needing osseointegration, not like restorative implants, and ease of removal. Hence, mini-implants have gained popularity than traditional means of supporting anchorage.^[11-20]

We conducted our study to compare the anchorage loss and thereby the anchorage value of the first molars, supported by an implant, and the first molars, supported by the second molar, during en masse retraction.

MATERIALS AND METHODS

The prospective study was performed on subjects chosen from the patients who reported for orthodontic treatment. A total of 15 patients were selected with a mean age of 18 years (age ranging from 13 to 23 years), of which 10 were females and 5 were males. The study was carried out after obtaining institutional ethics committee clearance (GPRDCH/IEC.12/2013) and informed consent from all the subjects. Sample size was calculated using G*Power software (Institute for Experimental Psychology in Dusseldorf, Germany). Total sample size obtained was 15. We included 15 consecutive patients, of which 10 were females. The study was carried out from January 2013 to December 2013.

INCLUSION CRITERIA

1. Age group between 13 and 23 years
2. Patients having class-I molar bimaxillary protrusion
3. Cases with good oral hygiene and minimal crowding in lower anterior teeth
4. Subjects without any systemic illness

PROCEDURE

Patients were informed about the study and after the formal consent, pretreatment records were obtained.

Patients were sent for extraction of all the first premolars following which the first and second molars were banded, and all the remaining teeth were bonded with 0.022" MBT system (Ormco, Brea, California) metal brackets.

After the initial alignment was achieved, the arch wires were upgraded in all the subjects to 0.019" × 0.025" SS. After alignment, pre-retraction records were obtained at the stage of 0.019" × 0.025" SS. The records obtained included study models and photographs.

The implant used in this study was a mini-screw (3M Unitek, Irwindale, California, MN 55144-1000USA) having a diameter of 1.5mm and a length of 8mm, which could withstand as much as 450g of force, whereas most orthodontic force applications need less than 300g of force. The implant site was marked using a 0.019" × 0.025" stainless steel stent [Figure 1], and its position was confirmed with the help of an intraoral periapical radiograph [Figure 2]. Local anesthetic agent was infiltrated at the site of implant placement. The

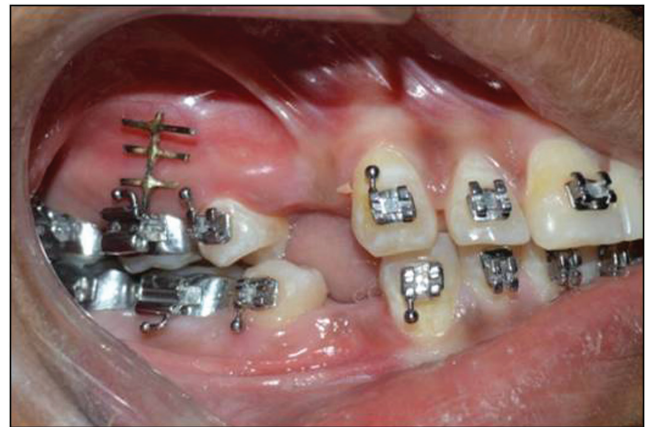

Figure 1: Surgical stent in maxilla

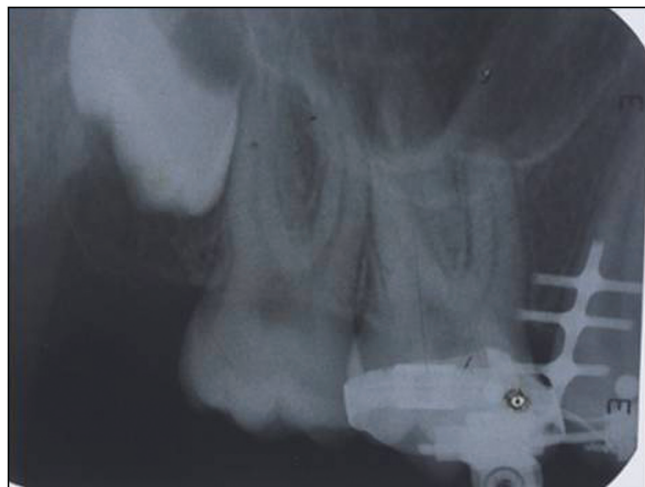


Figure 2: Intra oral peri apical of maxillary first molar

mini-implant was removed from the sterile package and mounted on the manual screwdriver, which was used to insert the implant. The implants were positioned in the first quadrant at a maximum thickness of infra-zygomatic crest between the roots of the second premolar and first molar, in third quadrant, the implants were positioned between the roots of the second premolar and first molar. The screw was self-driven by a manual screwdriver (3M Unitek, 504-301) at an angle of 45° to the cortical bone until the head of the screw reached its ideal position.

To differentiate between the right and left molars on the lateral cephalograms, a 0.019" × 0.025" stainless steel wire was made into an "L" shape with 2 cm of vertical length and 1 cm of horizontal length and inserted into the distal side of the first molar auxiliary tube on the first quadrant, and 1 cm of vertical length and 1 cm of horizontal length were inserted into the mesial side of the first molar auxiliary tube on the second quadrant. In the third quadrant, 1 cm of vertical length and 1 cm of horizontal length were inserted into the distal side of the first molar auxiliary tube, and in the fourth quadrant, 2 cm of vertical length and 1 cm of horizontal length were inserted into the mesial side of the first molar auxiliary tube [Figure 3]. After the placement of vertical lengths, lateral cephalograms were taken. The first, second, third, and fourth quadrant molars were identified by tracing the pre-retraction and six months post-retraction lateral cephalograms, which were taken with the "L"-shaped vertical lengths in place.

The implant was connected as an adjunct to the first molar with a straight length of 0.019" × 0.025" stainless steel wire bent in Z shape, which was connected from the implant head to the molar auxiliary tube to increase the anchorage value of molar in the en masse retraction of anteriors [Figure 4]. After reinforcement of molar with the help of implant, orthodontic forces were

applied with active tiebacks using ligating with 0.01" SS ligature wire from the first molar hook to J-hook, applying a force of 100 g on both sides. The duration of the study was 6 months. After 6 months, post-retraction lateral cephalograms were taken with the "L"-shaped vertical lengths in place.

SUPERIMPOSITION OF CEPHALOGRAMS

The anchorage loss of molars was determined by superimposing the pre- and post-cephalometric radiographs. The mesial movement of molars was measured by using a stable landmark, pterygoid vertical in the maxilla and sella vertical in the mandible. With the help of a brass wire, the distance from the pterygoid vertical and sella vertical to the vertical lengths of the 0.019" × 0.025" SS wire on first molars was measured and calculated with digital vernier calipers on pre- and post-retraction lateral cephalograms to assess and compare the anchorage loss on both sides, thereby determining the anchorage value of the anchorage units.

MAXILLA

The pre- and the posttreatment cephalograms were superimposed using Ricket's20 method. The tracings were superimposed along the palatal plane making the anterior nasal spine stable. The distance from the pterygoid vertical to the vertical lengths of the first molars on both the sides was measured to assess the anchorage loss, which thereby determined the anchorage value of the anchorage units.

MANDIBLE

The pre- and the posttreatment cephalograms were superimposed using Bjork's20 method. The tracings were superimposed by registering on the best fit of anterosuperior border of the chin and corpus axis. The distance from the sella vertical to the vertical lengths of

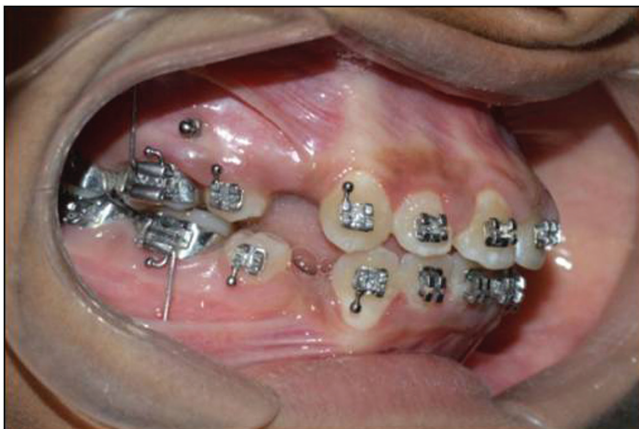

Figure 3: Mini-implants in position

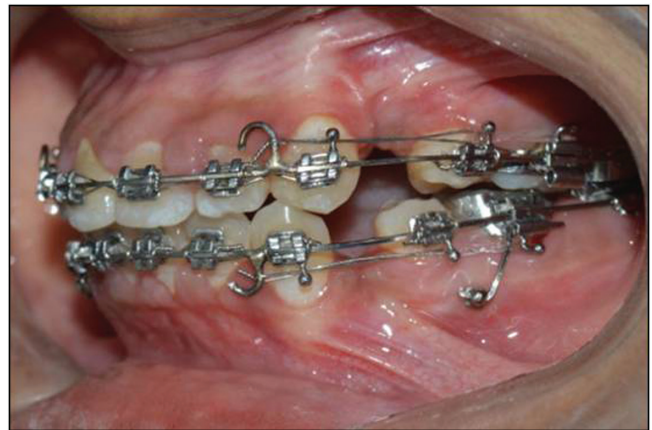


Figure 4: 0.019" × 0.025" Stainless steel engaged to the mini-implant and active tiebacks

the first molars on both sides was measured to assess the anchorage loss, which thereby determined the anchorage value of the anchorage units.

RESULTS

The mean age of the patients was 18 years. There was a loss of follow-up in four cases, and hence the final sample was 11. The distance from the reference line was measured, recorded, and compared with both the implant-supported molar side and conventional molar side. Anchorage loss values are given in Tables 1 and 2. The super impositions were carried out on the pre- and post-lateral cephalograms. The mean distance of first molar from pterygoid vertical in maxilla with implant-supported side was 22.64mm

and with the conventional molar side was 23.91mm. The mean distance of the first molar from sella vertical in mandible with implant-supported side was 35.91mm and with conventional molar side was 36.54mm [Table 3]. The data obtained were subjected to statistical analysis. The mean and the standard deviation (SD) were tabulated and paired *t*-test was used to determine anchorage loss between implant-supported molar and conventional molar in both the maxilla and mandible during en masse retraction. A *P* value of less than 0.05 was considered statistically significant.

The analysis showed the pre-retraction mean distance of the first molar from the pterygoid vertical on implant-supported first molar side was 22.64mm with

Table 1: Anchorage loss in maxilla

S. no.	Name	Age/sex	Distance from vertical leg to pterygoid vertical (mm)				Anchor loss in (mm)		P value
			Implant side		Non-implant side		Implant side	Non-implant side	
			Pre	Post	Pre	Post			
1.	Pt 1	18/F	24	24.2	20	22	0.2	2	
2.	Pt 2	21/F	27	27	24	26	0	2	
3.	Pt 3	19/F	20	20.4	22	24	0.4	2	
4.	Pt 4	22/M	25	25	27	28	0	1	
5.	Pt 5	21/M	30	30	31	32	0	1	
6.	Pt 6	19/M	21	21.3	23	25	0.3	2	
7.	Pt 7	18/F	17	17	21	22	0	2	
8.	Pt 8	22/F	22	22.2	17	18	0.2	1	
9.	Pt 9	20/M	23	23	17	18	0	1	
10.	Pt 10	18/F	23	23.4	24	25	0.4	1	
11.	Pt 11	21/F	17	17	22	23	0	1	
Pre values Mean							22.64 (3.9)	22.45 (4.0)	0.958
Post values Mean							22.91 (4.2)	23.91 (4.1)	0.465

Table 2: Anchorage loss in mandible

S. no.	Name	Age/sex	Distance from vertical leg to sella vertical (mm)				Anchor loss in (mm)		P value
			Implant side		Non-implant side		Implant side	Non-implant side	
			Pre	Post	Pre	Post			
1.	Pt 1	18/F	40	40.3	34	36	0.3	2	
2.	Pt 2	21/F	37	37	27	29	0	2	
3.	Pt 3	19/F	32	32.2	27	29	0.2	2	
4.	Pt 4	22/M	41	41	49	50	0	1	
5.	Pt 5	21/M	45	45.4	47	49	0.4	2	
6.	Pt 6	19/M	38	38	40	41	0	1	
7.	Pt 7	18/F	26	26.1	30	31	0.1	1	
8.	Pt 8	22/F	35	35	28	30	0	2	
9.	Pt 9	20/M	38	38.3	33	34	0.3	1	
10.	Pt 10	18/F	36	36	41	42	0	1	
11.	Pt 11	21/F	27	27.2	31	32	0.2	1	
Pre values Mean							35.91 (5.7)	22.45 (4.0)	0.958
Post values Mean							35.18 (7.9)	36.54 (4.1)	0.805

SD = 3.9 mm, and on conventional molar side, it was 22.45 mm with SD = 4.0 mm [Table 3]. Post-retraction mean distance of first molar from the pterygoid vertical on implant-supported first molar side was 22.91 mm with SD = 4.2 mm, and on conventional molar side, it was 23.91 mm with SD = 4.1 mm [Table 3].

The pre-retraction mean distance of the first molar from the sella vertical on implant-supported first molar side was 35.91 mm with SD = 5.7 mm, and on the conventional molar side, it was 35.18 mm with SD = 7.9 mm [Table 2]. Post-retraction mean distance of the first molar from the sella vertical on implant-supported first molar side was 36.18 mm with SD = 5.4 mm, and on the conventional molar side, it was 36.54 mm with SD = 7.7 mm [Table 4].

In the maxilla, the anchorage loss in implant-supported first molar side was 0.27 mm with the mean distance of 22.64 mm pre-retraction and 22.91 mm post-retraction with SD value of 3.9 mm pre-retraction and 4.2 mm post-retraction with no significant anchorage loss with P value of 0.08 [Table 3]. In conventional molar side, the anchorage loss was 1.46 mm with the mean distance of 22.45 mm pre-retraction and 23.91 mm post-retraction with SD value of 4.1 mm pre-retraction and 4.1 mm post-retraction, showing anchorage loss with a highly significant P value of 0.001 [Table 5].

In the mandible, the anchorage loss in implant-supported first molar side was 0.27 mm with the mean

distance of 35.91 mm pre-retraction and 36.18 mm post-retraction with SD value of 5.7 mm pre-retraction and 5.4 mm post-retraction, and no significant anchorage loss with P value at 0.08 was noticed [Table 5]. In conventional molar side, the anchorage loss was 1.36 mm with the mean distance of 35.18 mm pre-retraction and 36.54 mm post-retraction with SD value of 7.9 mm pre-retraction and 7.7 mm post-retraction, showing anchorage loss with a highly significant P value of 0.001 [Table 6].

DISCUSSION

Recently, orthodontists have been using mini-implants for better anchorage in the clinical management of space closure. The stability of mini-implants depends on several factors such as length, diameter, shape, location, and insertion angulation.

Deguchi *et al.*^[10] reported that the safest location for placing mini-screws was mesial or distal to the first molar, whereas Poggio *et al.*^[11] found that in the maxilla, the maximum amount of mesiodistal bone was seen on the palatal side between the roots of the second premolar and first molar and the least amount of bone was in the maxillary tuberosity. However, in the mandible, the maximum amount of mesiodistal dimension was between the roots of first and second premolar and the least amount of bone was seen between roots of the first premolar and the canine.

Table 3: Comparison of distances of upper first molars supported with implant and upper first molars supported with second molar during en masse retraction using unpaired t -test

	No. of samples	Pre values Mean (SD)	Post values Mean (SD)
Implant side	11	22.64 (3.9)	22.91 (4.2)
Non-implant side	11	22.45 (4.0)	23.91 (4.1)
t -value	-	0.053	0.745
P value	-	0.958	0.465

* $P < 0.05$, significant, ** $P < 0.001$, highly significant

Table 4: Comparison of distances of lower first molars supported with implant and lower first molars supported with second molar during en masse retraction using unpaired t -test

	No. of samples	Pre values Mean (SD)	Post values Mean (SD)
Implant side	11	35.91 (5.7)	36.18 (5.4)
Non-implant side	11	35.18 (7.9)	36.54 (7.7)
t value	-	0.247	0.250
P value	-	0.807	0.805

* $P < 0.05$, significant, ** $P < 0.001$, highly significant

Table 5: Comparison of pre- and post-anchorage loss of upper and lower first molars supported with implants using paired t -test

Implant side	No. of samples	Upper molars Mean (SD) in mm	Lower molars Mean (SD) in mm
Pre	11	22.64 (3.9)	35.91 (5.7)
Post	11	22.91 (4.2)	36.18 (5.4)
Mean difference	-	0.27	0.27
t value	-	1.936	1.936
P value	-	0.08	0.08

* $P < 0.05$, significant, ** $P < 0.001$, highly significant

Table 6: Comparison of pre- and post-anchorage loss of upper and lower first molars supported with second molar using paired t -test

Non-implant side	No. of samples	Upper molars Mean (SD) in mm	Lower molars Mean (SD) in mm
Pre	11	22.45 (4.1)	35.18 (7.9)
Post	11	23.91 (4.1)	36.54 (7.7)
Mean difference	-	1.46	1.36
t value	-	8.964	9.238
P value	-	<0.001**	<0.001**

* $P < 0.05$, significant, ** $P < 0.001$, highly significant

Seong-Hun *et al.*^[12] carried out a study to find out the initial point of placement of mini-implants by means of computed tomography and found that the area near to the mucogingival line (approximately 2–4 mm) from the cemento-enamel junction to be ideal. The site for the placement of implant as an adjunct to the molar for the en masse retraction of anterior teeth in our study was between the roots of second premolar and first molar at the mucogingival line at 8 mm from the cemento-enamel junction in both maxilla and mandible.

The length and diameter of the implant has key role in the stability of implant, and the ideal length of the mini-implant was 6–8 mm with a diameter ranging from 1.2 to 1.5 mm. In previous studies, the force was directly applied to the implants as a source of anchorage, whereas in our study, the implant was used as an adjunct to molar anchorage to reinforce the anchorage value of molar.

Seong-Hun *et al.*^[12] reported that an angulation less than 45° to the long axis of the tooth gave more stability during orthodontic loading, whereas Monnerat *et al.*^[19] showed that 10°–20° inclination to the bone provides best stability under loading conditions. In our study, the mini-implants were inserted at an angulation of 45° to the long axis of the tooth to reinforce the anchorage value of molar during the en masse retraction of anteriors. Garfinkle *et al.*^[13] found that the success rate with mini-implant treatment and positional stability were approximately 70.73%.

The mini-implants in our study were loaded immediately and they were found to be stable throughout the study. Bialveolar dental protrusion patients require maximum anchorage for retracting anterior teeth sagittally. To enhance anchorage, several studies have been conducted and they led to the development of mini-implants.

Wook *et al.*,^[14] Madhur *et al.*,^[15] and Basha *et al.*^[16] compared the anchorage value of mini-implant with the conventional molar anchorage during the en masse retraction of anteriors, and they found that mini-implant showed significantly higher anchorage value than conventional method of molar anchorage. We also found similar results.

The treatment with extraoral appliances such as headgear as anchorage unit requires highly compliant patients. The major disadvantages being unaesthetic and the need of wearing time of 12 h per day and also the usage of intermaxillary elastics. Hence, mini-implants were introduced recently as a source of anchorage in the en masse retraction procedures. Isao *et al.*^[17] and Jonathan *et al.*^[18] found that mini-implants provided better anchorage value than extraoral devices, especially in aesthetic-conscious adult patients. The results of our study showed that

there was no statistically significant anchorage loss in the mini-implant-supported molars ($P < 0.08$), whereas in the conventional molar anchorage side, there was anchorage loss (1.36 mm in mandible and 1.46 in the maxilla) with a P value less than 0.001, which was highly significant. We found that mini-implants can be used as a stable source of anchorage reinforcement to the molars in the en masse retraction of anteriors in patients who require maximum anchorage, and they also provide minimal discomfort to the patients.

Wook *et al.*^[14] reported that mini-implants provided a steady source of anchorage in the en masse retraction of anteriors, whereas even with the two-step retraction method to preserve the anchorage there was anchorage loss seen in the molars. Whereas Thiruvengkatachari *et al.*^[20] found that there was anchorage loss in the conventional molar side, which was not seen with mini-implants.

We found that this new method of reinforcing the anchorage value of the molars with the mini-implants is better than the en masse retraction of anterior teeth. We made comparison by tracing the pre- and posttreatment lateral cephalometric radiographs with the “L”-shaped vertical lengths in the molar auxiliary tubes to distinguish between the left and the right quadrant molars, both in maxilla and mandible. Our method of comparing the results within the same patient has a superior significance over the other studies, in which different methods of retraction were compared in two separate groups of patients, as the results obtained were evident clinically as well as statistically significant within the same subject having same bone density in the upper and lower arches contralaterally.

Thus, by the introduction of this new method of reinforcing, the anchorage value of molar, the scope of further improving the anchorage value of the posterior segment in the en masse retraction of anterior teeth in bimaxillary protrusion cases who require high anchorage, has increased significantly.

As the sample size in this study was less in number, further studies are required with an increase in the sample size to warrant the results obtained in this study so that the implant-supported molars have a high anchorage value compared with the conventional molar anchorage, and mini-implants can be used as an effective source of reinforcement to the molars during en masse retraction of anteriors in high anchorage cases

CONCLUSION

We found that implant-supported molars were an efficient source of intraoral anchorage and remained stable throughout six months of retraction phase.

The advantages of the treatment approach were the elimination of compliance-dependent intraoral and extraoral anchorage aids, favorable aesthetics, immediate force application, and relatively predictable outcome. The mini-implant insertion and retrieval procedures were quick, simple, and painless. There was no inflammation, bleeding, or pain associated with tissues adjacent to the implant.

ACKNOWLEDGEMENTS

None.

FINANCIAL SUPPORT AND SPONSORSHIP

Nil.

CONFLICTS OF INTEREST

There are no conflicts of interest.

AUTHOR CONTRIBUTIONS

M. Kaladhar Naik: study conception, data collection, manuscript writing Garadappagari Dharmadeep: data acquisition and analysis. Y Muralidhar Reddy: data interpretation. Sreekath C.A.B. data collection. Kranthi Praveen Raj; study conception. Vishnu vardhan Reddy; manuscript writing. All the authors approved the final version of the manuscript for publication.

ETHICAL POLICY AND INSTITUTIONAL REVIEW BOARD STATEMENT

The study was carried out after obtaining institutional (G Pulla Reddy Dental College and Hospital Kurnool Andhra Pradesh, India) ethical committee clearance (GPRDCH/IEC.12/2013).

PATIENT DECLARATION OF CONSENT

The authors certify that they have obtained all appropriate patient consent forms. In the form the patient(s) has/have given his/her/their consent for his/her/their images and other clinical information to be reported in the journal. The patients understand that their names and initials will not be published and due efforts will be made to conceal their identity, but anonymity cannot be guaranteed.

DATA AVAILABILITY STATEMENT

The data set used in the current study is available.

REFERENCES

1. Ringane AA, Hattarki R. Comparison of stress distribution on bone and mini-implants during en-masse retraction of maxillary anterior teeth in labial and lingual orthodontics: A three-dimensional finite element analysis. *Indian J Health Sci Biomed Res* 2018;11:130-5.
2. Khan BI, Singaraju GS, Mandava P, Reddy GV, Nettam V, Bhavikati VN. Comparison of anchorage pattern under two types of orthodontic mini-implant loading during retraction in type A anchorage cases. *J Clin Diagn Res* 2016;10:ZC98-102.
3. Kathrin B, Annika P, Caroline B, Benedict W, Michael W, Dieter D. Efficacy of orthodontic mini implants for en masse retraction in the maxilla: A systematic review and meta-analysis. *Int J Implant Dent* 2018;4:1-12.
4. Linkow LI. Implant in orthodontics. *J Clin Orthod* 1970; 4: 685-90.
5. Konomi R. Mini-implant for orthodontic anchorage. *J Clin Orthod* 1997; 31:763-767.
6. Umemori M, Sugawara J, Mitani H, Nagasaka H, Kawamura H. Skeletal anchorage system for open-bite correction. *Am J Orthod Dentofacial Orthop*. 1999;115:166-74.
7. Davis D, Krishnaraj R, Duraisamy S, Ravi K, Dilip S, Charles A, et al. Comparison of rate of canine retraction and anchorage potential between mini-implant and conventional molar anchorage: An *in vivo* study. *Contemp Clin Dent* 2018;9:337-42.
8. Chandra P, Kulshrestha RS, Tandon R, Singh A, Kakadiya A, Wajid M. Horizontal and vertical changes in anchor molars after extractions in bimaxillary protrusion cases. *APOS Trends Orthod* 2016;6:154-9.
9. Quraishi D, Rajoo TP, Kumar DA, Rajoo PRH. Comparison of rate of en masse retraction and anchorage loss in conventional labial appliance with labial and lingual force: A clinical study. *J Indian Orthod Soc* 2018;52:120-6.
10. Deguchi T, Nasu M, Murakami K, Yabuuchi T, Kamioka H, Yamamoto TT. Quantitative evaluation of cortical bone thickness with CT scanning for orthodontic implants. *Am J Orthod Dentofacial Orthop* 2006;129:721.e7-12.
11. Poggio PM, Incorvati C, Velo S, Carano A. "Safe zones": A guide for miniscrew positioning in the maxillary and mandibular arch. *Angle Orthod* 2006;76:191-7.
12. Seong-Hun K, Yoon-Ah K, Won L, Insoo K. Two-component mini-implant as an efficient tool for orthognathic patients. *Am J Orthod Dentofacial Orthop* 2009;135:110-7.
13. Garfinkle JS, Cunningham LL Jr, Beeman CS, Kluemper GT, Hicks EP, Kim MO. Evaluation of orthodontic mini-implant anchorage in premolar extraction therapy in adolescents. *Am J Orthod Dentofacial Orthop* 2008;133:642-53.
14. Wook H, Dong-Seok N, Seung-Hak B. En masse retraction and two-step retraction of maxillary anterior teeth in adult class I women angle orthodontist. 2007;77:975-8.
15. Madhur U, Sumit Y, Nagaraj K, Sameer P. Treatment effects of mini-implants for en-masse retraction of anterior teeth in bialveolar protrusion patients: A randomized controlled trial. *Am J Orthod Dentofacial Orthop* 2008;134:18-29.
16. Basha AG, Shantharaj R, Mogeowda SB. Comparative study between conventional en-masse retraction (sliding mechanics) and en-masse retraction using orthodontic micro implants. *Implant Dent* 2010;19:128-36.
17. Isao K, Shoichiro I, Yuka A, Teruko T-Y, Shouichi M. Differences between sliding mechanics with implant anchorage and straight-pull headgear and intermaxillary elastics in adults with bimaxillary protrusion. *Eur J Orthod* 2011;33:126-31.
18. Jonathan S, Alison M, Badri T, Rodrigo G, Paul S, Kevin O'B. Effectiveness of 3 methods of anchorage reinforcement for maximum anchorage in adolescents: A 3-arm multicenter randomized clinical trial. *Am J Orthod Dentofacial Orthoped* 2014;146:10-20.
19. Monnerat C, Restle L, Mucha JN. Tomographic mapping of mandibular interradicular spaces for placement of orthodontic mini-implants. *American Journal of Orthodontics and Dentofacial Orthopedics, Official Publication of the American Association of Orthodontists, Its Constituent Societies, and the American Board of Orthodontics*. 2009;135:428.e1-e9.
20. Thiruvencatachari B, Ammayappan P, Kandaswamy R. Comparison of rate of canine retraction with conventional molar anchorage and titanium implant anchorage. *Am J Orthod Dentofacial Orthop*. 2008;134:30-5.