

Decreased Premotor Cortex Volume in Victims of Urban Violence with Posttraumatic Stress Disorder

Vanessa Rocha-Rego^{1*}, Mirtes G. Pereira², Leticia Oliveira², Mauro V. Mendlowicz², Adriana Fiszman³, Carla Marques-Portella³, William Berger², Carlton Chu⁴, Mateus Joffily¹, Jorge Moll⁵, Jair J. Mari⁶, Ivan Figueira³, Eliane Volchan¹

1 Instituto de Biofísica Carlos Chagas Filho, Universidade Federal do Rio de Janeiro, Rio de Janeiro, Brazil, **2** Universidade Federal Fluminense, Niteroi, Brazil, **3** Instituto de Psiquiatria, Universidade Federal do Rio de Janeiro, Rio de Janeiro, Brazil, **4** University College London, London, United Kingdom, **5** D'Or Institute for Research and Education, Rio de Janeiro, Brazil, **6** Universidade Federal de São Paulo, São Paulo, Brazil

Abstract

Background: Studies addressing posttraumatic stress disorder (PTSD) have demonstrated that PTSD patients exhibit structural abnormalities in brain regions that relate to stress regulation and fear responses, such as the hippocampus, amygdala, anterior cingulate cortex, and ventromedial prefrontal cortex. Premotor cortical areas are involved in preparing to respond to a threatening situation and in representing the peripersonal space. Urban violence is an important and pervasive cause of human suffering, especially in large urban centers in the developing world. Violent events, such as armed robbery, are very frequent in certain cities, and these episodes increase the risk of PTSD. Assaultive trauma is characterized by forceful invasion of the peripersonal space; therefore, could this traumatic event be associated with structural alteration of premotor areas in PTSD?

Methodology/Principal Findings: Structural magnetic resonance imaging scans were acquired from a sample of individuals that had been exposed to urban violence. This sample consisted of 16 PTSD patients and 16 age- and gender-matched controls. Psychometric questionnaires differentiated PTSD patients from trauma-exposed controls with regard to PTSD symptoms, affective, and resilience predispositions. Voxel-based morphometric analysis revealed that, compared with controls, the PTSD patients presented significant reductions in gray matter volume in the ventral premotor cortex and in the pregenual anterior cingulate cortex.

Conclusions: Volume reduction in the premotor cortex that is observed in victims of urban violence with PTSD may be associated with a disruption in the dynamical modulation of the safe space around the body. The finding that PTSD patients presented a smaller volume of pregenual anterior cingulate cortex is consistent with the results of other PTSD neuroimaging studies that investigated different types of traumatic events.

Citation: Rocha-Rego V, Pereira MG, Oliveira L, Mendlowicz MV, Fiszman A, et al. (2012) Decreased Premotor Cortex Volume in Victims of Urban Violence with Posttraumatic Stress Disorder. PLoS ONE 7(8): e42560. doi:10.1371/journal.pone.0042560

Editor: Manos Tsakiris, Royal Holloway, University of London, United Kingdom

Received: March 14, 2012; **Accepted:** July 10, 2012; **Published:** August 31, 2012

Copyright: © 2012 Rocha-Rego et al. This is an open-access article distributed under the terms of the Creative Commons Attribution License, which permits unrestricted use, distribution, and reproduction in any medium, provided the original author and source are credited.

Funding: This work was supported by the National Council for Scientific and Technological Development (CNPq) and the Carlos Chagas Filho Foundation for Research Support in Rio de Janeiro (FAPERJ). Currently, Vanessa Rocha-Rego is funded by Coordenação de Aperfeiçoamento de Pessoal de Nível Superior (CAPES). The funders had no role in study design, data collection and analysis, decision to publish, or preparation of the manuscript.

Competing Interests: The authors have declared that no competing interests exist.

* E-mail: rochavr@biof.ufrj.br

Introduction

Post-Traumatic Stress Disorder (PTSD) is an anxiety disorder following an exposure to a traumatic event. The diagnostic criteria for PTSD require experiencing, witnessing, or being confronted with an event or events that involve actual or threatened death or serious injury, or a threat to the physical integrity of self or others (criterion A1). It also requires that the person experience intense fear, helplessness, or horror during the traumatic event (criterion A2). PTSD is characterized by a series of symptoms, including intrusions (e.g., nightmares or flashbacks), hyperarousal (e.g., insomnia or an exaggerated startle response), numbing (e.g., restricted affect or anhedonia), and avoidance of trauma-related stimuli. A diagnosis of PTSD requires these symptoms to last for a minimum of one month and disrupt the normal functioning of the

patient [1]. Lifetime prevalence of PTSD in the general population of the United States was estimated at 7.8% [2]. PTSD follows a chronic course that causes patients to experience significant functional impairment and increase their usage of healthcare resources, resulting in substantial personal and societal costs [3,4].

Over the past several years, neuroimaging studies of PTSD subjects have focused on elucidating the brain circuits that mediate this disorder [5–8]. Several PTSD studies have reported structural abnormalities in brain regions related to stress regulation and fear circuits [8], such as the hippocampus, anterior cingulate cortex, ventromedial prefrontal cortex, and amygdala. The hippocampus, a structure shown to contribute to PTSD etiology [9,10], plays a role in the fear conditioning and extinction aspects of contextual memory [11,12], as well as in stress regulation [13,14]. Different meta-analyses revealed significantly smaller hippocampal volumes

in PTSD patients than control subjects [15–17]. It has been suggested that the ventromedial prefrontal/anterior cingulate cortex, and the amygdala take part in a model of PTSD pathogenesis in which the cortical regions fail to inhibit a hyperactive amygdala [18,19]. A meta-analysis of structural abnormalities in PTSD found significantly smaller amygdala volumes in adults with PTSD compared with both healthy and trauma-exposed controls [15]. Recent structural studies found that ventromedial prefrontal/anterior cingulate cortex are reduced in PTSD subjects [20–26].

Studies of the neurobiology of PTSD had focused on a narrow spectrum of trauma. Indeed, combat veterans and survivors of childhood physical and sexual abuse accounted for 85% of all subjects recruited to PTSD neuroimaging studies [27]. Thus far, no study has investigated the structural brain changes associated with PTSD elicited by urban violence. Urban violence is an important and pervasive cause of human suffering, especially in the large population centers of the developing world [28]. Violent events, such as armed robbery, are very frequent in certain cities, and these episodes increase the risk of developing PTSD [29]. In fact, an epidemiologic study has revealed that being threatened with a weapon accounted for 32.6% of the risk of PTSD development in women [2].

Assaultive trauma is characterized by forceful invasion of the peripersonal space, which is defined as a margin of safety around the body [30–32]. The invasion of this margin of safety is often experienced as a threat to an individual's psychological or biological integrity and may lead to intense discomfort and anxiety [30–33]. A number of functional studies in PTSD have shown altered activity in premotor cortical areas [34–37]; these areas are involved both in preparing to respond to a threatening situation and in peripersonal space representation [38–41].

A recent structural study in PTSD victims of child sexual/physical abuse, a traumatic event that involves forceful invasion of personal space, observed volume reduction in premotor cortical region [25]. Structural abnormalities in hippocampus, anterior cingulate/ventromedial-prefrontal cortex and amygdala, but not in premotor areas, were observed in studies assessing traumatic situations such as terrorism [42], disaster [20,43,44], war [21–23] and disease [45]. These traumatic situations can be very heterogeneous and do not necessarily involve an invasion of peripersonal space.

Recently, an experimental study provided evidence that life-threatening urban violence events are a major trigger for motor defensive reactions in humans [46]. Neurobiology studies have suggested that the premotor cortex incorporates both a representation of peripersonal space and defensive-like motor repertoires [38–41]. Could PTSD resulting from forceful invasion of peripersonal space be associated with structural alteration in cortical premotor areas? In this study, we address this question by examining PTSD patients exposed to the trauma of urban violence. We expect to observe a volumetric reduction in the premotor cortex in these particular patients, in addition to the structural alterations in the hippocampus, anterior cingulate/ventromedial-prefrontal cortex and amygdala that are typically observed in PTSD patients.

Materials and Methods

Participants

In total, 32 patients with current PTSD were recruited from an outpatient university clinic that specialized in the posttraumatic stress assessment and treatment of urban violence victims. The diagnosis of PTSD was obtained using the Structured Clinical

Interview for DSM-IV Axis I [47], which had previously been translated and adapted to Portuguese [48]. For the following reasons, 16 patients were excluded from the study: history of alcohol/substance dependence or abuse ($n = 9$); psychosis ($n = 2$); risk of suicide ($n = 1$); claustrophobia ($n = 3$); and bullet lodged in the head ($n = 1$).

We acquired structural magnetic resonance imaging scans of the remaining 16 patients. These patients were under pharmacological treatment with antidepressant drugs in adequate doses according to the recommended guidelines for PTSD [49] and presented major depression co-morbidity. The control group was selected from a list of approximately 300 employees of the Federal University of Rio de Janeiro. From this list, 21 victims of urban violence matched by age, education level and gender with the patients were selected for an interview. After the administration of the Structured Clinical Interview for DSM-IV Axis I, 4 participants were excluded because they presented a past history of PTSD ($n = 2$), obsessive compulsive disorder ($n = 1$), or depression ($n = 1$). The remaining 16 trauma-exposed participants were scanned as controls. They met criteria A1 and A2 (DSM-IV) and had no past or current history of mental disorder. The predominant traumatic event for both patients and controls was armed robbery. The characteristics of the sample are described in Table 1.

Ethics statement

This study was approved by the Ethics Review Board of the Institute of Psychiatry of the Federal University of Rio de Janeiro. Written informed consent was obtained from all of the participants after a detailed description of the study.

Psychometric Assessment

All subjects included in our study were victims of urban violence. To characterize the contrast between the test group of patients with PTSD and the control group of trauma-exposed individuals without PTSD, an analysis of PTSD symptomatology,

Table 1. Characteristics of the sample population.

Characteristics	PTSD		Controls	
	N	%	N	%
Gender				
Women	9	56.2	9	56.2
Men	7	43.8	7	43.8
Relationship status				
Single	1	6.3	2	12.4
Married/living with partner	12	75.0	13	81.2
Divorced/widower	3	10.8	1	6.3
Type of traumatic event				
Armed violence	13	81.2	12	75.0
Motor vehicle accidents	3	10.8	2	12.4
Assault without gun	-	-	1	6.3
Sexual abuse	-	-	1	6.3
	Mean	SD	Mean	SD
Age	43.3	5.78	44.9	6.60
Education level (years)	10.5	2.59	11.8	3.56
Time elapsed since trauma (in years)	3.0	4.8	11	9.8

doi:10.1371/journal.pone.0042560.t001

affective dispositions and resilience traits was conducted. PTSD symptom severity was assessed using the Post-Traumatic Stress Disorder Checklist - Civilian Version (PCL-C) [50], translated and adapted to Portuguese by [51]. The PCL is a standardized self-report rating scale for PTSD and is composed of 17 items that correspond to the key symptoms of PTSD. The participants indicate how much they have been bothered by a symptom over the past month using a 5-point scale that ranges from 1 (Not at All) to 5 (Extremely). Affect traits were assessed using the Positive and Negative Affect Schedule scale (trait version, PANAS-T) [52], which uses 10 positive and 10 negative adjectives describing mood. The participants rated each mood adjective on a scale from 1 (very slightly or not at all) to 5 (extremely). The Ego-Resilience scale (ER-89) [53] was used to assess how each individual subject manages the challenges and experiences of daily life. The scale has 14 items, each of which are rated on a scale from 1 (does not apply at all) to 4 (applies very strongly).

MRI acquisition

All participants were scanned at the LABS-D'Or Network outpatient MRI unit using a 1.5-Tesla MR scanner (Philips Medical Systems, the Netherlands). High-resolution structural T1-weighted volumetric images were acquired with full head coverage. In total, 160 contiguous sagittal slices were acquired for each participant, using the following parameters: TR = 8.11 ms, TE = 3.7 ms, flip angle = 8°, field of view = 256 mm, slice thickness = 1.00 mm.

Pre-processing of images

Voxel-based morphometry (VBM) was conducted using SPM5 statistical parametric mapping software (Wellcome Department, University College London; <http://www.fil.ion.ucl.ac.uk/spm/>) running in MATLAB 7 (Mathworks, Sherborn, MA). The images were segmented by gray matter (GM), white matter (WM) and cerebrospinal fluid (CSF). Next, we applied the DARTEL toolbox for normalization of the data. This methodological approach provided improved inter-subject alignment accuracy [54].

DARTEL warps images from individual subjects to the group template, and an initial group average is created as the beginning target with rigidly aligned images. Then, individual images are warped to match the average. After a few iterations of warping, a shaper average is created. This procedure was repeated six times. At each stage, the regularization is reduced; hence, the amount of warping increases at each iteration. Additionally, Jacobian-scaled ("modulated") warped tissue class images were created to conserve the total volume within the voxels. Then, segmented, normalized and modulated GM images were smoothed with an 8-mm FWHM Gaussian kernel. The data were subsequently warped to MNI space.

Statistical Analyses

We compared psychometric measures between PTSD and controls groups using Student's t-test for independent samples. Statistical comparisons of gray matter volume between PTSD and controls groups were performed using t-tests with statistical parametric mapping (SPM5). Total brain volume was treated as a confounding variable. The resulting set of voxel values for each contrast constituted a statistical parametric map of t-statistics SPM(t). The SPM(t) values were converted into z-scores SPM(z). Significance was set at a voxel level of $p < 0.05$, which was FDR-corrected for multiple comparisons.

Additionally, as the hippocampus and amygdala have been the focus of many studies in PTSD, we performed a region of interest (ROI) analysis restricted to these structures. These ROIs were

defined using the Wake Forest Pickatlas, version 1.04 [55], and the analysis was performed using the Marsbar toolbox (<http://marsbar.sourceforge.net/>) for SPM5.

Results

The PTSD group presented significantly greater symptom severity scores than the control group ($p < 0.0001$). In addition, psychometric analysis indicated that the PTSD group had lower positive affect scores ($p < 0.0001$) and higher negative affect scores ($p < 0.0001$) than the control group. Moreover, the PTSD subjects had lower ego-resilience scores than the control subjects ($p < 0.0001$).

VBM analysis revealed decreased gray matter volume in the premotor cortex of the PTSD group compared to the traumatized control group, $p < 0.05$ corrected. We also observed a gray matter volume reduction in the anterior cingulate cortex in PTSD subjects, $p < 0.05$ corrected (Table 2 and Figure 1). Neither the hippocampus nor the amygdala differed in volume between the PTSD and control groups.

We estimated the cluster at the anterior cingulate cortex to be centered at the pregenual BA 32, according to the subdivision of the cingulate described by Vogt [56]; and the cluster at the premotor cortex to be centered at ventral BA 6, according to the subdivision of motor areas described by Rizzolatti et al [40].

ROI analysis showed that the hippocampal and amygdala volumes of traumatized victims with PTSD did not differ from controls.

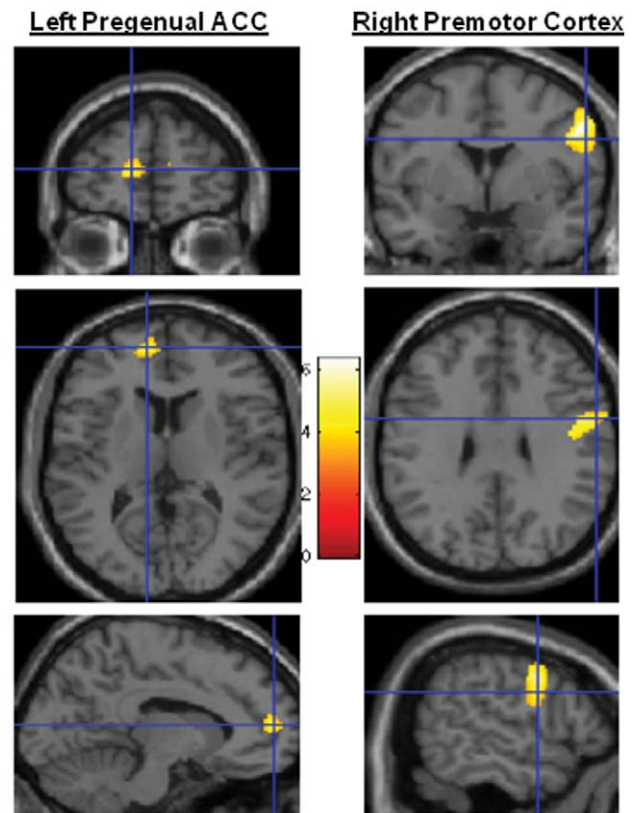


Figure 1. Statistical parametric mapping (SPM) showing clusters in the left pregenual anterior cingulate cortex and the right ventral premotor cortex. There are significant differences in gray matter volume between the PTSD and control groups. doi:10.1371/journal.pone.0042560.g001

Table 2. Results of t-tests comparing PTSD and control groups.

Brain region	Laterality	Coordinates			Cluster size	Z-score
		X	Y	Z		
Ventral premotor cortex*	R	53	-1	35	975	5.01
Pregenuar anterior cingulate cortex*	L	-12	54	10	242	4.14
Superior parietal sulcus†	R	31	-76	47	83	4.16
Superior temporal sulcus†	R	53	-25	-3	52	3.37

Stereotactic coordinates are quoted within MNI space.

* $p < 0.05$ corrected,

†For a more lenient statistical significance threshold of $p < 0.001$ (uncorrected).

doi:10.1371/journal.pone.0042560.t002

Discussion

The goal of this study was to investigate gray matter volume alteration in PTSD victims of urban violence, a traumatic event characterized by forceful invasion of peripersonal space. We found reduced gray matter volume in the ventral premotor cortex in PTSD patients compared to traumatized controls. We also found a reduction in the anterior cingulate cortex.

The present results suggest that structural alteration in the ventral premotor cortex may contribute to PTSD pathophysiology in victims of interpersonal violence. Graziano and Cooke [39] showed that the premotor cortex is involved in protective mechanisms that are essential in extreme, life-threatening situations [39]. These authors suggested that this region is involved in the representation of the peripersonal space as a margin of safety around the body, as well as in the selection and coordination of defensive behavior [39]. Studies of social interactions have indicated that individuals instinctively dynamically regulate the interpersonal distance between themselves and others to avoid discomfort [57] and that the invasion of peripersonal space can lead to anxiety on the part of the victim [33].

Premotor cortex structural abnormalities observed in PTSD patients may be associated with inappropriate construction of a margin of safety around the body, as well as inefficient selection and coordination of defensive responses. Restoring the margin of safety around the body in the aftermath of violence may be an essential aspect of the recovery from these traumatic events. The integrity of the premotor cortex is likely a critical factor for these restorative mechanisms.

Structural abnormalities in premotor cortex observed in PTSD patients may be associated to inappropriate construction of a margin of safety around the body as well as inefficient selection and coordination of defensive responses. Restoring the margin of safety around the body in the aftermath of violence may be an essential part of the recovering processes from these traumatic events. The integrity of the premotor cortex is likely important for these restorative mechanisms.

We observed significantly gray matter volume reduction in the anterior cingulate cortex in PTSD patients compared to traumatized controls. Previous VBM studies also observed volumetric reductions in this region in PTSD patients [20–25].

A review of functional imaging studies in PTSD detected less activation in this region as well as more activation in amygdala in response to emotional stimuli in patients compared to participants without PTSD [58]. These functional results are in accordance with a current model for PTSD; this model proposes that the anterior cingulate is hyporesponsive and that the amygdala is hyperresponsive in PTSD patients [58].

The anterior cingulate cortex is functionally and anatomically complex and heterogeneous [56,59]. Vogt [56], based on cytoarchitectonic, connectivity and neurotransmitter receptor criteria, proposed a subdivision of the anterior cingulate cortex into subgenual and pregenual regions. The subgenual region is heavily connected to the amygdala in both humans and non-human primates [60,61]. This region is also critical for the retention of fear extinction in healthy individuals [62] and is related to fear extinction deficits in PTSD patients [63]. The pregenual subdivision is less well connected to the amygdala [60,61], suggesting that it plays a smaller role in fear circuit modulation. In the present study, we observed volume reduction in the pregenual subdivision of the anterior cingulate; one interpretation for the abnormalities observed in the pregenual subdivision of the anterior cingulate cortex is the following line of reasoning. Functional studies in healthy subjects revealed increased activity in the pregenual anterior cingulate cortex when experiencing feelings of happiness that are induced by words [64], films [65], recalled experiences [66–68], music [69] or faces [70–72]. A recent study using a sensitive meta-analytic method that analyzed a substantially large number of neuroimaging studies also found that the pregenual anterior cingulate cortex was consistently associated with happiness [73]. It seems reasonable to hypothesize that reduced gray matter volumes in the pregenual anterior cingulate cortex of PTSD patients could be associated with a reduced ability to experience pleasurable emotions. Indeed, impairment in the processing of pleasant cues in PTSD has been reported [74]. In the present study, psychometric assessments revealed that compared with trauma-exposed controls, PTSD patients scored significantly lower on both positive affect and ego-resilience scales, which measure two important components of the concept of happiness [75].

A meta-analysis of structural brain abnormalities in PTSD found significantly smaller hippocampal volumes in PTSD compared to controls with and without trauma exposure [15]. Here, we did not observe hippocampal volume reduction in PTSD patients compared to trauma-exposed controls, both in the whole brain and in the region-of-interest analyses. More studies are necessary to clarify whether the absence of hippocampus reduction in the present study is due to distinctiveness of urban violence trauma or to other characteristics of the sample and/or methodology.

Amygdala volume did not differ between PTSD patients and trauma-exposed controls. A meta-analysis of structural brain abnormalities observed significantly smaller left amygdala volumes in adults with PTSD compared with both healthy and trauma-exposed controls [15]. A subsequent meta-analysis on amygdala volume in adult PTSD patients showed no significant differences

between PTSD and controls [76]. The authors of the more recent of these two meta-analyses [76] attributed this discrepancy to the inclusion of pediatric data in the initial meta-analysis [15].

As far as we know, this study is the first to find gray matter volume reduction in the ventral premotor cortex in PTSD patients. This finding may be explained by the type of traumatic event. Here, more than 80% of PTSD patients reported armed robbery as the index trauma. In this type of trauma, the victims were confronted with a threat represented by a weapon pointed at them, and their peripersonal space was violated by the robber. Other VBM studies assessed traumatic situations such as terrorism [42], disaster [20,43,44], war [21–23] and disease [45]. These traumatic situations, as well as those that assessed populations that experience mixed trauma, can be very heterogeneous and do not essentially involve an invasion of peripersonal space. Interestingly, a VBM study that evaluated victims of physical/sexual abuse, which also involves forceful invasion of the personal space, observed abnormalities in the supplementary motor area, a region adjacent to the ventral premotor cortex [25]. More studies evaluating traumatic events that violate peripersonal space are necessary to investigate motor area involvement in PTSD pathology.

References

- American Psychiatric Association (1994) Diagnostic and Statistical Manual of Mental Disorders, 4th edition. APA, Washington, DC.
- Kessler RC, Sonnega A, Bromet E, Hughes M, Nelson CB (1995) Posttraumatic stress disorder in the National Comorbidity Survey. *Arch Gen Psychiatry* 52:1048–60.
- Hidalgo RB, Davidson JR (2000) Posttraumatic stress disorder: epidemiology and health-related considerations. *J Clin Psychiatry* 7:5–13.
- Figueira I, da Luz M, Braga RJ, Cabizuca M, Coutinho E, et al. (2007) The increasing internationalization of mainstream posttraumatic stress disorder research: a bibliometric study. *J Trauma Stress* 20:89–95.
- Francati V, Vermetten E, Bremner JD (2007) Functional neuroimaging studies in posttraumatic stress disorder: review of current methods and findings. *Depress Anxiety* 24:202–18.
- Liberzon I, Sripada CS (2008) The functional neuroanatomy of PTSD: a critical review. *Prog Brain Res* 167:151–69.
- Robinson BL, Shergill SS (2011) Imaging in posttraumatic stress disorder. *Curr Opin Psychiatry* 24:29–33.
- Shin LM, Handwerker K (2009) Is posttraumatic stress disorder a stress-induced fear circuitry disorder? *J Trauma Stress* 22:409–15.
- Shin LM, Shin PS, Heckers S, Krangel TS, Macklin ML, et al. (2004) Hippocampal function in posttraumatic stress disorder. *Hippocampus* 14:292–300.
- Bremner JD, Vythilingam M, Vermetten E, Southwick SM, McGlashan T, et al. (2003) MRI and PET study of deficits in hippocampal structure and function in women with childhood sexual abuse and posttraumatic stress disorder. *Am J Psychiatry* 160:924–32.
- Maren S, Holt W (2000) The hippocampus and contextual memory retrieval in Pavlovian conditioning. *Behav Brain Res* 1:97–108.
- Sanders MJ, Wiltgen BJ, Fanselow MS (2003) The place of the hippocampus in fear conditioning. *Eur J Pharmacol* 463: 217–23.
- Bremner JD (2001) Hypotheses and controversies related to effects of stress on the hippocampus: an argument for stress-induced damage to the hippocampus in patients with posttraumatic stress disorder. *Hippocampus* 11: 75–81
- Sapolsky RM (2000) Glucocorticoids and hippocampal atrophy in neuropsychiatric disorders. *Arch Gen Psychiatry* 57:925–35.
- Karl A, Schaefer M, Malta LS, Dörfel D, Rohleder N, et al. (2006) A meta-analysis of structural brain abnormalities in PTSD. *Neurosci Biobehav Rev* 30:1004–31
- Smith ME (2005) Bilateral hippocampal volume reduction in adults with posttraumatic stress disorder: a meta-analysis of structural MRI studies. *Hippocampus* 15:798–807.
- Kitayama N, Vaccarino V, Kutner M, Weiss P, Bremner JD (2005) Magnetic resonance imaging (MRI) measurement of hippocampal volume in posttraumatic stress disorder: a meta-analysis. *J Affect Disord* 88:79–86.
- Shin LM, Rauch SL, Pitman RK (2006) Amygdala, medial prefrontal cortex, and hippocampal function in PTSD. *Ann N Y Acad Sci* 1071:67–79.
- Lobo I, Oliveira L, David IA, Pereira MG, Volchan E, et al. (2011) The neurobiology of posttraumatic stress disorder: dysfunction in the prefrontal-amygdala circuit? *Psychology & Neuroscience* 4: 191–203
- Chen S, Xia W, Li L, Liu J, He Z, et al. (2006) Gray matter density reduction in the insula in fire survivors with posttraumatic stress disorder: a voxel-based morphometric study. *Psychiatry Res* 146: 65–72.
- Kasai K, Yamasue H, Gilbertson MW, Shenton ME, Rauch SL, et al. (2008) Evidence for acquired pregenual anterior cingulate gray matter loss from a twin study of combat-related posttraumatic stress disorder. *Biol Psychiatry* 63: 550–556.
- Woodward SH, Kaloupek DG, Streeter CC, Martinez C, Schaer M, et al. (2006) Decreased anterior cingulate volume in combat-related PTSD. *Biol Psychiatry* 59:582–7.
- Eckart C, Stoppel C, Kaufmann J, Tempelmann C, Hinrichs H, et al. (2011) Structural alterations in lateral prefrontal, parietal and posterior midline regions of men with chronic posttraumatic stress disorder. *J Psychiatry Neurosci* 36:176–86.
- Kroes MC, Rugg MD, Whalley MG, Brewin CR (2011) Structural brain abnormalities common to posttraumatic stress disorder and depression. *J Psychiatry Neurosci* 36:256–65.
- Thomas K, Dorrepaal E, Draijer N, de Ruiter MB, van Balkom AJ, et al. (2010) Reduced anterior cingulate and orbitofrontal volumes in child abuse-related complex PTSD. *J Clin Psychiatry* 72:1636–44.
- Geuze E, Westenberg HG, Heinecke A, de Kloet CS, Goebel R, et al. (2008) Thinner prefrontal cortex in veterans with posttraumatic stress disorder. *Neuroimage* 41(3):675–81
- Hull AM (2002) Neuroimaging findings in post-traumatic stress disorder. Systematic review. *Br J Psychiatry* 181: 102–110.
- Reichenheim ME, de Souza ER, Moraes CL, de Mello Jorge MH, da Silva CM, et al. (2011) Violence and injuries in Brazil: the effect, progress made, and challenges ahead. *Lancet* 377:1962–75.
- Mari JJ, de Mello MF, Figueira I (2008) The impact of urban violence on mental health. *Rev Bras Psiquiatr* 30: 183–184.
- Horowitz MJ, Duff DF, Stratton LO (1964) Body buffer zone - exploration of personal space. *Archives of General Psychiatry* 11: 651–656
- Hayduk LA (1978) Personal space: An evaluative and orienting overview. *Psychological Bulletin* 85: 117–134.
- Lloyd DM (2009) The space between us: a neurophilosophical framework for the investigation of human interpersonal space. *Neurosci Biobehav Rev* 33:297–304
- Wieser MJ, Pauli P, Grosseibl M, Molzow I, Muhlberger A (2010) Virtual social interactions in social anxiety—the impact of sex, gaze, and interpersonal distance. *Cyberpsychol Behav Soc Netw* 13: 547–554.
- Bremner JD, Staib LH, Kaloupek D, Southwick SM, Soufer R, et al. (1999a) Neural correlates of exposure to traumatic pictures and sound in Vietnam combat veterans with and without posttraumatic stress disorder: a positron emission tomography study. *Biol Psychiatry* 45:806.
- Bremner JD, Narayan M, Staib LH, Southwick SM, McGlashan T, et al. (1999b) Neural correlates of memories of childhood sexual abuse in women with and without posttraumatic stress disorder. *Am J Psychiatry* 156:1787–95.
- Bremner JD, Vythilingam M, Vermetten E, Southwick SM, McGlashan T, et al. (2003) Neural correlates of declarative memory for emotionally valenced words in women with posttraumatic stress disorder related to early childhood sexual abuse. *Biol Psychiatry* 53:879–89.
- Falconer E, Bryant R, Felmingham KL, Kemp AH, Gordon E, et al. (2008) The neural networks of inhibitory control in posttraumatic stress disorder. *J Psychiatry Neurosci* 33:413–22

Limitations

Our study has a number of limitations. First, the sample size is relatively small. Second, the study lacks a second control group of healthy subjects that were not exposed to trauma. Third, this study is essentially cross-sectional and does not allow for causal conclusions to be derived regarding the structural alterations observed herein, which could have resulted from either PTSD or a pre-trauma vulnerability factor. Longitudinal studies will be essential for addressing this question.

Acknowledgments

We extend special thanks to Sonia Gleiser for her managing assistance.

Author Contributions

Conceived and designed the experiments: VRR MGP LO MVM AF CMP WB CC MJ JM IF EV. Performed the experiments: VRR MGP LO AF MVM CMP WB JM. Analyzed the data: VRR MGP CC MJ. Contributed reagents/materials/analysis tools: VRR MGP LO AF CC CMP WB JM. Wrote the paper: VRR MGP LO MVM AF CMP JM IF EV.

38. De Gelder B, Snyder J, Greve D, Gerard G, Hadjikhani N (2004) Fear fosters flight: a mechanism for fear contagion when perceiving emotion expressed by a whole body. *Proc Natl Acad Sci*. 101:16701–16706.
39. Graziano MS, Cooke DF (2006) Parieto-frontal interactions, personal space, and defensive behavior. *Neuropsychologia* 44: 2621–2635.
40. Rizzolatti G, Fogassi L, Gallese V (2002) Motor and cognitive functions of the ventral premotor cortex. *Curr Opin Neurobiol* 12: 149–154.
41. Grezes J, Pichon S, De Gelder B (2007) Perceiving fear in dynamic body expressions. *NeuroImage* 35:959–967
42. Yamasue H, Kasai K, Iwanami A, Ohtani T, Yamada H, et al. (2003) Voxel-based analysis of MRI reveals anterior cingulate gray-matter volume reduction in posttraumatic stress disorder due to terrorism. *Proc Natl Acad Sci U S A* 100: 9039–9043.
43. Jatzko A, Rothenhöfer S, Schmitt A, Gaser C, Demirakca T, et al. (2006) Hippocampal volume in chronic posttraumatic stress disorder (PTSD): MRI study using two different evaluation methods. *J Affect Disord*. 94:121–6.
44. Zhang J, Tan Q, Yin H, Zhang X, Huan Y, et al. (2011) Decreased gray matter volume in the left hippocampus and bilateral calcarine cortex in coal mine flood disaster survivors with recent onset PTSD. *Psychiatry Res* 192:84–90.
45. Hakamata Y, Matsuoka Y, Inagaki M, Nagamine M, Hara E, et al. (2007) Structure of orbitofrontal cortex and its longitudinal course in cancer-related post-traumatic stress disorder. *Neurosci Res* 59:383–9
46. Volchan E, Souza GG, Franklin CM, Norte CE, Rocha-Rego V, et al. (2011) Is there tonic immobility in humans? Biological evidence from victims of traumatic stress. *Biol Psychol* 88: 13–19
47. First MB, Spitzer RL, Gibbon M, Williams JBW (1997) Structured Clinical Interview for DSM-IV Axis I Disorders (SCID I), Clinical Version. Washington, D.C.: American Psychiatric Press, Inc.
48. Del-Ben C, Vilela J, Hallak J, Labate C, Zuardi AW (2001) Confiabilidade da “Entrevista Clínica Estruturada para o DSM-IV - Versão Clínica”, *Rev Bras Psiquiatr* 23: 156–159.
49. Friedman MJ, Davidson JR, Stein DJ (2008) Effective treatments for PTSD: practice guidelines from the International Society for Traumatic Stress Studies. In: *Psychopharmacology for Adults*. The Guilford Press, New York, pp. 245–268.
50. Weathers FW, Litz BT, Huska JA, Keane TM (1994) PTSD checklist-civilian version. National Center for PTSD Behavioral Science Division, Boston.
51. Berger W, Mendlowicz MV, Souza W, Figueira I (2004) Semantic equivalence of the Portuguese version of the Post-Traumatic Stress Disorder Checklist-Civilian Version (PCL-C) for the screening of post-traumatic stress disorder. *Revista de Psiquiatria do Rio Grande do Sul*, 26:167–175.
52. Watson D, Clark LA, Tellegen A (1988) Development and validation of brief measures of positive and negative affect — the PANAS scales. *J Pers Soc Psychol* 54: 1063–1070.
53. Block J, Kremen AM (1996) IQ and ego-resiliency: conceptual and empirical connections and separateness. *J Pers Soc Psychol*. 70: 349–61
54. Ashburner J (2007) A fast diffeomorphic image registration algorithm. *Neuroimage* 38: 95–113.
55. Maldjian JA, Laurienti PJ, Kraft RA, Burdette JH (2003) An automated method for neuroanatomic and cytoarchitectonic atlas-based interrogation of fMRI data sets. *Neuroimage* 19: 1233–1239.
56. Vogt BA (2009) *Cingulate Neurobiology and Disease*. Oxford University Press, London.
57. Hall E (1966) *The Hidden dimension*. Garden City, New York: Doubleday.
58. Hughes KC, Shin LM (2011) Functional neuroimaging studies of post-traumatic stress disorder. *Expert Rev Neurother*. 2011 11(2):275–85.
59. Bush G, Luu P, Posner MI (2000) Cognitive and emotional influences in anterior cingulate cortex. *Trends in Cognitive Sciences* 4: 215–222.
60. Ghashghaie HT, Hilgetag CC, Barbas H (2007) Sequence of information processing for emotions based on the anatomic dialogue between prefrontal cortex and amygdale. *Neuroimage*. 34: 905–923.
61. Johansen-Berg H, Gutman DA, Behrens TE, Matthews PM, Rushworth MF, et al. (2008) Anatomical connectivity of the subgenual cingulate region targeted with deep brain stimulation for treatment-resistant depression. *Cereb Cortex* 18:1374–83.
62. Phelps EA, Delgado MR, Nearing KI, LeDoux JE (2004) Extinction learning in humans: role of the amygdala and vmPFC. *Neuron* 43: 897–905.
63. Rauch SL, Shin LM, Phelps EA (2006) Neurocircuitry models of posttraumatic stress disorder and extinction: human neuroimaging research—past, present, and future. *Biol Psychiatry* 60: 376–382.
64. Takahashi H, Matsuura M, Koeda M, Yahata N, Suhara T, et al. (2008) Brain activations during judgments of positive self-conscious emotion and positive basic emotion: pride and joy. *Cereb Cortex* 18:898–903.
65. Lane RD, Reiman EM, Ahern GL, Schwartz GE, Davidson RJ (1997) Neuroanatomical correlates of happiness, sadness, and disgust. *Am J Psychiatry* 154:926–33.
66. George MS, Ketter TA, Parekh PI, Herscovitch P, Post RM (1996) Gender differences in regional cerebral blood flow during transient self-induced sadness or happiness. *Biol Psychiatry* 40:859–71.
67. Damasio AR, Grabowski TJ, Bechara A, Damasio H, Ponto LL, et al. (2000) Subcortical and cortical brain activity during the feeling of self-generated emotions. *Nat Neurosci*. 10:1049–56.
68. Pelletier M, Bouthillier A, Lévesque J, Carrier S, Breault C, et al. (2003) Separate neural circuits for primary emotions? Brain activity during self-induced sadness and happiness in professional actors. *Neuroreport* 14:1111–6.
69. Mitterschiffthaler MT, Fu CH, Dalton JA, Andrew CM, Williams SC (2007) A functional MRI study of happy and sad affective states induced by classical music. *Hum Brain Mapp* 28:1150–62.
70. Phillips ML, Bullmore ET, Howard R, Woodruff PW, Wright IC, et al. (1998) Investigation of facial recognition memory and happy and sad facial expression perception: an fMRI study. *Psychiatry Res* 83:127–38.
71. Kesler-West ML, Andersen AH, Smith CD, Avison MJ, Davis CE, et al. (2001) Neural substrates of facial emotion processing using fMRI. *Brain Res Cogn Brain Res* 11:213–26.
72. Killgore WD, Yurgelun-Todd DA (2004) Activation of the amygdala and anterior cingulate during nonconscious processing of sad versus happy faces. *Neuroimage*. 21:1215–23.
73. Vytal K, Hamann S (2010) Neuroimaging support for discrete neural correlates of basic emotions: a voxel-based meta-analysis. *J Cogn Neurosci* 22: 2864–2885.
74. Litz BT, Orsillo SM, Kaloupek D, Weathers F (2000) Emotional processing in posttraumatic stress disorder. *J Abnorm Psychol* 109:26–39.
75. Cohn MA, Fredrickson BL, Brown SL, Mikels JA, Conway AM (2009) Happiness unpacked: positive emotions increase life satisfaction by building resilience. *Emotion* 9: 361–368.
76. Woon FL, Hedges DW (2009) Amygdala volume in adults with posttraumatic stress disorder: a meta-analysis. *J Neuropsychiatry Clin Neurosci*. 21:5–12.