



OPEN



Scan code to view VIDEO

## Use of an Iris Speculum for Retrolental Membrane Dissection for Stage 5 Prematurity of Retinopathy Complicated With Pupillary Adhesion

**Purpose:** To report a novel use of an iris speculum to assist with membrane dissection and trough separation for stage 5 retinopathy of prematurity–related funnel-shaped tractional retinal detachment complicated with pupillary adhesion.

**Methods:** Limbus-based closed vitrectomy and membrane dissection were performed in 10 eyes (9 patients) with stage 5 retinopathy of prematurity–related tractional retinal detachment and pupillary adhesion. After synechiolysis, an iris speculum was positioned to enlarge the pupil for surgical visualization and maintain a neutral iris plane. The retrolental membrane was dissected bimanually and circumferentially along the peripheral trough and then toward the central retina with vertical scissors and end-gripping forceps.

**Results:** In all 10 eyes, retrolental membranes were entirely removed and troughs were circumferentially unraveled. Follow-up examinations performed 6 to 18 months postoperatively showed reattachment of the retina in 3 eyes with an open-narrow funnel and 6 of 7 eyes with a narrow-narrow funnel. A near-circular pupil without recurrent pupillary adhesion was preserved in all nine eyes showing retinal reattachment.

**Conclusion:** This use of the iris speculum effectively exposes the surgical field for the entire removal of retrolental tissue and interruption of the peripheral trough in stage 5 retinopathy of prematurity–related tractional retinal detachment complicated with pupillary adhesion. The pupil's configuration is well preserved postoperatively.

RETINA 43:138–143, 2023

In stage 5 retinopathy of prematurity (ROP), tractional components at the fibrovascular ridge contract circumferentially and detach the retina anteriorly, folding the peripheral avascular retina into a ridge-to-ora serrata trough.<sup>1–4</sup> In more severe cases, a pupil-traversing retrolental membrane seals the trough and firmly adheres to the periphery of the anteriorly detached retina behind the lens.<sup>5,6</sup> A limbal-based closed vitrectomy

provides access to the retrolental membrane without the risk of subretinal instrumentation entry. Complete dissection of the retrolental membrane from periphery to center can simultaneously interrupt the peripheral trough and release epiretinal traction, which may maximally facilitate retinal reattachment.<sup>2,5,7,8</sup> However, excessive inflammation and contractile retrolental tissue induce inadequate mydriasis, pupillary adhesion, and bulging of the iris–lens diaphragm.<sup>2,5,6</sup> With poor pupillary visualization and restricted retrolental space, technical difficulties prevent satisfactory delamination of extensive adhesion in the peripheral trough during a closed vitrectomy.<sup>2,9,10</sup> Extensive or sectional iridectomy combined with iris hooks was routinely performed to maximize the size of the pupil and to prevent postoperative reepithelialization along the posterior iris surface.<sup>2,5,8,11</sup> However, aggressive management of the iris leads to intensive inflammation and a permanently oversized pupil, which undermines anatomical improvement and patients' cosmetic appearance.

From the Department of Ophthalmology, Xinhua Hospital, School of Medicine, Shanghai Jiao Tong University, Shanghai, China.

The study was funded by the National Natural Science Foundation Project of China (81800837 to J. Lyu, 81770964 to P. Zhao).

None of the authors has any conflicting interests to disclose.

Supplemental digital content is available for this article. Direct URL citations appear in the printed text and are provided in the HTML and PDF versions of this article on the journal's Web site ([www.retinajournal.com](http://www.retinajournal.com)).

This is an open-access article distributed under the terms of the Creative Commons Attribution-Non Commercial-No Derivatives License 4.0 (CCBY-NC-ND), where it is permissible to download and share the work provided it is properly cited. The work cannot be changed in any way or used commercially without permission from the journal.

Reprint requests: Peiquan Zhao, 1665 Kong Jiang Road, Shanghai 200092, China; e-mail: [zhaopeiquan@xinhumed.com.cn](mailto:zhaopeiquan@xinhumed.com.cn).

The Xpand NT iris speculum (Diamatrix Ltd, Woodlands, TX) was previously used for pupillary expansion and iris stabilization during cataract surgery.<sup>12</sup> It is a delicate 6.75-mm ring with eight arches.<sup>12</sup> Here, we describe an innovative use of the device to assist in membrane dissection along the peripheral trough in limbal-based closed vitrectomy for stage 5 ROP complicated with pupillary adhesion. The device effectively improves surgical visualization during along-the-trough retrolental membrane dissection and preserves pupillary configuration.

## Methods

### *Techniques*

(Figure 1; see **Video, Supplemental Digital Content 1**, <http://links.lww.com/IAE/B168>).

Closed vitrectomy and retrolental membrane dissection were performed via a limbus approach. Pupillary adhesion to the endothelium and/or posterior synechiae was delaminated with viscoelastic. Limited iridectomy was performed by inserting a 23-G vitreous cutter into the pupillary margin (0.5 mm) to address any contractile fibrosis. A 20-G anterior chamber infusion line was created via the temporal limbal entry. After synechiolysis, 23-G lensectomy was performed in phakic eyes.

The anterior chamber and the retroiris space were inflated with viscoelastic. The X-pand NT iris speculum was mounted in an injector which was then inserted via a superior 3.0-mm corneal incision into the anterior chamber. The iris speculum was slowly advanced from the injector tube with its distal arch placed at the inferior pupillary rim, followed by positioning of the lateral arches and the proximal arch on the superior pupillary rim. A specific manipulator was used to help position the arches, if indicated. Narrow arches were oriented upward to clear a pathway for instrument insertion. Downward-facing wide arches anchored the posterior iris surface to provide space for retrolental dissection. The pupil was expanded to achieve an octagonal shape, and the iris plane was stabilized at a neutral position. The peripheral membrane over the trough proximal to the ciliary process was exposed, with the globe rotated in the intended direction.

Circumferential bimanual membrane dissection proceeded toward the anterior retina with 20-G end-gripping forceps (TITAN; Titan Surgical LLC, Kazan, Russia) in one limbal entry lifting the membrane over the peripheral trough and 20-G vertical scissors (TITAN) at the opposite entry site for incision and along-the-trough dissection, within the retrolental

space spared by the iris speculum. An invisible trough overlying an opaque and pupil-traversing membrane was explored from the edge of the membrane, proximal to the ciliary process. The blades of vertical scissors were slid into the trough, parallel to the underlying retina plateau, toward the gently lifted membrane in the space beneath the iris speculum. Then, the retrolental membrane was circumferentially delaminated to the center and entirely resected. Epiretinal fibrosis and condensed vitreous sheets were then trimmed. The vitreous cavity and anterior chamber were filled with viscoelastic to expand the retinal funnel and maintain intraocular pressure. The iris speculum was positioned on the iris surface with a manipulator and taken out from the anterior chamber with the injector. Limbal incisions were sutured with 10-0 nylon.

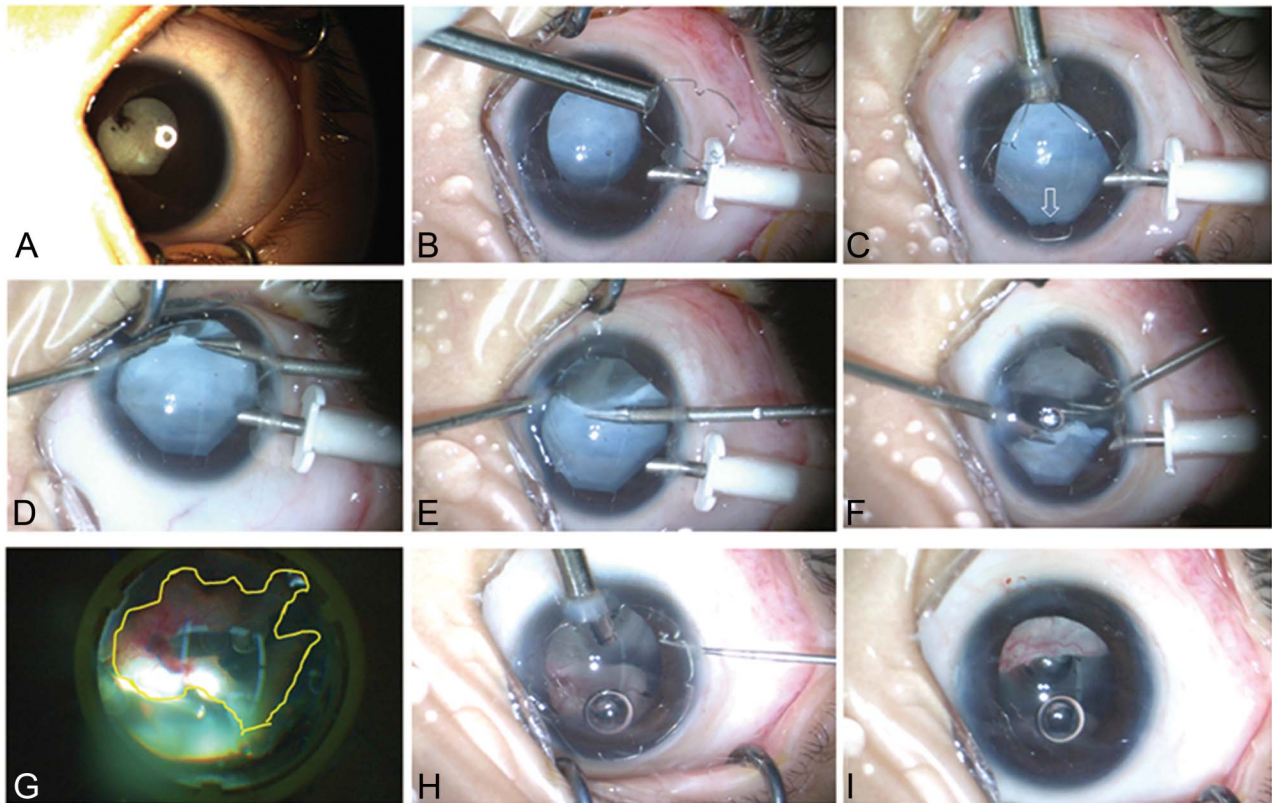
## Results

Ten eyes from 9 preterm infants with stage 5 ROP and pupillary adhesion underwent limbus-based closed vitrectomy and retrolental membrane dissection between October 2017 and October 2018 (Table 1). The iris speculum was manipulated smoothly in all eyes without causing iridodialysis or a sphincter tear. The median duration of surgery was 41 minutes. Pupillary expansion and the iris plane were stable, without dislocation or movement of the iris speculum. Retrolental membrane dissection along the trough was performed uneventfully in all eyes.

After 6 to 18 months of follow-up, 9 of 10 eyes showed partial retinal reattachment; 4 eyes had partial attachment of posterior pole, and 3 eyes had a flat posterior pole and macula. As for postoperative pupil configuration, 9 eyes with retinal reattachment had circular pupils without adhesion (Figure 2). In one eye with narrow–narrow tractional retinal detachment, the funnel of detached retina had expanded. The eye had a pupil deformation superiorly. Anterior chamber depth was normal in all eyes. Improved corneal transparency was observed in all two eyes with pre-existing corneal opacity. The visual testing available for these five infants demonstrated visual perception.

## Discussion

Previously, periphery-to-center membrane dissection during “open-sky” vitrectomy was believed to sufficiently remove anterior fibrovascular proliferation for the repair of stage 5 ROP.<sup>7,8</sup> In a closed vitrectomy, satisfactory separation of the peripheral trough adhesion demands sufficient exposure of the surgical



**Fig. 1.** Use of iris speculum in limbal-based closed vitrectomy and along-the-trough dissection of retrolental membrane in the left eye of patient 9 with stage 5 ROP and a funnel-shaped TRD. **A.** The eye showed posterior synechiae and a shallow anterior chamber. **B.** After synechiolysis and lensectomy, the X-paned NT iris speculum was folded into the injector tube. **C.** The anterior chamber was inflated with viscoelastic. The iris speculum was advanced into the anterior chamber from the injector via a superior 3.0-mm corneal incision. The iris speculum was placed on the pupillary rim with narrow arches upward. The pupil was enlarged, and the iris plane was stabilized to a neutral position. The retrolental membrane proximal to the ciliary process was exposed (hollow arrow). **D.** The trough was obscured underlying the retrolental membrane. An opening cut was selected at the edge of retrolental membrane proximal to the ciliary process. **E** and **F.** Bimanual dissection along the trough was performed circumferentially by 20 G end-gripping forceps in one hand and 20-G vertical scissors in the other hand. Firm adhesion on ridge was also removed. Exposure of the surgical field beneath the pupil and in the trough was maximized. **G.** The trough (anterior to the yellow line) was separated, and forces on retina were maximally released. **H.** The speculum was positioned on the iris speculum and then taken out by the injector. **I.** At the end of the surgery, the retinal funnel was unraveled, and pupil configuration was preserved. ROP, retinopathy of prematurity; TDR, tractional retinal detachment.

field for meticulous exploration of the epiretinal space proximal to the ciliary process.<sup>2,9,10</sup> Extensive iridectomy to manage pupillary adhesion and widen surgical visualization is invasive when performed in pediatric eyes. Iris hooks pinch out a square-shaped pupil, which is suboptimal for peripheral visualization and traumatic to the iris.<sup>13</sup> In addition, multiple external shafts of iris hooks clutter the surgical field and interfere with instrumentation.

The X-paned NT iris speculum is fashioned with a memory nitinol wire. It possesses good elasticity and resistance for stable pupil expansion and nice flexibility for gentle manipulation in fragile pediatric eyes. Its eight arches evenly enlarge the pupillary rim to a wide, near-circular shape.<sup>12</sup> For stage 5 ROP with pupillary adhesion, meticulous synechiolysis and use of the iris speculum sufficiently expose the circumferential surgical field proximal to the ciliary process during membrane dissection via limbal closed vitrectomy. In the

cases described previously, in contrast to routine usage, the narrow arches of the iris speculum were placed upward. This important modification was tailored for limbal closed vitrectomy to reduce the chances of interference with the instrument's entry. A Malyugin ring (MicroSurgical Technology, Redmond, WA), a polypropylene pupil expansion ring, allows for the standardization of pupil expansion in cataract and vitreoretinal surgery. The limitations of this tool include increased risk of ring deformation, fracture, and dislocation during manipulation (because of its soft nature).<sup>14</sup>

Furthermore, use of the X-paned NT iris speculum stabilizes the iris plane to ease trough membrane dissection. After the separation of pupillary adhesions, the iris, free of strain, readily prolapses or becomes caught during instrument entry and manipulation. The resulting lack of lens support often gives rise to iris retropulsion during membrane dissection. In the

Table 1. Surgical Outcomes of Patients With Stage 5 ROP-Related TRD and Inadequate Mydriasis

Pt	Gender	GA, week	BW, g	Eye	Preoperative				Previous Treatment
					TRD*	Trough	Pupil	Other Features	
1	Girl	28	1,005	OD	A/A	Wide, shallow	Secluded pupil	Corneal leukocoria, phakia, flat anterior chamber	/
2	Girl	31	1,600	OD	A/A	Wide, deep	Secluded pupil	Corneal leukocoria, white cataract, flat anterior chamber	IVR
3	Boy	30	1,250	OS	A/A	Wide, deep	Secluded pupil	Phakia, flat anterior chamber	/
4	Girl	29	1,450	OS	O/A	Narrow, shallow	Posterior synechia	Phakia	Laser
5	Boy	29	1,250	OS	A/A	Wide, shallow	Posterior synechia	Phakia, flat anterior chamber	/
6	Boy	28	1,200	OS	A/A	Wide, deep	Posterior synechia	Phakia, flat anterior chamber	/
7	Boy	25	560	OD	O/A	Wide, shallow	Posterior synechia	Aphakia due to a prior closed vitrectomy	Laser, V/L
				OS	O/A	Wide, shallow	Posterior synechia	Aphakia due to a prior closed vitrectomy	Laser, V/L
8	Boy	29	1,000	OD	A/A	Wide, deep	Posterior synechia	Phakia, shallow anterior chamber	/
9	Boy	27	870	OS	A/A	Wide, deep	Posterior synechia	Phakia	/

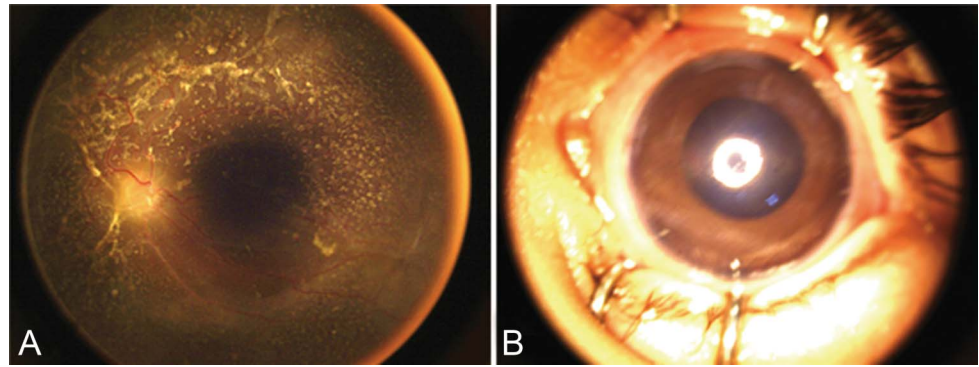
  

Pt	Peroperative			Postoperative			
	Adjusted Age at Surgery, Month	Surgery	Time of Surgery, minutes	Fundus	Pupil	Vision	Follow-up, Month
1	5	V/L/M	30	Expanded	Deformation	NA	14
2	22	V/L/M	40	Partially attached posterior pole	Circular	LP	15
3	12	V/L/M	37	Partially attached	Circular	LP	18
4	5	V/L/M	42	Partially attached posterior pole	Circular	LP	8
5	7	V/L/M	48	Partially attached posterior pole	Circular	FF	6
6	6	V/L/M	41	Attached macular and posterior pole	Circular	NA	6
7	8	V/M	45	Partially attached	Circular	NA	6
	9	V/M	37	Partially attached posterior pole	Circular	NA	6
8	9	V/L/M	49	Attached macular and posterior pole	Circular	FF	6
9	10	V/L/M	45	Attached macular and posterior pole	Circular	NA	6

\*The anterior and posterior configuration of the funnel-shaped retinal detachment was also based on the International Classification of ROP.<sup>4</sup>

A/A, narrow/narrow; CF, counting fingers; FF, fix and follow; GA, gestational age; IVR, intravitreal injection of ranibizumab; L, lensectomy; LP, light perception; M, membrane peeling; NA, not available; O/A, open/narrow; ROP, retinopathy of prematurity; TRD, tractional retinal detachment; V, vitrectomy.

**Fig. 2.** Postoperative examinations on 3 months with RetCam imaging. **A.** Posterior retina attachment. **B.** A round pupil without posterior synechiae.



current series, the iris speculum tightly cradled the pupillary rim and maintained the iris plane in a neutral position. The approach creates a surgical pathway extending from the anterior chamber to the retrolental space. In situ membrane dissection along the trough is feasible beneath the pupillary rim and does not require central lifting of the peripheral membrane for dissection. Notably, excessive traction on the peripheral avascular retina frequently leads to retinal dialysis or tear.<sup>7</sup> Iatrogenic retinal breaks are not rare, especially when outside-in dissection is performed in a relatively shallow and narrow trough.<sup>8</sup> We therefore used angled vertical scissors to circumferentially slide along the trough, rather than using blade-forward curved scissors, which are suboptimal for creating a safe and large cut along the trough. Use of the current method in combination with closed vitrectomy allows for sufficient removal of anterior fibrotic vectors and thus encourages retinal reattachment, prevents the recurrence of posterior synechiae, and preserves the circular configuration of the pupil.

Issues pertaining to the technique require attention. If the iris speculum cannot be entirely folded into the injector tube for insertion and removal, manipulation aided by microforceps or vitreoretinal forceps is feasible. The peripheral trough can also be explored after radial expansion of the central membrane through creation of a cut that extends to the periphery, although the risk of penetrating centrally detached retina increases. This technique was not used to address “crunching” retinal detachment in patients with aggressive posterior ROP after the use of anti-vascular endothelial growth factor drugs.<sup>15</sup> We did not use 25- or 27-G instruments because they may not adequately address firm adhesions and robust tissue.

In conclusion, the use of an iris speculum optimizes retrolental membrane dissection in closed vitrectomy for stage 5 ROP-related tractional retinal detachment complicated with pupillary adhesion. This surgical method allows for dissection of the entire peripheral trough and retrolental membrane, which sufficiently

releases tractional vectors. This technique maximally preserves the configuration of the pupil and prevents the recurrence of posterior synechiae.

**Key words:** pupil expander, membrane, retinopathy of prematurity, vitrectomy.

JIAO LYU, PhD, MD  
 QI ZHANG, MD  
 PEIQUAN ZHAO, PhD, MD

## References

1. Repka MX, Tung B, Good WV, et al. Outcome of eyes developing retinal detachment during the Early Treatment for Retinopathy of Prematurity study. *Arch Ophthalmol* 2011;129:1175–1179.
2. Trese MT. Surgical results of stage V retrolental fibroplasia and timing of surgical repair. *Ophthalmology* 1984;91:461–466.
3. Palmer EA, Flynn JT, Hardy RJ, et al. Incidence and early course of retinopathy of prematurity. *Ophthalmology* 1991;98:1628–1640.
4. International Committee for the Classification of Retinopathy of Prematurity. The international classification of retinopathy of prematurity revisited. *Arch Ophthalmol* 2005;123:991–999.
5. Chong LP, Machemer R, de Juan E. Vitrectomy for advanced stages of retinopathy of prematurity. *Am J Ophthalmol* 1986;102:710–716.
6. Fuchino Y, Hayashi H, Kono T, Ohshima K. Long-term follow-up of visual acuity in eyes with stage 5 retinopathy of prematurity after closed vitrectomy. *Am J Ophthalmol* 1995;120:308–316.
7. Hirose T, Schepens CL, Katsumi O, Mehta MC. Open-sky vitrectomy for severe retinal detachment caused by advanced retinopathy of prematurity. In: Flynn JT, Flynn TW, eds. *Retinopathy of Prematurity A Clinician’s Guide*. New York, NY: Springer-Verlag, Inc; 1992:95–114.
8. Tasman W, Borrone RN, Bolling J. Open sky vitrectomy for total retinal detachment in retinopathy of prematurity. *Ophthalmology* 1987;94:449–452.
9. Wong SC, Capone A Jr. Illumination techniques for complex pediatric anterior retinal detachment and associated retrolental plaque. *Retina* 2015;35:1905–1907.
10. Shah PK, Narendran V, Kalpana N, Tawansy KA. Anatomical and visual outcome of stages 4 and 5 retinopathy of prematurity. *Eye (Lond)* 2009;23:176–180.

11. Gopal L, Sharma T, Shanmugam M, et al. Surgery for stage 5 retinopathy of prematurity: the learning curve and evolving technique. *Indian J Ophthalmol* 2000;48:101–106.
12. Malyugin BE. Recent advances in small pupil cataract surgery. *Curr Opin Ophthalmol* 2018;29:40–47.
13. Akman A, Yilmaz G, Oto S, Akova YA. Comparison of various pupil dilatation methods for phacoemulsification in eyes with a small pupil secondary to pseudoexfoliation. *Ophthalmology* 2004;111:1693–1698.
14. Patel CK. The Malyugin pupil expander in vitreoretinal surgery. *Retina* 2010;30:357–363.
15. Yonekawa Y, Wu WC, Nitulescu CE, et al. Progressive retinal detachment in infants with retinopathy of prematurity treated with intravitreal bevacizumab or ranibizumab. *Retina* 2018;38:1079–1083.