



ELSEVIER

Contents lists available at ScienceDirect

International Journal of Surgery Case Reports

journal homepage: www.casereports.com

Myositis ossificans: A rare location in the foot. Report of a case and review of literature



Qays Ahmed Hassan Al-Timimy (M.B.CH.B., D.M.R.D., C.A.B.M.S. (RAD))^{a,*},
Mohammed Shehab Al-Edani (M.B.CH.B., F.I.C.M.S.)^b

^a Section of Radiology, Department of Surgery, Al-kindy College of Medicine, University of Baghdad, Baghdad, Iraq

^b Section of Orthopedics, Department of Surgery, Al-kindy College of Medicine, University of Baghdad, Baghdad, Iraq

ARTICLE INFO

Article history:

Received 3 June 2016

Received in revised form 23 June 2016

Accepted 9 July 2016

Available online 14 July 2016

Keywords:

Case report

Foot

Myositis ossificans

Heterotopic ossification

Soft tissue calcification

SUMMARY

BACKGROUND: Myositis ossificans is a benign, tumor-like lesion characterized by heterotopic ossification of soft tissue that usually affects the elbow and thigh. At different stages of maturity, it shows similar histologic appearances with sarcomatous lesions or maturing bone. Misdiagnosis can result in unnecessary radical treatment.

CASE REPORT: A 50-year-old woman with dorsal forefoot soft tissue mass was diagnosed as myositis ossificans after surgical excision and confirmed by a histopathological examination.

DISCUSSION: To our knowledge, myositis ossificans occurrence in the foot is rare and only a few cases have been reported in the literature.

SUMMARY: Increasing awareness on the unusual sites for myositis ossificans occurrence is necessary for differentiating this lesion from a malignant soft-tissue tumors and avoiding diagnostic pitfalls and unnecessary investigations, which can have major consequences and complications for patients.

© 2016 The Authors. Published by Elsevier Ltd on behalf of IJS Publishing Group Ltd. This is an open access article under the CC BY-NC-ND license (<http://creativecommons.org/licenses/by-nc-nd/4.0/>).

1. Introduction

Myositis ossificans (MO), otherwise known as heterotopic ossification, is a non-neoplastic, localized tumor-like lesion of new true bone formation that affects the muscles, ligaments, and fascia. Most cases of MO occur as a result of trauma, and thus the main demographics are adolescents and young adults [1,2]. The anterior muscle groups of the thighs and arms are more frequently affected as these sites are subjected to high-risk injuries [1,3]. Despite its being a clinically and histologically distinct entity, diagnosis may be very difficult, especially when it is presented in an uncommon location. MO can be confused with malignant lesions, such as osteosarcoma and soft-tissue sarcoma. Appropriate imaging is crucial for excluding infections or malignancies. Computed tomography generally is the imaging tool of choice in difficult cases and for planning for surgical resection.

In this article, we present a rare case of a MO lesion located in the dorsal forefoot soft tissue. In addition, we review the imaging and histopathological features of the MO lesion that are useful for differential diagnosis.

2. Case report

A 50-year-old woman was referred to our hospital because of a 6-month history of a mass in the right forefoot region. The patient described a minor trauma with hard object to the mass region from the medial side and subsequently, she noticed a painful and enlarging lesion on the medial aspect of her dorsal forefoot, which became firm and gradually less painful. The patient's significant medical history was negative and she specifically denied any weight loss, malaise, anorexia, fever, or chills. On examination she had a firm 2-cm lump that was well demarcated and palpable. Minimal local tenderness were noted. Her great toe movements were slightly restricted with pain. Her laboratory findings, including white blood cell count, erythrocyte sedimentation rate and C-reactive protein level, were normal.

Radiographs of the foot was unremarkable and there was no suspicion of a bone lesion or periosteal reaction. Contrast-enhanced computed tomography (CT) of the foot (Fig. 1) demonstrated dystrophic appearing subcutaneous calcifications scattered throughout the outlines of a well defined 18 × 9 mm non-enhancing soft tissue mass-like lesion just anterior to the head of the first metatarsal bone and metatarsal phalangeal joint without osseous involvement. A primary diagnosis of MO was made based on the clinical history and imaging findings and after a discussion

* Corresponding author.

E-mail address: qtimeme@yahoo.com (Q.A. Hassan Al-Timimy).

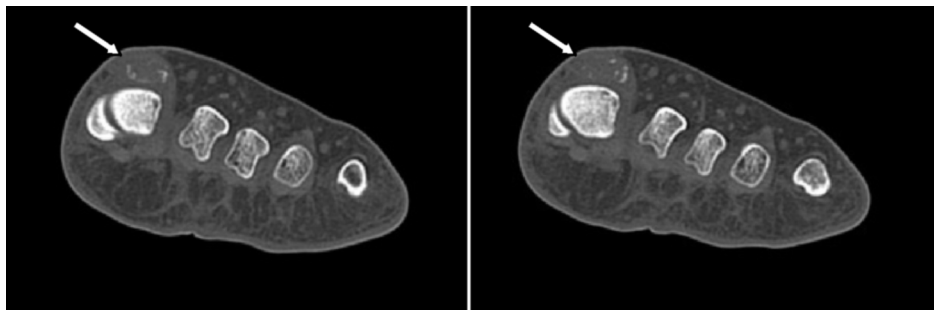


Fig. 1. Axial contrast-enhanced CT scan images of foot show dystrophic appearing subcutaneous calcifications scattered throughout the outlines of a well defined non-enhancing soft tissue mass-like lesion (arrows) just anterior to the head of the first metatarsal bone and metatarsal phalangeal joint with normal underlying bony structures.

with the patient and her family, the patient was referred to surgical excision for a definitive diagnosis.

After 6 days, surgical excision was performed as planned and under general anaesthesia, the lesion was exposed after a careful dissection at the dorsal surface of medial side of forefoot and proximal phalynx of the great toe and was excised with 1 cm of tumor-free margins after careful separation from the extensor hallucis longus tendon. The resected specimen was well circumscribed, totally separated from the extensor hallucis longus tendon sheath and showed a distinct zonal pattern of myositis ossificans (Fig. 2a). The histopathological study reflected morphologic changes compatible with MO. No malignant signs were observed in the sample. The definitive histopathological analysis described a central zone of immature fibroblastic spindle cells intersecting a myxochondroid stroma and the periphery comprised calcification and mature lamellar bone compatible with MO (Fig. 2b). The edges of the sample were tumor free.

The surgical wound healed in 2 weeks without complications and the patient recovered without incident. At the 2-months follow-up examination, the patient was asymptomatic and exhibited normal function and a full range of motion of all digits of the foot, particularly great toe flexion and extension.

3. Discussion

Myositis ossificans (MO) is a localized, self-limiting, extraskeletal formation of heterotopic bone and cartilage in soft tissues that usually occur after trauma in 60% to 75% of all cases (as in our case) and therefore called in sometimes myositis ossificans traumatica (MOT) [4]. The most agreed etiologic mechanism includes an osteoblast stimulation as a consequence of a bone or soft tissue damage causing a formation of new bone, dystrophic calcifications or calcified chondroid matrix. However, in approximately 25% of cases, there is no apparent history of preceding trauma, and in some of these cases, an infectious process has been implicated to be a possible cause or the initiating factor. Other provocative causes include burns, neuromuscular disorders and hemophilia.

MOT usually appears in adolescents or young adults. The majority of the patients are male. The lesions are predominately involves the high-risk sites of injury in about 80% of cases, such as thigh, elbow and buttocks [5]. The most commonly affected sites in the lower extremity are the quadriceps femoris and gluteus muscles, and those in the upper extremity are the brachialis muscle [4]. However, involvement of the foot is rare, and only a few cases have been reported to current date. Allard et al. [6] reported a rare case of plantar forefoot MO while De Maeseneer et al. [7] reported a rare case of MO located inferior to the second and third metatarsal bones in 37 years old woman.

Early in the disease, the lesion is soft and painful, and within a few weeks a firm and often painful mass develops in the affected muscles. This lesion matures over 6–12 months, and eventually ossifies and becomes painless [4]. The lesion may cause limitation in the range of movements according to its site and size. In this case, toe movements were slightly restricted especially the flexion and extension while other fingers show reserved full range of movements.

The microscopic histological findings vary according to the age of the lesion and are mirrored by radiographic findings. Early in the disease course, the lesion is mostly cellular with fibroblastic tissue resembling a granulation tissue, and radiographs are often negative. As the area of ossification expands, radiographs demonstrate flocculent radiodensities or calcifications. As the lesion matures, it completely ossifies. The most pivotal diagnostic feature of MO is that the bone maturity occurs from the periphery in a zonal manner with a fibroblastic center, whereas the central part presents with loose spindle cells with no cytological atypia [8,9]. However, in sometimes as in our case, the radiograph cannot detect the mineralization of MO. Ultrasonography has limited role in early diagnosis of MO, mature lesions have the echogenicity and dense shadowing of cortical bone. However, ultrasonography is an operator-dependent examination, and no data are available on the value of ultrasonography in the diagnosis of MO in the foot [10]. Magnetic resonance imaging (MRI) is not routinely used for the evaluation of MO. Typical MRI findings include a low-signal-intensity rim and a heterogeneous, high-signal-intensity and tumor-like enlargement of affected tissues. Intravenous gadolinium administration results in early, intense, heterogeneous enhancement of the lesions [10]. CT is the preferred imaging modality to demonstrate the zonal pattern in posttraumatic MO [11]. It optimally identifies the typical patterns of this disease, including the separation of the mass from the adjacent cortex and the decreased attenuation of the center of the mass.

The term myositis ossificans is inconsistent because the inflammation is absent and, if present, it is usually minimal and the muscle may not be involved. Hence, the term heterotopic ossification is more agreeable.

When MO occurs in its common locations and/or if a clear clinical history and findings are obtained, the diagnosis is straightforward. However, the differential diagnosis may be problematic in patients with a lesion that lacks the characteristic zoning phenomenon and grows in an irregular multifocal or multilobulated form [4]. In our patient, the rare location of the lesion necessitated histopathological assessment to distinguish the lesion from extraskeletal osteosarcoma.

There are many differential diagnosis for skeletal and soft tissue tumors that originate in the foot and share similar presentation with MO including periosteal and parosteal osteosarcoma, synovial

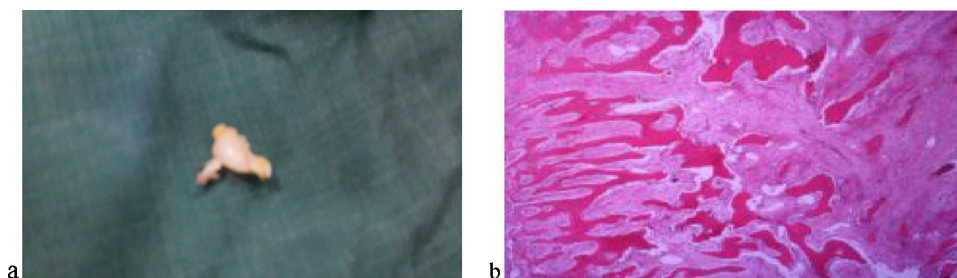


Fig. 2. a) Macroscopic image of the surgical specimen that consisted of one tissue fragment measuring $2.3 \times 1.6 \times 1.5$ cm. b) Histopathological examination showing a central zone of immature fibroblastic spindle cells intersecting a myxochondroid stroma and the periphery comprised calcification and mature lamellar bone.

sarcoma, periosteal chondroma, osteomyelitis, giant cell tumors of tendon sheath and vascular tumors. Other non-neoplastic soft tissue processes with bone formation such as pseudomalignant osseous tumor of soft tissues, florid reactive periostitis, and bizarre parosteal osteochondromatous proliferation occur more commonly in the foot than myositis ossificans. Presenting features of malignant tumors that arise in the foot are similar to those of benign lesions, including palpable mass, swelling, increased warmth, limp and pain; and many of patients reports history of trauma [12]. In contrast to MO, osteosarcoma presents a more disorganized growth of hyperchromatic and pleomorphic cells with osteoid formation. Additionally, the greater degree of cellular atypism and infiltration of adjacent tissues in a destructive fashion are highly indicative of this lesion. Although mitotic figures are present in immature MO and osteosarcoma lesions, clearly atypical or tripolar forms guide toward malignancy [4]. Furthermore, unless adequate biopsy material is obtained, including the central and peripheral components of the lesion, histological differentiation may also be difficult.

The histological features of our case included a lobulated, well demarcated and partially encapsulated lesion with peripheral calcification and mature cartilaginous tissue. There was a central zone made of a cellular proliferation with mesenchymal features. Nor cytological atypia neither mitosis were seen in the lesion.

Early in the disease course, rest, ice, compression, and elevation are universally recommended [1]. MO is a reactive self limiting condition, can spontaneously resolve and there is no compelling evidence that malignant degeneration ever occurs [2]. Surgery may be necessary in cases of considerable decreases in the range of motion, muscle atrophy, unremitting pain, and deterioration of function after 6–12 months of unsuccessful conservative care [13]. Excision is only indicated if the lesion is completely ossified because removal of immature bone may cause extensive local recurrence. Some studies suggest that using prophylactic indomethacin and etidronate can be beneficial in reducing postsurgical ectopic calcification [1].

In our patient, we decided to perform surgery as the lesion was located in an unusual site. Intra-operatively, we found that the MO occupied a limited space just above the extensor hallucis longus tendon. The patient's post-operative course was nevertheless uneventful, and no functional deficit was apparent.

In summary we report a rare case of a 50-year-old woman with MO in the dorsal forefoot. The history of antecedent trauma and computed tomography findings allowed preoperative accurate diagnosis. Because of the rare location of the lesion, surgical excision and a histopathological examination was necessary to establish the diagnosis. Pathology reports confirmed the MO diagnosis. The patient recovered without complications. Increasing awareness on the unusual sites for MO occurrence is necessary for differentiating a MO lesion from a malignant soft-tissue tumors and

avoiding diagnostic pitfalls and unnecessary investigations, which can have major consequences and complications for patients.

Conflict of interest

The authors declare that they have no conflict of interest.

Funding

None.

Ethical approval

Not requested as the study not involved the patient.

Consent

Informed consent was obtained from the patient for publication of this case report and any accompanying images.

Author contribution

As a 1st author and corresponding author, Qays A. Hassan contribute to case report writing, data collection and discussion writing. Mohammed Al-edani performed surgery. Both authors reviewed critically the manuscript for important intellectual content.

Guarantor

The Guarantor is Qays A. Hassan.

References

- [1] J.F. Sodl, R. Bassora, G.R. Huffman, et al., Traumatic myositis ossificans as a result of college fraternity hazing, *Clin. Orthop. Relat. Res.* 466 (2008) 225–230.
- [2] G. Kluger, A. Kochs, H. Holthausen, Heterotopic ossification in childhood and adolescence, *J. Child Neurol.* 15 (June) (2000) 406–413.
- [3] J.M. Beiner, P. Jokl, Muscle contusion injury and myositis ossificans traumatica, *Clin. Orthop. Relat. Res.* (2002) S110–S119.
- [4] S.W. Weiss, J.R. Goldblum, *Osseous Soft Tissue Tumors*, 4, Mosby, St Louis, MO, 2001, pp. 1389–1405.
- [5] L.E. Almeida, A. Doetzer, F. Camejo, J. Bosio, Operative management of idiopathic myositis ossificans of lateral pterigoid muscle, *Int. J. Surg. Case Rep.* 5 (2014) 796–799.
- [6] M.M. Allard, R.L. Thomas, R.W. Nicholas Jr., Myositis ossificans: an unusual presentation in the foot, *Foot Ankle Int.* 18 (1997) 39–42.
- [7] M. De Maeseneer, S. Jaovisidha, L. Lenchik, et al., Myositis ossificans of the foot, *J. Foot Ankle Surg.* 36 (1997) 290–293.
- [8] L.W. Bancroft, C. Pettis, C. Wasyliv, Imaging of benign soft tissue tumors, *Semin. Musculoskel. Radiol.* 17 (2013) 156–167.
- [9] E. Luczynska, H. Kasperkiewicz, A. Domalik, et al., Myositis ossificans mimicking sarcoma, the importance of diagnostic imaging—case report, *Pol. J. Radiol.* 79 (2014) 228–232.

- [10] F. Andreas, M. Mavrogenis, N. Panayotis, et al., Heterotopic ossification revisited, *Orthopedics* 34 (2011) 177.
- [11] A.E. Rosenberg, Pseudosarcomas of soft tissue, *Arch. Pathol. Lab. Med.* 132 (2008) 579–586.
- [12] P.J. Papagelopoulos, A.F. Mavrogenis, A. Badekas, F.H. Sim, Foot malignancies: a multidisciplinary approach, *Foot Ankle Clin.* 8 (2003) 751–763.
- [13] E. Estrada-Villasenor, E.D. Cedillo, G.R. Martinez, Scrape cytology of myositis ossificans: report of a case and analysis of the cytologic findings described previously, *Diagn. Cytopathol.* 36 (2008) 50–53.

Open Access

This article is published Open Access at scimedirect.com. It is distributed under the [IJSCR Supplemental terms and conditions](#), which permits unrestricted non commercial use, distribution, and reproduction in any medium, provided the original authors and source are credited.