



CrossMark

## Unusual Cause of Dysphagia

Shahram Agah <sup>1</sup>, Ramak Ghavam <sup>1</sup>, Ahmad Darvishi Zeidabadi <sup>1</sup>, Arash Sarveazad <sup>1\*</sup>

1. Colorectal Research Center, Iran University of Medical Sciences, Tehran, Iran.

Please cite this paper as:

Agah S, Ghavam R, Darvishi Zeidabadi A, Sarveazad A. Unusual Cause of Dysphagia. *Middle East J Dig Dis* 2017;9:58-59. DOI: 10.15171/mejdd.2016.53

A 54-year-old man was referred to our center with complaint of dysphagia since 1 year ago. Before admission to our center, esophagogastroduodenoscopy (EGD) had been done by general internist, which was reported normal. The patient had mentioned discomfort with solid and liquid diets. He suffered from cough and sometimes nausea during swallowing. Nasal regurgitation was not reported. Because of such complaints, thorough gastrointestinal and pulmonary investigations were performed and eventually he was discharged with medical treatment.

The patient's dysphagia exacerbated over the last month, so more investigations were done. No weight loss was detected. Drug history revealed consumption of amiodarone and captopril for longstanding hypertension. Medical history showed surgery of cervical vertebrae due to car accident and fixation of fracture by cervical plate 10 years earlier. After surgery, the patient had developed abscess formation, therefore another surgery for drainage of abscess collection had been done.

Physical examination was otherwise normal, except the scar at the site of previous surgery. Barium swallow was ordered and the results showed soft tissue widening and dislocation of cervical plate (due to loosening of cervical plate) in prevertebral space. After ingestion of barium, leakage of contrast material from esophagus (around the device) was visible. This confirmed esophageal wall defect and probably infection in prevertebral / retroesophageal space. No evidence of obstruction along the esophagus was seen. Further investigations by cervical computed tomography (CT) with contrast and magnetic resonance imaging (MRI) did not verified abscess collection, although the other findings were compatible with the results of barium swallow. Cervical plate dislocation into prevertebral space and invasion into lumen of esophagus in the distance of 20 cm from incisors were confirmed by endoscopy.

Neurosurgery consultation was done and elective surgery in cooperation with otolaryngologists was scheduled. After the surgery, the patient's symptoms relieved.

Views related to barium swallow, CT, MRI, and endoscopy are attached to this report (figures 1-4).

### What is your diagnosis?

#### Answer:

Cervical Plate Dislocation as an Unusual Cause of Dysphagia

### DISCUSSION

Dysphagia is a significant sign that needs immediate evaluation, to define the etiology and set up proper therapeutic strategy.<sup>1</sup>

The primary step in the evaluation of patients with dysphagia is to identify its type (oropharyngeal or esophageal) by suitable precise history taking.<sup>2</sup> Patients, who suffer from oropharyngeal dysphagia, have trouble in initiation of swallowing and when they are asked to specify its location, they usually point to the cervical area. The other symptoms include dysarthria, sialorrhea, drooling, food spillage, cough, and choking during swallow. In the case of esophageal dysphagia, difficult swallowing is seen just a few seconds after the initiation of swallowing. The patient

#### \* Corresponding Author:

Arash Sarveazad, PhD  
Rasoul Akram Hospital, Niyayesh St, Sattarkhan Ave, Tehran, Iran  
Telefax: + 98 21 66516001  
Email: Arashsarveazad@gmail.com

Received: 03 Sep. 2016

Accepted: 27 Oct. 2016

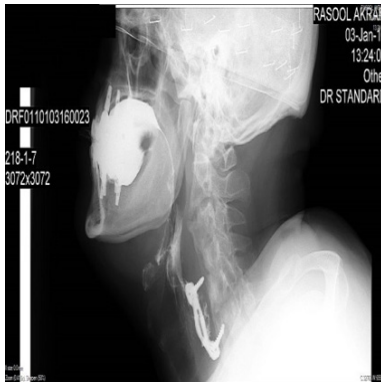

Fig.1: Neck X-ray: Lateral view

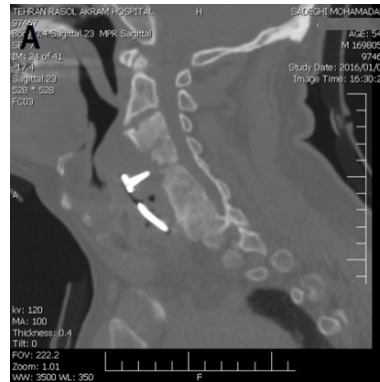

Fig.2: Neck computed tomography (CT): A) Lateral view. B) Transverse (cross sectional) view

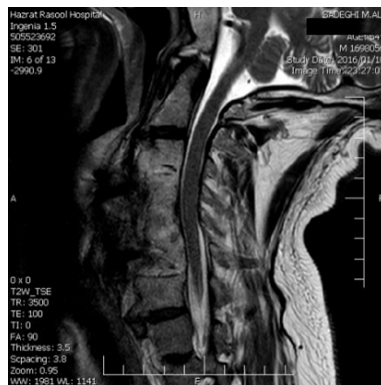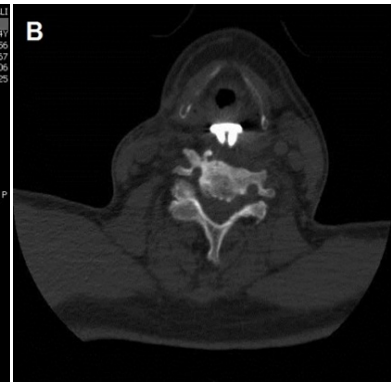


Fig.3: Neck magnetic resonance Imaging (MRI): Lateral view

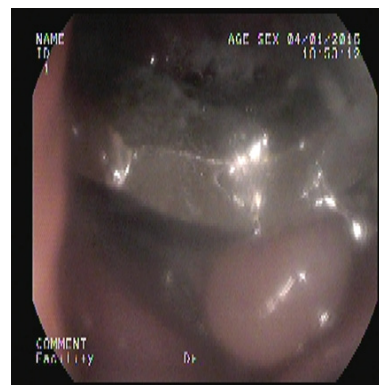


Fig.4: Endoscopic view

describes food sticking sensation in the more upper portion of esophagus, suprasternal notch, or substernal region. Even though, retrosternal dysphagia is usually related to the site of lesion, suprasternal dysphagia is usually referred from lower portion of esophagus.<sup>3</sup>

In the case of esophageal dysphagia, the patients should be referred to a gastroenterologist for an upper endoscopy.<sup>4</sup> Endoscopy provides a chance to take biopsy in order to determine the etiology and carry out therapeutic intervention in case of lesions (such as esophageal ring) that are potentially manageable.

The indications of barium swallow are as follow:

- Patients with suspected proximal esophageal lesion (e.g., Zenker’s diverticulum, history of laryngeal or esophageal cancer or radiation therapy), a known stricture (e.g., prior caustic injury and radiation therapy).<sup>5</sup> In these patients, the risk of perforation following blind endoscopy exists.
- Patients with negative upper endoscopy that shows mechanical obstruction, such as lower esophageal rings or extrinsic esophageal compression, which can be easily missed after an upper endoscopy.<sup>6</sup>

Our case was rare and no similar case was reported pre-

viously, which was diagnosed with upper endoscopy and barium swallow.

REFERENCES

1. Shamburek RD, Farrar JT. Disorders of the digestive system in the elderly. *N Engl J Med* 1990;**322**:438-43. doi: 10.1056/NEJM199002153220705
2. Trate DM, Parkman HP, Fisher RS. Dysphagia. Evaluation, diagnosis, and treatment. *Primary Care* 1996;**23**:417-32. doi: 10.1016/S0095-4543(05)70338-9
3. Wilcox CM, Alexander LN, Clark WS. Localization of an obstructing esophageal lesion. Is the patient accurate? *Dig Dis Sci* 1995;**40**:2192-6. doi:10.1007/BF02209005
4. Varadarajulu S, Eloubeidi MA, Patel RS, Mulcahy HE, Barkun A, Jowell P, et al. The yield and the predictors of esophageal pathology when upper endoscopy is used for the initial evaluation of dysphagia. *Gastrointest Endosc* 2005;**61**:804-8. doi: 10.1016/S0016-5107(05)00297-X
5. Spechler SJ. American gastroenterological association medical position statement on treatment of patients with dysphagia caused by benign disorders of the distal esophagus. *Gastroenterolog.* 1999;**117**:229-33. doi: 10.1016/S0016-5085(99)70572-X
6. Ott DJ. Radiographic techniques and efficacy in evaluating esophageal dysphagia. *Dysphagia* 1990;**5**:192-203. doi:10.1007/BF02412687