



Promising impact of platelet rich plasma and carbon dioxide laser for stress urinary incontinence



Fariba Behnia-Willison^{a,b,c,*}, Tran T.T. Nguyen^{a,b,c}, Aidan J. Norbury^b, Behrang Mohamadi^c, Stefano Salvatore^d, Alan Lam^e

^a Department of Obstetrics & Gynaecology, Flinders Medical Centre, Adelaide, Australia

^b Flinders University, Adelaide, Australia

^c FBW Gynaecology Plus, Adelaide, Australia

^d IRCCS San Raffaele University, Milan, Italy

^e Centre for Advanced Reproductive Endosurgery, Sydney, Australia

ARTICLE INFO

Article history:

Received 26 May 2019

Received in revised form 17 September 2019

Accepted 14 October 2019

Available online 22 October 2019

Keywords:

Stress urinary incontinence
Fractional carbon dioxide laser
Platelet rich plasma
Bladder function
Urinary leakage
Bladder urgency

ABSTRACT

Objectives: To evaluate the safety, feasibility and efficacy of trans-vaginal fractional micro-ablative CO₂ laser therapy in combination with platelet rich plasma (PRP) for the treatment of stress urinary incontinence (SUI) in women.

Study design: Participants with SUI underwent three sessions of transvaginal CO₂ laser and PRP treatment, administered at 4–6-week intervals. Outcomes were assessed using the bladder function section of the Australian Pelvic Floor Questionnaire (APFQ). The primary outcome was changes in the participants' symptoms of SUI. Secondary outcomes were related to general bladder function. Outcome differences from baseline (T1) to 3 months (T2) and 12 months (T3) were analysed using Wilcoxon signed-rank tests. Subjective verbal scales were used to assess the degree of pain associated with PRP injections and laser treatment.

Results: Sixty-two women with SUI were enrolled into this study. There were 66% (41/62) of participants who reported improved SUI symptoms from T1 to T2 ($p < 0.001$) and at T3, 62% (23/37) of patients reported improved SUI symptoms ($p < 0.001$). From T1 to T2, all bladder function variables were improved significantly ($p < 0.002$). At T3, significant improvements ($p < 0.03$) were maintained for all bladder function variables, except pad usage ($p = 0.073$).

Conclusions: Combining transvaginal fractional CO₂ laser with PRP might be a beneficial treatment for SUI. It may have the potential to be a minimally-invasive and low-risk alternative to surgery, with reduced recovery time.

© 2019 The Authors. Published by Elsevier B.V. This is an open access article under the CC BY-NC-ND license (<http://creativecommons.org/licenses/by-nc-nd/4.0/>).

Introduction

Urinary incontinence (UI) has a prevalence of 45% in women [1]. UI can impact on one's social, physical, mental and sexual wellbeing, and lead to depression and social isolation [2,3]. Many women are reluctant to seek medical help due to the associated embarrassment and social stigma [4]. UI is projected to cost \$1.27 billion by 2018 in Australia [5].

Stress urinary incontinence (SUI) refers to the involuntary leakage of urine accompanying physical exertion (i.e.

coughing, exercise, sneezing) [2]. It is commonly acquired after pregnancy and childbirth due to weakening of the pelvic floor muscles that support the urethra against the anterior vaginal wall [2,4]. Current SUI treatment includes surgery to re-establish sufficient urethral resistance in order to prevent urine leakage during increased intra-abdominal pressure [2]. The mid-urethral sling (MUS) has become the preferred procedure, as it is less invasive than the Burch colposuspension [6]. However, the MUS procedure has a 5–20% failure rate and carries risks such as infection, voiding dysfunction, haemorrhaging, pain, bladder/urethral injury, and mesh erosion [7,8]. Internationally, there has been a shift away from transvaginal implants, with the Therapeutic Goods Administration (TGA) in Australia withdrawing their approval for certain transvaginal mesh products [9]. Hence, there is a need for alternative efficacious, outpatient SUI treatments.

* Corresponding author at: Department of Obstetrics & Gynaecology, Flinders Medical Centre, FBW Gynaecology Plus, 46 Marleston Ave, Ashford, South Australia 5035, Australia.

E-mail address: fbw@fbwgynplus.com (F. Behnia-Willison).

Researchers have recently explored transvaginal laser as a less invasive treatment option for SUI [10,11]. By inducing thermal changes to tissues, the laser can instigate an inflammatory healing cascade, resulting in various histological, cytological, metabolic and gene expression changes that can restore and remodel tissues by promoting collagen synthesis and structural remodelling of collagen fibres [12–14]. In SUI patients, the laser applied to vaginal wall may improve pubo-cervical fascial collagen content and structure as well as the mucosal thickness, thus reinforcing urethral/bladder neck support [4,15,16]. Salvatore et al demonstrated that transvaginal laser reduced UI symptoms in women with vaginal atrophy [11]. Furthermore, Ogrinc et al and Gambacciani et al recorded significant improvements in SUI in women treated with Er:YAG non-ablative laser [10,17]. Currently, there are no published larger-scale studies investigating the long-term effects of micro-ablative CO₂ laser treatment for SUI.

Platelet-rich plasma (PRP) can drive cell migration, proliferation, differentiation, angiogenesis and removal of tissue debris, through growth factors and chemical mediators released by platelets. As a result, PRP can assist in tissue repair, healing and regeneration [18–21]. Clinically, PRP has effectively treated burns, skin disorders, lichen sclerosus, problematic wounds and tendonitis [14,18,20,21].

The primary reason for combining PRP with laser is based on the potential synergistic therapeutic effect [21]. The fibroblasts and collagen content were higher in the skin when PRP was used in conjunction with fractional CO₂ laser to promote healthy tissue healing [21]. The PRP may also reduce inflammation of laser treated areas to expedite tissue remodelling by stem cell activation, migration, and proliferation [14]. Gaspar et al investigated the combined application of fractional CO₂ laser and PRP for vaginal atrophy and found histological evidence of vaginal regeneration and subjectively, the patients reported reduced vaginal dryness and dyspareunia [22]. Moreover, water is the chromophore for CO₂ laser, meaning that dehydrated tissues would respond poorly to the laser. PRP can hydrate and optimise the tissues (i.e. vaginal mucosa) [22].

This study sought to investigate the feasibility and efficacy of transvaginal CO₂ laser with PRP for the treatment of SUI, in women. The primary outcome measured was symptoms of SUI, cough test, and bladder neck funnelling on ultrasound and urodynamics study. Secondary outcomes included symptoms of general bladder function, level of bother with bladder issues, and quality of life (QoL).

Materials and methods

This single-centre prospective observational pilot study enrolled 62 women suffering from SUI who were treated with transvaginal CO₂ laser and PRP. Participants provided written informed consent prior to treatment. This study was approved by the local ethics committee in adherence with the Declaration of Helsinki. Patients were not compensated for participation.

Participants

Inclusion criteria for this study included women who exhibited clinically significant symptoms of SUI (judged by pad usage and had a negative impact on QoL from SUI symptoms), a positive cough test, urethral hypermobility as detected by translabial ultrasound, who did not respond or responded unsatisfactorily to previous therapies and were opting for non-surgical treatment. Exclusion criteria included prolapse \geq stage II as per the Pelvic Organ Prolapse Quantification (POPQ) system, current malignancy, known cervical dysplasia, acute or recurrent urinary tract infections, previous pelvic reconstructive surgery, current

pregnancy, undiagnosed abnormal uterine bleeding, concurrent use of anti-platelet or anti-coagulant medications and any psychiatric disorder precluding informed consent. Women were encouraged to continue conservative SUI treatments, such as topical oestrogen therapy and pelvic floor exercises.

Study protocol

All participants underwent transvaginal laser treatments (MonaLisa Touch, SmartXide2 V2LR, DEKA, Italy), with the following settings applied: power 40 W, dwell time 1000 μ s, DOT spacing 700 μ m, SmartStak parameter 3, and double pulse mode. Prior to treatment, a topical anaesthetic cream was applied to the vulva. A 90° vaginal laser-emitting probe was then inserted up to the level of the bladder neck, rotated and withdrawn, exposing the anterior lower one-third of the vagina to the laser. Participants were also subjected to total vaginal length laser treatments with a 360° probe, as described by Salvatore et al [26]. Overall, patients received three treatments, four to six weeks apart, conducted at FBW Gynaecology Plus. Patients were advised to avoid vaginal intercourse for five days after each laser treatment and to avoid lifting loads >10 kg for two weeks. Patients with a past history of genital herpes were given antiviral prophylaxis two hours prior the laser treatments. A hydrating silicone-based balm was applied to the vulvo-vestibular area to minimise dryness post-laser.

Participants also received the same amount of RegenPRP[®] treatment immediately after each vaginal laser treatment. The 10 mL blood sample was drawn and prepared on site with a RegenLab[®] centrifuge. After topical local anaesthetic cover, the PRP was injected into the anterior lower one-third of the vagina and periurethral area. Post-treatment pain scores were measured after each treatment using a verbal scale from 0 to 10.

The primary treatment outcome and the secondary treatment outcomes (symptoms relating to general bladder function, such as nocturia, urge urinary incontinence and pad usage) were measured using the participant's scores from relevant items of the Australian Pelvic Floor Questionnaire (APFQ), which is a validated quality of life questionnaire (see Appendix 1). The 15 bladder function variables were added to calculate an overall bladder function score out of 45 [27]. Questionnaires were completed at baseline (T1), three months after the third treatment (T2) and at a 12–24 months after treatment (T3). Additionally, sociodemographic data was gathered from the practitioner's medical records (including records of patient POPQ scores) [25].

Statistical analysis

Statistically significant differences in all primary and secondary outcomes occurring between T1-T2 and T1-T3 were detected using Wilcoxon signed-rank tests. The threshold for statistical significance was set at 0.05. IBM SPSS software, version 21.0 (IBM, Chicago, Ill) was used for data processing and analysis.

Results

This study recruited 62 women, ranging from 32 to 86 years of age (mean = 55.98; SD = 11.27), 48 (77.4%) were postmenopausal. Most women (92%, 57/62) were multiparous with 72.6% (45/62) having an average of 2.3 vaginal births. Most women were Caucasian (95.2%, 59/62). There were 65.2% (28/43) obese women in this cohort. All women were candidates for urodynamic assessment. However, 56.5% (35/62) women proceeded to have baseline urodynamics. There were 39.3% (24/62) of women who used vaginal oestrogen despite all women were recommended this treatment if not contraindicated.

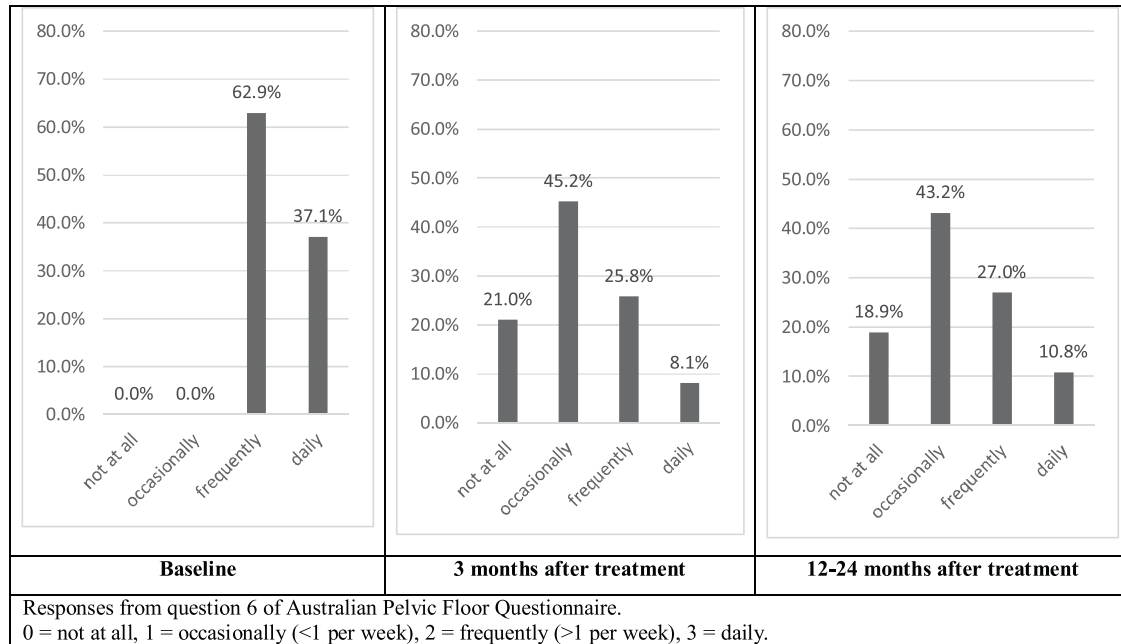


Fig. 1. Changes in stress incontinence symptoms in women who underwent PRP and fractional CO2 laser at pre-treatment (T1; n = 62), 3 months post-treatment (T2; n = 62), and 12–24-month post-treatment (T3; n = 37). The vertical and horizontal axes show the frequency percentages and the disease status respectively.

Stress urinary incontinence

Fig. 1 reveals changes in SUI symptoms, as measured by APFQ item 6 at 3 months follow-up (T2) and at 12–24 month follow up (T3), compared to baseline (T1). At T1, 100% (62/62) of participants reported either frequent or daily SUI symptoms, compared to 25.8% (16/62) for frequent symptoms and 8.1% (5/62) for daily symptoms at T2. At T1, no participants reported that they experienced either occasional or no SUI symptoms. Whilst at T2, 66.2% (41/62) of participants reported either occasional or no symptoms of SUI. At T3, 18.9% (7/37) reported no SUI symptoms, 43.2% (16/37) reported occasional symptoms, 27% (10/37) reported frequent symptoms and 10.8% (4/37) reported daily symptoms.

These improvements are also reflected in the decrease in mean and median scores, from 2.3 ± 0.4 and 2 (T1), to 1.2 ± 0.8 and 1 (T2), to 1.3 ± 0.9 and 1 (T3) for APFQ item 6. Overall, 66% (41/62) of participants reported improvements in their SUI symptoms from T1-T2 ($p < 0.001$) (Table 1) and 62% (23/37) from T1-T3 ($p < 0.001$) (Table 2).

Secondary outcomes relating to bladder function

Fig. 2 reveals lower levels of patient-reported bother with their bladder symptoms after the treatment protocol. At T1, 3.3% of participants reported that their bladder symptoms didn't bother them. At T2 and T3, these numbers improved to

Table 1

Outcomes for women who underwent PRP and fractional CO2 laser at pre-treatment (T1) compared to 3 months after treatment (T2). Changes are represented using Wilcoxon's signed-rank test scores.

	APFQ	Change between T1-T2					Mean ± STD	Median
		Improvement % (n)	z	r	p			
Primary outcome								
Stress incontinence	6	66 (62)	-5.9	0.54	<0.001	T1 = 2.3 ± 0.4 T2 = 1.2 ± 0.8	T1 = 2 T2 = 1	
Secondary outcomes								
Bladder Function	1-15	86 (57)	-5.2	0.49	<0.001	T1 = 1.0 ± 0.8 T2 = 0.3 ± 0.5	T1 = 1 T2 = 0	
Urge incontinence	5	73 (62)	-4.7	0.43	<0.001	T1 = 1.6 ± 0.9 T2 = 0.8 ± 0.7	T1 = 2 T2 = 1	
Urgency	4	62 (62)	-4.5	0.40	<0.001	T1 = 1.7 ± 1 T2 = 1 ± 0.8	T1 = 2 T2 = 1	
Wearing pads	10	48 (62)	-3.5	0.32	0.001	T1 = 1.4 ± 1.2 T2 = 0.9 ± 1.0	T1 = 2 T2 = 1	
Impact of urinary leakage on QOL	14	67 (58)	-4.5	0.41	<0.001	T1 = 1.4 ± 1 T2 = 0.6 ± 0.9	T1 = 1 T2 = 0	
Degree of bothersome bladder	15	58 (60)	-5.4	0.50	<0.001	T1 = 2 ± 0.8 T2 = 1.1 ± 0.9	T1 = 2 T2 = 1	

APFQ = Australian Pelvic Floor Questionnaire.

STD = Standard deviation.

z = Z value = standard scores.

r = Effect size = z / square root of N = total number of cases. $r > 0.35$ is medium effect. $r > 0.5$ is strong effect.

p = Probability value: statistically significant is set at $p < 0.05$ and statistically highly significant as $p < 0.001$.

Table 2
Outcomes for women who underwent PRP and fractional CO₂ laser at pre-treatment (T1) compared to 12–24 months after treatment (T3). Changes are represented using Wilcoxon's signed-rank test scores.

	APFQ	Change between T1-T3					
		Improvement % (n)	z	r	p	Mean ± STD	Median
Primary outcome							
Stress incontinence	6	62 (37)	-4.3	0.50	<0.001	T1 = 2.3 ± 0.4 T2 = 1.3 ± 0.9	T1 = 2 T2 = 1
Secondary outcomes							
Bladder Function	1-15	57 (17)	-3	0.52	0.002	T1 = 1 ± 0.8 T2 = 0.4 ± 0.6	T1 = 1 T2 = 0
Urge incontinence	5	46 (37)	-2.5	0.29	0.012	T1 = 1.6 ± 0.9 T2 = 1.1 ± 0.9	T1 = 2 T2 = 1
Urgency	4	44 (37)	-3.1	0.36	0.002	T1 = 1.7 ± 1 T2 = 1.1 ± 0.9	T1 = 2 T2 = 1
Wearing pads	10	41 (37)	-1.7	0.20	0.073	T1 = 1.4 ± 1.2 T2 = 1 ± 1.1	T1 = 2 T2 = 1
Impact of urinary leakage on QOL	14	70 (37)	-3.7	0.43	<0.001	T1 = 1.4 ± 1 T2 = 0.6 ± 0.9	T1 = 1 T2 = 0
Degree of bothersome bladder	15	57 (37)	-3.9	0.46	<0.001	T1 = 2.0 ± 0.8 T2 = 1.1 ± 1.1	T1 = 2 T2 = 1

APFQ= Australian Pelvic Floor Questionnaire.

STD= Standard deviation.

z = Z value = standard scores.

r = Effect size = z / square root of N = total number of cases. r > 0.35 is medium effect. r > 0.5 is strong effect.

p = Probability value: statistically significant is set at p < 0.05 and statistically highly significant as p < 0.001.

26.2% and 37.8%, respectively. The number of participants reporting moderate or great bother decreased from T1 to T2 and T3. The mean and median scores for degree of bothersome bladder at T1 were 2 ± 0.8 and 2. They fell to 1.1 ± 0.9 and 1 at T2 and 1.1 ± 1.1 and 1 at T3. Overall, from T1-T2 and T1-T3, 58% and 57% of participants, respectively, experienced improvements in the degree to which their bladder issues bothered them (p < 0.001) (Tables 1 and 2).

Similarly, improvements were also seen from T1-T2 in urge incontinence, urgency, pad usage, impact of urine leakage on quality of life and overall bladder function (p < 0.02) (Table 1). These improvements remained significant at T3 (p < 0.03), except for pad usage (p = 0.073) (Table 2). Additionally, the mean and

median scores for every secondary outcome (Tables 1 and 2) decreased from T1 to T2 and T3.

No participants experienced any adverse events due to these treatments. There were five participants who proceeded to have MUS surgery following the study. Nevertheless, PRP and fractional CO₂ laser treatment yielded pre-operative benefits in these women to increase mucosal thickness and quality [13,15].

In our cohort, two women (aged 70 and 78 years) who proceeded with SUI surgery consented for histological evaluation post-treatment of PRP and laser. They originally presented with severe GSM and SUI not responding to vaginal estrogen and other conservative measures. The histology at surgery demonstrated healthy non-atrophic vaginal mucosa.

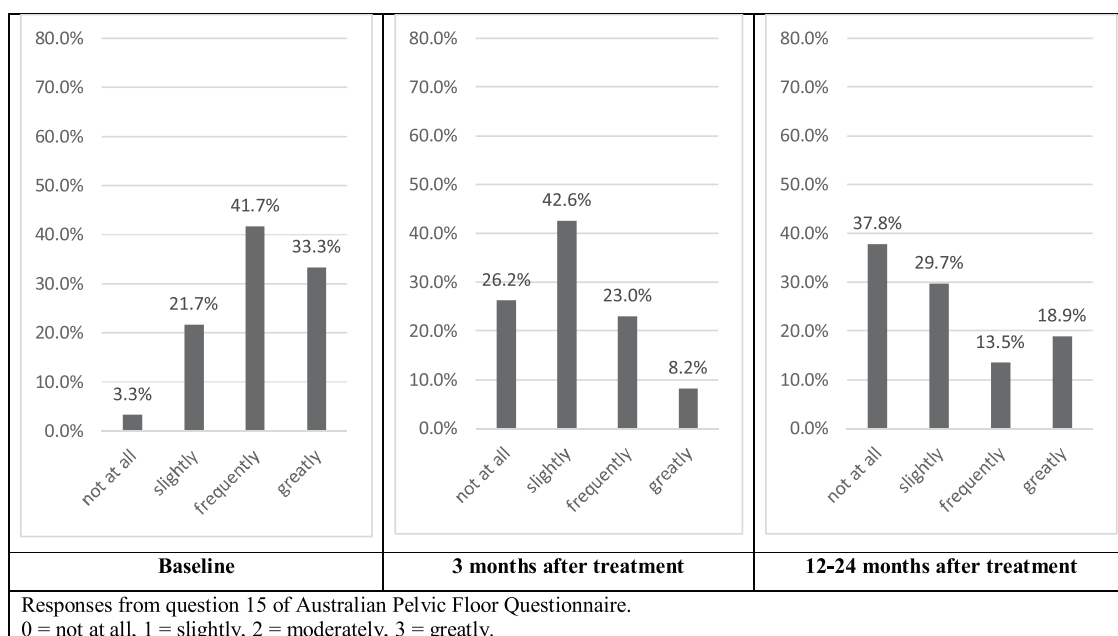


Fig. 2. Changes in bothersome symptoms in women who underwent PRP and fractional CO₂ laser at pre-treatment (T1; n=60), 3 months post-treatment (T2; n=36), and 12–24-month post-treatment (T3; n=37). The vertical and horizontal axes show the frequency percentages and the disease status respectively.

Comment

This study was based on the recently published study on transvaginal laser on SUI treatment, where the non-responders to transvaginal were treated with adjuvant PRP and had a successful outcome [28]. This study is the first to investigate short- and long-term effects of transvaginal PRP and laser for SUI treatment. A number of participants reported improvements in SUI symptoms at T2 and T3, both with statistically significant changes compared with T1. Moreover, mean and median scores for item 6 on the APFQ (Tables 1 and 2) decreased from T1 to T2 and T3. These results suggest that the combined use of PRP and fractional micro-ablative CO₂ laser may be an effective treatment for SUI, and that it may yield long-term improvements in SUI symptoms (up to 12–24 months).

SUI is burdensome both on a personal and national economic level [3,5]. In terms of treating SUI, surgery is currently the most effective option, with MUS being the standard procedure [7,8]. However, the invasiveness, recovery time and risks associated with MUS are drawbacks of this procedure [7,8], and due to recent comments made by regulatory bodies such as the TGA on the use of transvaginal mesh in gynaecological procedures, there has been widespread negative publicity surrounding procedures involving such materials [9]. Consequently, many SUI patients refuse to consider MUS. This is reflected by a considerable decline in SUI surgery in Australia since 2012 [6–8]. Aside from this, some women are unable to undergo complex laparoscopic surgery for urinary incontinence due to medical comorbidities. Hence, there is a profound need for an effective minimally-invasive treatments.

Whilst there are several conservative treatment strategies available, most rely on patient motivation [26,27]. Such strategies include behavioural modifications (i.e. moderating fluid intake and pelvic floor muscle training), pessaries (an intravaginal device which elevates the vesico-urethral angle) and pharmacological agents, like serotonin and noradrenaline reuptake inhibitors (SNRIs) and topical oestrogen, which can increase urethral sphincter muscle tone [26,27]. However, there is often poor compliance with behavioural-based therapies, side effects of the medications, and considerable costs associated with the pessaries as well as discomfort associated with the necessary insertion and removal of the devices on a regular basis [26,27].

PRP and laser may offer a minimally invasive, non-surgical, low-risk and efficacious treatment alternative for SUI. The findings from this study support and build upon previous research, such as the small prospective cohort study from Ogrinc et al, which demonstrated the short-term efficacy (up to 12 months) of Er: YAG non-ablative laser in treating UI (including SUI) [10], and the study from Salvatore et al, which demonstrated improvements in SUI symptoms following three fractional micro-ablative CO₂ laser treatments [11]. Studies have also shown PRP to be effective in treating gynaecological conditions, such as lichen sclerosus and GSM [18]. Additionally, combined application of PRP and laser has yielded benefit in vaginal rejuvenation [22].

Another benefit of the PRP and laser combination treatment is that the patient opt to urodynamic (UD) studies prior to surgical treatment if indicated. UD studies are an added expense to national health and patient, which can be time-consuming, invasive and uncomfortable for the patient [27]. Overall, rates of urodynamic studies at this centre were reduced by 43% and surgery also reduced by 92%, which may have a cost benefit to the patient and national health system.

There were several weaknesses associated with this study. Firstly, there was no comparison of the patients receiving PRP and laser to other participants receiving single modality treatment (PRP or laser alone). Therefore, this study could not reveal the individual contributions of PRP and the laser treatments to the improvements in SUI symptoms. It would be important to assess

the impact of topical estrogen use on vaginal mucosa with the study treatment. Similarly, there was also no direct comparison with other current standard treatments such as the MUS procedure, or with a control group. A randomised control trial (RCT) is desirable to confirm the findings of this study. It would also be valuable to assess the treatment effects beyond 24 months. Additionally, 22.6% of women in this study were pre-menopausal. Future studies should attempt to better represent this demographic. Finally, there was a high attrition rate from pre-treatment (T1) to the 12–24 month follow up (T3). This creates a potential for bias.

In conclusion, this study suggests that the combined use of transvaginal PRP and CO₂ laser is a novel treatment option for SUI. This treatment protocol is minimally-invasive, requires negligible recovery time and is comparatively lower risk than surgery. These findings warrant further investigation into this treatment, ideally as an RCT comparing PRP and laser to a placebo and/or current treatments, including surgery. Future research should also assess the individual contributions of the PRP and laser to the improvement of symptoms, and maintenance of treatment benefit beyond 24 months.

Funding

There were no funding sources for this study.

The authors have no conflict of interest and have not received any support (financial or otherwise) to conduct this study. However, SS is a consultant for DEKA laser.

Declaration of Competing Interest

The authors have no conflict of interest and have not received any support (financial or otherwise) to conduct this study. However, SS is a consultant for DEKA laser.

Acknowledgements

The authors wish to acknowledge the staff from FBW Gynaecology Plus for assisting in running the study and participant follow up.

References

- [1] Buckley BS, Lapitan MC. Prevalence of urinary incontinence in men, women, and children-current evidence: findings of the fourth international consultation on incontinence. *Urology* 2010;76:265–70.
- [2] Kavia R, Rashid T, Ockrim J. Stress urinary incontinence. *J Clin Urol* 2013;6: 377–90.
- [3] Sinclair AJ, Ramsay IN. The psychosocial impact of urinary incontinence in women. *Obstet Gynecol* 2011;13:143–8.
- [4] Fistonc I, Findri Gustek S, Fistonc N. Minimally invasive laser procedure for early stages of stress urinary incontinence (SUI). *J Laser Health Acad* 2012;1:67–74.
- [5] Doran CM, Chiarelli P, Cockburn J. Economic costs of urinary incontinence in community-dwelling Australian women. *Med J* 2001;174:456–8.
- [6] Brown J, King J. Age-stratified trends in 20 years of stress incontinence surgery in Australia. *Aust N Z J Obstet Gynaecol* 2016;56:192–8.
- [7] Han J, Lee K, Choo M. Management of recurrent or persistent stress urinary incontinence after mid-urethral sling. *LUTS* 2012;4:95–100.
- [8] Nitti VW. Complications of midurethral slings and their management. *Can Urol Assoc J* 2012;6:120–2.
- [9] Therapeutic Goods Administration. TGA actions after review into urogynaecological surgical mesh implants [Internet]. [updated 2019 May 17; cited 2019 Aug 31]. 9 p. Available from: Canberra: Therapeutic Goods Administration; 2018. <https://bit.ly/2G6NuMy>.
- [10] Ogrinc UB, Sencar S, Lenasi H. Novel minimally invasive laser treatment of urinary incontinence in women. *Lasers Surg Med* 2015;47:689–97.
- [11] Salvatore S, Calligaro A. Use of CO₂ laser therapy against vaginal atrophy, vaginal laxity and urinary incontinence. DEKA White Paper. July.
- [12] Zerbinati N, Serati M, Origoni M, et al. Microscopic and ultrastructural modifications of postmenopausal atrophic vaginal mucosa after fractional carbon dioxide laser treatment. *Lasers Med Sci* 2015;30:429–36.
- [13] Salvatore S, Leone Roberti Maggiore U, Athanasios S, et al. Histological study on the effects of microablative fractional CO₂ laser on atrophic vaginal tissue: an ex vivo study. *Menopause* 2015;22:845–9.

- [14] Hui Q, Chang P, Bingyu Guo, Zhang Y, Tao K. The clinical efficacy of autologous platelet-rich plasma combined with ultra-pulsed fractional CO₂ laser therapy for facial rejuvenation. *Rejuvenation Res* 2017;20:25–31.
- [15] Keane DP, Sims TJ, Abrams P, Bailey AJ. Analysis of collagen status in premenopausal nulliparous women with genuine stress incontinence. *Br J Obstet Gynaecol* 1997;104:994–8.
- [16] Rechberger T, Postawski K, Jakowicki JA, Gunja-Smith Z, Woessner [114_TD \$DIF\$]r. F. Role of fascial collagen in stress urinary incontinence. *Am J Obstet Gynecol* 1998;179(6 Pt1):1511–4.
- [17] Gambacciani M, Levancini M, Cervigni M. Vaginal erbium laser: the second-generation thermotherapy for the genitourinary syndrome of menopause. *Climacteric* 2015;18:757–63.
- [18] Behnia-Willison F, Pour NR, Mohamadi B, et al. Use of platelet-rich plasma for vulvovaginal autoimmune conditions like lichen sclerosus. *Plast Reconstr Surg Glob Open* 2016;4:e1124.
- [19] Nikolopoulos KI, Pergialiotis V, Perrea D, Doumouchtsis SK. Restoration of the pubourethral ligament with platelet rich plasma for the treatment of stress urinary incontinence. *Med Hypotheses* 2016;90:29–31.
- [20] Jeon YR, Kang EH, Yang CE, Yun IS, Lee WJ, Lew DH. The effect of platelet-rich plasma on composite graft survival. *Plast Reconstr Surg* 2014;134:239–46.
- [21] Salcido RS. Autologous platelet-rich plasma in chronic wounds. *Adv Skin Wound Care* 2013;26:248.
- [22] Gaspar A, Addamo G, Brandi H. Vaginal fractional CO₂ laser: a minimally invasive option for vaginal rejuvenation. *Am J Cosmet Surg* 2011;28:156–62.
- [25] Persu C, Chapple CR, Cauni V, Gutue S, Geavlete P. Pelvic Organ Prolapse Quantification System (POP-Q) – a new era in pelvic Prolapse staging. *J Med Life* 2011;4:75–81.
- [26] DeMaagd GA, Davenport TC. Management of urinary incontinence. *Pharmacy Therapeut* 2012;37(June (6)):345–61.
- [27] Weber AM, Walters MD. Cost-effectiveness of urodynamic testing before surgery for women with pelvic organ prolapse and stress urinary incontinence. *Am J Obstet Gynecol* 2000;183:1338–47.
- [28] Behnia-Willison F, Mohamadi B, Vancaille T, Nguyen T, Lam A, Willison N, et al. Fractional CO₂ laser for treatment of stress urinary incontinence. *Eur J Obstet Gynecol Reprod Biol: X* 2019, doi:<http://dx.doi.org/10.1016/j.eurox.2019.10004>.