

Periosteal Transplantation Combined with the Autologous Matrix-Induced Chondrogenesis (AMIC) Technique in Isolated Patellofemoral Osteoarthritis: A Case Report

Stefan Schüttler^{1,2} and Nenad Andjelkov^{2,3}

Abstract

Objective: Isolated cases of osteoarthritis of the knee represent a major clinical problem. A particular challenge is a case in which both articular surfaces are affected. Such is the case with the isolated form of patellofemoral osteoarthritis. Studies that describe methods for treating such conditions are few, and the results are not too promising. **Methods:** In this article, we present one such case of isolated patellofemoral osteoarthritis in which we used a new approach combining periosteal transplantation on one side and the autologous matrix-induced chondrogenesis (AMIC) technique on the other side. **Results:** The patient has improved, measured by the Knee injury and Osteoarthritis Outcome Score (KOOS) from 48 preoperatively to 77 at 1 year postoperatively (mean improvement) and measured by the Lysholm score from 45 preoperatively to 90 at 1 year postoperatively. **Conclusion:** This original approach has shown promising results in this patient and could be tested in a larger group of patients with the same type of osteoarthritis in order to estimate its real clinical value.

Keywords

cartilage repair, knee, osteoarthritis

Case Presentation

A 35-year-old man, a former basketball player, is currently working in an office. The patient had his first contact with the orthopedic surgeon in 2004, at the age of 29 years, with already a 2-year history of knee pain behind the kneecap, which was related to physical activity. He also had difficulties in the sitting position with the knees in flexion as well as locking of the knee. No prior trauma was related to the beginning of symptoms. In 2006, arthroscopy was performed for the first time in his right knee, where shaving and trimming of the transverse ligament were done. However, nothing seen during the arthroscopy could explain locking of the knee. He continued having symptoms even postoperatively and experienced an acceleration of the symptoms including postoperative pain, swelling, and crepitation in his knee. MRI of his right knee was performed in March 2007 and showed an excessive amount of synovial fluid, patella subluxation, and light edema in its lateral part (**Fig. 1**, left). No visible cartilage damage was seen at this point using MRI, according to a radiologist.

The patient's symptoms worsened with time, and a decision was made to do another arthroscopy 6 months after MRI. This time, significant cartilage damage was found, which was described as "severe cartilage damage in the patellofemoral joint" by the operating surgeon, and the patient was diagnosed with patellofemoral osteoarthritis grade III to IV according to the Outerbridge classification. Arthroscopic shaving, microfracture, and lateral release were performed. The patient did not experience any improvement postoperatively; on the contrary, his symptoms accelerated over time, and we saw the patient for the first time 6 months after the last operation. A decision was

¹Specialist Center Scandinavia, Eskilstuna, Sweden

²Centre for Clinical Research, Västerås, Sweden

³Department of Orthopaedics, Västmanland Regional Hospital, Västerås, Sweden

Corresponding Author:

Nenad Andjelkov, Ortopedkliniken, Västmanlands sjukhus Västerås, Landstinget Västmanland, 721 89 Västerås, Sweden
Email: nenad.andjelkov@ltv.se, andjelkovn@hotmail.com

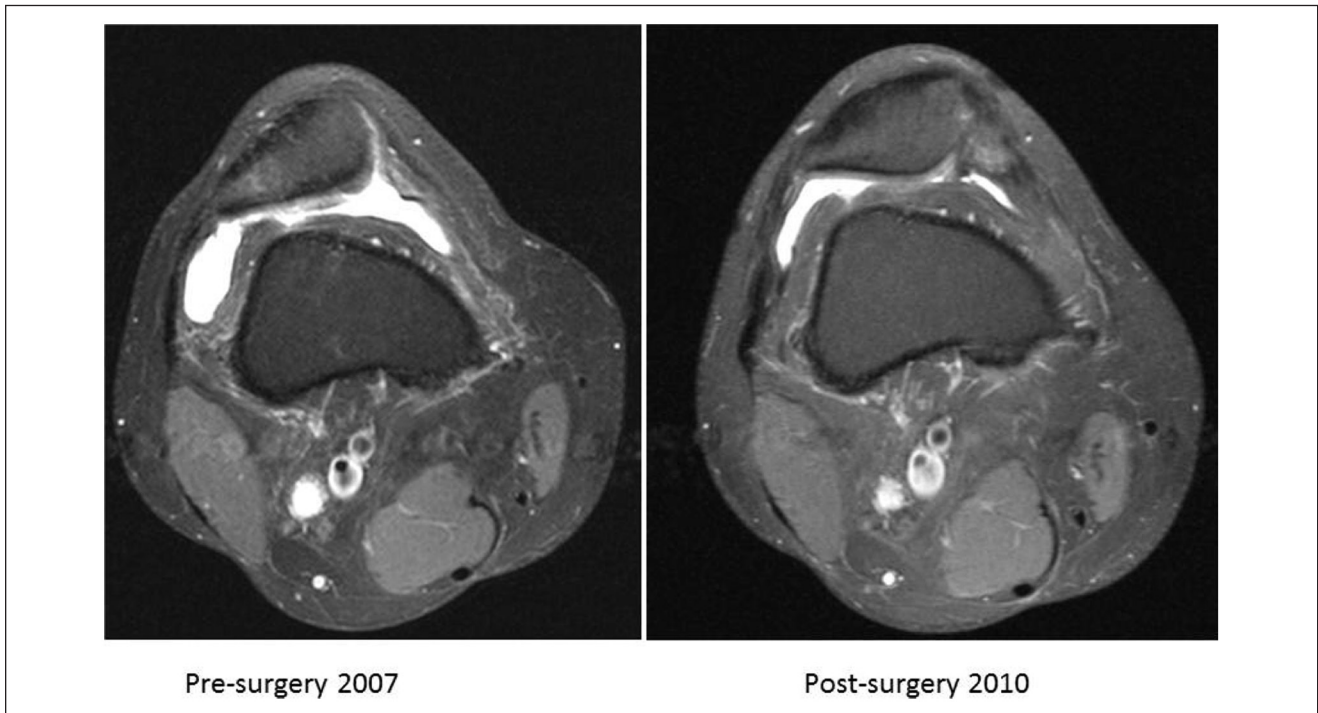

Figure 1. MRI scans before the lateral release procedure and MRI image of the control 1 year postoperatively. Transversal view.

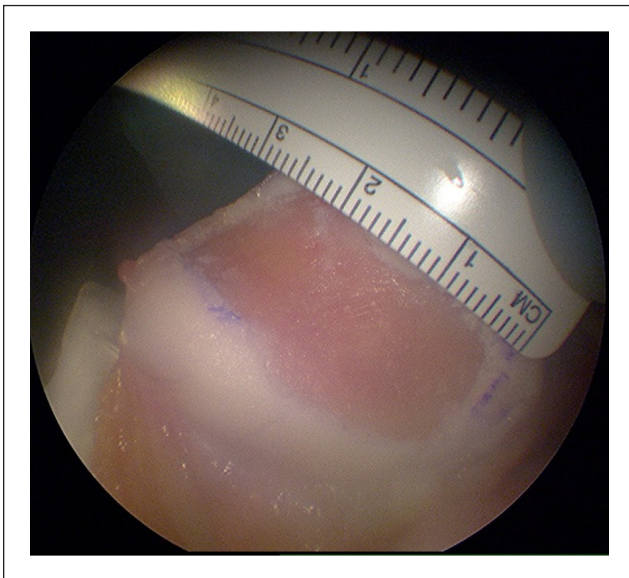


Figure 2. Cartilage defect on the patellar side. The size of the defect was $40 \times 20 \times 4$ mm after the debridement of damaged cartilage.

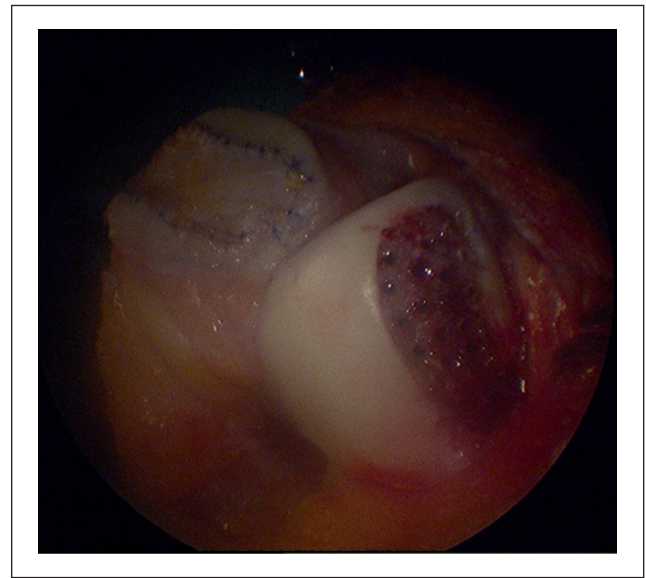


Figure 3. Cartilage defect on the trochlear side. The size of the defect was $40 \times 15 \times 4$ mm after the debridement of damaged cartilage.

made to do a cartilage repair procedure 2 years after the last operation. We started with explorative arthroscopy and found complete damage on the articular surface centrally in the patella and trochlea, which was estimated as grade III to IV according to the Outerbridge classification (**Figs. 2 and 3,**

after debridement). The rest of the articular cartilage in the affected knee joint was judged as normal. We decided to proceed with knee arthrotomy using a medial parapatellar incision. The osteophytes on the trochlear side were removed. A periosteum transplantation on the patellar side^{1,2} and the

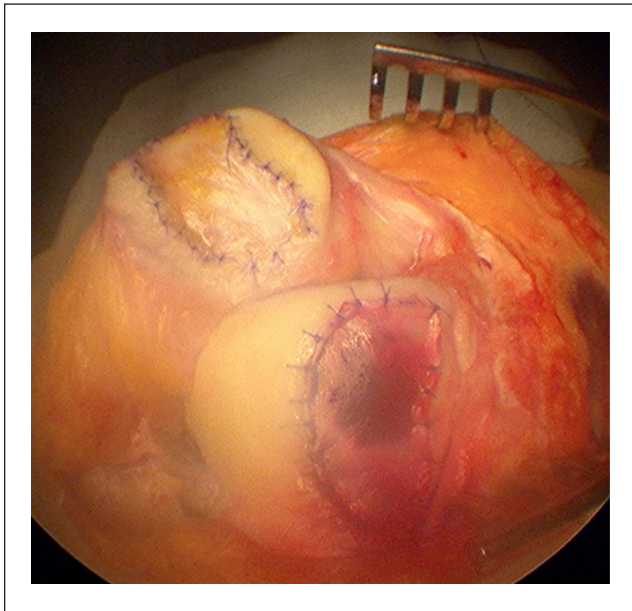


Figure 4. Patellofemoral joint prior to closing the wound. The patellar side of the joint after suturing of the periosteal flap and injection of fibrin under the periosteum cover. Microfracture was performed on the trochlear side. The Chondro-Gide membrane was sutured and secured with fibrin injected under the membrane on the trochlear side.

autologous matrix-induced chondrogenesis (AMIC) technique on the trochlear side^{3,4} were performed. On both sides, we used fibrin glue (Tisseel Duo Quick, Baxter Medical AB, Kista, Sweden) to secure the periosteal flap, which we harvested from the proximal tibia, and Chondro-Gide membrane (Chondro-Gide, Geistlich Pharma AG, Wolhusen, Switzerland) in place. Fibrin was also used as a matrix.^{5,6} We could not perform a patellar ridge preservation technique, that is, the “double-eye technique”,⁷ because there was no cartilage to preserve between the lateral and medial parts of the patella (**Fig. 2**). However, relatively normal patellar cartilage anatomy was restored by injecting an excess of fibrin between the medial and lateral articular surfaces (**Fig. 4**). The soft-tissue layers and skin were closed, and no drainage was applied.⁸ The patient was administered a femoral nerve block, painkillers, antibiotics and thrombosis prevention, an ice bandage, a brace locked in 0°, and crutches, and he was released from the hospital after a few hours. Therefore, the operation was performed as a day-care surgery. The patient followed a standard rehabilitation program recommended by the Chondro-Gide manufacturer by the time of the operation (http://www.geistlich.com/upload/docs/pdf/AMIC_Knee_e_lowres.pdf).

Control MRI was done 1 year postoperatively (**Fig. 1**, right). The Knee injury and Osteoarthritis Outcome Score (KOOS) and Lysholm knee score were used preoperatively and then at 6 and 12 months postoperatively and showed

Table 1. Knee Injury and Osteoarthritis Outcome Score (KOOS) and Lysholm Knee Score Preoperatively and 6 and 12 Months Postoperatively

Time point	KOOS					Lysholm
	Pain	Symptoms/ stiffness	Activities of daily living	Sports	Quality of life	
Preoperatively	53	57	75	35	19	45
6 months	72	68	85	10	31	42
12 months	100	93	100	55	38	90

Table 2. SOLEC, Chair Stand Test, Quadriceps Muscle Strength, and Range of Motion 6 and 12 Months Postoperatively

Time point	Range of motion, degree		Chair stand test, repetitions		Quadriceps strength, Nm		SOLEC, s	
	Right knee	Left knee	Right knee	Left knee	Right knee	Left knee	Right knee	Left knee
	6 months	125	130	0	11	228	430	10
12 months	135	135	12	13	324	416	22	42

remarkable improvement 1 year after the operation (**Table 1**). Standing on one leg with eyes closed test (SOLEC), chair stand test, range of motion, and quadriceps muscle strength were all measured at 6 and 12 months’ follow-up but not preoperatively because of administrative omission, and the data were unfortunately lost for comparison (**Table 2**). The 1-year control with MRI showed new cartilage-like tissue formation on both treated surfaces with well-filled defects (**Fig. 1**, right). The MRI scans were not classified according to magnetic resonance observation of cartilage repair tissue (MOCART)⁹ because the radiologists at our hospital who interpreted the images were not familiar with this classification. The patient was very satisfied with the result. He did not feel any pain postoperatively. He had discreet crepitation in his operated knee after the operation but no pain and no swelling. He went back to his normal daily activities without any limitations, with the exception of jogging, which he could not do even before the operation. However, this time, the reason was not pain and swelling after knee overload, which was the case preoperatively, but rather quadriceps muscle hypotrophy after the operation that gave him a certain sense of instability when jogging.

Discussion

The repair of large symptomatic cartilage defects was and still is a major clinical problem. At present, many different operative techniques are used in daily clinical practice, but there is still no general consensus about which of them

gives the best clinical results.⁵ Of all locations, the poorest clinical results were reported for chondral defects in the patellofemoral joint, mainly the patellar.⁷ This is due to specific cartilage properties in the patella as well as complex biomechanics in this joint.¹⁰ Good clinical outcome was supposed to deteriorate even more when both articular surfaces are damaged because AMIC was not recommended in those cases by its inventors (http://www.geistlich.com/upload/docs/pdf/AMIC_Knee_e_lowres.pdf). Cartilage repair techniques were initially aimed for isolated symptomatic chondral defects of mainly traumatic origin, osteochondritis dissecans, and lately even osteoarthritis.¹¹⁻¹³ Generalized osteoarthritis was postulated as an absolute contraindication for the use of these techniques.¹²

There is just one report at present describing a novel surgical technique for the treatment of patellofemoral osteoarthritis.² A different approach was used in that study as well when compared to ours, as periosteal transplantation was used on the trochlear side and AMIC using Pridie's drilling technique¹⁴ on the patellar side. The periosteum was also placed onto the bottom of the defect, while we sutured it to the top. The reasons for doing so were explained in a study,⁵ but also when performing autologous chondrocyte implantation (ACI), the periosteum is sutured to the top of the defect.¹¹ It seemed more reasonable to us to use the periosteum on the patellar side because the periosteum has a tendency for graft hypertrophy.¹⁵ Because cartilage is thickest in the patella, we thought it would be a good idea to place the periosteal flap there, where we need the most new cartilage-like tissue formation. One should avoid or at least reduce the thermal damage to the subchondral bone plate by constantly irrigating with physiological solution while drilling. We used the drilling technique and not the Steadman microfracture technique¹⁶ because of a risk of fracturing the sclerotic bone, which is often the case in the patella. In those cases, microfracture should generally be avoided in the patella. In addition, drilling seems to be superior to microfracture by reaching the subchondral bone marrow and stimulating bone marrow.¹⁷ We used fibrin on both surfaces, not just as a biological glue but also as a matrix,⁶ which was not the case in the aforementioned study. Another issue that needs to be discussed at this point is possible periosteal flap hypertrophy. Namely, it is a fact that the use of a periosteum results in a higher frequency of excessive new tissue growth in comparison to other techniques.^{15,18,19} On the other hand, other techniques give more of some other complications.^{18,19} Our reason for using a periosteum on the patellar side was cartilage thickness and specific anatomy of the patella. In our opinion, tissue hypertrophy on the patellar side of the joint would be less harmful in this case for the following reason: if we look at the MRI scans of this patient, we can notice that the trochlear groove in

this case almost does not exist (**Fig. 1**, left). We should not forget the fact that the patient underwent a patellar realignment procedure before we operated on him due to lateral dislocation of the patella. In our opinion, new tissue hypertrophy in the trochlear groove would give him new instability in the patellofemoral joint due to the absence of the groove. Obviously, our goal was to try to restore the normal anatomy of the patellofemoral joint as much as possible. For that reason, we used the Chondro-Gide membrane on the femoral side, which gives less tissue hypertrophy when compared to a periosteum. The Chondro-Gide membrane manufacturer does not recommend its use in the case of cartilage damage on 2 opposite joint surfaces, in this case, the patella and trochlea.^{3,17,20} One reason could be an increased coefficient of friction between 2 surfaces and the negative effect that it could have on the membrane itself. Here, we are referring to physical damage to the membrane. A second reason would be the difficulty in ensuring membrane stability due to higher friction that would increase the risk for membrane delamination and therapy failure. Using 2 different types of material, in this case, different membranes, seems to reduce the friction coefficient.² In our case, we used a natural material, which was very smooth in its nature as the periosteum. We believe that the combination of these 2 membranes has been used in the reported study for the same reasons.² As we mentioned earlier, the patient had discreet crepitation without pain or any other symptom. Because both articular surfaces were damaged and repaired, which certainly increases the friction, we believe that the crepitation was a result of that rather than hypertrophy of the periosteum. Therefore, there was no need for second-look arthroscopy and shaving. Even if there were hypertrophy of the periosteum, for the previous reasons, it was considered asymptomatic and therefore left untreated. Finally, the question remains about the patellar misalignment. We are fully aware of the importance of its possible correction.^{21,22} The reason this has not been done is that the lateral release procedure has already been performed before we operated on the patient, although no medialization of the tuberosity has been made. We had the impression during the wound closure and the medial plication procedure that had been performed prior to this that the patella was placed and moved correctly in the joint. The obvious difference in the position of the patella is shown on MRI before the lateral release, which was made in 2007 (**Fig. 1**, left), and MRI 1 year postoperatively after the cartilage repair procedure (**Fig. 1**, right).

Overall, we report for the first time an original approach for the treatment of complex patellofemoral osteoarthritis with a 1-year follow-up, with excellent clinical results. We are aware that we need further midterm to long-term follow-up as well as a greater number of patients to get a more exact validation of this approach.

Acknowledgments and Funding

The authors thank Marta Baranowska and Johan Thunberg for their help in the rehabilitation of the patient. The patient was informed that data concerning the case would be submitted for publication, and informed consent was obtained. The author(s) received no financial support for the research, authorship, and/or publication of this article.

Declaration of Conflicting Interests

The author(s) declared no potential conflicts of interest with respect to the research, authorship, and/or publication of this article.

References

1. Bruns J, Steinhagen J. Transplantation of chondrogenic tissue in the treatment of lesions of the articular cartilage. *Orthopade*. 1999;28(1):52-60.
2. Kusano T, Marti C, Jacobi M, Jakob R. Autologous matrix-induced chondrogenesis (AMIC) on the patella plus periosteal coverage on the trochlea combined with mechanical realignment: a new treatment option in symptomatic isolated femoropatellar osteoarthritis due to subluxation of the patella. Ninth World Congress of the International Cartilage Repair Society; 2010 Sep 26-29; Sitges/Barcelona, Spain.
3. Benthien JP, Behrens P. Autologous matrix-induced chondrogenesis (AMIC): a one-step procedure for retropatellar articular resurfacing. *Acta Orthop Belg*. 2010;76(2):260-3.
4. Gille J, Schuseil E, Wimmer J, Gellissen J, Schulz AP, Behrens P. Mid-term results of autologous matrix-induced chondrogenesis for treatment of focal cartilage defects in the knee. *Knee Surg Sports Traumatol Arthrosc*. 2010;18(11):1456-64.
5. Hunziker EB. Articular cartilage repair: basic science and clinical progress. A review of the current status and prospects. *Osteoarthritis Cartilage*. 2001;10:432-63.
6. Kim MK, Choi SW, Kim SR, Oh IS, Won MH. Autologous chondrocyte implantation in the knee using fibrin. *Knee Surg Sports Traumatol Arthrosc*. 2010;18(4):528-34.
7. Niemeyer P, Kreuz PC, Steinwachs M, Köstler W, Mehlhorn A, Kraft N, *et al*. Technical note: the "double eye" technique as a modification of autologous chondrocyte implantation for the treatment of retropatellar cartilage defects. *Knee Surg Sports Traumatol Arthrosc*. 2007;15(12):1461-8.
8. Tai TW, Jou IM, Chang CW, Lai KA, Lin CJ, Yang CY. Non-drainage is better than 4-hour clamping drainage in total knee arthroplasty. *Orthopedics*. 2010;10:156-60.
9. Welsch GH, Mamisch TC, Zak L, Blanke M, Olk A, Marlovits S, *et al*. Evaluation of cartilage repair tissue after matrix-associated autologous chondrocyte transplantation using a hyaluronic-based or a collagen-based scaffold with morphological MOCART scoring and biochemical T2 mapping: preliminary results. *Am J Sports Med*. 2010;38(5):934-42.
10. Niemeyer P, Steinwachs M, Erggelet C, Kreuz PC, Kraft N, Köstler W, *et al*. Autologous chondrocyte implantation for the treatment of retropatellar cartilage defects: clinical results referred to defect localisation. *Arch Orthop Trauma Surg*. 2008;128(11):1223-31.
11. Peterson L, Minas T, Brittberg M, Lindahl A. Treatment of osteochondritis dissecans of the knee with autologous chondrocyte transplantation: results at two to ten years. *J Bone Joint Surg Am*. 2003;85-A(Suppl 2):17-24.
12. Knutsen G, Engebretsen L, Ludvigsen TC, Drogset JO, Grøntvedt T, Solheim E, *et al*. Autologous chondrocyte implantation compared with microfracture in the knee: a randomized trial. *J Bone Joint Surg Am*. 2004;86-A(3):455-64.
13. Braun S, Steadman JR, Rodkey WG, Briggs KK. Microfracture and specific rehabilitation for treating osteoarthritis of the knee: indications, surgical technique, and rehabilitation protocol. *Z Rheumatol*. 2009;68(10):811-8.
14. Pascarella A, Ciatti R, Pascarella F, Latte C, Di Salvatore MG, Liguori L, *et al*. Treatment of articular cartilage lesions of the knee joint using a modified AMIC technique. *Knee Surg Sports Traumatol Arthrosc*. 2010;18(4):509-13.
15. Erggelet C, Kreuz PC, Mrosek EH, Schagemann JC, Lahm A, Ducommun PP, *et al*. Autologous chondrocyte implantation versus ACI using 3D-bioresorbable graft for the treatment of large full-thickness cartilage lesions of the knee. *Arch Orthop Trauma Surg*. 2010;130(8):957-64.
16. Steadman JR, Briggs KK, Rodrigo JJ, Kocher MS, Gill TJ, Rodkey WG. Outcomes of microfracture for traumatic chondral defects of the knee: average 11-year follow-up. *Arthroscopy*. 2003;19(5):477-84.
17. Benthien JP, Behrens P. The treatment of chondral and osteochondral defects of the knee with autologous matrix-induced chondrogenesis (AMIC): method description and recent developments. *Knee Surg Sports Traumatol Arthrosc*. 2011;19(8):1316-9.
18. Zeifang F, Oberle D, Nierhoff C, Richter W, Moradi B, Schmitt H. Autologous chondrocyte implantation using the original periosteum-cover technique versus matrix-associated autologous chondrocyte implantation: a randomized clinical trial. *Am J Sports Med*. 2010;38(5):924-33.
19. Niemeyer P, Pestka JM, Kreuz PC, Erggelet C, Schmal H, Suedkamp NP, *et al*. Characteristic complications after autologous chondrocyte implantation for cartilage defects of the knee joint. *Am J Sports Med*. 2008;36:2091-9.
20. Benthien JP, Behrens P. Autologous matrix-induced chondrogenesis (AMIC): combining microfracturing and a collagen I/III matrix for articular cartilage resurfacing. *Cartilage*. 2010;1(1):65-8.
21. Vasiliadis HS, Lindahl A, Georgoulis AD, Peterson L. Malalignment and cartilage lesions in the patellofemoral joint treated with autologous chondrocyte implantation. *Knee Surg Sports Traumatol Arthrosc*. 2011;19(3):452-7.
22. Gigante A, Enea D, Greco F, Bait C, Denti M, Schonhuber H, *et al*. Distal realignment and patellar autologous chondrocyte implantation: mid-term results in a selected population. *Knee Surg Sports Traumatol Arthrosc*. 2009;17(1):2-10.