



CLINICAL PRACTICE ARTICLE

REVISED

# Recurrent internal hip rotation gait in cerebral palsy: Case reports of two patients [version 2; peer review: 2 approved]

Previously titled: Recurrent internal hip rotation gait in cerebral palsy: Report of two patients

Rory O'Sullivan , Damien Kiernan 

Gait Analysis Laboratory, Central Remedial Clinic, Dublin, Dublin, Dublin 3, Ireland

**v2** First published: 23 Dec 2018, 1:28 (<https://doi.org/10.12688/hrbopenres.12893.1>)Latest published: 29 Jan 2019, 1:28 (<https://doi.org/10.12688/hrbopenres.12893.2>)

## Abstract

Internal hip rotation in cerebral palsy (CP) is typically treated with a femoral derotation osteotomy. This has been shown to be largely a successful procedure but recurrence rates up to 41% have been reported. Reported risk factors include younger age, reduced hip joint impulse and ankle plantar-flexion.







We report on two patients with bilateral CP demonstrating recurrent unilateral internal hip rotation despite surgical intervention(s). Both demonstrate a number of the reported risk factors for recurrence. In addition, this case report specifically compared gait kinematic patterns pre and post recurrence. On comparing both patient's hip rotation and ankle dorsi/plantarflexion kinematics they are seen to be almost identical both pre-operatively and post-operatively. Both patients appear to revert to approximately 30° of internal hip rotation which has been shown to maximise hip abductor function. Therefore, this case report suggests that surgical derotation in isolation is unlikely to be successful in this group and we suggest that this hip and ankle pattern may help predict recurrence in unilateral internal hip rotation.

## Keywords

Cerebral palsy, internal rotation gait, internal hip rotation

## Open Peer Review

Reviewer Status  

	Invited Reviewers	
	1	2
<b>version 2</b> (revision) 29 Jan 2019	 report	 report
<b>version 1</b> 23 Dec 2018	  report	  report

- Mauro César de Morais Filho** , AACD, São Paulo, Brazil
- Damien Bennett**, Public Health Agency, Belfast, Ireland

Any reports and responses or comments on the article can be found at the end of the article.

**Corresponding author:** Rory O'Sullivan ([royosullivan@rcsi.com](mailto:royosullivan@rcsi.com))**Author roles:** O'Sullivan R: Conceptualization, Data Curation, Formal Analysis, Methodology, Writing – Original Draft Preparation, Writing – Review & Editing; Kiernan D: Data Curation, Formal Analysis, Writing – Review & Editing**Competing interests:** No competing interests were disclosed.**Grant information:** The author(s) declared that no grants were involved in supporting this work.**Copyright:** © 2019 O'Sullivan R and Kiernan D. This is an open access article distributed under the terms of the [Creative Commons Attribution License](https://creativecommons.org/licenses/by/4.0/), which permits unrestricted use, distribution, and reproduction in any medium, provided the original work is properly cited.**How to cite this article:** O'Sullivan R and Kiernan D. **Recurrent internal hip rotation gait in cerebral palsy: Case reports of two patients [version 2; peer review: 2 approved]** HRB Open Research 2019, 1:28 (<https://doi.org/10.12688/hrbopenres.12893.2>)**First published:** 23 Dec 2018, 1:28 (<https://doi.org/10.12688/hrbopenres.12893.1>)

**REVISED Amendments from Version 1**

In this revised version of the manuscript the following changes were incorporated-

- All minor typographical errors have been corrected
- The title has been slightly edited to: "Recurrent internal hip rotation gait in cerebral palsy: Case report of two patients"
- A figure (Figure 2) has been added to document the temporary improvement in hip rotation following derotation surgery in both Patients.
- References for the modified Oxford Grading of muscle strength have been included.
- It has been made more obvious through-out the manuscript that this is a case report of two similarly presenting patients rather than a formal study. This has led to more formal analysis of recurrence of internal hip rotation in our center, focusing on the kinematic pattern of hip rotation pre and post operatively as seen in the two cases presented here.

See referee reports

## Introduction

Cerebral Palsy (CP) is the most common cause of motor deficiency in young children occurring in 2.1 per 1000 live births (Oskoui *et al.*, 2013). Internal hip rotation gait (IHRG) is common with a reported prevalence of 31.6% in bilateral CP and is a unilateral issue in the majority (78.4%) of cases (O'Sullivan *et al.*, 2006).

IHRG in CP has been attributed to a variety of impairments associated with CP, including hip flexor, hamstring, adductor or gluteus medius tightness; femoral anteversion and hip abductor lever arm dysfunction (Arnold *et al.*, 1997; Arnold *et al.*, 2000; Arnold & Delp, 2001; Delp *et al.*, 1999; O'Sullivan *et al.*, 2006). While the correlation between static measure of femoral anteversion and hip rotation during gait is low (Braatz *et al.*, 2013; Lee *et al.*, 2013), femoral derotation osteotomy (FDRO) remains the 'gold-standard' treatment for IHRG (Niklasch *et al.*, 2015a; Schwartz *et al.*, 2014). This is largely a successful intervention and a recent systematic review and meta-analysis has confirmed the positive effects of this surgery on the hip and pelvis during gait (Carty *et al.*, 2014) with long-term benefits reported up to 9 years post-surgery (Dreher *et al.*, 2012).

However, recurrence rates of 15% to 41% have been reported (Church *et al.*, 2017; Niklasch *et al.*, 2015a) and in clinical practice these patients present a significant challenge. Recurrence of IHRG following surgery can be frustrating, presenting a dilemma for both therapist and surgeon regarding how best to preserve the effect of initial surgery or whether to consider repeat FDRO following recurrence. Being able to identify those patients likely to revert to internal hip rotation following FDRO would be of significant benefit to facilitate more informed surgical planning. If the decision is made to proceed with the FDRO the realistic potential for recurrence should be discussed with the family to manage expectations and potentially plan appropriate post-operative strategies to try and best preserve the effect of derotation.

Little is known about risk factors for recurrent FDRO and to our knowledge only two studies have reported on this. Church *et al.* (Church *et al.*, 2017) found that those more likely to recur had slower gait velocity and higher levels of spasticity. However, this is not particularly specific as a number of factors can influence gait speed. Niklasch *et al.* (2015b) reported more specific risk factors for recurrence including younger age (<10 years old), reduced hip joint impulse and increased ankle plantar-flexion and internal foot progression pre-operatively.

The purpose of this clinical case report is to highlight similarities in a recurring internal hip rotation kinematic pattern in two cerebral palsy patients despite surgical intervention(s).

## Description of the two cases

We analysed two patients with bilateral spastic cerebral palsy presenting with recurrent unilateral IHRG. Both patients were GMFCS level II meaning they could ambulate independently without assistive devices. The parents of both patients were seeking advice on possible repeat FDRO after IHRG recurred following previous intervention(s). The primary goal of any further surgical intervention was to improve the internal foot progression angle and the cosmetic appearance of gait. Both patients had an initial gait analysis prior to any surgical intervention at age five and nine years respectively. The current, most recent analysis was carried out at ages 17 and 15 years respectively. Intervening analyses were carried out following any surgical intervention demonstrating initial, short-term improvement in hip rotation but these analyses are not included in this case report.

## Initial pre-operative analysis

### Gait analysis

Three-dimensional kinematic and kinetic data were captured using a 4 camera Codamotion cx1 active marker system (Charnwood Dynamics, Leicestershire, UK). Kinematic data were sampled at a rate of 200 Hz while force data were captured using two Kistler force plates at a sampling rate of 400Hz. Infrared markers were placed on each participant's lower limbs as per a modified Helen Hayes protocol (Kiernan *et al.*, 2016). Patient A demonstrated excessive internal rotation of the right hip while the left hip was more internal in Patient B. The hip kinematic graph comparing Patient A and Patient B at initial analysis demonstrates a similar degree and pattern of excessive internal hip rotation (Figure 1). Due to young age and reduced step-lengths kinetics were not collected at the initial analysis.

### Clinical examination

Hip internal and external rotation range of movement was measured in prone lying using a gravity-reference goniometer (Myrin). Femoral anteversion was estimated in the same position using the trochanteric prominence angle test (TPAT) (Davids *et al.*, 2002).

Hip abductor strength was assessed in side lying with the knee extended and the thigh in a neutral position in terms of flexion/extension. The limb was brought into abduction and the patient asked to hold the limb in this position while progressive manual resistance was applied. Strength was scored

out of a maximum of five using the modified Oxford grading (Dan *et al.*, 2014; Paternostro-Sluga *et al.*, 2008). Clinical examination data at first and last assessments are summarised in Table 1.

At initial assessment, both patients demonstrated increased internal hip rotation range versus external hip rotation range and decreased strength in the hip abductors. Patient B had significantly increased femoral anteversion value at initial

assessment compared to Patient A. Despite this, the dynamic hip internal rotation during gait was very similar (Figure 1) consistent with the previously reported findings that the correlation between static measure of femoral anteversion and hip rotation during gait is low (Braatz *et al.*, 2013; Lee *et al.*, 2013).

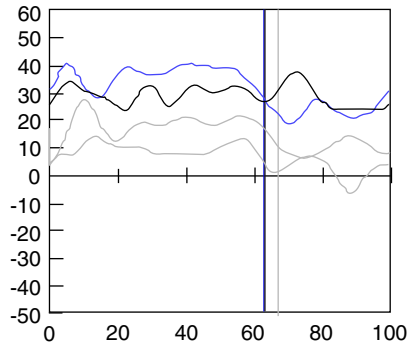
**Surgical intervention**

Patient A had a FDRO age 7 in combination with other orthopaedic procedures. The FDRO was repeated age 11 and at age 14 a surgical release of the anterior fibres of the gluteus medius was undertaken to attempt to correct the recurrent internal hip rotation. Patient B had one previous FDRO at age 11 with no additional soft-tissue releases. The current patient characteristics and past surgical histories are summarised in Table 2. In each case, post-operative gait analysis one year following intervention documented some short-term correction of IHRG but this pattern recurred in both patients (Figure 2).

**Current post-operative analysis**

**Gait analysis**

On review, current gait kinematics were compared to pre-operative gait patterns for both patients. In the case of Patient A there were 12 years between pre-operative analysis and current analysis and an interval of 5 years for Patient B. We found that the current post-operative degree and pattern of internal hip rotation were almost identical to their pre-operative data (Figure 3).



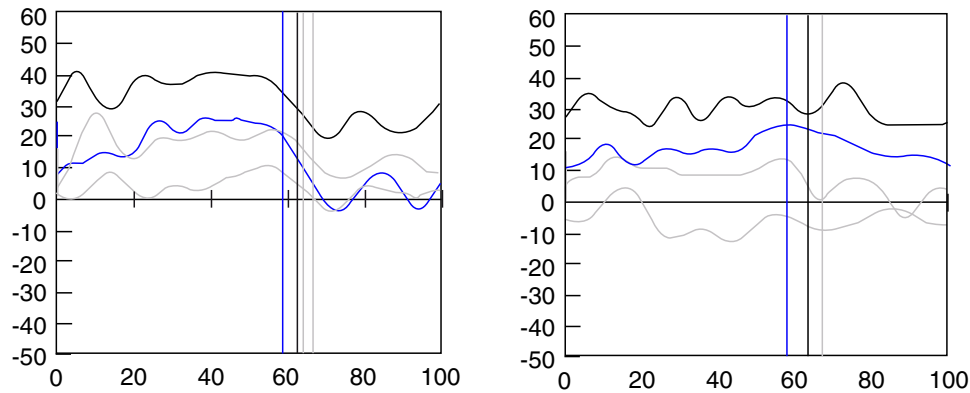
**Figure 1.** Hip rotation graphs at time of initial, pre-operative gait analysis comparing Patient A right leg-blue; Patient B left leg-black; Contralateral limbs in grey. X-axis shows percent gait cycle; Y-axis shows hip rotation (internal rotation positive; external rotation negative).

**Table 1.** Clinical examination values at first and last assessments.

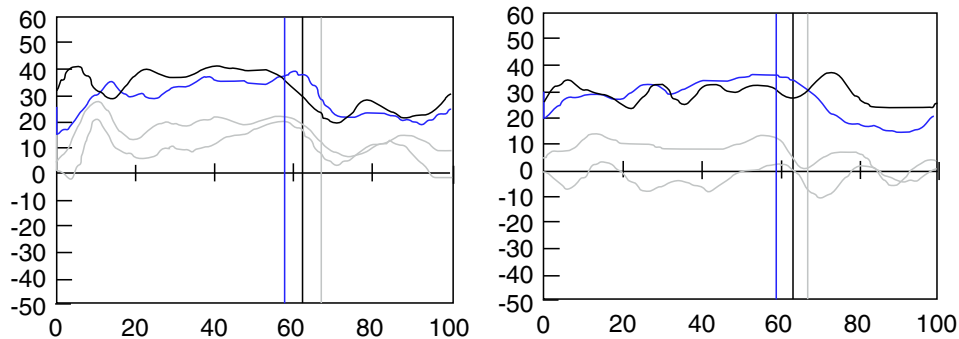
	Patient A		Patient B	
	Initial Assessment	Final Assessment	Initial Assessment	Final Assessment
Internal/External Hip Rotation (°)	80/10	75/0	95/0	80/10
Femoral Anteversion (°)	30	25	60	48
Hip Abductor Strength	3/5	3/5	4-/5	4-/5

**Table 2.** Current patient characteristics and relevant surgical and gait data.

Patient	Sex	Age at last analysis	Internally rotated Limb	Surgical History	Mean Hip Rotation in Stance (°)	Mean Hip Rotation in Swing (°)	Mean Ankle Plantar-flexion in Stance (°)	Trunk Lean	Reduced Hip Joint Impulse
A	F	16	Right	Age 7: Right FDRO, Right transfer of rectus femoris to gracillis, right medial hamstring lengthening, bilateral adductor release. FDRO Age 11: Right FDRO Age 14: Release of anterior fibres of gluteus medius	33.37	22.51	0.63	Yes	Yes
B	M	15	Left	Age 11: Left FDRO	31.26	22.54	1.27	Yes	Yes



**Figure 2.** Hip rotation graphs comparing pre and post-operative analysis for Patient A (left; femoral derotation osteotomy and soft-tissue releases) and Patient B (right; femoral derotation osteotomy). Post-operative analysis in blue; pre-operative data in black; contra-lateral pre and post-operative data in grey. X-axis of each graph shows percent gait cycle; Y-axis shows hip rotation (internal rotation positive; external rotation negative).



**Figure 3.** Hip rotation graphs comparing most recent gait analysis to pre-operative analysis for Patient A (left) and Patient B (right). Current analysis in blue; pre-operative data in black; contra-lateral pre and post-operative data in grey. X-axis of each graph shows percent gait cycle; Y-axis shows hip rotation (internal rotation positive; external rotation negative).

On current gait analysis, both displayed some of the recently reported risk factors for recurrence of IHRG, namely reduced hip joint impulse and dynamic ankle plantar-flexion in the absence of ankle contracture. In addition, on video analysis, both had a significant trunk lean to the internally rotated side during stance indicative of probable hip abductor lever arm dysfunction.

On over-laying both patients current gait kinematics we found that both had almost identical degrees and patterns of internal hip rotation and ankle plantar-flexion during gait (Figure 4 and Table 1). This was despite otherwise different kinematics at the pelvis, hip and knee, different patient characteristics and different histories of previous surgical intervention aimed at correcting IHRG.

The hip rotation pattern in both cases demonstrates progressive internal rotation occurring through stance phase following initial contact but a significant reduction in this internal hip rotation during swing phase. Consistent with the trunk lean and reduced hip joint impulse, this kinematic pattern further suggests

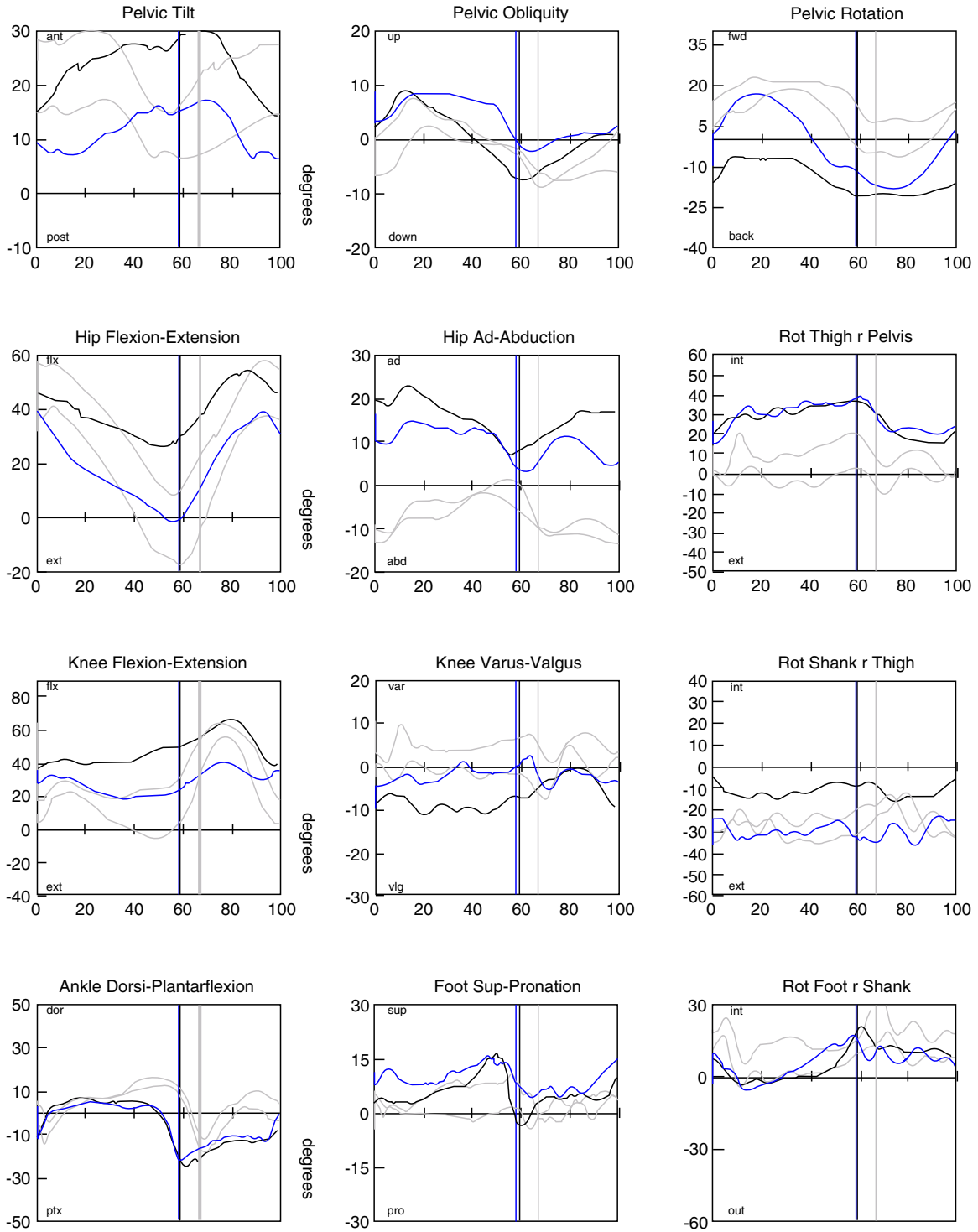
that the internal hip rotation is to compensate for hip abductor dysfunction as it occurs primarily when the stance phase limb is loaded but corrects when un-loaded during swing phase.

#### Clinical examination

Table 1 summarises the clinical examination findings at initial and final analysis. Despite surgical intervention, both patients continue to demonstrate significantly increased hip internal rotation versus external rotation. Femoral anteversion values have decreased compared to pre-operative values; however it must be highlighted that the reliability of the TPAT may be affected by the surgical intervention and subsequent alterations to the bony anatomy. Of note, neither patient demonstrated any change or improvement in hip abductor strength.

#### Discussion

Our case report agrees with the findings of Niklasch (Niklasch *et al.*, 2015b) that reduced hip joint impulse and ankle plantar-flexion during gait appear to predict recurrence of IHRG. In addition, this case report is the first report, that we are aware of,



**Figure 4.** Current gait kinematic graphs for Patient A right leg-blue; Patient B left leg-black; Contralateral limbs in grey. X-axis of each graph shows percent gait cycle; Y-axis shows angular displacement. Hip rotation (internal rotation positive; external rotation negative) and ankle dorsi/plantar flexion (dorsiflexion positive; plantarflexion negative) graphs circled.

to specifically compare the joint kinematic patterns both pre and post operatively within individual patients and also between separate patients. These comparisons show that despite documented short-term improvement post-operatively after a number of surgical interventions there was a recurrence to an almost identical position of hip rotation and ankle plantar-flexion in each case. Furthermore, it appears that the hip rotation and ankle plantar/dorsiflexion kinematic patterns were very similar between the two described cases.

The similarities suggest that this pattern is somehow preferential and possibly used to maximise hip abductor function. As far back as 1965, a cadaveric study found that rotation deformities of the femur represent the most efficient use of the hip abductors (Merchant, 1965). More recently, Arnold *et al.* (Arnold *et al.*, 1997) used musculo-skeletal modelling to suggest that 30° of internal hip rotation best restores hip abductor moment arm. This is very similar to the recurrent position of 31–34° seen in stance phase in these two patients. The relationship between ankle equinus and hip rotation has been reported in the literature (Brunner *et al.*, 2008). Therefore, we suggest that this position of ankle plantar-flexion during gait assists with passively internally rotating the hip.

This case report primarily presents the kinematic outcomes following surgery to address IHRG in two patients. While the similarities in hip rotation kinematics are notable, the conclusions that can be drawn from this case report are obviously limited. The findings suggest that more formal research studies on larger numbers specifically comparing kinematic patterns pre and post operatively is warranted to establish if this pattern is indeed predictive of recurrence of IHRG. Based on these preliminary findings we are now examining outcomes post FDRO in a larger group. Additionally, investigation into how this pattern develops pre-operatively is suggested as, if this internal rotation is to compensate for hip abductor dysfunction, it seems likely that growth and changes in body mass index may play a role.

In terms of our current clinical practice, the findings are consistent with previous work suggesting that in a cohort of those displaying IHRG an FDRO is not likely to offer a long-lasting solution, at least in isolation. It would appear that intervention should instead be targeted at improving hip abductor capacity but at present there is no consensus on either the cause of this hip abductor dysfunction or how best to address it. Surgery aimed at altering the pull of the hip abductor muscles has been proposed but only three studies have reported on this in CP (Cobeljić *et al.*, 2005; Joseph, 1998; Steel, 1980) all of which have very small patient numbers and none have reported outcome measures using gait analysis. Therefore, we feel that the evidence does

not currently exist for this intervention and so FDRO still offers the best potential for surgical correction of this gait pattern. However, while acknowledging the need for more formal research, we suggest that this gait kinematic pattern is a ‘red-flag’ for potential recurrence and this realistic possibility should be discussed with the relevant families. In addition, as hip abductor dysfunction is not addressed with FDRO we suggest specific focus on these muscle groups post-operatively and that a crutch or stick on the contra-lateral side be considered long-term post operatively to reduce the demand on the hip abductors and potentially reduce the need for recurrent internal hip rotation gait. Again though, future more formal research is needed to examine if these post-operative interventions preserve correction of IHRG.

## Conclusions

Our clinical case report highlights recurrent internal hip rotation gait in two individuals with CP despite surgical intervention(s). On specifically comparing the joint kinematic graphs we have shown that in these two case reports, the position of recurrent internal hip rotation and ankle plantar-flexion are very repeatable both within each case following surgical intervention and also between the two cases. This recurrent pattern appears to be consistent with an attempt maximize hip abductor function due to the unaddressed hip abductor weakness. While the conclusions that can be drawn from this case report are limited, we now suggest that this pattern is a potential ‘red flag’ prior to surgery which should only proceed after significant discussion on potential recurrence of IHRG. As hip abductor function is not addressed with a FDRO, post-operative rehabilitation should focus on this and a stick/crutch on the contra-lateral side may reduce the demand on the hip abductors and help preserve surgical outcomes. We suggest that more formal study on the kinematic pattern in recurrent internal hip rotation is warranted and based on this preliminary case report this work is on-going in our laboratory.

## Consent

Informed, signed consent for the use of anonymised gait analysis data was obtained from parents/guardians using our standard gait laboratory consent form and local institutional approval allows the use of such data.

## Data availability

All data underlying the results are available as part of the article and no additional source data are required.

## Grant information

The author(s) declared that no grants were involved in supporting this work.

## References

Arnold AS, Asakawa DJ, Delp SL: **Do the hamstrings and adductors contribute to excessive internal rotation of the hip in persons with cerebral palsy?** *Gait Posture*. 2000; 11(3): 181–190.  
[PubMed Abstract](#) | [Publisher Full Text](#)

Arnold AS, Delp SL: **Rotational moment arms of the medial hamstrings and**

**adductors vary with femoral geometry and limb position: implications for the treatment of internally rotated gait.** *J Biomech*. 2001; 34(4): 437–447.  
[PubMed Abstract](#) | [Publisher Full Text](#)

Arnold AS, Komattu AV, Delp SL: **Internal rotation gait: a compensatory mechanism to restore abduction capacity decreased by bone deformity.** *Dev*



*Med Child Neurol.* 1997; **39**(1): 40–44.

[PubMed Abstract](#) | [Publisher Full Text](#)

Braatz F, Wolf SI, Gerber A, *et al.*: **Do changes in torsional magnetic resonance imaging reflect improvement in gait after femoral derotation osteotomy in patients with cerebral palsy?** *Int Orthop.* 2013; **37**(11): 2193–2198.

[PubMed Abstract](#) | [Publisher Full Text](#) | [Free Full Text](#)

Brunner R, Dreher T, Romkes J, *et al.*: **Effects of plantarflexion on pelvis and lower limb kinematics.** *Gait Posture.* 2008; **28**(1): 150–156.

[PubMed Abstract](#) | [Publisher Full Text](#)

Carty CP, Walsh HP, Gillett JG, *et al.*: **The effect of femoral derotation osteotomy on transverse plane hip and pelvic kinematics in children with cerebral palsy: a systematic review and meta-analysis.** *Gait Posture.* 2014; **40**(3): 333–340.

[PubMed Abstract](#) | [Publisher Full Text](#)

Church C, Lennon N, Pineault K, *et al.*: **Persistence and Recurrence Following Femoral Derotational Osteotomy in Ambulatory Children With Cerebral Palsy.** *J Pediatr Orthop.* 2017; **37**(7): 447–453.

[PubMed Abstract](#) | [Publisher Full Text](#)

Cobeljić G, Bajin Z, Vukasinović Z, *et al.*: **[Medial rotation deformity of the hip in cerebral palsy: surgical treatment by transposition of gluteal muscles].** *Srp Arh Celok Lek.* 2005; **133**(1–2): 36–40.

[PubMed Abstract](#) | [Publisher Full Text](#)

Dan B, Paneth N, Rosenbloom L: **Cerebral Palsy: Science and Clinical Practice.** ed. M.M.: MacKeith Press. 2014.

[Reference Source](#)

Davids JR, Benfanti P, Blackhurst DW, *et al.*: **Assessment of femoral anteversion in children with cerebral palsy: accuracy of the trochanteric prominence angle test.** *J Pediatr Orthop.* 2002; **22**(2): 173–178.

[PubMed Abstract](#) | [Publisher Full Text](#)

Delp SL, Hess WE, Hungerford DS, *et al.*: **Variation of rotation moment arms with hip flexion.** *J Biomech.* 1999; **32**(5): 493–501.

[PubMed Abstract](#) | [Publisher Full Text](#)

Dreher T, Wolf SI, Heitzmann D, *et al.*: **Long-term outcome of femoral derotation osteotomy in children with spastic diplegia.** *Gait Posture.* 2012; **36**(3): 467–470.

[PubMed Abstract](#) | [Publisher Full Text](#)

Joseph B: **Treatment of internal rotation gait due to gluteus medius and minimus overactivity in cerebral palsy: anatomical rationale of a new surgical procedure and preliminary results in twelve hips.** *Clin Anat.* 1998; **11**(1): 22–28.

[PubMed Abstract](#) | [Publisher Full Text](#)

Kiernan D, Hosking J, O'Brien T: **Is adult gait less susceptible than paediatric**

**gait to hip joint centre regression equation error?** *Gait Posture.* 2016; **45**: 133–136.

[PubMed Abstract](#) | [Publisher Full Text](#)

Lee KM, Chung CY, Sung KH, *et al.*: **Femoral anteversion and tibial torsion only explain 25% of variance in regression analysis of foot progression angle in children with diplegic cerebral palsy.** *J Neuroeng Rehabil.* 2013; **10**: 56.

[PubMed Abstract](#) | [Publisher Full Text](#) | [Free Full Text](#)

MERCHANT AC: **HIP ABDUCTOR MUSCLE FORCE; AN EXPERIMENTAL STUDY OF THE INFLUENCE OF HIP POSITION WITH PARTICULAR REFERENCE TO ROTATION.** *J Bone Joint Surg Am.* 1965; **47**(3): 462–476.

[PubMed Abstract](#) | [Publisher Full Text](#)

Niklasch M, Dreher T, Doderlein L, *et al.*: **Superior functional outcome after femoral derotation osteotomy according to gait analysis in cerebral palsy.** *Gait Posture.* 2015a; **41**(1): 52–56.

[PubMed Abstract](#) | [Publisher Full Text](#)

Niklasch M, Wolf SI, Klotz MC, *et al.*: **Factors associated with recurrence after femoral derotation osteotomy in cerebral palsy.** *Gait Posture.* 2015b; **42**(4): 460–465.

[PubMed Abstract](#) | [Publisher Full Text](#)

O'Sullivan R, Walsh M, Hewart P, *et al.*: **Factors associated with internal hip rotation gait in patients with cerebral palsy.** *J Pediatr Orthop.* 2006; **26**(4): 537–541.

[PubMed Abstract](#) | [Publisher Full Text](#)

Oskoui M, Coutinho F, Dykeman J, *et al.*: **An update on the prevalence of cerebral palsy: a systematic review and meta-analysis.** *Dev Med Child Neurol.* 2013; **55**(6): 509–519.

[PubMed Abstract](#) | [Publisher Full Text](#)

Paternostro-Sluga T, Grim-Stieger M, Posch M, *et al.*: **Reliability and validity of the Medical Research Council (MRC) scale and a modified scale for testing muscle strength in patients with radial palsy.** *J Rehabil Med.* 2008; **40**(8): 665–71.

[PubMed Abstract](#) | [Publisher Full Text](#)

Schwartz MH, Rozumalski A, Novacheck TF: **Femoral derotational osteotomy: surgical indications and outcomes in children with cerebral palsy.** *Gait Posture.* 2014; **39**(2): 778–783.

[PubMed Abstract](#) | [Publisher Full Text](#)

Steel HH: **Gluteus medius and minimus insertion advancement for correction of internal rotation gait in spastic cerebral palsy.** *J Bone Joint Surg Am.* 1980; **62**(6): 919–927.

[PubMed Abstract](#) | [Publisher Full Text](#)

## Open Peer Review

Current Peer Review Status:  

---

### Version 2

Reviewer Report 30 January 2019

<https://doi.org/10.21956/hrbopenres.13967.r26494>

© 2019 Bennett D. This is an open access peer review report distributed under the terms of the [Creative Commons Attribution License](#), which permits unrestricted use, distribution, and reproduction in any medium, provided the original work is properly cited.



**Damien Bennett**

Public Health Agency, Belfast, Ireland

The authors have comprehensibly addressed all relevant suggestions.

**Competing Interests:** No competing interests were disclosed.

**Reviewer Expertise:** Bio-mechanical engineering, public health medicine

**I confirm that I have read this submission and believe that I have an appropriate level of expertise to confirm that it is of an acceptable scientific standard.**

Reviewer Report 30 January 2019

<https://doi.org/10.21956/hrbopenres.13967.r26495>

© 2019 de Moraes Filho M. This is an open access peer review report distributed under the terms of the [Creative Commons Attribution License](#), which permits unrestricted use, distribution, and reproduction in any medium, provided the original work is properly cited.



**Mauro César de Moraes Filho** 

Pediatric Orthopedic Surgeon, Gait Laboratory and Cerebral Palsy Clinic, AACD, São Paulo, Brazil

No further comments to make.

**Competing Interests:** No competing interests were disclosed.

**Reviewer Expertise:** Cerebral Palsy

**I confirm that I have read this submission and believe that I have an appropriate level of expertise to confirm that it is of an acceptable scientific standard.**



---

**Version 1**

Reviewer Report 17 January 2019

<https://doi.org/10.21956/hrbopenres.13962.r26460>

© 2019 Bennett D. This is an open access peer review report distributed under the terms of the [Creative Commons Attribution License](#), which permits unrestricted use, distribution, and reproduction in any medium, provided the original work is properly cited.

**Damien Bennett**

Public Health Agency, Belfast, Ireland

## Summary

- This useful exploratory/pilot work highlights the possibility that hip abductor lever arm dysfunction may be a risk factor for recurrence of internal hip rotation following femoral de-rotation osteotomy surgery.
- It is suggested that post-operative rehabilitation should focus on addressing hip abductor lever arm dysfunction to help preserve surgical outcomes.
- However, further work involving larger numbers of patients is required to test these hypotheses.

This a well-defined and well described study. The study highlights the risk of recurrence of internal rotation which will be very useful to patients, their families and for clinicians involved. The take home message seems to be that unaddressed hip abductor weakness is a risk factor for recurrence and the authors suggest post-operative rehabilitation targeting the hip abductors may help preserve surgical outcomes. However it needs to be clear that this is a pilot/exploratory piece of work and this should be clear from the title, abstract, limitations section and conclusions.

Some other points are outlined below:

1. The main risk is of bias will come from the authors presenting 2 cases – how were they chosen? Have the authors looked at previous “failures”?
2. The limitations of such a small number of patients needs to be highlighted to ensure that generalisability is not implied from just this study. A brief limitations section in the discussion to specifically emphasise these may be useful. This would make the conclusions more balanced.
3. Rates of 15-41% are referenced from other studies. Do the authors have estimates of failure rates for their institution?
4. The impact of age and growth at different ages would presumably also be important although may be difficult to quantify – perhaps a comment on this would be useful in the discussion.
5. Perhaps a larger study/analysis is already being considered? – If this is the case it would be useful to emphasise this in the conclusions or as future work.
6. Strength was scored out of a maximum of five using the modified oxford grading – give reference for the modified oxford grading system.
7. Figures - Figure 3. Patient B left leg-red – this should be black.
8. From the previous work referenced and this study it seems there are number of RFs for recurrence including slower walking speed, higher levels of spasticity, younger age, reduced hip joint impulse, increased ankle plantar-flexion and internal foot progression pre-operatively and now hip abductor dysfunction. The question is then which are the most important? It’s still likely that a case by case

approach will be taken, but it seems the case made is that hip abductor lever arm dysfunction is a key new factor. To help teams in this area – how can this be most easily identified? Can this be done just from the kinematic data as shown (as well as video analysis) or do hip moments need to be considered (also see below)?

9. The authors report “significant trunk lean and on video analysis” which suggests “probable hip abductor lever arm dysfunction”, but kinetic data is not presented here. I presume this was confirmed on hip ab/adduction moments? To demonstrate this to the reader would hip moment data be available and, if possible, would a still image be possible (assuming consent for this). Or perhaps clean force plate data was not available?

Some points re possible future work are outlined below:

1. The addition of an appropriate comparator group would be key to further work which could then assess both risk and protective factors for recurrence.
2. Regarding suggestions for a more comprehensive study this would ideally involve comparison between children who have similar gait differences and/or severity before surgery (and ideally similar characteristics such as age and possibly sex also...) and (1) had a good response to FDR Sx and those that (2) did not have a good response. The numbers here may be small, but a retrospective case control type study like this may be the only way to accurately determine what the risk factors for “failure” are.
3. Part of a possible larger study is whether post-operative rehabilitation does prevent recurrence – presumably there are a large number of children in whom recurrence does **not** occur and is post-operative rehabilitation in these children protective?

**Is the background of the cases’ history and progression described in sufficient detail?**

Yes

**Are enough details provided of any physical examination and diagnostic tests, treatment given and outcomes?**

Yes

**Is sufficient discussion included of the importance of the findings and their relevance to future understanding of disease processes, diagnosis or treatment?**

Partly

**Is the conclusion balanced and justified on the basis of the findings?**

Partly

**Competing Interests:** No competing interests were disclosed.

**Reviewer Expertise:** Bio-mechanical engineering, public health medicine

**I confirm that I have read this submission and believe that I have an appropriate level of expertise to confirm that it is of an acceptable scientific standard, however I have significant reservations, as outlined above.**

Author Response 21 Jan 2019

**Rory O’Sullivan**, Central Remedial Clinic, Dublin, Ireland

We thank the reviewer for the thorough and comprehensive review and note the suggestions for further research. Firstly we would like to highlight this is a case presentation of two patients who presented similarly following recurrence of internal hip rotation. This is certainly not intended as a formal study and we were careful not to use the term 'study' in our manuscript for that reason. Based on the reviewers comments we have made this distinction more obvious through-out the paper.

Based on this case series we are moving on to more formal research on this topic and the suggestions in this regard are all valid and extremely helpful.

A number of the suggestions made by the reviewer have been incorporated into the revised manuscript.

Answers to more specific points are questions are summarized below- (our response in italics)

Some other points are outlined below:

1. The main risk is of bias will come from the authors presenting 2 cases – how were they chosen? Have the authors looked at previous “failures”? *The two cases were patients we happened to present at an orthopaedic review meeting within our centre. I over-laid the graphs as presented and was struck by the similarity. So in essence they were not "chosen" but presented but we agree that to progress to more formal research we will need to look at a more complete series of "failures" to establish how common this pattern is.*
2. The limitations of such a small number of patients needs to be highlighted to ensure that generalisability is not implied from just this study. A brief limitations section in the discussion to specifically emphasise these may be useful. This would make the conclusions more balanced. *As mentioned above we have made clearer that this is a preliminary case report that we hope might stimulate more formal research and has done in our center.*
3. Rates of 15-41% are referenced from other studies. Do the authors have estimates of failure rates for their institution? *As yet, we do not have estimates for our failure rates but this is something we are now looking to document as part of more formal study.*
4. The impact of age and growth at different ages would presumably also be important although may be difficult to quantify – perhaps a comment on this would be useful in the discussion. *Definitely agree with this point. Preliminary work seems to suggest that this pattern, in some CP children, does appear to develop secondary to growth and increasing BMI which put increased demand on the hip abductors. We have added a comment to the discussion as suggested and it is something we are examining in more formal, follow-on research.*
5. Perhaps a larger study/analysis is already being considered? – If this is the case it would be useful to emphasise this in the conclusions or as future work. *Agree and have done.*
6. Strength was scored out of a maximum of five using the modified oxford grading – give reference for the modified oxford grading system. *Done*
7. Figures - Figure 3. Patient B left leg-red – this should be black. *Done*

8. From the previous work referenced and this study it seems there are number of RFs for recurrence including slower walking speed, higher levels of spasticity, younger age, reduced hip joint impulse, increased ankle plantar-flexion and internal foot progression pre-operatively and now hip abductor dysfunction. The question is then which are the most important? It's still likely that a case by case approach will be taken, but it seems the case made is that hip abductor lever arm dysfunction is a key new factor. To help teams in this area – how can this be most easily identified? Can this be done just from the kinematic data as shown (as well as video analysis) or do hip moments need to be considered (also see below)? *I don't think hip abductor dysfunction is newly presented in this paper as Niklash et al previously linked reduced hip joint impulse to recurrence. We agree that hip moments are useful in an individual assessment on a case by case basis. What we are suggesting, based on this preliminary report of these 2 patients, is that the kinematic pattern of approximately 30-degrees internal rotation in stance might potentially be indicative of hip abductor dysfunction as this degree on hip rotation has been shown to maximise abductor moment arm. However, more formal work is certainly required. I think that further work may highlight that CP walkers internally rotate for different reasons rather than being a homogeneous group e.g. some rotate to maximise hip abductor function and some probably just as a consequence of persistence of femoral anteversion for example. The treatment of each, and success of treatment, will depend on the cause.*
9. The authors report “significant trunk lean and on video analysis” which suggests “probable hip abductor lever arm dysfunction”, but kinetic data is not presented here. I presume this was confirmed on hip ab/adduction moments? To demonstrate this to the reader would hip moment data be available and, if possible, would a still image be possible (assuming consent for this). Or perhaps clean force plate data was not available? *It is correct that on a retrospective review of data, clean force plate data was not always available particularly in the data collected at a younger age. In the most recent analysis in each case, there was 'clean' force data and in both cases there was reduced hip joint impulse. We have not specifically included numbers or graphs of this in this case report as we feel it is beyond the scope of this preliminary report and the value to presenting 2 patients kinetic data in particular is probably questionable. For this reason, we have just highlighted it (and the trunk lean) in Table 2 but intend to examine this more formally.*

**Competing Interests:** No competing interests were disclosed.

Reviewer Report 07 January 2019

<https://doi.org/10.21956/hrbopenres.13962.r26458>

© 2019 de Moraes Filho M. This is an open access peer review report distributed under the terms of the [Creative Commons Attribution License](#), which permits unrestricted use, distribution, and reproduction in any medium, provided the original work is properly cited.



**Mauro César de Moraes Filho** 

Pediatric Orthopedic Surgeon, Gait Laboratory and Cerebral Palsy Clinic, AACD, São Paulo, Brazil

The case report is very interesting and provocative. I believe that the paper can bring some new information for the readers.

The Introduction is very well done and it provides a very good overview about the topic addressed for the readers.

I believe that there is a typing mistake in page 2 at Clinical Examination Section. Please, put Oxford in page 2 (section Clinical Examination) with the first "O" on capital letter.

Also, it would be very nice to include the short term analysis after surgical procedures showing some improvement after intervention in order to characterize the recurrence.

Finally, the Discussion is also very good and it stimulates further research about the same subject.

**Is the background of the cases' history and progression described in sufficient detail?**

Yes

**Are enough details provided of any physical examination and diagnostic tests, treatment given and outcomes?**

Yes

**Is sufficient discussion included of the importance of the findings and their relevance to future understanding of disease processes, diagnosis or treatment?**

Yes

**Is the conclusion balanced and justified on the basis of the findings?**

Yes

**Competing Interests:** No competing interests were disclosed.

**Reviewer Expertise:** Cerebral Palsy

**I confirm that I have read this submission and believe that I have an appropriate level of expertise to confirm that it is of an acceptable scientific standard.**

Author Response 21 Jan 2019

**Rory O'Sullivan**, Central Remedial Clinic, Dublin, Ireland

We thank the reviewer for the helpful review and comments. The highlighted typing error has been corrected and a new figure has been added to the re-submitted manuscript to document the temporary improvement in hip internal rotation following surgery.

The aim of this submitted case presentation was primarily to provoke thought on this important topic in ambulant cerebral palsy and potentially stimulate further research on the topic and we thank the reviewer for highlighting this in the review.

**Competing Interests:** No competing interests were disclosed.

