

Balloon dilatation of a benign biliary stricture through a T-tube tract

Pankaj Gupta, Naveen Kalra, Ajay Kumar, Rakesh Kochhar¹, Vikas Gupta², Niranjan Khandelwal

Departments of Radiodiagnosis and Imaging, ¹Gastroenterology and ²General Surgery, Postgraduate Institute of Medical Education and Research, Chandigarh, India

Correspondence: Dr. Naveen Kalra, Additional Professor, Department of Radiodiagnosis and Imaging, Postgraduate Institute of Medical Education and Research, Chandigarh - 160 012, India. Email: navkal2004@yahoo.com

Abstract

Percutaneous cholangioplasty is a commonly performed procedure for both benign and malignant diseases. The most common route for accessing the biliary tree is transhepatic, following ultrasound or fluoroscopic-guided percutaneous puncture. There are situations when alternative routes can be utilized to access the common bile duct (CBD). We accessed the CBD via T-tube placed surgically in a 57-year-old man who had obstructive jaundice of obscure etiology which was likely inflammatory.

Key words: Balloon dilatation; cholangioplasty; T-tube

Introduction

A T-tube is commonly placed following biliary surgery. Cholangiograms through this route are frequently performed to assess the biliary tree prior to removing the T-tube and discharging the patients from hospital. However, utilization of T-tube for percutaneous cholangioplasty has been described in a few case reports only.^[1,2]

Case Report

A 57-year-old male presented with acute epigastric pain and decreased urine output. The pain was mild-to-moderate in severity, intermittent, with occasional vomiting. There was no radiation of pain, and the patient had little relief with analgesics. The patient had decreased urine output over the past 24 h. He was a chronic smoker. There was no past history of diabetes mellitus, hypertension, or tuberculosis. There was no past surgical history. On examination, there was mild pallor. Mild tenderness was elicited in

the right upper quadrant. Hemogram revealed a low platelet count (14,000/ μ l). There was mild elevation of liver enzymes [aspartate transaminase (AST) 87 IU/l, alanine transaminase (ALT) 95 IU/l, alkaline phosphatase 198 IU/l] and serum bilirubin (1.5 mg/dl). Renal function tests were within normal range.

Abdominal USG (iU22 \times MATRIX, Philips, Best, Netherlands) revealed echogenic contents within gallbladder (GB) lumen. Common bile duct (CBD) was prominent (8 mm). There was no intrahepatic biliary radical (IHBR) dilatation and the pancreas was normal. A magnetic resonance cholangiography (MAGNETOM[®] Aera, Siemens, Erlangen, Germany) was performed that revealed mild dilatation of CBD and intrahepatic biliary radicles [Figure 1]. No filling defects were noted within the CBD. GB was normal. There was worsening of the abdominal pain over the ensuing few days associated with progressive elevation of conjugated bilirubin (7.5 mg/dl). Endoscopic retrograde cholangiography (ERCP) was performed. There was blood ooze seen at the papilla. However, cholangiogram did not reveal any filling defects. A naso-biliary drainage (NBD) tube was placed which resulted in decline of conjugated bilirubin to 4.4 mg/dl. Cholangiogram was performed through the NBD after 1 week, which revealed filling defects within the GB and CBD suggestive of blood clots.

Patient continued to deteriorate with a falling hemoglobin suggesting ongoing hemobilia. A vascular

Access this article online

Quick Response Code:



Website:
www.ijri.org

DOI:
10.4103/0971-3026.150133

cause [pseudoaneurysm or arteriovenous (AV) malformation] was suspected and computed tomography (CT) angiography (SOMATOM® Definition Flash, Siemens, Erlangen, Germany) and digital subtraction angiography (Allura Xper FD 10, Best, Netherlands) was performed. The vascular causes were ruled out. Finally, an exploratory laparotomy was performed. Cholecystectomy and CBD exploration was performed. No calculus or mass was detected within the CBD. Intraoperative cholangioscopy, however, revealed unhealthy mucosa at the confluence that was biopsied. A T-tube was left *in situ* to achieve continuous drainage. Subsequently, there was no hemobilia. Histopathologic examination of the tissue revealed only inflammation. There was improvement in patient's condition with falling levels in serum bilirubin. However, 4 weeks later, there was mild rise in the serum bilirubin as well as alkaline phosphatase.

A T-tube cholangiogram was performed. There were filling defects within the proximal CBD with no opacification of IHBR suggestive of an inflammatory stricture at or just beyond the confluence [Figure 2]. Cholangioplasty was planned through the T-tube tract under conscious sedation. A 0.035" guidewire was passed into the left ductal system across the stricture at the confluence. After removal of the T-tube, a 7F 35 cm sheath was inserted over the wire and advanced into

the biliary tree. Balloon dilatation was performed using a 10 mm diameter by 40 mm long angioplasty balloon (Advance®, ATB PTA dilatation catheter; Cook® Medical, Bloomington, IN, USA), inflated for 10 min. We also did cholangioplasty of the lower end of CBD as filling defects were seen in the proximal CBD on the T-tube cholangiogram suggesting distal stasis. Repeat balloon dilatation of the hilar stricture was done after 3 weeks. A temporary external drainage tube [12F percutaneous transhepatic biliary drainage catheter (PTBD catheter)] was placed with its tip just across the stricture, after each session of cholangioplasty. Cholangiography via the biliary catheter following the procedure revealed good opacification of the entire biliary tree [Figure 3]. The external biliary drainage catheter was finally removed 3 weeks after the second session of cholangioplasty. The procedure was successful, with no complications. Patient was followed with serial evaluation of serum bilirubin, alkaline phosphatase, and ultrasound examinations. At the last follow-up, i.e. 7 months after the procedure, the patient was asymptomatic.

Discussion

Various treatment options for benign biliary strictures include endoscopic sphincterotomy, percutaneous cholangioplasty/stenting, and surgical biliary enteric diversion.^[2] Percutaneous sphincterotomy is performed

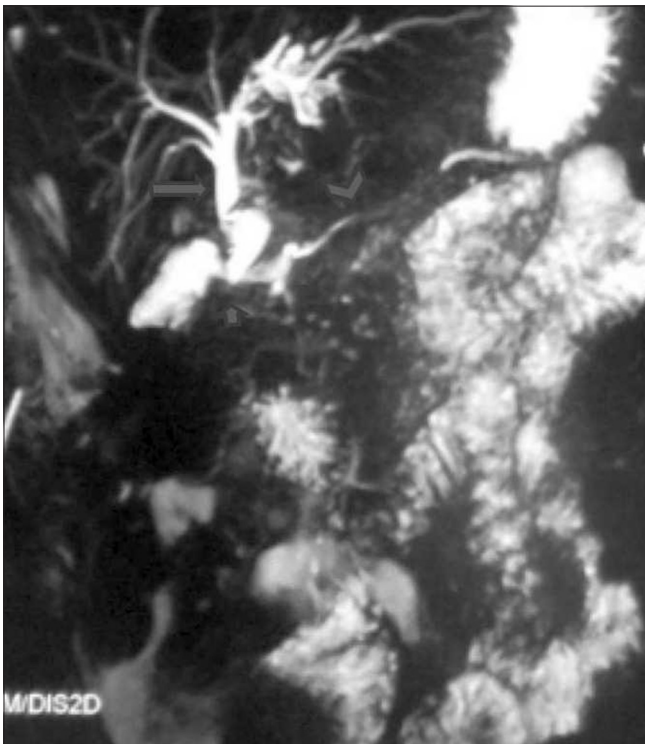


Figure 1: Thick slab magnetic resonance cholangiopancreatography (MRCP) image reveals mild dilatation of the entire common bile duct (CBD, arrow) with smooth distal tapering (short arrow). No filling defects are seen within the CBD. The main pancreatic duct is of normal calibre (arrowhead)

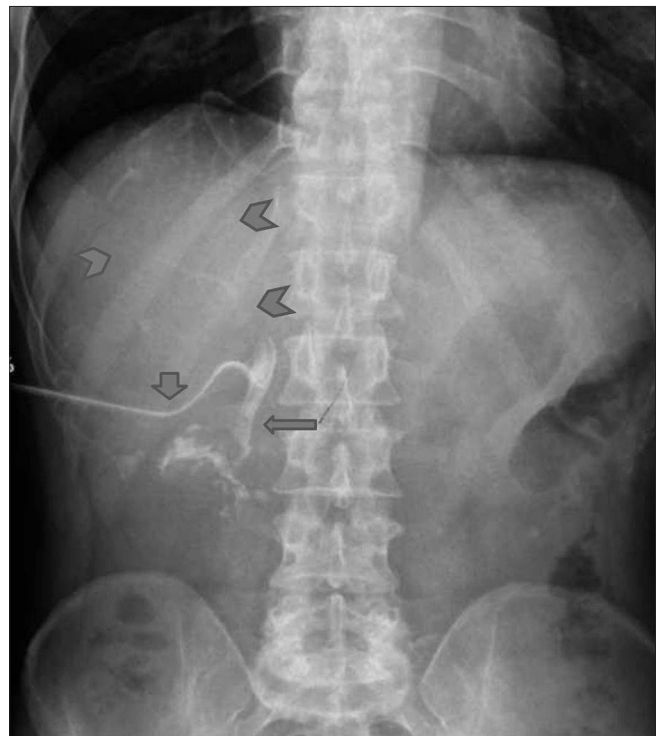


Figure 2: T-tube cholangiogram reveals lack of contrast opacification of the common hepatic duct and intrahepatic biliary radicles (arrowheads). Note the opacified CBD (arrow) and T-tube in situ (short arrow)

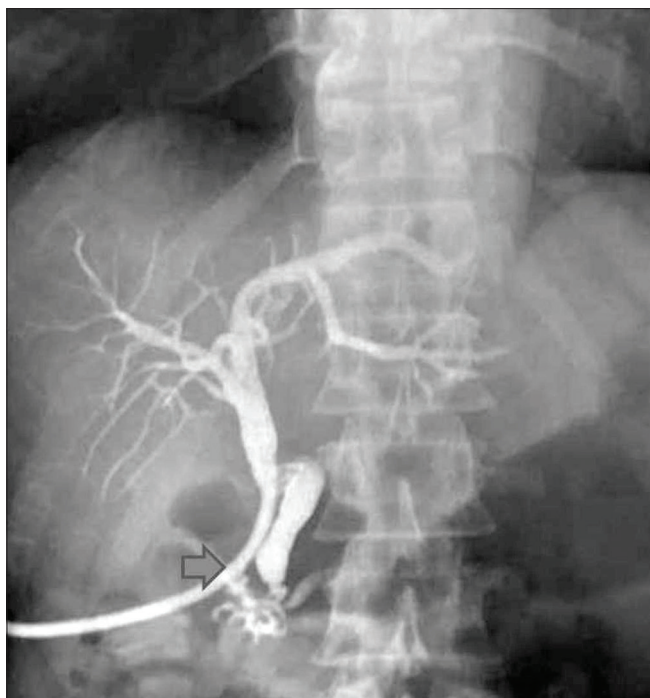


Figure 3: Cholangiogram performed through percutaneous transhepatic biliary drainage catheter (PTBD catheter, arrow) following balloon dilatation of stricture reveals good opacification of the entire biliary tree

for peri-ampullary stricture.^[3] Surgical diversion is best reserved for patients with anastomotic, extrahepatic, extra-pancreatic biliary stricture.^[4] Thus, in majority of patients, interventional radiology techniques in the form of percutaneous cholangioplasty/stenting are employed. However, a successful and long-term favorable outcome involves consideration of several important issues. Restenosis rates are high as these patients have a long expectancy of life. Cause of stricture (*viz.* traumatic, post-transplant, post-infective, etc.), site of stricture (*viz.* hilar, proximal or distal CBD, peri-ampullary), presence of any pre-existing access (*viz.* T-tube, PTBD, Hutson Russell loop), and length of stricture are all expected to have a bearing on the results of cholangioplasty.^[5]

Cholangioplasty involves dilatation of the stricture using a transluminal angioplasty balloon (balloon cholangioplasty/biliary balloon dilatation). The traditional route for this procedure is transhepatic.^[6] It involves access to the intrahepatic biliary radicles through percutaneous puncture, either under ultrasound guidance (when the ducts are dilated) or fluoroscopic guidance after obtaining a cholangiographic picture following a central puncture (when there is minimal ductal dilatation). Subsequently, the stricture is crossed using a guidewire. Two options follow: (a) placing an internal-external drain catheter and upgrading the catheter every 3 weeks to a larger caliber to dilate the tract or (2) balloon dilatation of the stenotic segment every 3 weeks, upsizing the balloon size every

session. Former approach leads to reduced quality of life and the external catheter is prone to infections.

Alternative access routes have been rarely described.^[7] When there is indication of repeated dilatations for biliary stenoses and endoscopic access is not available, a transjejunal approach has been described. In these cases, the dilatation is performed through the fixed limb (either afferent or efferent limb) of a Roux-en-Y hepaticojejunostomy. In this context, it is helpful to remember that the efferent limb of the Roux loop is attached to the peritoneum in the right anterior location and the afferent limb is fixed anteriorly in the central upper abdomen. Under fluoroscopic or CT guidance, the selected loop is punctured using a thin needle. Subsequently, the biliary tree is catheterized in a retrograde fashion and bilioplasty is performed. Fontein, *et al.*^[7] described their experience in 494 patients who were planned for cholangioplasty through the Roux loop. In 86% of the interventions, the Roux loop was successfully accessed.

Another potentially useful, yet a rarely described route for balloon dilatation, is the T-tube. T-tube is left in place following surgery for benign or malignant disease. In cholelithiasis with suspected choledocholithiasis, following CBD exploration, the T-tube is left in place to facilitate endoscopic treatment through the mature tract. T-tube placement is also performed in a difficult biliary-enteric anastomosis and extensive invasion of the distal bile duct. The basic technique of biliary balloon dilatation is similar to conventional percutaneous transhepatic route. A cholangiogram is obtained through the T-tube. Following detailed evaluation of the biliary anatomy, cholangioplasty is performed. Kim, *et al.*^[1] reported three cases of biliary stent placement through the T-tube. The cause of biliary obstruction in these cases was malignant disease process in the CBD or peri-ampullary region. The procedure was successful in all three cases and follow-up did not show recurrence of jaundice.

Conclusion

In conclusion, unconventional access routes for cholangioplasty constitute a viable treatment option for benign biliary strictures.

References

1. Kim JK, Kim HJ, Kim HK, Seo JJ, Park JG, Kang HK, *et al.* Percutaneous placement of biliary stent through T-tube tract. *Abdom Imaging* 1994;19:512-4.
2. Lillemoe KD, Pitt HA, Cameron JL. Current management of benign bile duct strictures. *Adv Surg* 1992;25:119-74.
3. Judah JR, Draganov PV. Endoscopic therapy of benign biliary strictures. *World J Gastroenterol* 2007;13:3531-9.
4. Braasch JW, Bolton JS, Rossi RL. A technique of biliary tract reconstruction with complete follow-up in 44 consecutive cases. *Ann Surg* 1981;194:635-8.

5. McAllister AJ, Hicken NF. Biliary stricture: A continuing study. *Am J Surg* 1976;132:567-71.
6. Mueller PR, van Sonnenberg E, Ferrucci JT Jr, Weyman PJ, Butch RJ, Malt RA, *et al.* Biliary stricture dilatation: Multicentre review of clinical management in 73 patients. *Radiology* 1986;160:17-22.
7. Fontein DB, Gibson RN, Collier NA, Tse G, Wang LL, Speer TG, *et al.* Two decades of percutaneous transjejunal biliary intervention

for benign biliary disease: A review of the intervention nature and complications. *Insights Imaging* 2011;2:557-65.

Cite this article as: Gupta P, Kalra N, Kumar A, Kochhar R, Gupta V, Khandelwal N. Balloon dilatation of a benign biliary stricture through a T-tube tract. *Indian J Radiol Imaging* 2015;25:21-4.

Source of Support: Nil, **Conflict of Interest:** None declared.