



# Right middle pulmonary vein classification by 3D-CT reconstruction and its clinical significance

Wenwei Wei<sup>1,2,3#^</sup>, Hang Zhou<sup>1#</sup>, Hao He<sup>1#</sup>, Hui Lin<sup>1</sup>, Yasmeen K. Tandon<sup>4</sup>, Timothy J. Jaykel<sup>4</sup>, Xiaofeng Chen<sup>1</sup>, Pei-Yuan Wang<sup>1</sup>, Shuo-Yan Liu<sup>1</sup>, Feng Wang<sup>1</sup>

<sup>1</sup>Department of Thoracic Oncology Surgery, Fujian Cancer Hospital, Clinical Oncology School of Fujian Medical University, Fuzhou, China;

<sup>2</sup>Fujian Key Laboratory of Translational Cancer Medicine, Fuzhou, China; <sup>3</sup>Fujian Provincial Key Laboratory of Tumor Biotherapy, Fuzhou, China;

<sup>4</sup>Department of Radiology, Mayo Clinic, Rochester, MN, USA

**Contributions:** (I) Conception and design: W Wei, H Zhou, H He; (II) Administrative support: F Wang, SY Liu; (III) Provision of study materials or patients: All authors; (IV) Collection and assembly of data: W Wei; (V) Data analysis and interpretation: W Wei; (VI) Manuscript writing: All authors; (VII) Final approval of manuscript: All authors.

<sup>#</sup>These authors contributed equally to this work.

**Correspondence to:** Shuo-Yan Liu, BS; Feng Wang, PhD. Department of Thoracic Oncology Surgery, Fujian Cancer Hospital, Clinical Oncology School of Fujian Medical University, No. 420 Fuma Road, Fuzhou 350014, China. Email: shuoyanliu2010@163.com; wfmd120@163.com.

**Background:** A profound understanding of the type of right middle lobe (RML) vein return is crucial for thoracic surgeons to ensure safe anatomic lung resection. In this study, the type of venous return in the RML and its clinical significance were analyzed using the 3D computed tomography (3D-CT) reconstruction technique.

**Methods:** This retrospective study analyzed the patients who underwent anatomical lobectomy or anatomical lung segment resection with preoperative 3D-CT reconstruction at the Department of Thoracic Oncology Surgery, Fujian Cancer Hospital from January 2020 to October 2022. The exclusion criteria were as follows: (I) blurred CT images and inadequate IQQA 3D reconstruction for clear visualization of bronchial and vascular subsegmental branches; (II) patients with a previous history of right middle lobectomy; (III) incomplete medical records.

**Results:** This study included 608 eligible cases, 245 males (40.30%) and 363 females (59.70%), with an average age of 58.61 years. We identified four major types of RML venous return, including 407 cases (66.94%) of central vein type, 123 cases (20.23%) of isolated vein type, 11 cases (1.81%) of basal vein type, and 67 cases (11.02%) of combined vein type. Furthermore, the central venous type comprised four subtypes: 191 cases (27.3%) had one branch, 165 cases (27.14%) had two branches, 43 cases (7.07%) had three branches, and 8 cases (1.32%) had more than three branches. The combined venous type includes four subtypes: combination type A (n=37 cases, 6.09%), combination type B (n=7 cases, 1.15%), combination type C (n=21 cases, 3.45%), and combination type D (n=2 cases, 0.33%).

**Conclusions:** Based on 3D-CT reconstruction, numerous types of venous return in the RML were found, highlighting the significance of 3D-CT reconstruction for thoracic surgeons. It plays a crucial role in understanding the type of RML venous return prior to surgery, providing invaluable information to ensure surgical safety and success.

**Keywords:** Right middle lobe (RML); venous return; 3D computed tomography (3D-CT)

Submitted Oct 07, 2023. Accepted for publication Dec 01, 2023. Published online Dec 14, 2023.

doi: 10.21037/jtd-23-1560

View this article at: <https://dx.doi.org/10.21037/jtd-23-1560>

<sup>^</sup> ORCID: 0009-0008-1162-7905.

## Introduction

According to the latest epidemiological survey report, lung cancer ranks second in incidence rate and first in mortality among all cancers (1). Currently, surgery is still the preferred treatment for early and middle stages non-small cell lung cancer (NSCLC) (2). With the wide application of computed tomography (CT), more and more early operable pulmonary nodules have been found (3), with a majority of these patients opting for anatomical lobectomy or sublobectomy. Since 1962, when Shimkin *et al.* (4) established lobectomy as the gold standard for radical treatment of lung cancer, this standard has been applied by thoracic surgeons. In recent years, segmentectomy has challenged lobectomy as the gold standard treatment method for radical lung cancer (5-8). Anatomical segmentectomy requires thoracic surgeons to have a deeper understanding of the anatomical structure of the lung. With the continuous development and improvement of 3D-CT technology, the high-quality 3D-CT technology has also been introduced into the field of thoracic surgery, contributing to the continuous maturity of anatomical segmentectomy of the lung.

The variable anatomy of pulmonary vessels (PVs) has consistently been a focal point of research in the field of cardiothoracic surgery, primarily due to the potential surgical complications posed by variant vessels. 3D-CT reconstruction has been proven to be an effective method

for detecting not only conventional lung anatomy but also abnormalities. With the extensive application and continuous advancement of 3D-CT reconstruction technology, a growing number of lung, bronchus, and vascular variations have been discovered and described (9-11). Although previous studies have addressed the dissection and variations of pulmonary veins (12-14), the incorporation of 3D-CT reconstruction techniques has led to a deeper understanding of pulmonary vein anatomy and variations. This study aims to demonstrate various types of right lung middle lobe venous return, utilizing 3D-CT reconstruction technology with precision in the field of thoracic surgery. The ultimate goal is to better assist thoracic surgeons in performing related operations. We present this article in accordance with the STROBE reporting checklist (available at <https://jtd.amegroups.com/article/view/10.21037/jtd-23-1560/rc>).

## Methods

### *Clinical data*

We conducted a retrospective analysis of patients with concurrent anatomical lobectomy or segmentectomy at the Department of Thoracic Oncology Surgery, Fujian Cancer Hospital from January 2020 to October 2022, who underwent 3D-CT reconstruction before surgery. A total of 636 eligible cases were initially identified; 28 cases were excluded and 608 cases were finally included (*Figure 1*). The basic clinical information of the patients is shown in *Table 1*. The exclusion criteria were as follows: (I) CT images were blurred and IQQA 3D reconstruction could not clearly show branches of bronchial and vascular subsegments; (II) previous history of right lung middle lobe resection; (III) incomplete medical records.

### *CT images and 3D-CT reconstruction*

Our hospital employs a 256-channel multilayer spiral CT (Philips, Tokyo, Japan) combined with 3D image reconstruction software IQQA (EDDA Technology, Princeton, NJ, USA) to obtain 3D reconstruction data. The patient laid supine on the spiral CT bed, raised his hands above head, and 50 mL of ioversol (Jiangsu Hengrui Pharmaceutical Co., Ltd., Lianyungang, China) was intravenously injected with a high-pressure syringe at a speed of 5 mL/s. Arterial and venous enhanced scans were performed within the lung scan range. The scanning

### Highlight box

#### Key findings

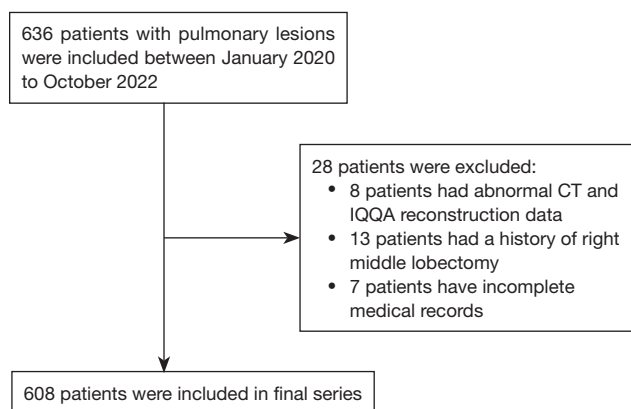
- This study identified four major patterns of the return of the middle lobe vein to the left atrium.

#### What is known and what is new?

- Although there have been previous studies describing partial types of right middle lobe (RML) venous return, these types were not analyzed for deep excavation.
- In this study, 3D computed tomography (3D-CT) reconstruction technique was introduced, which precisely demonstrated the multiple types of RML venous return characteristics. All common types of RML venous return were systematically analyzed, and summarized in order to better serve clinical practice.

#### What is the implication, and what should change now?

- The 3D-CT reconstruction technique can help the thoracic surgeon to better understand the anatomy of the RML vein and reduce surgical complications. Therefore, the clinical application of 3D-CT reconstruction technology should be strengthened.



**Figure 1** Flowchart of study population selection. CT, computed tomography.

**Table 1** Baseline and clinicopathological characteristics of cases (n=608)

Characteristics	N (%)
Gender	
Male	245 (40.30)
Female	363 (59.70)
Average age (years)	58.61
Histologic diagnosis	
AIS	51 (8.39)
MIA	201 (33.06)
IAC	216 (35.53)
SCC	48 (7.89)
Other cancer	10 (1.64)
Benign	82 (13.49)

AIS, adenocarcinoma in situ; MIA, minimally invasive adenocarcinoma; IAC, invasive adenocarcinoma; SCC, squamous cell carcinoma.

parameters were as follows: tube voltage 120 V, tube current 150 mA, reconstruction layer thickness 0.6 mm, layer spacing 1 mm, and pulmonary artery CT angiography was completed. The scanned data were imported into the IQQA system, where 3D reconstruction was conducted to ultimately form a 3D image. The software automatically identifies the pulmonary structures and reconstructs the 3D pulmonary structures of the bronchial tree, arteries, and veins. A few differences between the reconstructed structure and 2D CT images were manually reconciled. After reconstruction, the data were saved as still images and dynamic videos.

### Nomenclature of venous branches

In this study, the naming of the right middle lobe (RML) vein and its subsegmental vein branches are based on the two books: *Illustrated Anatomical Segmentectomy for Lung Cancer* by Nomori and Okada (15) and *Atlas of Thoracoscopic Anatomical Pulmonary Subsegmentectomy* by Chen *et al.* (16). The RML vein and its subsegmental vein are named as follows: the RML vein consists of the lateral segmental vein (V4) and the medial segmental vein (V5). V4 is composed of the intersubsegmental vein (V4a) and the intersegmental vein (V4b). V5 consists of the intersubsegmental vein (V5a) and the intrasubsegmental or interlobar vein (V5b). V4a is an intersubsegmental vein, which runs between the lateral subsegment (S4a) and the medial subsegment (S4b). V4b is an intersegmental vein, which runs between the medial subsegment (S4b) and the inferior subsegment (S5b). V5a is an intersubsegmental vein, which runs between the superior subsegment (S5a) and the inferior subsegment (S5b). V5b is an intrasubsegmental vein or interlobar vein, which runs below the inferior subsegment (S5b) or between the inferior subsegment (S5b) and the medial basal segment (S7).

### Statistical analysis

All statistical analyses were conducted using SPSS 22.0 software (IBM Corp., Armonk, NY, USA). Frequency and percentage calculation of each categorical variable were performed.

### Ethical statement

This study was conducted in accordance with the Declaration of Helsinki (as revised in 2013). It was approved by the Ethics Committee of Fujian Cancer Hospital, Clinical Oncology School of Fujian Medical University (No. K2022-017-01), and the requirement for individual informed consent was waived for this retrospective analysis.

### Results

In total, 608 patients who underwent anatomical lobectomy or segmentectomy at the Department of Thoracic Oncology Surgery, Fujian Cancer Hospital from January 2020 to October 2022 were included in this study. All patients underwent 3D reconstruction before surgery. Of these, 245 (40.30%) were males and 363 (59.70%) were females, with an average age of 58.61 years. The postoperative pathology

revealed 51 cases (8.39%) of adenocarcinoma in situ (AIS), 201 cases (33.06%) of minimally invasive adenocarcinoma (MIA), 216 cases (35.53%) of invasive adenocarcinoma (IAC), 48 cases (7.89%) of squamous cell carcinoma (SCC), 82 cases (13.49%) of benign lesions, and 10 cases (1.64%) of other types of cancer. Specific baseline and clinicopathological information of the included cases are shown in *Table 1*.

### Types of RML pulmonary venous return

We identified four major patterns of venous return from the RML to the left atrium (LA) (*Table 2*). There were 407 cases (66.94%) of central vein type, in which the RML vein completely reflows into the right superior central vein (*Figure 2A*). There were 123 cases (20.23%)

of isolated vein type, in which the RML vein completely independent reflows into the LA (*Figure 2B*). There were 11 cases (1.81%) of basal vein type, in which the RML veins completely reflow into the basal vein (*Figure 2C*). There were 67 cases (11.02%) of combination vein type, in which the RML vein reflows from two or more of the other three types in random combinations or other rare combinations finally common return into the LA (*Figure 2D*).

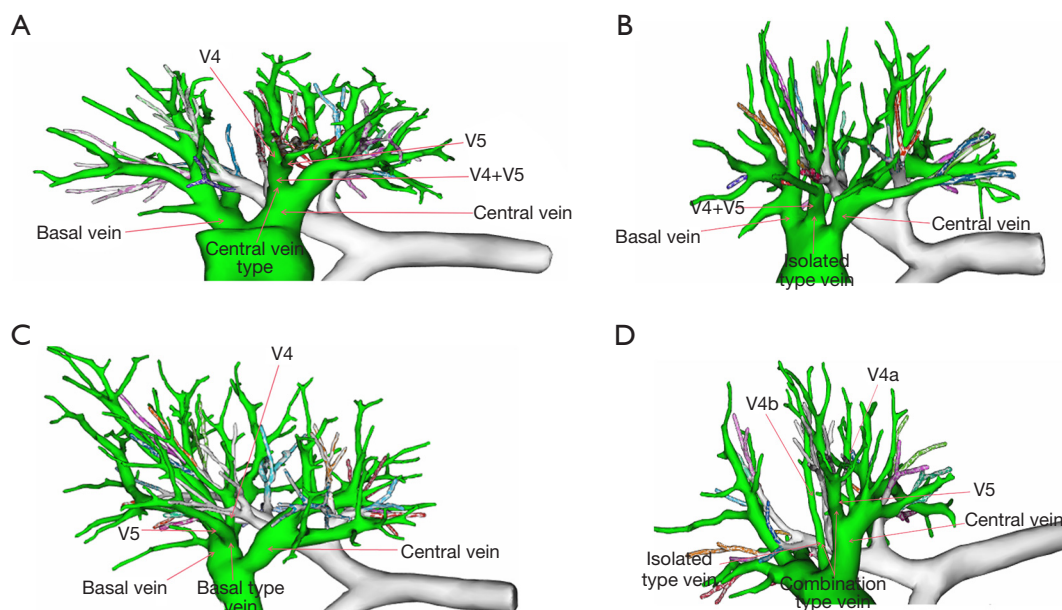
### Branch vein subtypes

The central vein type in this study encompasses four subtypes (*Table 3*). The 1-branch type involves the co-stem formation of V4 and V5 (V4+V5) that merged into the central vein (*Figure 3A*), of which there were a total of 191 cases, accounting for 27.3% of this study and 46.93% of this subtype. The 2-branch type consists of the right middle lung vein draining from two branch veins into the central vein in 165 cases, making up 27.14% of this study and 40.54% of the central vein type. The 2-branch type mainly includes: (I) the right middle lung vein with V4 and V5 independently flowing into the central vein (V4, V5). There were 62 cases of this presentation (*Figure 3B*), accounting for 10.20% in this study, 15.23% of the central vein type, and 37.58% of the 2-branch type. (II) the right middle lung vein with V4+V5b and V5a independently flowing into

**Table 2** Types of RML pulmonary venous arrangement (n=608)

Type of vein	N (%)
Central vein type	407 (66.94)
Isolated vein type	123 (20.23)
Basal vein type	11 (1.81)
Combination vein type	67 (11.02)

RML, right middle lobe.



**Figure 2** Three-dimensional reconstruction of four major patterns of venous return from the right middle lung to the left atrium.

**Table 3** Subtypes vein of the central vein type

Subtypes vein of the central vein type (n=407)	Number of cases	Proportion of the study	Proportion of the central vein type	Proportion of two/three-branch type
One branch type	191	27.30%	46.93%	–
V4+V5	191	27.30%	46.93%	–
Two-branch type	165	27.14%	40.54%	–
V4, V5	62	10.20%	15.23%	37.58%
V4+V5b, V5a	52	8.55%	12.78%	31.52%
V4a, V4b+V5	33	5.43%	8.11%	20.00%
V4a+V5a, V4b+V5b	18	2.96%	4.42%	10.91%
Three-branch type	43	7.07%	10.57%	–
V4, V5a, V5b	6	0.99%	1.47%	13.95%
V4a, V4b+V5b, V5a	37	6.09%	9.09%	86.05%
Over three-branch type	8	1.32%	1.97%	–
V4a, V4b, V5a, V5b	8	1.32%	1.97%	–

the central vein (V4+V5b, V5a). There were 52 cases of this presentation (*Figure 3C*), accounting for 8.55% in this study, 12.78% of the central vein type, and 31.52% of the 2-branch type. (III) the right middle lung vein with V4a and V4b+V5 independently flowing into the central vein (V4a, V4b+V5). There were 33 cases of this presentation (*Figure 3D*), accounting for 5.43% of this study, 8.11% of the central vein type, and 20.00% of the 2-branch type. (IV) the right middle lung vein with V4a+V5a and V4b+V5b independently flowing into the central vein (V4a+V5a, V4b+V5b). There were 18 cases of this presentation (*Figure 3E*), accounting for 2.96% of this study, 4.42% of the central vein type, and 10.91% of the 2-branch type. The 3-branch type is characterized by the manifestation whereby the right middle lung vein drained from 3 branches into the central vein in 43 cases, accounting for 7.07% of this study, and 10.57% of the central vein type. The 3-branch type mainly includes: (I) the right lung middle lung vein with V4, V5a, and V5b independently flowing into the central vein (V4, V5a, V5b) (n=6 cases, *Figure 3F*), accounting for 0.99% of this study, 1.47% of the central vein type, and 13.95% of the 3-branch type; (II) the right lung middle lung vein with V4a, V4b+V5b, and V5a independently flowing into the central vein (n=37 cases, *Figure 3G*), accounting for 6.09% of this study, 9.09% of the central vein type, and 86.05% of the 3-branch type. The over 3-branch type refers to the right middle lung vein draining from more than 3 branches into the central vein (n=8 cases), for example, V4a, V4b,

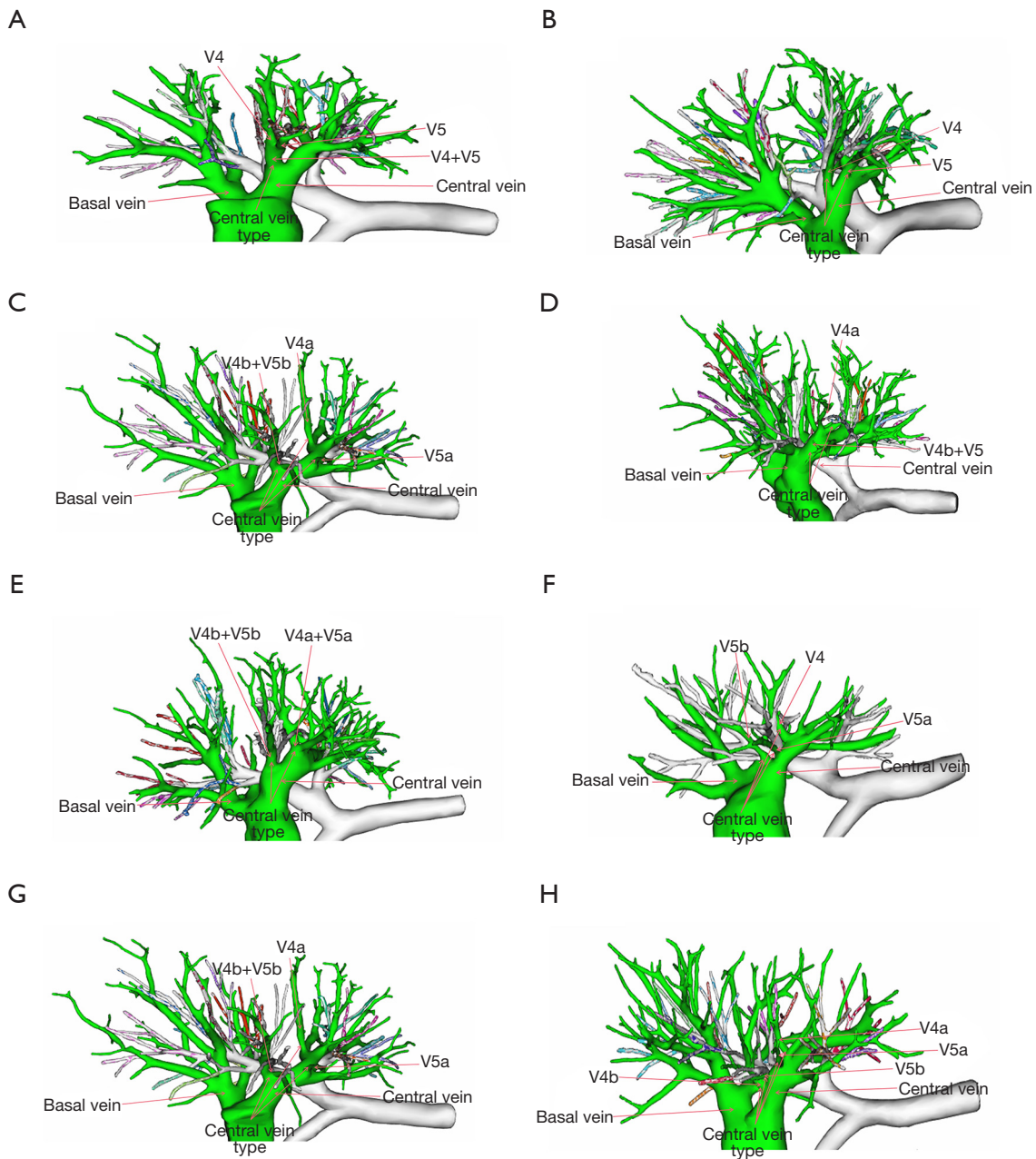
V5a, and V5b independently flowing into the central vein (*Figure 3H*), accounting for 13.2% of this study and 1.97% of the central vein type.

The combination vein type in this study comprises four subtypes (*Table 4*). The combination vein type A refers to two or more branch veins flowing back into the central vein and LA, respectively (*Figure 4A*), a total of 37 cases, making up 6.09% in this study and 55.22% of the combination vein type. The combination vein type B involves two or more branch veins flowing back into the basal vein and LA, respectively (*Figure 4B*), observed in a total of seven cases, accounting for 1.15% in this study and 10.45% in the combination vein type. The combination vein type C includes two or more branch veins flowing back into the basal vein and the central vein, respectively (*Figure 4C*), identified in a total of 21 cases, making up 3.45% in this study and 31.34% in the combination vein type. The combination vein type D refers to the irregular random combination of the middle vein and other non-middle veins flowing back into the LA through various ways, which was present in a total of two cases (*Figure 4D, 4E*), accounting for 0.33% of this study and 2.99% of the combination vein type.

## Discussion

The anatomy of the bronchus and lung blood vessels can be highly variable. Numerous articles (17-19) have shown





**Figure 3** Three-dimensional reconstruction of four subtypes of the central vein type.

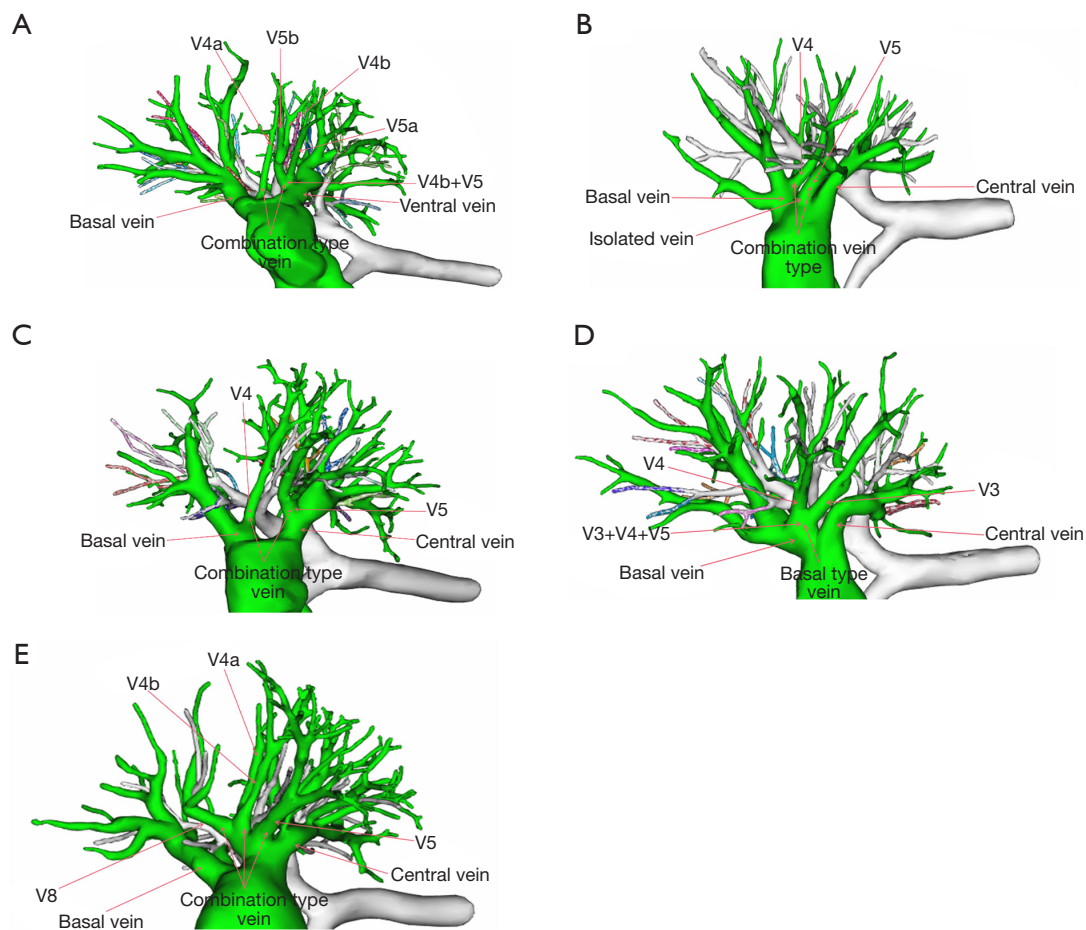
that the variation in lung anatomy poses a potential risk for thoracic surgeons performing anatomical lobectomy or segmentectomy, leading to the possibility of accidental intraoperative bleeding, pulmonary congestion, and even pulmonary infarction. Therefore, it is crucial for thoracic surgeons to have a thorough understanding of both routine and variant lung anatomy to safely perform anatomical lobectomy or segmentectomy. In recent years, with the rapid

advancement of medical technology, 3D-CT reconstruction technology has become widely utilized in thoracic surgery, providing assurance for thoracic surgeons to perform lung surgeries safely. The IQQA 3D reconstruction technology utilized by our center accurately locates the lesion nodules before surgery and enhance the anatomical structure of the lung from the 2D to the 3D, providing a comprehensive view of the anatomical structure without blind spots. This

**Table 4** Subtypes vein of the combination vein type

Subtypes vein of the combination vein type (n=67)	Number of cases (patients)	Proportion of the study	Proportion of the combination vein type
Type A	37	6.09%	55.22%
Type B	7	1.15%	10.45%
Type C	21	3.45%	31.34%
Type D	2	0.33%	2.99%

Type A: two or more branching veins flow back to the central vein and LA. Type B: two or more branch veins flowing back into the basal vein and LA, respectively. Type C: two or more branch veins flowing back into the basal vein and the central vein, respectively. Type D: the irregular random combination of the middle vein and other non-middle veins flowing back into the LA through various ways. LA, left atrium.

**Figure 4** Three-dimensional reconstruction of four subtypes of the combination vein type.

technique not only delineates the tumor margin within 2 cm, but also provides precise information on the drainage basin and volume of each subsegment, enabling surgeons to make informed decisions about surgical methods. Additionally, 3D-CT reconstruction can dynamically display

blood vessels and bronchus reconstruction data in real-time during surgery, offering accurate navigation for surgeons performing anatomical lobectomy or segmentectomy.

Pulmonary vascularization occurs during the 5th week of gestation (20). At the end of development, there are usually

four collateral pulmonary veins, two right pulmonary veins, and two left pulmonary veins returning together into the LA (21,22). However, there are significant individual differences in the anatomy of the pulmonary veins. Direct drainage of the pulmonary vein branches alone leads to increased openings into the LA, and the way that the right middle lung vein flows back into the LA is the key factor causing the difference.

In this study, assisted by 3D reconstruction technology of IQQA, the common and rare right lung middle venous reflux modes were analyzed and comprehensively summarized. While some earlier articles (20,23-25) have described the pattern of the RML pulmonary venous return, the descriptions were not comprehensive. A thorough description of the type of venous return in the middle lobe of the right lung in this article is also rare in other literature. Although Nagashima *et al.*'s study (26) details the classification of the middle lobe vein of the right lung, it solely focuses on the simplistic categorization of refluxing into the middle lobe vein based on the number of vessels in the gyrus. In our study, we not only graded refluxing vessels in the right pulmonary vein but also incorporated various route combinations of these vessels. The comprehensive classification of four major types of RML venous return in this study will empower clinicians with a deeper understanding of the anatomy of the RML vein. The reason for this may be attributed to limitations in development at that time, absence of effective 3D-CT reconstruction technology, or the diverse nature of the RML pulmonary venous return mode. In this study, assisted by 3D-CT reconstruction technology of IQQA, it was discovered that there were four main types of the RML pulmonary venous return, 407 cases (66.94% of this study) of the central vein type, which was higher than that described in the article by Rajeshwari and Ranganath (53.8%) (13), 123 (20.23%) of the isolated vein type was similar to 26.9% described by Rajeshwari and Ranganath (13), 11 (1.81%) of the basal vein type in the present study, which was present at a significantly lower frequency than in Rajeshwari's study [11.53% (13)], and 67 (11.02% of this study) of the combination vein type. Among the four main types of venous return, we found that subtypes existed in some types. Specifically, the central vein type (Table 3) and the combination vein type (Table 4) each contain four subtypes, which have not been thoroughly addressed in other articles. Additionally, we identified two cases (0.33% of this study) of very rare variants of the combination vein type,

which had not been previously described in the literature. However, Tekbas *et al.* (25) described approximately 82.6% of the combination vein type and 11.8% of the independent vein type in some articles (24,25,27). Yamashita (27) found about 4.8% of the basal vein type, with these figures differing slightly from our study. The discrepancy may be due to their lack of subdivision of the combination vein type, and direct generalization into the other three types. Therefore, conducting in-depth classification research is essential for a comprehensive understanding of the types of right middle lung vein return. Guided by 3D-CT reconstruction technology, thoracic surgeons gain a thorough understanding of the anatomy of the right middle pulmonary vein in patients preoperatively, enabling them to assess the type of venous return, reduce or avoid the intraoperative leakage or mistargeting of veins, and minimize associated surgical complexities. In real-world surgery, the type of RML venous return can be complex and varied, potentially causing interference during intraoperative targeting of disconnected veins, especially in cases of thoracic adhesion and underdeveloped lung fissure. The diversification of the types of venous return in the middle lobe of the right lung necessitates that thoracic surgeons develop an understanding of the anatomical lung structure. Intraoperative and postoperative complications may occur if the surgeon lacks knowledge or understanding of venous return type in the middle of the right lung during right lung surgery (17). Especially when the fissure is hypoplastic, it is crucial to know the type of venous return in the middle lobe of the right lung before surgery. In clinical practice, when the pulmonary fissure is hypoplastic, proportion of pulmonary trans-fissure veins can be as high as 82.26%, with a significantly higher occurrence on the right lung (80.65%) compared to the left lung (11.94%) (28). In cases of a hypoplastic pulmonary fissure and presence of a trans-fissure vein, the branches of the middle lobe vein and the branches of the superior lobe vein are often mistaken, which may lead to inadvertent injury during surgical procedures involving the right upper lobe or middle lobe. Specifically, in situations where the middle portal vein (MPV) is of central vein type and multi-branch, it is frequently mistaken as V4a being V2t or V2c, and V4b+V5b or V5a being V2c or V3b, resulting in incorrect or missed disconnection. Xu *et al.* (28) reported that the likelihood of V3b becoming the intersegmental vein in the right upper lobe and RML of the lung was 58.4%. Consequently, in cases where the MPV is the central vein type and multi-branch, the risk of



accidental injury of V3b will be higher. Furthermore, when the MPV is of the basal vein type, it is a higher probability of mistaking the MPV for a branch of inferior pulmonary vein (IPV), potentially resulting in accidental injury or disconnection. Similarly, when the MPV is of combination vein type, there is a higher risk of mistaking the branches of the MPV for those of superior pulmonary vein (SPV) or IPV branches, leading to accidental injury, misdiagnosis, or incomplete disconnection. In this study, we also identified two cases (0.33% of this study) of rare venous assemblage, a variation not previously reported in the literature. In one case, V3 and the right middle lung vein were drained into the basal trunk vein together (*Figure 4D*). This particular combination increases the likelihood of misidentifying V3 as one of the branches of the right middle lung vein, resulting in misdiagnosis or surgical leakage. In the other case, V8 and the right middle lung vein share the central trunk vein (*Figure 4E*). This combination makes it easy to misdiagnose or misconnect V8 as a branch of the right middle lung vein. Such errors may lead to accidental bleeding, pulmonary congestion, or even serious pulmonary infarction. Post-operatively, obstruction of venous return or poor return, along with the formation of thrombosis of narrow blood vessels can exacerbate compromised return, leading to pulmonary congestion, hemoptysis, or pulmonary embolism which may be serious and life-threatening. The incidence of these complications may be even higher in patients with hypoplasia of the fissure and the presence of trans-fissure veins or rare combination vein return. Sometimes the pulmonary vein return route to the heart may have other rare return routes due to the influence of the pulmonary artery bronchus. The return of the right middle pulmonary vein into the heart via the superior vena cava (SVC) is mentioned in the articles by Demir *et al.* and Najm *et al.* (29,30). Therefore, 3D-CT reconstruction before operation and understanding the type of the MPV return is one of the important factors for accurate anatomic lobectomy, segmental resection, and subsegmental resection of the lung and reducing the risk of surgery.

### Limitation

The limitations of this study include that it was a single-center retrospective study with a small sample size, only one 3D-CT reconstruction software was used in the study, and there may be other types and subtypes of the middle lobe of the right lung venous return. This article is a descriptive study lacking data on clinical complications.

### Conclusions

Through 3D-CT reconstruction technology, clinicians can accurately determine the type of venous reflux in the middle lobe of the right lung, reducing the occurrence of surgical complications.

### Acknowledgments

*Funding:* None.

### Footnote

*Reporting Checklist:* The authors have completed the STROBE reporting checklist. Available at <https://jtd.amegroups.com/article/view/10.21037/jtd-23-1560/rc>

*Data Sharing Statement:* Available at <https://jtd.amegroups.com/article/view/10.21037/jtd-23-1560/dss>

*Peer Review File:* Available at <https://jtd.amegroups.com/article/view/10.21037/jtd-23-1560/prf>

*Conflicts of Interest:* All authors have completed the ICMJE uniform disclosure form (available at <https://jtd.amegroups.com/article/view/10.21037/jtd-23-1560/coif>). The authors have no conflicts of interest to declare.

*Ethical Statement:* The authors are accountable for all aspects of the work in ensuring that questions related to the accuracy or integrity of any part of the work are appropriately investigated and resolved. This study was conducted in accordance with the Declaration of Helsinki (as revised in 2013). It was approved by the Ethics Committee of Fujian Cancer Hospital, Clinical Oncology School of Fujian Medical University (No. K2022-017-01), and the requirement for individual informed consent was waived for this retrospective analysis.

*Open Access Statement:* This is an Open Access article distributed in accordance with the Creative Commons Attribution-NonCommercial-NoDerivs 4.0 International License (CC BY-NC-ND 4.0), which permits the non-commercial replication and distribution of the article with the strict proviso that no changes or edits are made and the original work is properly cited (including links to both the formal publication through the relevant DOI and the license). See: <https://creativecommons.org/licenses/by-nc-nd/4.0/>.

## References

- Sung H, Ferlay J, Siegel RL, et al. Global Cancer Statistics 2020: GLOBOCAN Estimates of Incidence and Mortality Worldwide for 36 Cancers in 185 Countries. *CA Cancer J Clin* 2021;71:209-49.
- Pearson FG. Non-small cell lung cancer: role of surgery for stages I-III. *Chest* 1999;116:500S-3S.
- de Koning HJ, van der Aalst CM, de Jong PA, et al. Reduced Lung-Cancer Mortality with Volume CT Screening in a Randomized Trial. *N Engl J Med* 2020;382:503-13.
- SHIMKIN MB, CONNELLY RR, Marcus SC, et al. Pneumonectomy and lobectomy in bronchogenic carcinoma. A comparison of end results of the Overholt and Ochsner clinics. *J Thorac Cardiovasc Surg* 1962;44:503-19.
- Altorki NK, Wang X, Wigle D, et al. Perioperative mortality and morbidity after sublobar versus lobar resection for early-stage non-small-cell lung cancer: post-hoc analysis of an international, randomised, phase 3 trial (CALGB/Alliance 140503). *Lancet Respir Med* 2018;6:915-24.
- Kamigaichi A, Tsutani Y, Fujiwara M, et al. Postoperative Recurrence and Survival After Segmentectomy for Clinical Stage 0 or IA Lung Cancer. *Clin Lung Cancer* 2019;20:397-403.e1.
- Suzuki K, Saji H, Aokage K, et al. Comparison of pulmonary segmentectomy and lobectomy: Safety results of a randomized trial. *J Thorac Cardiovasc Surg* 2019;158:895-907.
- Abbas AE. Surgical Management of Lung Cancer: History, Evolution, and Modern Advances. *Curr Oncol Rep* 2018;20:98.
- He H, Chen P, Chen X, et al. Analysis of anatomical variations of the lingular artery of the left upper lobe using 3D computed tomography angiography and bronchography. *J Thorac Dis* 2021;13:5035-41.
- Shimizu K, Nagashima T, Ohtaki Y, et al. Analysis of the variation pattern in right upper pulmonary veins and establishment of simplified vein models for anatomical segmentectomy. *Gen Thorac Cardiovasc Surg* 2016;64:604-11.
- Zhou H, Wei W, He H, et al. A cross-sectional study: analysis of anatomical variation in the right upper lung intersegmental vein V2a based on a 3D reconstruction technique. *J Thorac Dis* 2022;14:4460-7.
- Arslan G, Dincer E, Kabaalioglu A, et al. Right top pulmonary vein: evaluation with 64 section multidetector computed tomography. *Eur J Radiol* 2008;67:300-3.
- Rajeshwari MS, Ranganath P. Variations in Draining Patterns of Right Pulmonary Veins at the Hilum and an Anatomical Classification. *Isrn Pulmonology* 2012. doi: 10.5402/2012/786549
- Fourdrain A, De Dominicis F, Bensussan M, et al. Three-dimensional computed tomography angiography of the pulmonary veins and their anatomical variations: involvement in video-assisted thoracoscopic surgery-lobectomy for lung cancer. *Folia Morphol (Warsz)* 2017;76:388-93.
- Nomori H, Okada M. Illustrated anatomical segmentectomy for lung cancer. Tokyo: Springer; 2012.
- Chen L, Zhu Q, Wu W. Atlas of thoracoscopic anatomical pulmonary subsegmentectomy. 1st Edition. Elsevier; 2023.
- Asouhidou I, Karaikos T, Natsis K. Pulmonary vein anatomical variation during videothoracoscopy-assisted surgical lobectomy. *Surg Radiol Anat* 2017;39:229-31.
- Polaczek M, Szaro P, Jakubowska L, et al. Pulmonary veins variations with potential impact in thoracic surgery: a computed-tomography-based atlas. *J Thorac Dis* 2020;12:383-93.
- Kandathil A, Chamarthy M. Pulmonary vascular anatomy & anatomical variants. *Cardiovasc Diagn Ther* 2018;8:201-7.
- Yazar F, Ozdogmus O, Tuccar E, et al. Drainage patterns of middle lobe vein of right lung: an anatomical study. *Eur J Cardiothorac Surg* 2002;22:717-20.
- Wannasopha Y, Oilmungmool N, Euathrongchit J. Anatomical variations of pulmonary venous drainage in Thai people: multidetector CT study. *Biomed Imaging Interv J* 2012;8:e4.
- Douglas YL, Jongbloed MR, Deruiter MC, et al. Normal and abnormal development of pulmonary veins: state of the art and correlation with clinical entities. *Int J Cardiol* 2011;147:13-24.
- Hof I, Chilukuri K, Arbab-Zadeh A, et al. Does left atrial volume and pulmonary venous anatomy predict the outcome of catheter ablation of atrial fibrillation? *J Cardiovasc Electrophysiol* 2009;20:1005-10.
- Subotich D, Mandarich D, Milisavljevich M, et al. Variations of pulmonary vessels: some practical implications for lung resections. *Clin Anat* 2009;22:698-705.
- Tekbas G, Ekici F, Tekbas E, et al. Evaluation of pulmonary vein variations in the middle pulmonary lobe with 64-slice multidetector computed tomography. *Eur*

- Rev Med Pharmacol Sci 2011;15:1395-400.
26. Nagashima T, Shimizu K, Ohtaki Y, et al. An analysis of variations in the bronchovascular pattern of the right upper lobe using three-dimensional CT angiography and bronchography. *Gen Thorac Cardiovasc Surg* 2015;63:354-60.
  27. Yamashita H. Variations in the pulmonary segments and the bronchovascular trees. *Roentgenologic anatomy of the lung*. Tokyo: Igaku-syoin; 1978:46-58.
  28. Xu W, Li Z, He Z, et al. Translobar Phenomenon of Pulmonary Veins and Its Clinical Significance in Lobectomy. *Zhongguo Fei Ai Za Zhi* 2021;24:99-107.
  29. Demir E, Aşkin M, Midyat L, et al. Scimitar syndrome associated with partial anomalous pulmonary venous draining into superior vena cava. *Eur J Pediatr* 2010;169:1263-5.
  30. Najm HK, Ahmad M, Salam Y, et al. Early Outcomes for In Situ Pericardial Roll Repair for Distant Anomalous Pulmonary Venous Return. *Ann Thorac Surg* 2021;111:169-75.

**Cite this article as:** Wei W, Zhou H, He H, Lin H, Tandon YK, Jaykel TJ, Chen X, Wang PY, Liu SY, Wang F. Right middle pulmonary vein classification by 3D-CT reconstruction and its clinical significance. *J Thorac Dis* 2023;15(12):6868-6878. doi: 10.21037/jtd-23-1560