



Contents lists available at ScienceDirect

International Journal of Surgery Case Reports

journal homepage: www.casereports.com

Successful treatment of hepatic gas gangrene by open drainage: A case report and review of the Japanese literature

Ryohei Ono, Hiroyuki Kashiwagi*, Jun Kawachi, Naoko Isogai, Katsunori Miyake, Takaaki Murata, Rai Shimoyama, Ryuta Fukai, Hidemitsu Ogino, Nobuaki Shinozaki

Department of Surgery, Shonan Kamakura General Hospital, Japan

ARTICLE INFO

Article history:

Received 1 March 2018

Received in revised form 6 April 2018

Accepted 15 June 2018

Available online 30 June 2018

Keywords:

Hepatic gas gangrene

Laparotomy drainage

Non-clostridial

Post biliary surgery

Hyperbaric oxygen therapy

ABSTRACT

INTRODUCTION: Liver gas gangrene is rare and has a low prognosis. This case, reports a successful treatment of hepatic gas gangrene using an open drainage technique, followed by antibiotics and hyperbaric oxygen therapy (HBO).

PRESENTATION OF THE CASE: An 82-year-old male with a history of left hepatectomy and bile duct resection for hilar cholangiocarcinoma presented with chilling, lethargy and dyspnea. He had a history of diabetes mellitus, hypertension, atrial fibrillation, and angina pectoris. Physical examination revealed sclerotic icterus, right hypochondrium tenderness and percussion tenderness of the liver, with warm extremities. Laboratory findings revealed leukocytosis and increased levels of hepatobiliary enzymes. A computed tomography (CT) scan showed gas accumulation in an S8 lesion with portal vein gas. Percutaneous drainage was performed immediately, and broad-spectrum antibiotics were started, but the drainage was insufficient. Consequently, laparotomy drainage was carried out, followed by HBO. No abscess was detected at one-year of follow-up.

DISCUSSION: Hepatic gas gangrene progresses rapidly and has a high mortality rate. Malignant disease and diabetes mellitus may be predisposing factors. While half of non-clostridial cases survive, most cases of hepatic gas gangrene are associated with clostridial infection and have a fatal outcome.

CONCLUSION: All survival cases of hepatic gas gangrene were treated by laparotomy drainage, thus immediate laparotomy seems essential to prevent a fatal outcome.

© 2018 The Author(s). Published by Elsevier Ltd on behalf of IJS Publishing Group Ltd. This is an open access article under the CC BY-NC-ND license (<http://creativecommons.org/licenses/by-nc-nd/4.0/>).

1. Introduction

Hepatic gas gangrene is a rare and is associated with a high mortality rate. Infection by anaerobic bacteria spreads rapidly to the liver parenchyma, leading to desmoplastic air accumulation in liver. Gas gangrene typically occurs after surgery, trauma, or of skin and soft tissue infection [1]. It may be associated with clostridium or non-clostridium infection, although a clostridial cause has been reported in most cases. Recently, increasing numbers of non-clostridial cases have been reported [2,3]. Development of this dreadful disease is associated with host conditions such as malignancy and immunosuppression. We report a case of successful treatment of hepatic gas gangrene by emergent open drainage combined with appropriate antibiotics and hyperbaric oxygen therapy and discuss the etiology with other cases reported in Japan. The work in this case has been reported in line with the SCARE criteria [4].

2. Case presentation

An 82-year-old Japanese male presented with a one day history of dyspnea and a one week history of chilling and lethargy. Three months previously, the patient underwent biliary surgery with liver resection for hilar cholangiocarcinoma. His post-operative course was uneventful and he was discharged without any complications on the 14th post-operative day (POD). His medical history includes diabetes mellitus, hypertension, atrial fibrillation, and angina pectoris, and he was taking medications for these conditions. His family history was unremarkable. On arrival, his consciousness was clear but he was slightly drowsy. His blood pressure, pulse, body temperature, and respiratory rate were 105/74 mmHg, 101 beats/min, 36.8 °C and 22/min, respectively. Physical examination revealed icterus of his eyes and right hypochondrium tenderness. His extremities were warm. Laboratory findings revealed elevated C-reactive protein and leukocytosis. Serum hepato-biliary enzymes and total bilirubin were also elevated (Table 1). A computed tomography (CT) scan showed a massive gas attenuation, 48 mm × 46 mm in size, in the anterior segment of the liver. Portal gas could be seen around it (Fig. 1). Liver gas gangrene was diagnosed. The patient was immediately commenced on broad-spectrum anti-

* Corresponding author at: Department of Surgery, Shonan Kamakura General Hospital, Okamoto1370-1, Kamakura City, Kanagawa, Japan.

E-mail address: h.kashiwagi@shonankamakura.or.jp (H. Kashiwagi).

Table 1
Laboratory data.

Complete Blood Count			Biochemistry			Coagulation					
WBC	18.5	10 ³ /mm ³	T-BIL	5.4	mg/dL	Na	132	mEq/L	PT-%	52.7	%
Neu	89.6	%	AST	419	IU/L	K	4	mEq/L	PT-INR	1.36	
Lym	5.2	%	ALT	275	IU/L	Cl	98	mEq/L	APTT	36.6	sec
Mono	4.9	%	LDH	867	IU/L	Ca	8.9	mg/dL			
RBC	3.83	10 ⁶ /L	γGTP	339	IU/L	Mg	2	mg/dL			
Hb	12.3	g/dL	TP	6.2	g/dL	IP	2	mg/dL			
Ht	37.1	%	ALB	2.9	g/dL	Glu	187	mg/dL			
MCV	96.9	fl	BUN	17.3	mg/dL	HbA1c	6.2	%			
PLT	112	10 ³ /L	CRE	0.69	mg/dL	CRP	27.2	mg/dl			

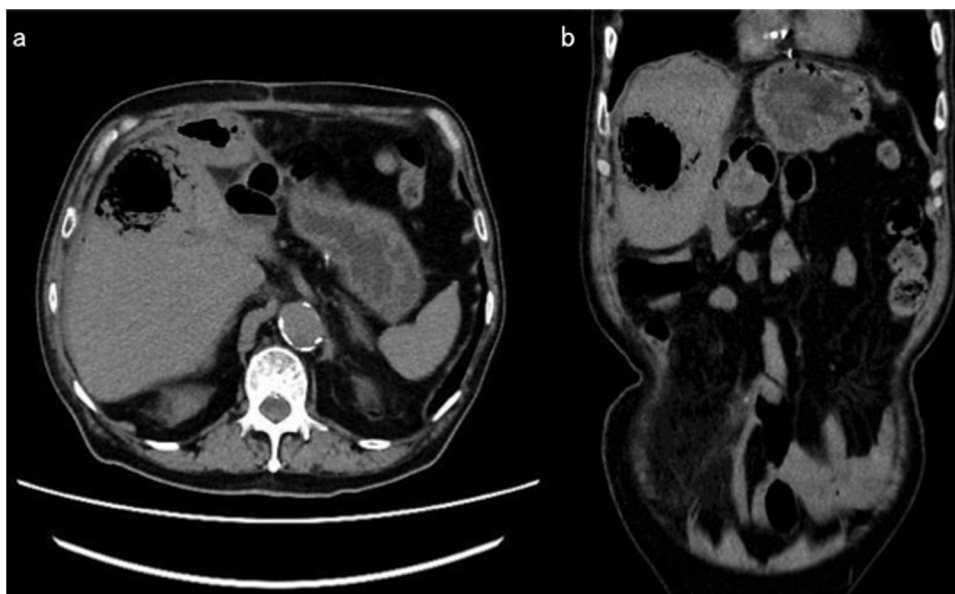


Fig. 1. Abdominal CT scan showing a 48 mm × 46 mm air accumulation in the anterior segment of the liver. Portal gas formation is seen. (a; axial view. b; coronal view.)

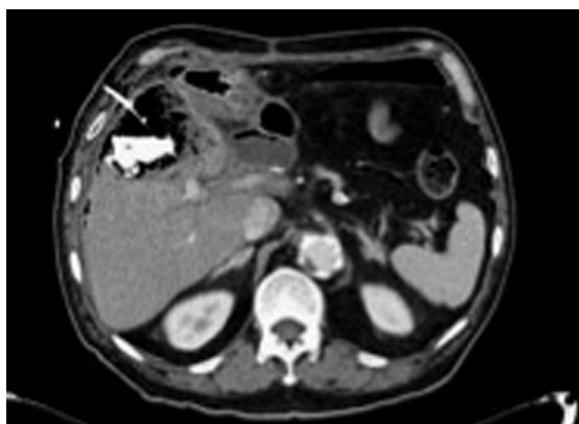


Fig. 2. Contrast CT scan of the abdomen made two hours after the percutaneous drainage. The amount of gas accumulation is the same as in the previous examination. Enhanced material was present in the area with accumulated gas.

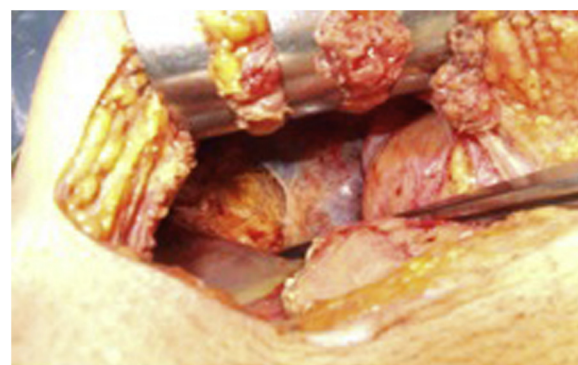


Fig. 3. Operative findings showing the disrupted surface of the anterior segment of the liver with a dark brownish color.

otics and tube drainage was attempted. A CT scan, 2 h after the first procedure, showed the tube drainage to be ineffective (Fig. 2). A surgical drainage was then performed. Operative findings revealed disrupted anterior surface of the liver, with a dark brownish color of liver parenchyma and hemorrhagic ascites in the right subphrenic space. The findings showed signs of ruptured liver gas gangrene (Fig. 3). Surgical debridement of the liver surface, saline lavage in the abdominal cavity and insertion of drainage tubes were performed. Continuous saline perfusion was carried out through the drainage tubes after surgery. One week of hyperbaric oxygen

therapy (HBO) and intensive antibiotics treatment was provided. *Enterococcus faecium*, *Klebsiella pneumoniae* and *Proteus mirabilis* were detected in the blood and drainage samples. De-escalation of antibiotics was considered, based on the results of the culture samples. After open drainage, the patient’s condition improved immediately, and the levels of WBC and CRP decreased significantly (WBC 6.8–10³ cells/mm³ and CRP 1.08 mg/dL on POD 23). The patient was discharged on the 28th post-operative day. Three months after the surgical drainage, the drainage tube was removed at the clinic. 8 months after, no liver abscess or gas forming area was detected on the abdominal CT scan (Fig. 4). There were no complications detected, one year after the treatment.

Table 2
Japanese reported cases of liver gas gangrene.

Year	Author	Age	Sex	Chief complaint	Primary disease	Comobidities	Previous treatment for primary disease	Interventional Treatment for hepatic gas gangrene	Antibiotic Treatment	Time to hepatic gas gangrene development from 1st surgery	Pathogenic bacteria	Outcome	Time to death after diagnosis
1979	Konishi	52	M	Epigastric pain	Gastric cancer/necrotizing cholecystitis	None	Surgery (Appleby ope.)	Surgical drainage	Not described	53 days	E. Coli	Death	4 days
1988	Nakano	68	M	Epigastric pain, fever, dyspnea	None	Diabetes mellitus	None	Concervative	Not described	–	C. perfringens, E.coli	Death	50 min
1989	Tokita	74	M	Consciousness disorder	Transverse colon cancer/liver metastasis	BPH	None	Concervative	Yes	–	C. septicum	Death	10 h
1989	Takahata	64	M	Fever, chilling	Cholelithiasis /choledocholithiasis	Diabetes mellitus	Surgery (cholecystectomy/papilloplasty)	Concervative	Yes	1 year	C. perfringens	Death	24 h
1989	Mandai	75	M	Back pain, dyspnea	Triple cancer (lung, stomach, liver)	Diabetes mellitus, arteriosclerosis obliterans	Surgery (gastrectomy, lung lobectomy), TAE	Concervative	Yes	Not described	C. perfringens	Death	10 h
1991	Mori	74	M	Dysphagia	Esophageal cancer	None	Surgery (esophagectomy/esophageal reconstruction)	Concervative	Yes	24 days	C. perfringens	Death	24 h
1992	Yoshida	67	F	None	Duodenal cancer	None	Surgery (biliary reconstruction(+))	Concervative	Yes	70 days	C. perfringens, E.coli	Death	3 days
1996	Toma	77	M	Abdominal pain, dyspnea	None	Peptic ulcer	None	Concervative	No	–	C. perfringens, E.coli	Death	90 min
2000	Aoki	83	M	Nausea, precordial pressure	Liver gas gangrene	Acute pancreatitis	None	Concervative	Not described	–	C. perfringens	Death	5 h
2004	Ohtani	73	F	Fever, abdominal pain, back pain	Necrotizing cholecystitis	Diabetes mellitus, hypertension	PTGBD	Percutaneous drainage	No	Simultaneously	C. perfringens	Death	6 h
2011	Kishi	70	M	Dyspnea, back pain, lethargy	Gallbladder cancer	Hypertension	Surgery (biliary reconstruction(+))	Concervative	Not described	Not described	C. perfringens	Death	3 days
2013	Nakano	60	M	Epigastric distress	Pancreas cancer	COPD	Surgery (biliary reconstruction(+))	Surgical drainage	Not described	6 days	Enterobacter cloacae	Alive	–
2013	Watanabe	60s	M	Fever, back pain	Hepatocellular carcinoma	Multiple myeloma, bladder cancer	TAE	Concervative	No	7 days	C. perfringens	Death	3 h
2015	Echigoya	84	F	Epigastric pain	Liver gas gangrene	Not described	None	Surgical drainage	Yes	–	C. perfringens	Death	5 h
2016	Kondo	60s	M	Not described	Hepatocellular carcinoma	Not described	RFA, TAE, PEIT	Concervative	Not described	Not described	C. perfringens	Death	Not described
2016	Miyata	57	F	Melena	Bile duct cancer	Hypertension, Diabetes mellitus, Cerebral infarction	Surgery (biliary reconstruction(+))	Surgical drainage	Yes	19 days	Enterococcus, Klebsiella pneumoniae	Death	3 days
2018	Ono	82	M	Chilling, lethargy, dyspnea	Hilar cholangiocarcinoma	Diabetes mellitus, Hypertension, Atrial fibrillation, Angina pectoris	Surgery (biliary reconstruction(+))	Surgical drainage	Yes	75 days	Klebsiella pneumoniae, Proteus mirabilis, Enterococcus faecium	Alive	–

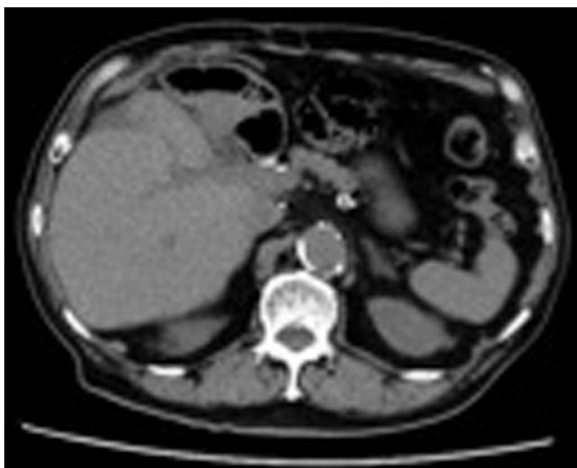


Fig. 4. No liver abscess or accumulation of gas was detected in the abdominal CT scan made after 8 months.

3. Discussion

Since the first description of gas gangrene in an organ by Fraenkel in 1889, few cases of acute organ failure following acute *Clostridium perfringens* infection have been described in the literature [2]. Up to the middle of the last century, generalized gas gangrene was most often a consequence of soil-contaminated war wounds and was mostly lethal. Gas gangrene is usually due to clostridia infections or infection by other species. The condition frequently occurs under anaerobic conditions and therefore is rare to be detected in blood-enriched organs, such as the liver.

We reported previously a fatal case of gas gangrene of the liver and discussed the features of this dreadful disease on the basis of ten manuscripts reported in Ichushiweb in Japan from 1979 [2]. We concluded that history of malignant disease or an ischemic condition of the liver or neighboring organs may be crucial risk factors for liver gas gangrene.

To date, 16 cases have been reported in Japan [2,5–16]. Table 2 shows the characteristics of the patients with liver gas gangrene, including our case. The outcomes of the reported cases were dismal and most cases showed rapid progression. Fifteen cases (88%) were fatal and ten (59%) patients died within 24 h of the diag-

nosis. Clostridial infection tended to be worse than non-clostridium infection in these reported cases. All 17 cases had comorbidity diseases, of which 11 cases (65%) had malignant diseases and 6 cases (35%) had diabetes mellitus. Eight cases (47%) had received previous surgical treatment for malignant diseases, and 3 cases (18%) had developed hepatic gas gangrene after transcatheter arterial embolization (TAE) for hepatic cancer. These results indicate that patient's condition, such as a history of malignant disease and an ischemic condition of the liver, may be associated with this dreadful disease.

Specific symptoms of liver gas gangrene may be absent. Therefore, emergent morphological studies, such as CT scans and magnetic resonance imaging, are crucial for early diagnosis. There is currently no treatment strategy for liver gas gangrene. Liver gas gangrene usually is fatal and only two surgical drainage cases survived among the cases reported in Japan. Normally, tubes providing percutaneous drainage can aspirate fluid accumulated in the liver, but this procedure seems to be ineffective for gas forming lesions. In our case, percutaneous drainage was ineffective during the two hours following the procedure, therefore we converted to open drainage. These results indicate that surgical treatment always should be considered as the means of drainage for gas accumulating infections of the liver, such as liver gas gangrene.

We also attempted HBO therapy with saline irrigation, along with antibiotic therapy, after the open drainage. HBO therapy is defined as the inhalation of 100% oxygen under elevated atmospheric pressure. HBO seems to be safe for patients because its side effects are rare and oxygen toxicity seems to be caused primarily by higher doses or longer durations of use than recommended [17]. In terms of our current understanding of HBO, this has been widely indicated as an adjunctive treatment for various ischemic conditions, such as arterial gas embolism, carbon dioxide poisoning, soft tissue infection, refractory osteomyelitis, problematic wounds, liver transplantation, and peripheral gas gangrene [18]. Although the role of HBO therapy for gas gangrene remains controversial, some positive effects on the ischemic tissues are to be expected. In an animal model, the oxygen concentration is increased via activation of endothelial nitric oxide, which may dilate the micro-circulation [17]. HBO therapy is also able to exert hepatoprotective effects by inhibiting hepatocyte apoptosis [19]. Because gas gangrene occurs under anaerobic conditions, HBO therapy can be effective with adequate antibiotic use and drainage. This is the first

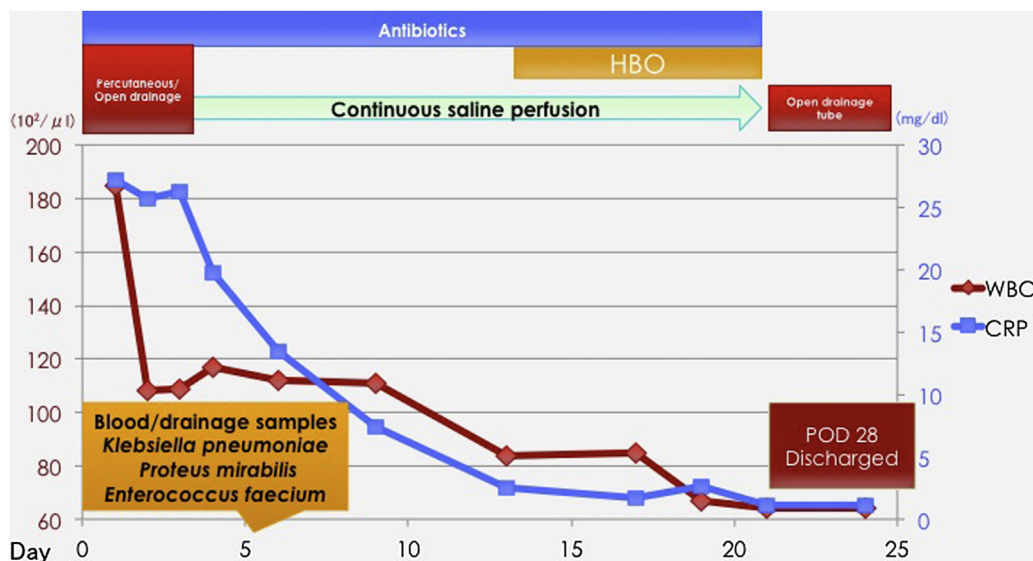


Fig. 5. Clinical course of the case.

report of the use of HBO therapy for liver gas gangrene. Fig. 5 shows the clinical course of our case. Inflammatory reactions such as WBC and CRP improved immediately. De-escalation of antibiotics was considered, based on the results of culture samples. Surgical open drainage, HBO and appropriate antibiotic therapy are crucial for this type of disease.

4. Conclusion

We report a case of successful treatment of hepatic gas gangrene by laparotomy drainage, combined with appropriate antibiotics and HBO. All survival cases of hepatic gas gangrene were treated by laparotomy drainage; thus, immediate laparotomy could be essential to avoid a fatal outcome.

Conflict of interest statement

We all do not have any financial and personal relationships with other people or organisations that could inappropriately influence (bias) their work.

Funding

This research did not receive any specific grant from funding agencies in the public, commercial, or not-for-profit sectors.

Ethical approval

This is only a case-report after the surgical operation, not the result of the clinical study. In such case, the evaluation by Ethical Committee does not require currently in our hospital.

However, the ethical checks of this case report, in terms of an informed consent for the presentation of the patient, and the appropriate manner for protection of the privacy, have been executed by the Research Support Office in our hospital.

Consent

Written informed consent was obtained from the patient for publication of this case report and accompanying images.

Author's contribution

Dr. Ryohei Ono is the first author and drafted manuscript. Dr. Hiroyuki Kashiwagi is the corresponding author, drafted and finalized the manuscript. Dr. Hiroyuki Kashiwagi and Dr. Takaaki Murata performed open drainage surgery. Other doctors, Jun Kawachi, Naoko Isogai, Katsunori Miyake, Rai Shimoyama, Ryuta Fukai, Hidemitsu Ogino and Nobuaki Shinozaki have cooperated in this manuscript.

Registration of research studies

This is the first case-report, and which doesn't require registration in "Study Registry".

Therefore, we don't have UIN of this.

Also, Dr. Riaz Agha, who is a director of Research Registry, has proposed this manner for us.

I am very happy if you receive this report to your journal, and I believe that this case-report will be very beneficial for every surgeon in this field.

Guarantor

Hiroyuki Kashiwagi.

References

- [1] D.J. Birnbaum, E. Grégoire, J. Hardwigsen, Y.P. Le Treut, Salvage liver transplantation for hepatic gas gangrene, *J. Gastrointest. Surg.* 16 (9) (2012) 1802–1804.
- [2] Y. Miyata, H. Kashiwagi, K. Koizumi, J. Kawachi, M. Kudo, S. Teshima, N. Isogai, K. Miyake, R. Shimoyama, R. Fukai, H. Ogino, Fatal liver gas gangrene after biliary surgery, *Int. J. Surg. Case Rep.* 39 (2017) 5–8.
- [3] M. Nakano, H. Okamoto, T. Okamura, K. Ono, Y. Tamiya, A case of hepatic gas gangrene with disseminated intravascular coagulation and multiple organ failure successfully treated with repeated necrosectomy, *Jpn. J. Gastroenterol. Surg.* 46 (6) (2013) 416–423.
- [4] R.A. Agha, A.J. Fowler, A. Saeta, I. Barai, S. Rajmohan, D.P. Orgill, S. Group, The SCARE statement: consensus-based surgical case report guidelines, *Int. J. Surg.* 34 (2016) 180–186.
- [5] K. Konishi, K. Miwa, O. Nagata, M. Yamagishi, I. Miyazaki, A case of hepatic gas gangrene, *Shokakigeka* 2 (6) (1979) 1245–1250.
- [6] O. Nakano, M. Okita, M. Miura, T. Hozumi, K. Suzuki, M. Maeda, K. Okada, T. Chinzei, K. Yamashiro, An autopsy case of clostridial liver abscess, *J. Jpn. Soc. Int. Med.* 77 (5) (1988) 690–694.
- [7] H. Tokita, M. Shimizu, K. Ohshima, S. Kobayashi, O. Nishikawa, T. Takai, Y. Takahashi, K. Yamaoka, K. Watanabe, K. Ueno, A case of nontraumatic clostridium septieum infection with intrahepatic pneumatic tumor and adenocarcinoma of the transverse colon, *J. Jpn. Soc. Int. Med.* 77 (12) (1988) 1873–1878.
- [8] T. Takahata, M. Nishihira, E. Heizan, K. Eto, Y. Horikawa, A case of hemolytic anemia due to clostridium perfringens infection, *Okinawa Med. J.* 26 (1) (1989) 186–187.
- [9] K. Mandai, S. Moriwaki, H. Doihara, Y. Nakanishi, M. Murakami, S. Takashima, I. Akehi, Two autopsy cases of clostridial gas gangrene associated with malignant tumors, *Pathol. Clin. Med.* 7 (1) (1989) 119–124.
- [10] T. Mori, S. Soda, M. Oshima, A case of gas gangrene following operation for cervical esophageal carcinoma, *J. Jpn. Surg. Soc.* 92 (7) (1991) 889–892.
- [11] M. Yoshida, M. Ryu, Y. Fujita, I. Honda, S. Watanabe, Y. Kawakami, M. Miyauchi, W. Takayama, M. Hirokawa, K. Sasada, S. Wakatsuki, An autopsy case of clostridial gas gangrene of liver, *Jpn. J. Gastroenterol. Surg.* 25 (8) (1992) 2181–2185.
- [12] Y. Toma, N. Son, T. Miyazawa, M. Ohta, M. Fujita, K. Sakata, Fulminant spontaneous intrahepatic clostridial gas gangrene, *J. Jpn. Assoc. Acute Med.* 7 (1996) 27–32.
- [13] M. Nakano, H. Okamoto, T. Okamura, K. Ono, Y. Tamiya, A case of hepatic gas gangrene with disseminated intravascular coagulation and multiple organ failure successfully treated with repeated necrosectomy, *Jpn. J. Gastroenterol. Surg.* 46 (6) (2013) 416–423.
- [14] Y. Watanabe, S. Monzawa, N. Yuasa, A. Higashida, H. Yamada, Fatal hepatic gas gangrene due to clostridium perfringens infection after transcatheter arterial chemoembolization, *Jpn. J. Intervent. Radiol.* 28 (2013) 58–61.
- [15] R. Echigoya, A. Kuriyama, N. Umakoshi, Hepatic gas gangrene, *Intern. Med.* 54 (2014) 1319.
- [16] T. Kondo, An autopsy case of hepatic gas gangrene due to clostridium perfringens, *Intern. Med.* 117 (2) (2014) 303.
- [17] H. Lv, C.H. Han, X.J. Sun, W.W. Liu, Application of hyperbaric oxygen in liver transplantation, *Med. Gas Res.* 6 (4) (2016) 212–218.
- [18] T. Oyaizu, M. Enomoto, N. Yamamoto, K. Tsuji, M. Horie, T. Muneta, I. Sekiya, A. Okawa, K. Yagishita, Hyperbaric oxygen reduces inflammation, oxygenates injured muscle, and regenerates skeletal muscle via macrophage and satellite cell activation, *Sci. Rep.* 8 (1) (2018) 1–12.
- [19] J.C. Chaves, D.J. Fagundes, M. De J. Simoes, P.R. Bertoletto, C.T. Oshima, M.O. Taha, R.S. Simoes, A.L. Fagundes, Hyperbaric oxygen therapy protects the liver from apoptosis caused by ischemia-reperfusion injury in rats, *Microsurgery* 29 (7) (2009) 578–583.

Open Access

This article is published Open Access at [scienceopen.com](https://www.scienceopen.com). It is distributed under the [IJSCR Supplemental terms and conditions](#), which permits unrestricted non commercial use, distribution, and reproduction in any medium, provided the original authors and source are credited.