



# Open 4-Compartment Fasciotomy for Chronic Exertional Compartment Syndrome of the Leg

Amos Z. Dai, B.S., Michael Zacchilli, M.D., Neha Jejurikar, B.S., Hien Pham, M.D., and Laith Jazrawi, M.D.

---

**Abstract:** Chronic exertional compartment syndrome (CECS) is a significant source of lower extremity pain and morbidity in the athletic population. Although endoscopic techniques have been introduced, open fasciotomy remains the mainstay of surgical treatment because of the paucity of evidence in support of an endoscopic approach. The literature on surgical management of CECS is mixed, and overall success rates are modest at best. Optimizing surgical technique, including prevention of neurovascular injury and wound complications, can make a significant impact on the clinical outcome. Here we present our surgical technique, including pearls and pitfalls, for open 4-compartment fasciotomy for treatment of chronic exertional compartment syndrome.

---

**C**hronic exertional compartment syndrome (CECS) is a significant source of lower extremity pain and morbidity in the athletic population. Although the incidence of CECS in the general population is unknown, it was determined to be 0.49 cases per 1,000 person-years in a physically active military population.<sup>1</sup> When conservative measures fail to resolve symptoms, surgical fasciotomy is indicated.

In a recent systematic review<sup>2</sup> on the surgical management of CECS, the overall success rate was determined to be 66%, the satisfaction rate was 84%, and the rate of return to previous or full activity was 75%. Furthermore, symptom recurrence rate ranged from 0% to 44.7%, the reoperation rate ranged from 0% to 19%, and the overall complication rate was 13%. However, the study does not compare the outcomes of various techniques. Although endoscopic techniques<sup>3-5</sup> have been introduced, open fasciotomy remains the mainstay of surgical treatment because of the paucity of evidence in support of an endoscopic approach.

The literature on surgical management of CECS is mixed, and overall success rates are modest at best. Optimizing surgical technique, including prevention of neurovascular injury and wound complications can make a significant impact on clinical outcome. Here we present our surgical technique, including pearls and pitfalls, for open 4-compartment fasciotomy for treatment of chronic exertional compartment syndrome.

## Indications and Contraindications

Patient selection is perhaps the most significant challenge for surgeons treating CECS patients. Classical “indications” have been consistently reported across publications, but largely consist of symptomatology rather than hard data (Table 1).<sup>2</sup> The history and physical examination therefore remain the mainstay for indicating a patient for elective fasciotomy. The ideal candidate presents complaining of exercise-induced pain, fullness/tightness, and neurologic disturbances limited to the associated nerve distribution (e.g., a patient complaining of anterior and lateral compartment pain and fullness without calf discomfort, weakness with dorsiflexion and/or steppage gait, and associated numbness in the lateral leg, ankle, and dorsal foot). The presence of muscle herniations (present in more than 45% of CECS patients and only 12.9% of asymptomatic controls), is the most reliable physical examination finding.<sup>6</sup> In the experience of the authors, patients with these “textbook” presentations have the most favorable response to surgical intervention. Unfortunately, patient presentation is frequently more variable. Diagnostic testing including

---

From the NYU Hospital for Joint Diseases, New York, New York, U.S.A. The authors report that they have no conflicts of interest in the authorship and publication of this article. Full ICMJE author disclosure forms are available for this article online, as [supplementary material](#).

Received April 1, 2017; accepted August 7, 2017.

Address correspondence to Amos Z. Dai, B.S., NYU Hospital for Joint Diseases, 301 E 17th Street, Suite 1500, New York, NY 10003, U.S.A. E-mail: [amos.z.dai@gmail.com](mailto:amos.z.dai@gmail.com)

© 2017 by the Arthroscopy Association of North America. Published by Elsevier. This is an open access article under the CC BY-NC-ND license (<http://creativecommons.org/licenses/by-nc-nd/4.0/>).

2212-6287/17498

<http://dx.doi.org/10.1016/j.eats.2017.08.014>

**Table 1.** Surgical Criteria

Indications	Relative Contraindications
<b>History</b>	
Pain induced by activity/exercise, relieved with rest, ideally reproducible with stress testing (e.g., clinic treadmill)	Pain/fullness at rest <sup>V</sup>
Paresthesias in the associated dermatome	Paresthesias proximal to leg or inconsistent with involved compartment/nerve dermatome <sup>N,V</sup>
Anterior compartment: first web space	
Lateral compartment: dorsal foot	
Posterior compartments: plantar foot	
Weakness/footdrop	Weakness/footdrop at rest or in isolation <sup>N</sup>
Fullness/tightness/cramping	
Failure of nonsurgical management	Inadequate nonsurgical trial
Active patient and/or onset during ADL	Low-demand patient, rare occurrences Unable/unwilling to follow postoperative plan Persistent, unrealistic expectations
<b>Physical examination</b>	
Full/firm compartments at rest or following stress testing	Soft compartments after stress testing <sup>N</sup>
Palpable muscle herniations and fascial defects <sup>1</sup>	
Objective weakness following stress testing	Weakness/footdrop at rest or in isolation <sup>N</sup> Abnormal resting pulse or positional stress test <sup>V</sup>
<b>Diagnostic testing</b>	
Intramuscular compartment pressure (IMCP) Pedowitz criteria ( $\geq 1$ criteria, ideally ultrasound-guided) <sup>6,7</sup>	Normal compartment measurements. Inverted response (progressive increase in pressure during postexercise phase): consider repeat examination, add ultrasound guidance if not used primarily
1. Pre-exercise rest $>15$ mmHg	
2. 1 minute post-exercise $>30$ mmHg <sup>*,8</sup>	
3. 5 minutes post-exercise $>20$ mmHg	
4. 15 minutes post-exercise $>15$ mmHg	
Dynamic compartment pressure testing <sup>9</sup>	
Phase II $\geq 105$ mmHg <sup>†</sup>	
(Phase II: 15-kg backpack, 5% incline treadmill, 6.5 km/h pace for 5 minutes)	
Near-infrared spectroscopy <sup>10</sup> : Peak exercise $StO_2 \leq 55\%$	
% $\Delta StO_2$ [(baseline – peak)/baseline] $\geq 35\%$	
In-scanner exercise-based MRI <sup>11</sup>	
T2-weighted intensity ratio threshold $\geq 1.54$	

NOTE. Careful history and physical examination remain the mainstay of diagnosis, with a particular focus on ruling out all other causative factors. Given the potential morbidity and inconsistent surgical outcomes, surgeons should approach chronic exertional compartment syndrome as a diagnosis of exclusion. Because of the inconsistent reliability of diagnostic tools, they should generally be reserved for patients in one of 2 categories: (1) patients with an established clinical diagnosis, an understanding of the risks and benefits of surgical intervention, and a desire to proceed, or (2) patients with an inconsistent clinical picture, with a negative neurologic and vascular workup, and continued significant impact of symptoms on their quality of life. Finally, the clinician must consider the entire constellation of indications and contraindications for each patient, as none of these criteria provide absolute arguments for or against surgical management.

<sup>V</sup>Recommendation: rule out other etiologies, focus on vascular pathology.

<sup>N</sup>Recommendation: rule out other etiologies, focus on neurologic pathology.

ADL, activities of daily living; MRI, magnetic resonance imaging.

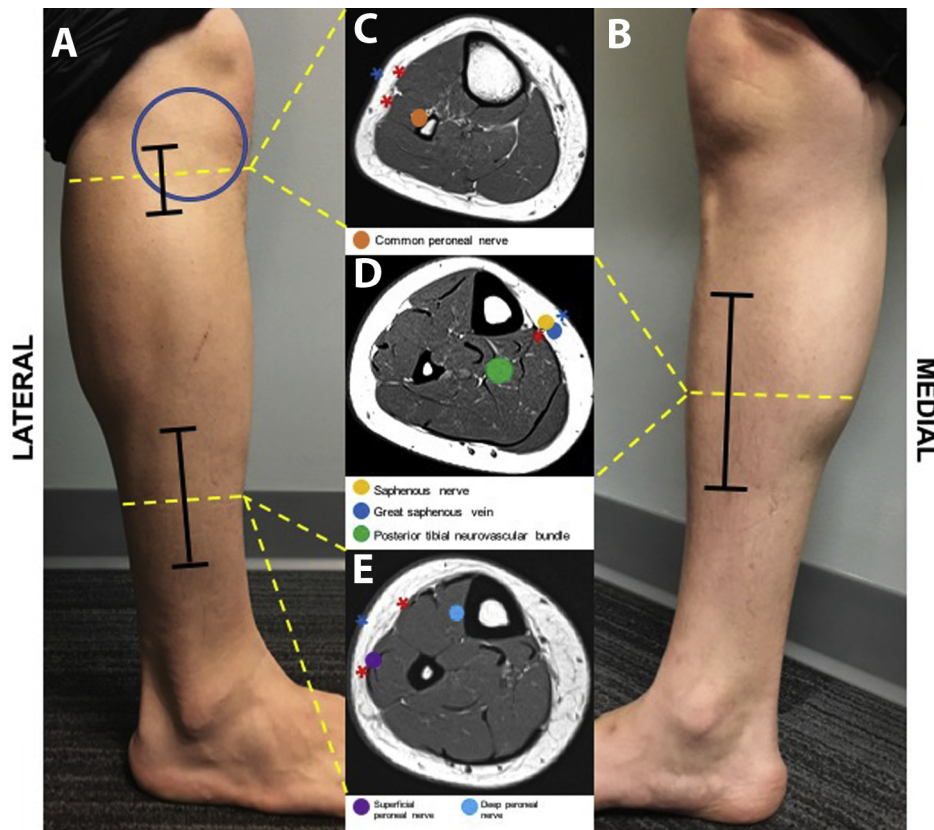
\*Immediate or 1-minute post-exercise IMCP is the most accurate time point based on a recent systematic review.

<sup>†</sup>Although research on continuous dynamic IMCP testing shows an improved receiver operating characteristic curve and diagnostic accuracy compared with published values for intermittent timed IMCP, the reported threshold value of 105 mmHg has only been established for isolated anterior compartment measurement in a military population.

intramuscular compartment pressure, near-infrared spectroscopy, and in-scanner exercise-based magnetic resonance imaging can provide surgeons objective parameters for indicating patients, particularly in the face of clinical inconsistencies.

The contraindications for this surgery (Table 1) can be summarized as patients with (1) an alternate diagnosis, (2) an insufficient nonoperative course, (3) low functional demand, and (4) limited disease impact. All reasonable steps must be taken to evaluate for alternate etiologies, particularly neurologic and vascular disorders. Variations in the history and physical can help to direct an extended workup. Evaluation for vascular

pathology begins with a careful 3-point lower extremity pulse examination, including a positional stress test to rule out popliteal compression. Abnormalities in the examination or resting perfusion should prompt further workup, which may include the following: vascular surgery referral, arterial brachial indices, dynamic Doppler ultrasonography (including unresisted plantarflexion, resisted plantarflexion, and heel raise provocative testing), magnetic resonance imaging (neutral, plantarflex, and dorsiflexed sequences), magnetic resonance angiography (plantarflexed after provocative exercise), and occasionally computed tomography or angiography. Neurologic evaluation should include a

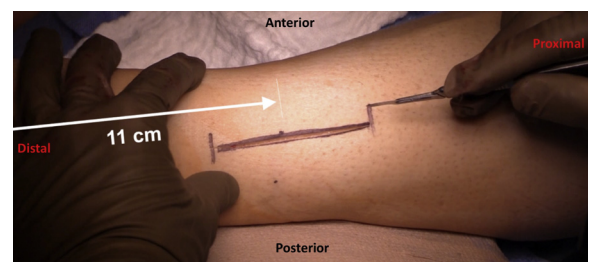


**Fig 1.** Superficial anatomic images demonstrate our preferred lateral (A) and medial (B) incision locations for 4-compartment fasciotomy in the setting of chronic exertional compartment syndrome. Representative axial cut magnetic resonance images (C, D, E) indicate the locations of critical neurovascular structures and fasciotomy locations (red asterisk) at each level. The distal lateral incision (A) is centered over the intermuscular septum 11 cm proximal to the tip of the lateral malleolus to facilitate direct visualization of the superficial peroneal nerve at its exit from the crural fascia. Identification, mobilization, and control of the nerve at this location allows performance of a controlled anterior and lateral compartment fasciotomy in the distal two-thirds of the leg (red asterisks: D, E). The proximal lateral incision (A) is localized over the posteroinferior edge of Gerdy safe zone (blue circle: an approximately 45-mm-radius circle centered on Gerdy tubercle) where the peroneal nerve and its major branches course along the posterior and inferior circumference (C). The most proximal portion of the anterior and lateral compartment fasciotomies can be completed through this incision while protecting the nerve. The medial incision is centered just off the medial tibial border overlying the saphenous nerve and vein (B, D). The posterior tibial neurovascular bundle must be visualized and protected during deep posterior compartment fasciotomy (D). Blue asterisks denote locations of skin incisions.

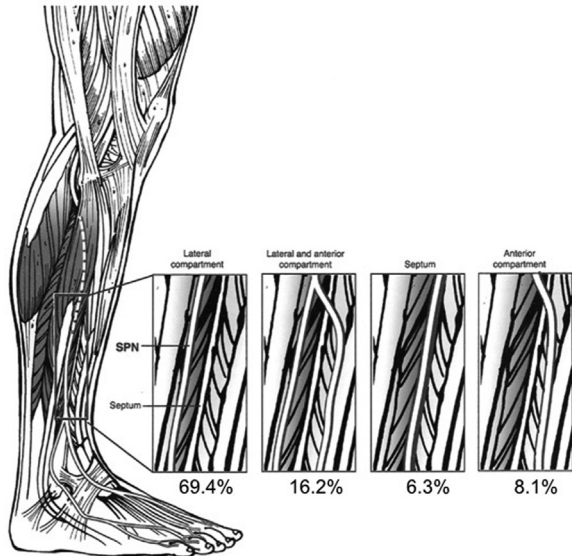
complete spine examination with sensory and motor evaluation. Any nonanatomic distributions on history and physical examination, or the presence of objective neurologic deficits at rest, should prompt complete neurologic evaluation with advanced imaging or electromyography as necessary, with specific attention to the lumbar spine.

CECS may respond to activity/exercise modifications and gait retraining and should be pursued, particularly in low-demand individuals or recreational athletes amenable to changing sports or training regimens. Although competitive athletes are less likely to tolerate or respond to these strategies, an attempted course is advocated, particularly given the inconsistency of surgical outcomes. Inadequate nonsurgical treatment attempts or poor patient adherence to conservative measures are therefore

relative contraindications to surgery. Focused monitoring provides an honest evaluation of disease impact, engages the patient in education and decision



**Fig 2.** Distal incision for anterior and lateral compartment fasciotomies of the left leg. The distal incision is centered over the intermuscular septum with its midpoint 11 cm proximal to the tip of the lateral malleolus.



**Fig 3.** The 4 main patterns of superficial peroneal nerve anatomy and crural fascia perforation in the distal leg and relative proportions of these variations in the general population. Surgeon must be aware of these variations as well as other rare variations when performing anterior and lateral compartment fasciotomy. Reproduced and adapted with permission from Ducic I, Dellon AL, and Graw KS. The clinical importance of variations in the surgical anatomy of the superficial peroneal nerve in the mid-third of the lateral leg. *Ann Plast Surg* 2006;56(6):635-638.

making, and evidences their ability to follow crucial rehabilitation guidelines—all of which are useful even in the setting of failed conservative care.

## Technique

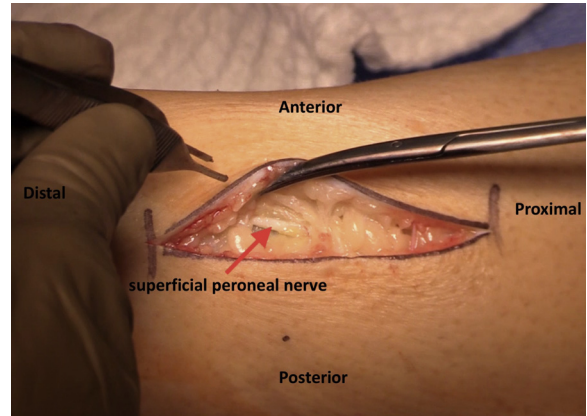
### Patient Positioning

The procedure is performed with the patient under general anesthesia with appropriate prophylactic antibiotics. The patient is positioned supine on the operating table. Thigh tourniquet is applied and inflated.

### Anterior and Lateral Compartments

The anterior and lateral compartments are each released using 2 longitudinal incisions: 1 longer distal incision and 1 shorter proximal incision (Fig 1). A point is marked 11 to 12 cm proximal to the tip of the distal fibula, and midway between the anterior border of the fibula and the tibial crest (Fig 2). This point marks the center of the 8-cm-long distal incision. Subcutaneous dissection within this incision accounts for anatomic variation as the superficial peroneal nerve exits the crural fascia (Fig 3). Whether single or multiple branches are identified, this incision is almost universally adequate for direct visualization.

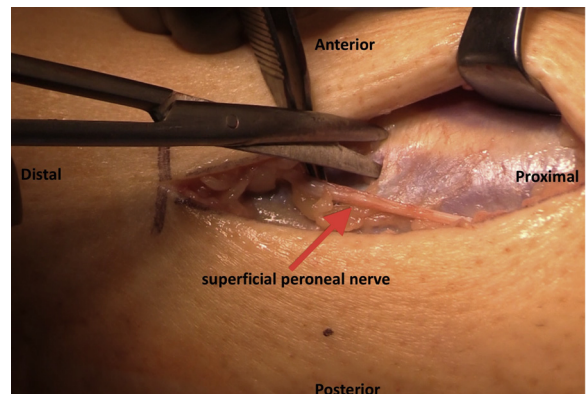
The 3- to 4-cm proximal longitudinal incision is planned 2 to 3 fingerbreadths distal to the Gerdy



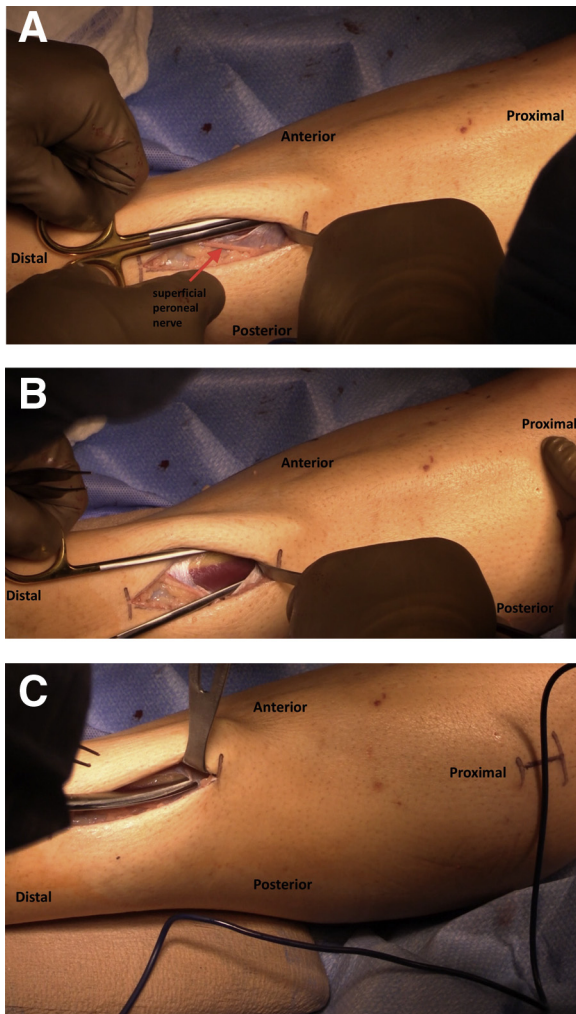
**Fig 4.** Exposure of the anterior and lateral compartments of the left leg via the distal incision. Blunt dissection through the subcutaneous tissues will usually expose the superficial peroneal nerve as it passes proximal to distal. The nerve is carefully mobilized.

tubercle and is centered anteroposteriorly overlying the intermuscular septum, which is generally palpable (Fig 1). This incision overlies the posteroinferior border of the described “Gerdy safe zone,” an approximately 45-mm-radius circle centered over the tubercle.<sup>4</sup> The posterior and inferior aspects of the circle’s circumference generally describe the course of the peroneal nerve as it courses posterior to anterior about the fibular neck. The positioning of the proximal incision allows the surgeon to complete the proximal fasciotomy in a direct and controlled manner in this region.

The distal incision is made first. Blunt transverse spreading and limited sharp dissection using Metzenbaum scissors is carried through the subcutaneous tissue to the level of the anterior and lateral compartment fasciae, full-thickness skin flaps are raised bluntly, and the nerve is identified (Fig 4). A combination of blunt finger dissection and the “chopstick” technique with Army-Navy retractors helps to clearly define the fascial

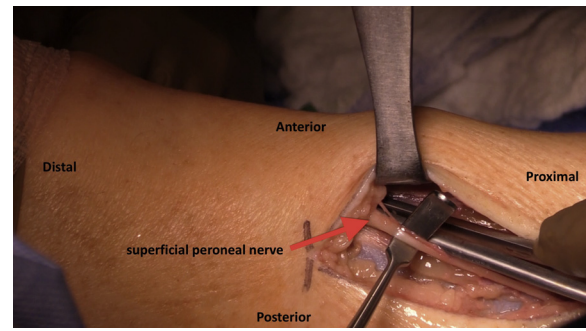


**Fig 5.** Anterior compartment fasciotomy of the left leg, distal incision. A 1-cm superficial incision is placed in the anterior compartment fascia approximately 2 cm lateral to the tibial crest.



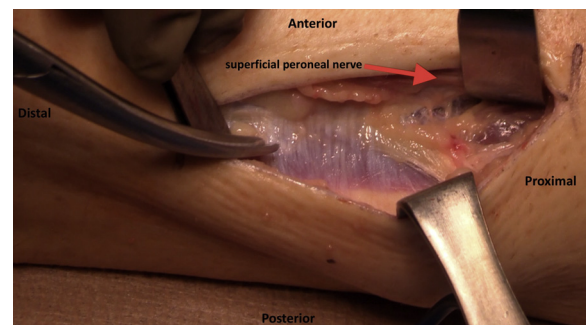
**Fig 6.** (A) Anterior compartment fasciotomy of the left leg, distal incision. Subfascial and prefascial tracts are created with long Metzenbaum scissors. Scissors should be closed when passing them underneath the skin. Scissor tips should face superficially to avoid superficial peroneal nerve damage. (B) Anterior compartment fasciotomy of the left leg, distal incision. Subfascial and prefascial tracts are created with long Metzenbaum scissors. Scissors should be open when coming out of the skin. Scissor tips should face superficially to avoid superficial peroneal nerve damage. (C) Anterior compartment fasciotomy of the left leg, distal incision. The tips are opened slightly over the fascial edge and directed anterior and superficial, and the proximal fasciotomy is performed with a single sliding motion.

plane. Variations in the superficial peroneal nerve path must be appreciated: it may exit directly through the lateral compartment fascia posterior to the septum (most common), through both the anterior and lateral compartments, by traversing a fibrous tunnel within the intermuscular septum, or exit immediately anterior to the intermuscular septum from the anterior compartment alone (Fig 3). Regardless of this anatomic variation, a careful neuroplasty is carried out as the first

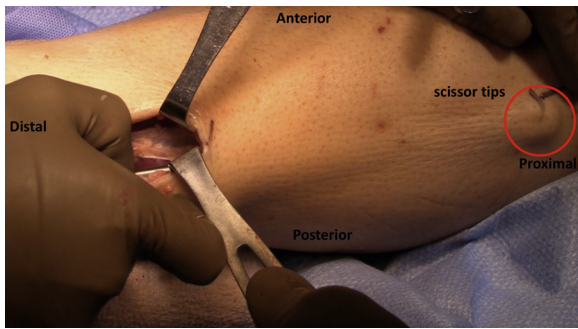


**Fig 7.** Anterior compartment fasciotomy of the left leg, distal incision. This same process of creating subfascial and prefascial tracts with Metzenbaum scissors is repeated distally to the level of the extensor retinaculum.

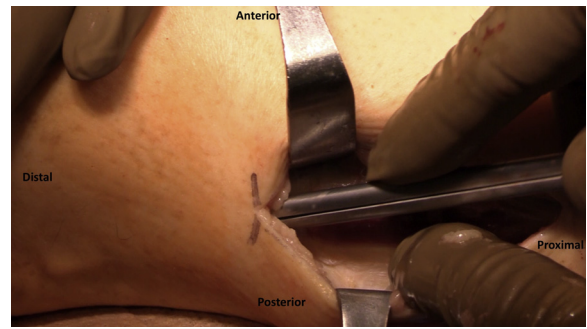
step of fascial release, improving its excursion and allowing safe retraction during longitudinal fasciotomy (Video 1). To perform proximal release of the anterior compartment, a 1-cm superficial fascial incision, using a small scalpel or Metzenbaum scissors, is made in the fascia anterior to both the intermuscular septum and the superficial peroneal nerve with posterior retraction of the nerve (Fig 5). Alternatively, the neuroplasty site may be used. With tips closed and directed superficially, long Metzenbaum scissors (e.g., Sklar Curved Bariatric Metzenbaum-Nelson Scissors, 61-0004 [16"] and 61-2004 [20"]; Sklar, West Chester, PA) are placed immediately deep into the anterior compartment fascia and passed proximally in the direction of the tibial tubercle, to the level of the planned proximal incision (Fig 6A). The scissors are then opened and slowly retracted to develop the plane, taking care not to close the scissors during removal (Fig 6B). A plane between the subcutaneous tissue and superficial fascia is created in a similar fashion, again directing the tips superficially. Longitudinal fasciotomy is then performed with the same long Metzenbaum scissors. The tips are opened 2 to 3 mm and pointed anteriorly, and maintaining 1 tip



**Fig 8.** Lateral compartment fasciotomy of the left leg, distal incision. The nerve is retracted anteriorly and an initial fascial incision is created, carefully extending to the nerve's exit point and ensuring release at this location.



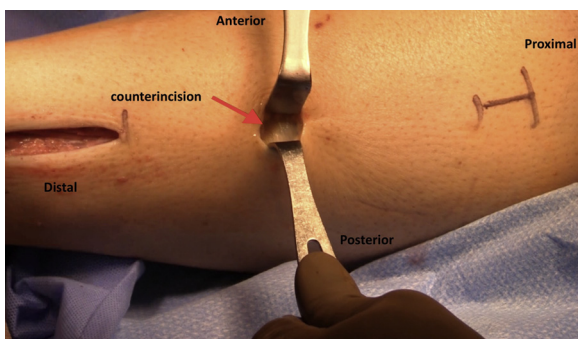
**Fig 9.** Lateral compartment fasciotomy of the left leg, distal incision. Proximal fasciotomy is performed in similar fashion with the Metzenbaum tips directed superficially and slightly posterior.



**Fig 11.** Lateral compartment fasciotomy of the left leg, distal incision. The lateral compartment fasciotomy is completed distally to the level of the peroneal retinaculum.

on each side of the fascia, the instrument is pushed retrograde to the level of the planned proximal incision (Fig 6C). Distally, the anterior compartment release is directed toward the anterior aspect of the lateral malleolus, down to the level of the extensor retinaculum, with particular attention to the nerve as it courses anteriorly in the distal subcutaneous space (Fig 7).

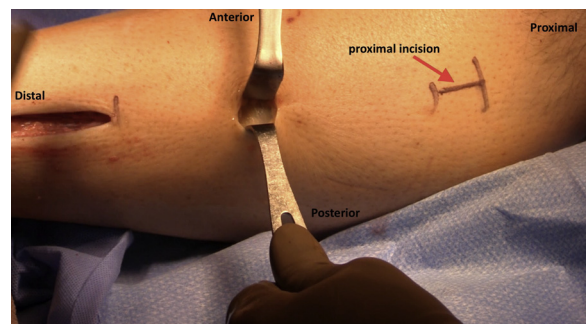
Attention is turned toward the lateral compartment release using the same skin incision. A tiny incision is made in the fascia overlying the peroneal tendons (Fig 8). Proximal release is carried out in the direction of the fibular head to the level of the planned proximal incision (Fig 9). Scissor tips are then curved away from the tibial crest and visualized; the superficial peroneal nerve is then retracted anteriorly to avoid injury. Passage is ideally performed with a single pass. Of note, passage of the scissors should be done smoothly in 1 direction, as any backward movement may cause the tips to fall off the fascia. If tips fall off the fascia in a portion of the fascia that cannot be directly visualized, a 3- to 4-cm accessory incision should be made at that location (Fig 10). Distally, release is directed toward the posterior aspect of the lateral malleolus, down to the level of the ankle joint (Fig 11).



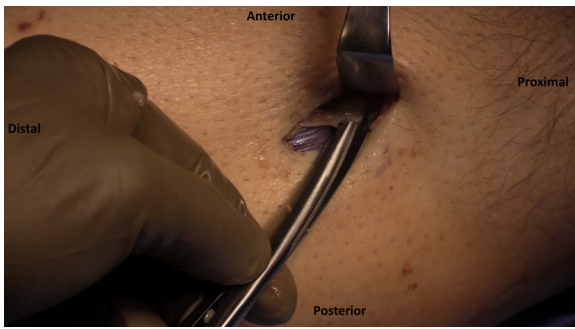
**Fig 10.** Lateral compartment fasciotomy of the left leg, distal incision. If the tips disengage prematurely from the fascial edge, a small counterincision at the apex is preferred to blind attempts, which can place the nerve at risk.

Next, the planned 3- to 4-cm proximal incision is made (Fig 12). Skin flaps are elevated bluntly. Using this incision, the proximal extents of the anterior and lateral releases are identified and extended proximally to the level of Gerdy tubercle (Fig 13). Direct visualization in this area allows for complete and controlled release with avoidance of the peroneal nerve branches as they course into their respective compartments. Occasionally, fascial bands are identified about the fibular neck that directly compress the branches, and this proximal incision also allows for direct release in these cases. These fascial bands have been identified in series of patients failing initial fasciotomy, and visualization through this proximal incision allows release and may decrease failure risk.

The lateral wounds are packed with moist gauze and the tourniquet is released. This step allows for visualization and control of any significant bleeding in the anterior and lateral compartments. It also facilitates direct visualization and palpation of the saphenous vein and the posterior tibial bundle, which the authors find helpful during fasciotomy of the superficial and deep posterior compartments.



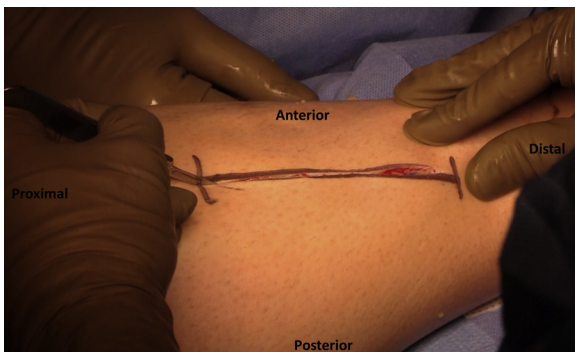
**Fig 12.** Anterior and lateral compartment fasciotomies of the left leg, proximal incision. A proximal incision is placed in the Gerdy safe zone, 2-3 fingerbreadths distal to the tubercle, to ensure controlled completion of the anterior and lateral fasciotomy proximally under direct visualization.



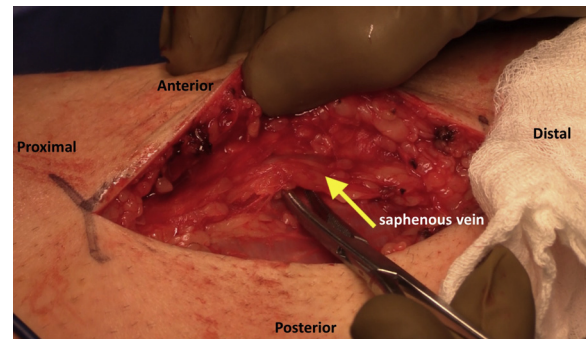
**Fig 13.** Anterior and lateral compartment fasciotomies of the left leg, proximal incision. The proximal incision allows for controlled completion of the anterior and lateral fasciotomy proximally under direct visualization.

### Superficial Posterior and Deep Posterior Compartments

The superficial posterior and deep posterior compartments are released through a single 8-cm incision on the medial side of the leg (Fig 1). This incision is centered 2 cm medial to the posterior crest of the tibia, at the junction of the middle and distal one-thirds of the leg (Fig 14). Incision is made and a combination of blunt and sharp dissection is carried down to the level of the fascia. Remaining subcutaneous tissues are cleared using finger sweep dissection. Next, the saphenous nerve and vein are identified just medial and posterior to the medial border of the tibia, overlying the deep posterior compartment fascia (Fig 15). These are retracted and protected as necessary. An approximately 5-cm incision is made in the fascia using a scalpel under direct visualization (Fig 16). With Metzenbaum scissors, this is then extended proximally and diagonally (anteroinferior to posterosuperior) across the medial head of the gastrocnemius, up to the level of the knee joint (Fig 17). Distally, the release is extended to the level of the



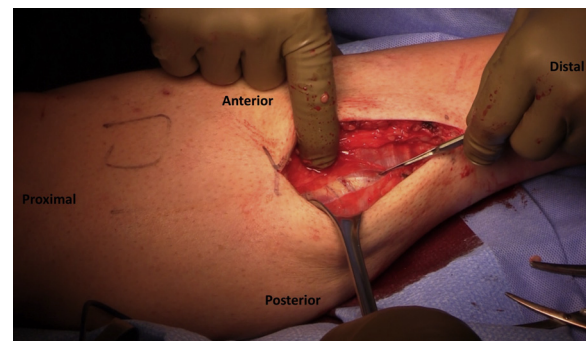
**Fig 14.** Incision for superficial posterior and deep posterior compartment fasciotomies of the left leg. Posterior compartment fasciotomies are performed through an incision placed 2 cm posterior to the medial tibial border at the middle third of the leg. These compartments are released with the tourniquet down to aid in saphenous vein and posterior tibial neurovascular bundle.



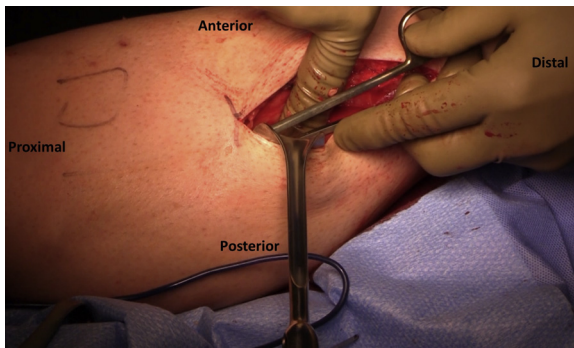
**Fig 15.** Superficial posterior and deep posterior compartment fasciotomies of the left leg. Subcutaneous dissection reveals the saphenous nerve and vein, and these structures are isolated and mobilized off the fascia.

distal Achilles tendon with special care to avoid the sural nerve.

Once the superficial posterior compartment is released, the posterior neurovascular bundle (posterior tibial artery/vein, tibial nerve) may be visualized within the deep posterior compartment, posterior to the medial border of the tibia (Fig 18). As previously noted, tourniquet release prior to superficial and deep posterior compartment fasciotomies aids in visualization of the posterior neurovascular bundle. Any vessels crossing over the deep posterior compartment are ligated with curved Kelly clamps and electrocautery or are tied off with 2-0 Silk (Fig 19). To gain access to the proximal portion of the deep posterior compartment, the soleus bridge (soft tissue connection between the soleus muscle and the periosteum of the tibia)<sup>5</sup> must be released. To begin the deep posterior compartment release, a 1-cm superficial incision is made 1 cm medial to the medial border of the tibia. The deep posterior compartment fascia and the soleus bridge are released simultaneously by running a periosteal elevator or finger along the posteromedial border of the tibia (Fig 20). Directly visualized fascia is released using Metzenbaum scissors. Distally, release



**Fig 16.** Superficial posterior compartment fasciotomy of the left leg. An approximately 5-cm incision is made in the fascia using a scalpel under direct visualization.

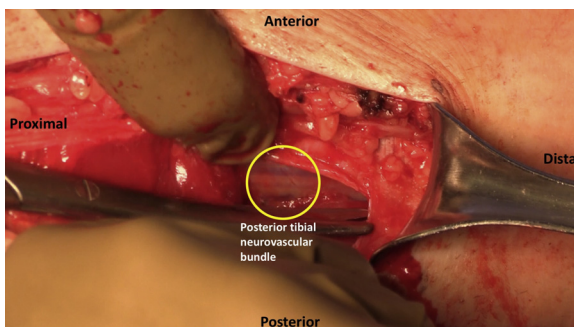


**Fig 17.** Superficial posterior compartment fasciotomy of the left leg. With Metzenbaum scissors, this incision is then extended proximally and diagonally (anteroinferior to posterosuperior) across the medial head of the gastrocnemius, up to the level of the knee joint. Distally, the release is extended to the level of the distal Achilles tendon with special care to avoid the sural nerve.

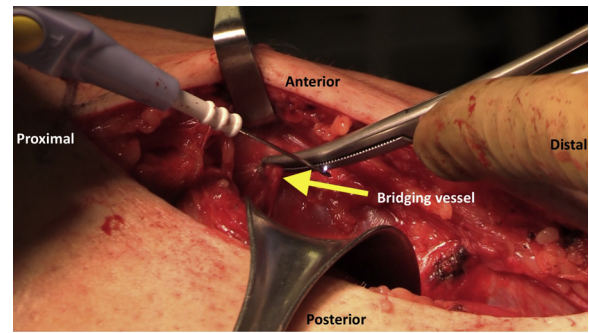
is completed toward the posterior aspect of the medial malleolus (Fig 21).

### Postoperative Rehabilitation

The optimal postoperative rehabilitation program after elective fasciotomy has not been established. Presented here is the preferred protocol of the senior surgeon (L.M.J.) used in all patient groups. Patient response is variable, and many patients are able to advance activity faster than the rehabilitation guidelines allow. The senior author (L.M.J.) allows advancement as tolerated as long as the patient is pain-free and reports excellent outcomes with this approach. Another author (M.A.Z.) has seen overly aggressive progression in some high-level and combat athletes, and anecdotally notes chronic residual pain along the fasciotomy when progression is too rapid. In this subset of highly motivated patients, he considers increased supervision, strict adherence to the “pain-free” protocol, and addition of a controlled ankle motion (CAM) boot during phase I and phase II (except for rehabilitation and sleep).



**Fig 18.** Superficial posterior compartment fasciotomy of the left leg. Distally, the release is extended to the level of the distal Achilles tendon with special care to avoid the sural nerve.



**Fig 19.** Deep posterior compartment fasciotomy of the left leg. The soleal sling is identified. Bridging vessels in this region are common and are carefully isolated and coagulated or tied off to decrease hematoma risk.

### Phase I (day 1-14 postoperation)

Goals: Pain management, wound healing, swelling control

Modalities: Ice, elevation, compression

Weightbearing: Crutches and partial weightbearing, consider CAM boot

Range of motion (ROM)/stretching: Unrestricted nonweightbearing dorsiflexion/plantarflexion

Exercises: Unresisted ankle plantarflexion/dorsiflexion

### Phase II (weeks 2-4 postoperation)

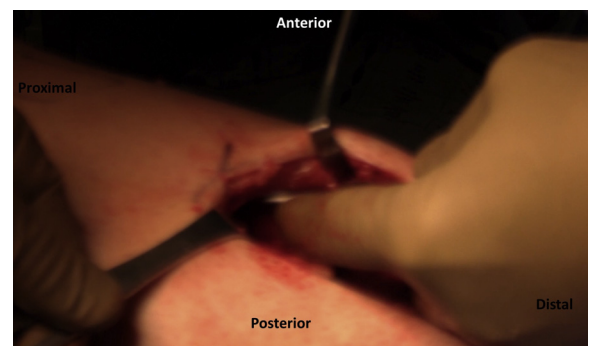
Goal: Normal ankle ROM

Modalities: Ice, compression stockings

Weightbearing: Wean crutches, progress to full weightbearing as tolerated, consider CAM boot

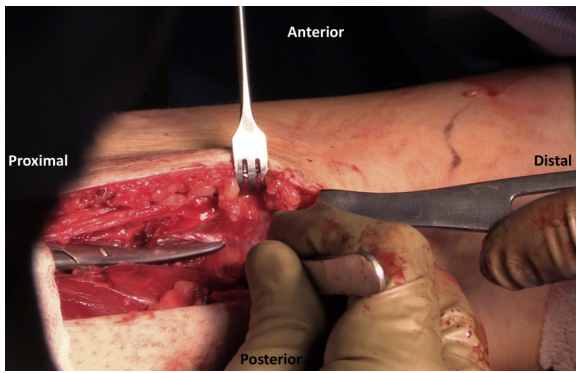
ROM: Begin alphabet/ankle rotation exercises, dorsiflexion towel stretches

Exercises: Progression—light TheraBand dorsiflexion/plantarflexion and inversion/eversion (seated), seated BAPS (biomechanical ankle



**Fig 20.** Deep posterior compartment fasciotomy of the left leg. The soleal sling is divided approximately 1 cm off the medial tibial border and released proximally in a controlled manner with a medium key elevator.





**Fig 21.** Deep posterior compartment fasciotomy of the left leg. The deep compartment fascia is identified as it continues distally and is released while retracting the bundle away from the fasciotomy location.

platform system) board, pain-free calf-press and leg-press, limited to <25% body weight.

#### Phase III (weeks 4-6 postoperation)

Goal: Improved ankle strength, normal gait pattern maintained for at least 1 mile

Modalities: Ice, compression stockings, scar massage

Weightbearing: weightbearing as tolerated, discontinue CAM boot if used

ROM/stretching: Full and unrestricted, continue towel stretches as needed

Exercises: Progression—TheraBand, progress to standing and increase resistance; mini-squats to wall squats; double-leg heel raise to single-leg heel raise; standing double-leg BAPS board progressing to single-leg/ball toss/body blade; pain-free cardio—treadmill (forward and backward), elliptical, and pool therapy running

#### Phase IV (weeks 6-12 postoperation)

Goals: 45 minutes of low-impact cardio, resistance weight training at 90% normal

Modalities: Ice, compression stockings, scar massage as needed

Weightbearing: Unrestricted

ROM/stretching: Unrestricted

Exercises: Progression—weight machines: leg press, hip abduction/adduction, hamstring curls, leg extensions; slide board; sit-up and pushup progression; pain-free cardio—treadmill walking progression, StairMaster, and pool therapy

#### Phase V (weeks 12-16 postoperation)

Goals: Running (normal pace  $\times$  1 mile), return to sports

Modalities: None

Weightbearing: Unrestricted

ROM/stretching: Unrestricted

Exercises: Begin running progression, agility drills, and plyometrics when able to complete:

- (a) 3  $\times$  20 heel raises at 90% contralateral strength, and
- (b) pain-free 2-mile walk at 15 minutes/mile pace without swelling. Return to home gym/exercise program twice weekly as tolerated.

## Discussion

Study of clinical outcomes of patients treated for CECS demonstrate mixed results. In a study of 7 patients with CECS of the leg, ultrasound-guided fasciotomy was performed.<sup>12</sup> Comparison of preoperative and postoperative pain demonstrated a decrease in pain in all patients. All but 1 patient in the sample returned to presymptomatic exercise levels. Another study of 18 CECS patients showed significant improvement in Short Form 36-item Health Survey and EQ-5D scores and significant increases in the amount of patients that returned to preinjury or higher level of sport after single minimal incision fasciotomy.<sup>13</sup> Most studies showing the effectiveness of fasciotomy as a treatment option for CECS have small cohort sizes. A retrospective case-series study of 95 legs of CECS patients showed significant long-term improvement (measured by the Tegner Activity Score, numerical analog scale, Short Form-12) in patients' activity level and quality of life after undergoing single-incision fasciotomy.<sup>14</sup> When comparing CECS patients who had nonoperative treatment with those who undergo operative treatment, the operative group had higher satisfaction rates.<sup>15</sup> The operative group's satisfaction rates were higher in those who were in high school or college versus those who were postcollege.<sup>15</sup> Campano et al.<sup>2</sup> demonstrated in their systematic review of the literature that it is difficult to standardize clinical outcomes across studies. They offered a combined cumulative success rate of 66% (range, 48%-100%; standard deviation 15%).

Current available literature estimates the rate of nerve-related complications to be 5% and an 11% to 13% overall complication rate, which includes hemorrhage, infection, thromboembolism, vascular injury, and skin breakdown (Table 2).<sup>2,14,16-18</sup> The superficial peroneal nerve (SPN) typically originates from the common peroneal nerve at or distal to the level of the fibular neck and travels through the lateral compartment as it supplies motor and sensory innervation to the lower leg.<sup>19</sup> However, studies have shown that the SPN can originate proximal to the fibular neck and can also travel through the anterior compartment of the leg.<sup>20-23</sup> Ducic et al.<sup>19</sup> dissected 111 legs and discovered the SPN traveled through the lateral compartment in 69.4% of the legs, through the anterior compartment in 8.1% of the legs, had branches in both the anterior and lateral compartments in 16.2% of the

**Table 2.** Pearls, Pitfalls, and Complications

Pearls	Pitfalls	Complications
The superficial peroneal nerve (SPN) should be directly visualized, carefully mobilized and retracted	Scissor open too wide increases risk of neurovascular injury	Nerve-related injury (superficial peroneal nerve, saphenous nerve)
Tips of Metzenbaum scissors should always point superficially and away from neurovascular structures	If tips of scissors disengage prematurely from the fascial edge, further blind attempts should not be made A small counterincision is preferred instead	Infection
A single, sliding motion should be used to perform releases	Insufficient release proximally and/or distally	Hematoma/seroma
Medial compartment release should be performed with the tourniquet down to aid in visualization of the saphenous vein and posterior tibial neurovascular bundle		Wound dehiscence
Bridging vessels overlying the soleal sling should be tied off or coagulated		Deep vein thrombosis
Portions of the deep posterior compartment fascia that are not directly visualized should be released using blunt finger dissection and/or key elevator		Lymphocele

legs, and was within the intermuscular septum in 6.3% of the legs. It is therefore essential to understand the anatomic variability of the SPN to perform successful fasciotomy and avoid iatrogenic nerve damage.

### Advantages and Disadvantages

There are inherent advantages and disadvantages to all surgical techniques. The described multiple-incision technique, in our practice, has helped to produce consistent results while limiting the complications of elective fasciotomy. The advantages and disadvantages of our technique are listed in [Table 3](#). In particular, direct visualization of the neurologic structures both medially and laterally carries significant benefit. Iatrogenic injury is exceedingly uncommon with such visualization. The surgeon can also directly decompress the nerve at its fascial perforation. Residual entrapment at this perforation, even in the setting of a complete fasciotomy, can cause residual symptomatology. Because of the increased proximal-distal spread of incisions laterally, there is greater access to control bleeding intraoperatively with the tourniquet released, limiting postoperative hematomas and associated wound complications. Finally, the

surgeon can confirm a complete fasciotomy either visually or manually along the entire length of the leg, which is particularly useful in considering the condition of recalcitrant cases postoperatively.

Despite these benefits, the use of multiple incisions may cause increased pain and cosmetic morbidity for patients. The lateral skin bridge has potential for cutaneous vascular compromise if incisions are placed in close proximity with one another or if the bridge is undermined too aggressively. Additionally, the medial incision has been the most painful and most frequently implicated incision for wound healing complications, which may be avoided using a laterally based technique for the superficial and deep posterior fasciotomy in exchange for other potential risks. Although our experience has shown more consistent results using the multiple incision technique presented here, several authors have reported equivalent success rates in their practices using minimally invasive single incision or endoscopic fasciotomies. It is therefore important for surgeons to evaluate their own preferred risk-benefit profile when identifying their preferred technique.

**Table 3.** Advantages and Disadvantages

Advantages	Risks/Limitations
Multiple-incision technique	Pain: multiple incisions
Direct visualization/protection of nerves	Cosmesis: multiple scars
Controlled-release/external neurolysis at fascial perforation	Skin bridge: potential for more cutaneous vascular compromise/complications
Counterincisions: complete and controlled fasciotomy	Medial incision: potential healing concern, risk to posteromedial neurovascular bundle
Greater overall proximal-distal access to control sources of bleeding	

## References

- Waterman BR, Liu J, Newcomb R, Schoenfeld AJ, Orr JD, Belmont PJ Jr. Risk factors for chronic exertional compartment syndrome in a physically active military population. *Am J Sports Med* 2013;41:2545-2549.
- Campano D, Robaina JA, Kusnezov N, Dunn JC, Waterman BR. Surgical management for chronic exertional compartment syndrome of the leg: A systematic review of the literature. *Arthroscopy* 2016;32:1478-1486.
- Lohrer H, Nauck T. Endoscopically assisted release for exertional compartment syndromes of the lower leg. *Arch Orthop Trauma Surg* 2007;127:827-834.
- Wittstein J, Moorman CT 3rd, Levin LS. Endoscopic compartment release for chronic exertional compartment syndrome: Surgical technique and results. *Am J Sports Med* 2010;38:1661-1666.
- Knight JR, Daniels M, Robertson W. Endoscopic compartment release for chronic exertional compartment syndrome. *Arthrosc Tech* 2013;2:e187-e190.
- Pedowitz RA, Hargens AR, Mubarak SJ, Gershuni DH. Modified criteria for the objective diagnosis of chronic compartment syndrome of the leg. *Am J Sports Med* 1990;18:35-40.
- Aweid O, Del Buono A, Malliaras P, et al. Systematic review and recommendations for intracompartmental pressure monitoring in diagnosing chronic exertional compartment syndrome of the leg. *Clin J Sport Med* 2012;22:356-370.
- Winkes MB, Tseng CM, Pasmans HL, van der Crujisen-Raaijmakers M, Hoogeveen AR, Scheltinga MR. Accuracy of palpation-guided catheter placement for muscle pressure measurements in suspected deep posterior chronic exertional compartment syndrome of the lower leg: A magnetic resonance imaging study. *Am J Sports Med* 2016;44:2659-2666.
- Roscoe D, Roberts AJ, Hulse D. Intramuscular compartment pressure measurement in chronic exertional compartment syndrome: New and improved diagnostic criteria. *Am J Sports Med* 2015;43:392-398.
- van den Brand JG, Verleisdonk EJ, van der Werken C. Near infrared spectroscopy in the diagnosis of chronic exertional compartment syndrome. *Am J Sports Med* 2004;32:452-456.
- Ringler MD, Litwiller DV, Felmler JP, et al. MRI accurately detects chronic exertional compartment syndrome: A validation study. *Skeletal Radiol* 2013;42:385-392.
- Balius R, Bong DA, Ardevol J, Pedret C, Codina D, Dalmau A. Ultrasound-guided fasciotomy for anterior chronic exertional compartment syndrome of the leg. *J Ultrasound Med* 2016;35:823-829.
- Maffulli N, Loppini M, Spiezia F, D'Addona A, Maffulli GD. Single minimal incision fasciotomy for chronic exertional compartment syndrome of the lower leg. *J Orthop Surg Res* 2016;11:61.
- Drexler M, Rutenberg TF, Rozen N, et al. Single minimal incision fasciotomy for the treatment of chronic exertional compartment syndrome: Outcomes and complications. *Arch Orthop Trauma Surg* 2017;137:73-79.
- Packer JD, Day MS, Nguyen JT, Hobart SJ, Hannafin JA, Metzl JD. Functional outcomes and patient satisfaction after fasciotomy for chronic exertional compartment syndrome. *Am J Sports Med* 2013;41:430-436.
- de Fijter WM, Scheltinga MR, Luiting MG. Minimally invasive fasciotomy in chronic exertional compartment syndrome and fascial hernias of the anterior lower leg: Short- and long-term results. *Mil Med* 2006;171:399-403.
- Howard JL, Mohtadi NG, Wiley JP. Evaluation of outcomes in patients following surgical treatment of chronic exertional compartment syndrome in the leg. *Clin J Sport Med* 2000;10:176-184.
- Tucker AK. Chronic exertional compartment syndrome of the leg. *Curr Rev Musculoskelet Med* 2010;3:32-37.
- Ducic I, Dellon AL, Graw KS. The clinical importance of variations in the surgical anatomy of the superficial peroneal nerve in the mid-third of the lateral leg. *Ann Plast Surg* 2006;56:635-638.
- Barrett SL, Dellon AL, Rosson GD, Walters L. Superficial peroneal nerve (superficial fibularis nerve): The clinical implications of anatomic variability. *J Foot Ankle Surg* 2006;45:174-176.
- Adkison DP, Bosse MJ, Gaccione DR, Gabriel KR. Anatomical variations in the course of the superficial peroneal nerve. *J Bone Joint Surg Am* 1991;73:112-114.
- Aigner F, Longato S, Gardetto A, Deibl M, Fritsch H, Piza-Katzer H. Anatomic survey of the common fibular nerve and its branching pattern with regard to the intermuscular septa of the leg. *Clin Anat* 2004;17:503-512.
- Ryan W, Mahony N, Delaney M, O'Brien M, Murray P. Relationship of the common peroneal nerve and its branches to the head and neck of the fibula. *Clin Anat* 2003;16:501-505.