



ORIGINAL ARTICLE

## Autotransplant tissue selection criteria with or without stereomicroscopy in parathyroidectomy for treatment of renal hyperparathyroidism<sup>☆</sup>



Monique Nakayama Ohe<sup>a,\*</sup>, Rodrigo Oliveira Santos<sup>b</sup>, Murilo Catafesta das Neves<sup>b</sup>,  
Aluizio Barbosa Carvalho<sup>c</sup>, Ilda Sizue Kunii<sup>a</sup>, Márcio Abrahão<sup>b</sup>,  
Onivaldo Cervantes<sup>b</sup>, Marise Lazaretti-Castro<sup>a</sup>, José Gilberto Henriques Vieira<sup>a</sup>

<sup>a</sup> Department of Endocrinology and Metabology, Escola Paulista de Medicina, Universidade Federal de São Paulo (EPM-UNIFESP), São Paulo, SP, Brazil

<sup>b</sup> Department of Otorhinolaryngology, Head and Neck, Escola Paulista de Medicina, Universidade Federal de São Paulo (EPM-UNIFESP), São Paulo, SP, Brazil

<sup>c</sup> Department of Nephrology, Escola Paulista de Medicina, Universidade Federal de São Paulo (EPM-UNIFESP), São Paulo, SP, Brazil

Received 2 July 2013; accepted 24 January 2014

Available online 11 June 2014

### KEYWORDS

Parathyroid hormone;  
Hyperparathyroidism,  
secondary;  
Parathyroidectomy

### Abstract

**Introduction:** Several methods have been proposed to improve operative success in renal hyperparathyroidism.

**Objective:** To evaluate stereomicroscopy in parathyroid tissue selection for total parathyroidectomy with autotransplantation in secondary (SHPT)/tertiary (THPT) hyperparathyroidism.

**Methods:** 118 renal patients underwent surgery from April of 2000 to October 2009. They were divided into two groups: G1, 66 patients operated from April of 2000 to May of 2005, with tissue selection based on macroscopic observation; G2, 52 patients operated from March of 2008 to October 2009 with stereomicroscopy for tissue selection searching for the presence of adipose cells. All surgeries were performed by the same surgeon. Patients presented SHPT (dialysis treatment) or THPT (renal-grafted). Follow-up was 12–36 months. Intra-operative parathyroid hormone (PTH) was measured in 100/118 (84.7%) patients.

**Results:** Data are presented as means. G1 included 66 patients (38 SHPT, 24 females/14 males; 40.0 years of age; 28 THPT, 14 females/14 males; 44 years of age). G2 included 52 patients (29 SHPT, 11 females/18 males; 50.7 years of age; 23 THPT, 13 females/10 males, 44.4 years of age). SHPT patients from G2 presented preoperative serum calcium higher than those of SHPT patients in G1 ( $p < 0.05$ ), suggesting a more severe disease. Definitive hypoparathyroidism was found in seven of 118 patients (5.9%). Graft-dependent recurrence occurred in four patients, two in each group. All occurred in dialysis patients.

<sup>☆</sup> Please cite this article as: Ohe MN, Santos RO, Neves MCD, Carvalho AB, Kunii IS, Abrahão M, et al. Autotransplant tissue selection criteria with or without stereomicroscopy in parathyroidectomy for treatment of renal hyperparathyroidism. Braz J Otorhinolaryngol. 2014;80:318–24.

\* Corresponding author.

E-mail: [moniqueohe@uol.com.br](mailto:moniqueohe@uol.com.br) (M.N. Ohe).

**PALAVRAS-CHAVE**

Hormônio paratireóideo; Hiperparatireoidismo secundário; Paratireoidectomia

**Conclusion:** Stereomicroscopy in SHPT/THPT surgical treatment may be a useful tool to standardize parathyroid tissue selection.

© 2014 Associação Brasileira de Otorrinolaringologia e Cirurgia Cérvico-Facial. Published by Elsevier Editora Ltda. All rights reserved.

### Influência do critério de seleção de tecido paratiroideano com ou sem estereomicroscopia para autoimplante no resultado do tratamento cirúrgico do hiperparatireoidismo associado a doença renal crônica

**Resumo**

**Introdução:** Diversos métodos têm sido propostos com intuito de melhorar índices de sucesso cirúrgico no tratamento do hiperparatireoidismo associado à doença renal crônica (DRC).

**Objetivos:** Avaliar uso do estereomicroscópio na seleção de tecido paratiroideano na paratireoidectomia total com autoimplante em pacientes com DRC.

**Métodos:** 118 pacientes DRC operados entre 04/2000-10/2009 foram divididos em: G1-66 pacientes operados entre 04/2000-05/2005 cuja seleção de tecido foi realizada por método convencional (macroscopia); G2-52 pacientes operados entre 03/2008-10/2009, cuja seleção de tecido foi realizada com uso da estereomicroscopia: Leica-Stereomicroscope (amplificação: 10×-80×). Pacientes foram ainda categorizados em hiperparatireoidismo secundário (HPS) ou terciário (HPT) (HPS-diálise/HPT-transplantados renais). Seguimento pós-operatório: 12-36 meses. PTH intraoperatório medido 100/118 pacientes (84.7%). Todos pacientes foram operados pelo mesmo cirurgião.

**Resultados:** Dados em média. G1, 66 pacientes (38 HPS, 24f/14m; 40 anos; 28 HPT, 14f/14m; 44 anos). G2, 52 pacientes (29 HPS, 11f/18m; 50,7 anos; 23 HPT, 13f/10m; 44,4 anos). Pacientes dialíticos do G2 apresentaram cálcio pré-operatório maior que G1 ( $p < 0,05$ ), sugerindo doença mais severa. Hiperparatireoidismo definitivo: 7/118 (5,9%) pacientes: G1, 4/66 (6%); G2, 3/52 (5,7%). Recorrência do hiperparatireoidismo no autoimplante: 4 pacientes, 2 em cada grupo. Todas foram em pacientes em diálise.

**Conclusão:** Estereomicroscopia no tratamento do hiperparatireoidismo associado à DRC é útil na padronização da técnica de seleção de tecido para o autoimplante.

© 2014 Associação Brasileira de Otorrinolaringologia e Cirurgia Cérvico-Facial. Publicado por Elsevier Editora Ltda. Todos os direitos reservados.

**Introduction**

The longer survival of chronic renal patients has increased the incidence of symptomatic hyperparathyroidism, increasing the need of surgical procedure.<sup>1</sup> The best surgical approach for renal hyperparathyroidism is still debated and controversy remains. Relevant questions have been raised regarding treatment election, since post-surgical recurrence and the risk of definitive hypoparathyroidism should be avoided. Total parathyroidectomy with parathyroid tissue autotransplantation is a well-accepted technique for the management of these patients.<sup>2-7</sup> Since recurrence rates of 8%<sup>8</sup> to 20%<sup>9</sup> and up to 76%<sup>10</sup> have been reported in the literature, the great majority graft-dependent, tissue selection for autotransplantation has been presented as a considerable challenge. Analysis of parathyroid hyperplastic tumors, using X-chromosome inactivation, have demonstrated that monoclonal transformation is a frequent occurrence in uremic patients.<sup>11</sup> In fact, the great majority (64%) of parathyroid glands with generalized hyperplasia (non-nodular component) were unequivocally monoclonal, as demonstrated by Arnold et al.<sup>11</sup> This finding imposes a difficult condition in parathyroid tissue selection for autotransplantation.

Intraoperative tissue selection of parathyroid fragments using a stereomagnifier was first described by Neyer et al. in 2002.<sup>12</sup> The technique can differentiate parathyroid non-motrophic areas by the presence of stromal fat cells from those that are dysfunctional and hyperplastic tissue without fat cells.<sup>12</sup> Cells from these lipid-containing areas present an optimal *in vitro* suppression of parathyroid hormone (PTH) secretion by high calcium levels,<sup>13</sup> indicating a normal calcium set-point and suggesting the eligibility for autotransplantation.

The aim of this study was to compare stereomicroscopy to conventional macroscopic observation in parathyroid tissue selection using a historical control, in order to provide a standardized procedure for renal hyperparathyroidism surgery.

**Patients and methods****Patients**

118 renal patients underwent total parathyroidectomy with intramuscular presternal autotransplantation<sup>7</sup> from April of 2000 to October of 2009. Patients were followed-up

at the Renal Osteodystrophy Unit in this institution and were referred to surgical treatment for persistent hypercalcemia not responsive to medical interventions and/or persistent hyperphosphatemia despite the continued use of dietary phosphorus restriction and phosphate-binding agents, with signs and symptoms such as intractable pruritus, severe bone pain, fractures or high risk of fracture, skeletal deformities, extra skeletal calcifications, development of calciphylaxis, and radiographic evidences of renal osteodystrophy.

Patients were divided into two groups: group 1 (G1) consisted of 66 patients who underwent surgery from April of 2000 to May of 2005, and parathyroid tissue selection for autotransplantation was performed using conventional technique based on macroscopic parathyroid tissue observation by a single experienced surgeon; group 2 (G2) consisted of 52 patients who underwent surgery from March of 2008 to October of 2009, and parathyroid tissue selection for autotransplantation was performed by the same surgeon as G1, based on stereomicroscopy observation using a Leica Stereo Zoom S8 APO Stereomicroscope (Leica Microsystems GmbH – Wetzlar, Germany), with magnification of 10–80 $\times$ .

Patients were classified as secondary or tertiary hyperparathyroidism: secondary hyperparathyroidism (SHPT) was characterized as an acquired disorder observed in end-stage renal disease, in which the uremic state presents a continuous stimulus to the parathyroid glands. The SHPT group included patients under dialysis treatment who presented severe hyperparathyroidism with normal or high serum calcium levels. The tertiary hyperparathyroidism (THPT) group comprised renal patients with functioning kidney transplant and nonsuppressible parathyroid hyperplasia, with persistent increased PTH levels and hypercalcemia. Hypercalcemia after kidney transplantation is usually due to hyperparathyroidism that persists from the preceding chronic kidney disease period.<sup>14</sup>

Surgical cure was defined as restoration of serum calcium and PTH levels<sup>14</sup> throughout the first six months after surgery. Recurrence was defined when high levels of PTH were observed throughout late post-operative follow-up (one year after surgical procedure) that failed to respond to medical/pharmacological management. Definitive hypoparathyroidism was defined when PTH measurements under 10 pg/mL endured one year after parathyroidectomy, with normal or low serum calcium levels under vitamin D and oral calcium supplementation.

Serum ionized calcium (iCa), phosphorus (P), alkaline phosphatase (AP), and intact parathyroid hormone (iPTH) were measured before parathyroidectomy and every six months after surgery in all patients from both groups.

Regarding the follow-up, patients from both groups were followed-up after surgery on a regular basis in the Renal Osteodystrophy Unit, and patient data from medical reports were available for this study. Patients from G1 underwent surgery from 2000 to 2005, while patients from G2 underwent surgery from 2008 to 2009. Thus, for surgical outcome analysis, the first 36 months were the period selected for study in both groups, since it was the longest period available for G2 patients.

## Methods

### Study design

This was a comparative study using a historical control, evaluating stereomicroscopy in comparison to conventional macroscopic technique in parathyroid tissue selection in surgical treatment of renal hyperparathyroidism.

This investigation was approved by the institutional ethics committee (approval No. CEP 0234/06) and patients signed an informed consent prior to their inclusion in the study.

### Surgical strategy

Bilateral cervical exploration with at least four-gland excision confirmed by frozen section examination and/or intra-operative PTH (IO-PTH) measurement was performed in all 118 patients (IO-PTH available in 100 patients).

Removed parathyroid glands were carefully examined in order to select a parathyroid area (non-nodular region) for implant and cryopreservation. The selected parathyroid fragment was gently diced into small pieces measuring approximately 2.0 mm<sup>3</sup>. Approximately 30 parathyroid fragments were implanted in presternal musculature over a single area of 1.5 cm in length.<sup>7</sup> Another 30 fragments were selected for cryopreservation. The reasons for changing the grafted area from the forearm to the presternal musculature are related to some potential advantages. First, it preserves the forearm for arterio-venous-fistula dialysis if needed. Second, the presternal region is close to the cervicotomy, exposing the same surgical area. Third, it allows for an easier graft-removal in case of graft-dependent recurrence; the sternal bone presents a posterior boundary for the grafted tissue, enabling a graft removal under local anesthesia.<sup>7</sup> All surgeries were performed by the same surgeon in both groups G1 and G2.

### Protocol for intraoperative tissue selection

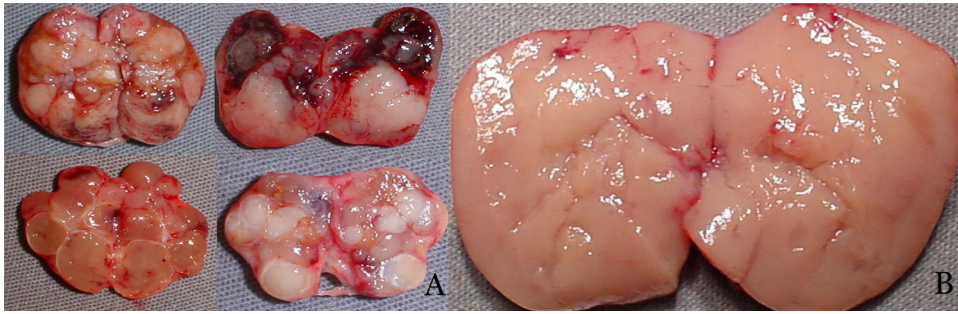
*Group 1* – Conventional technique: tissue selection for autotransplantation based on macroscopic parathyroid observation was performed in 66 patients. Nodular parathyroid regions were avoided, while hyperplastic non-nodular parathyroid areas were considered eligible for autotransplantation (Fig. 1).

*Group 2* – Stereomicroscopy: parathyroid tissue selection using Leica Stereo Zoom S8 APO Stereomicroscope (Leica Microsystems GmbH – Wetzlar, Germany) with apochromatic 8:1 zoom, 10–80 $\times$  magnification, was performed in 52 patients. Resected parathyroid glands were first observed macroscopically, and stereomicroscopic analysis was performed thereafter, searching for the presence of stromal fat cells in the parathyroid glands (Fig. 2, arrows).

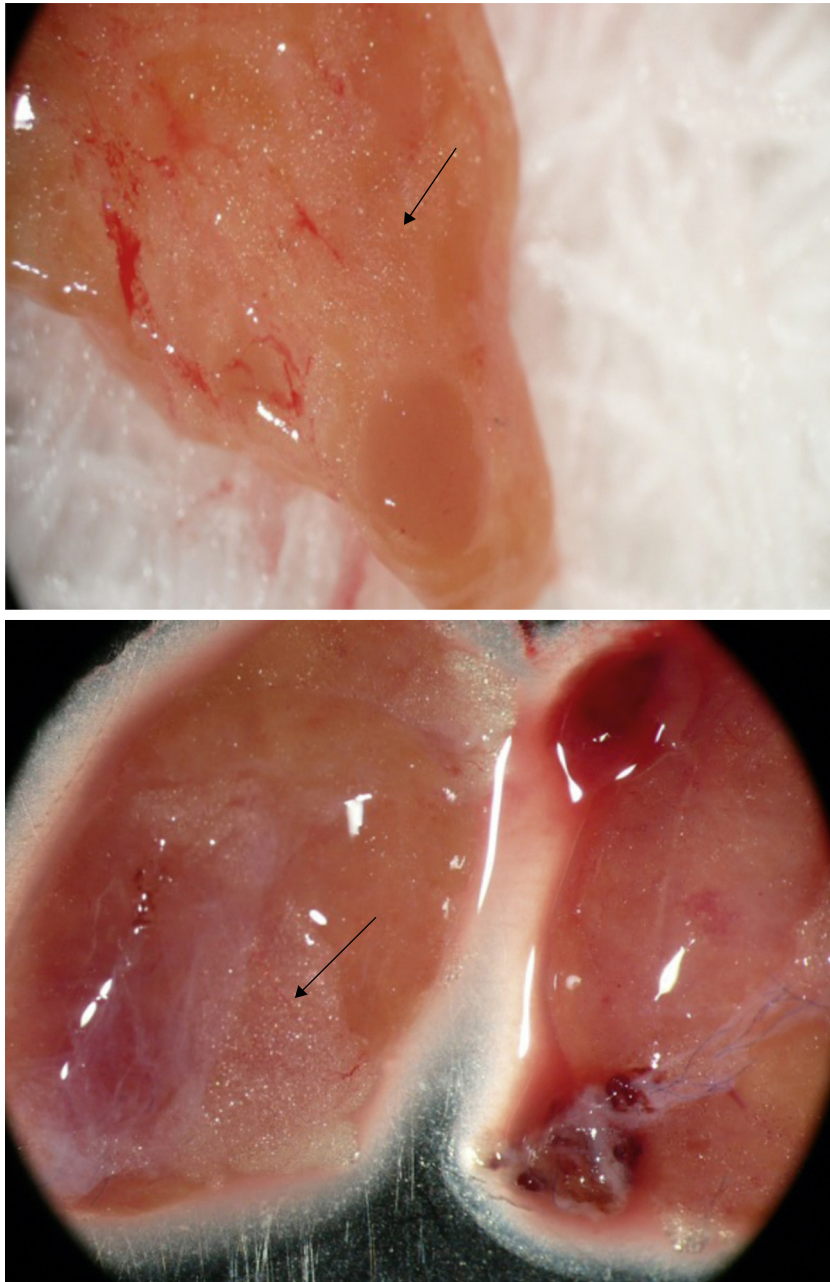
### Biochemistry

IO-PTH was performed to confirm total removal of the parathyroid glands, in order to avoid overlooking remaining or supernumerary hyperfunctioning glands. IO-PTH was





**Figure 1** Macroscopic parathyroid tissue observation: A, nodular parathyroid regions not eligible for autotransplantation; B, hyperplastic non-nodular parathyroid area eligible for autotransplantation.



**Figure 2** Stromal fat cells (arrows) in resected parathyroid glands.

**Table 1** Pre-operative data and laboratory findings.

	G1 (n=66)		G2 (n=52)	
	SHPT	THPT	SHPT	THPT
n	38	28	29	23
Age	40.0 (14–58)	44.0 (24–62)	50.7 (26–74)	44.4 (28–63)
Female/male	24/14	14/14	11/18	13/10
Years on dialysis	7.7 (0.6–16)	6.5 (2–20)	7.9 (3–25)	6.4 (0.8–13)
Years of renal graft	–	2.8 (0.5–7)	–	3.3 (0.4–10)
Pre-op iCa	1.36 <sup>a</sup> (1.19–1.83)	1.59 (1.42–1.77)	1.41 <sup>a</sup> (1.21–1.59)	1.58 (1.41–1.90)
Pre-op iPTH	1618.7 (298–2500)	442.2 (109–1758)	1810.2 (561–3500)	465.8 (181–2237)

Reference values: iCa = 1.20–1.40 mmol/L; iPTH = 10–65 pg/mL.

Data expressed as mean and range.

SHPT, secondary hyperparathyroidism; THPT, tertiary hyperparathyroidism; iCa, serum ionized calcium; iPTH, intact parathyroid hormone.

<sup>a</sup> *t*-test: *p* < 0.05.

**Table 2** Post-operative mean iCa and iPTH in cured patients in G1-group (conventional).

		SHPT		THPT		
		iCa	iPTH	iCa	iPTH	
12 months	(n=34)	1.17	79.8	(n=25)	1.25	58.4
24 months	(n=29)	1.22	86.0	(n=19)	1.22	64.7
36 months	(n=21)	1.19	83.0	(n=16)	1.22	78.5

Reference values: iCa = 1.20–1.40 mmol/L; iPTH = 10–65 pg/mL.

Data expressed as means.

SHPT, secondary hyperparathyroidism; THPT, tertiary hyperparathyroidism; iCa, serum ionized calcium; iPTH, intact parathyroid hormone.

measured using the Elecsys PTH Immunoassay (Elecsys 1010 System; Roche – Mannheim, Germany) and was available for 100 patients (84.7%). The time required to perform the assay is nine minutes and reference values are 10–70 pg/mL. Peripheral venous blood sample (4.0 mL) was obtained immediately after induction of anesthesia and 20 min after removal of all parathyroid glands.<sup>15–17</sup>

Total serum calcium, phosphorus, total alkaline phosphatase, and creatinine were measured by means of standard automatic assays (Hitachi 912 – Roche). Serum ionized calcium was measured by using an ion-specific electrode (AVL 9180 Electrolyte Analyzer – Roswell, Georgia, United States). Parathyroid hormone in ambulatory conditions was measured by immunometric assay

(Immulite; Siemens – São Paulo, Brazil: reference values 10–65 pg/mL).

All removed parathyroid tissue underwent complete histopathology analysis.

## Results

Pre-operative data and laboratory findings are depicted in [Table 1](#).

Mean post-operative iPTH and iCa serum measurements during the follow-up of cured patients in both groups are shown in [Tables 2 and 3](#).

**Table 3** Post-operative mean iCa and iPTH in cured patients in G2-group (stereomicroscopy).

		SHPT		THPT		
		iCa	iPTH	iCa	iPTH	
12 months	(n=26)	1.15	61.3	(n=21)	1.20	60.8
24 months	(n=18)	1.09	113.2	(n=14)	1.18	65.0
36 months	(n=13)	1.13	125.4	(n=9)	1.22	80.1

Reference values: iCa = 1.20–1.40 mmol/L; iPTH = 10–65 pg/mL.

Data expressed as mean.

SHPT, secondary hyperparathyroidism; THPT, tertiary hyperparathyroidism; iCa, serum ionized calcium; iPTH, intact parathyroid hormone.

**Table 4** Graft-dependent recurrence in patients from G1 (2/66) – conventional technique, and from G2 (2/52) – stereomicroscopy.

	12 months		24 months		36 months	
	iCa	iPTH	iCa	iPTH	iCa	iPTH
Patient 1 (G1)	1.46	13	–	–	1.29	1165
Patient 2 (G1)	0.90	22	1.29	104	1.56	168
Patient 3 (G2)	1.49	70	1.40	717	1.49	940
Patient 4 (G2)	1.21	224	0.97	1259	–	–

Reference values: iCa = 1.20–1.40 mmol/L; iPTH = 10–65 pg/mL. iCa, serum ionized calcium; iPTH, intact parathyroid hormone.

Persistent hyperparathyroidism due to supernumerary parathyroid glands not recognized during surgical procedure was observed in two patients, one from each group; those patients were excluded from the study.

Definitive hypoparathyroidism was observed in 7/118 (5.9%) patients, 4/66 (6%) in G1, and 3/52 (5.7%) in G2.

Graft-dependent recurrence was observed in 4/118 (3.3%) patients, two in each group (G1, 2/66; 3.0% and G2, 2/52; 3.8%) (Table 4). All graft-dependent recurrences were observed in dialysis patients. None occurred in kidney-grafted patients.

## Discussion

Surgery for renal hyperparathyroidism is performed in Brazil in relatively few medical centers, sometimes leading to long waiting times and, consequently, to worse clinical conditions at the time of surgery. Throughout the years, the authors have observed a worsening in medical conditions among renal patients at the time of surgery, when comparing patients from G1 (surgeries performed from 04/2000 to 05/2005) to G2 (surgeries performed from 03/2008 to 10/2009). As observed in SHPT patients from G2, serum calcium levels were higher than those seen in SHPT patients from G1 (*t*-test; *p* < 0.05). This finding is in agreement with patients with a more severe disease and, moreover, these are indicators that patients in G2 underwent surgery in a worse condition. Thus, the apparently similar surgical results in graft-dependent recurrence observed between G1 and G2 (two recurrences in each group) could be assessed as a positive outcome for stereomicroscopy. The more severe disease observed in G2 may be the explanation for the finding of a similar recurrence in both groups. Since the macroscopic examination protocol used in G1 was performed by the same surgeon that also supervised the stereomicroscopy in G2, a fair comparison can be performed.

From the 118 overall patients, graft-dependent recurrence was observed only in four (3.3%). This can be considered a low graft-dependent recurrence rate compared to literature data.<sup>18–20</sup> Considering the gravity of the illness observed in these patients, the experience of the surgeon probably contributed to such a positive outcome.

The clearly abnormal macroscopic findings observed in removed parathyroid indicate the severity of the illness and impose an especially difficult challenge in tissue

selection. The effort for finding eligible areas for autotransplantation among abnormal parathyroid glands makes stereomicroscopy an interesting tool for its standardization. The search for stromal fat cells as previously described by Neyer et al.<sup>12</sup> may provide a reproducible technique for tissue selection in attempts to reach low graft-dependent recurrences rates, even for surgeons not so experienced in parathyroid surgeries.

Another important observation is that all graft-dependent recurrences were in dialysis patients. None occurred in kidney-grafted patients. It is probable that the continuous exposure of the grafted parathyroid tissue to uremic environment may be the main driver for tumor recurrence in patients under long-term dialysis treatment, independent of the surgical technique employed.

Post-operative PTH measurements during the follow-up of cured patients were similar in G1 and G2, as were definitive hypoparathyroidism rates.

As mentioned above, persistent hyperparathyroidism due to supernumerary parathyroid glands not recognized during surgical procedure was observed in two patients, one in each group and those patients were excluded from the study. Occurrence of supernumerary and/or ectopic parathyroid glands is more frequent among chronic kidney failure patients,<sup>21</sup> and this presents an important and additional challenge in surgical treatment of renal hyperparathyroidism.

Limitations are related to the heterogeneous characteristics of renal patients enrolled in this study, with their particular clinical and laboratory findings, and considering them as a group presents a real challenge, especially when a historical control is used. Another limitation is related to the severity of these patients: the marked illness and long-lasting renal condition makes them a special group, whose outcome would not be expected in ordinary patients with chronic renal disease. In addition, levels of 25-OH vitamin D were not available in this study.

## Conclusion

Stereomicroscopy in renal hyperparathyroidism surgical treatment may provide a standardized parathyroid tissue selection for autotransplantation, and is potentially helpful in obtaining a low incidence of graft-dependent recurrence. Additional controlled and randomized studies are necessary to confirm these results.

## Funding

This study was supported by FAPESP: N° 07/51056-5.

## Conflicts of interest

The authors declare no conflicts of interest.

## References

1. Monchik JM, Bendinelli C, Passero Jr MA, Roggin KK. Subcutaneous forearm transplantation of autologous parathyroid tissue in patients with renal hyperparathyroidism. *Surgery*. 1999;126:1152–8.
2. Wells Jr SA, Gunnells JC, Shelburne JD, Schneider AB, Sherwood LM. Transplantation of the parathyroid glands in man: clinical indications and results. *Surgery*. 1975;78:34–44.
3. Wells Jr SA, Ross 3rd AJ, Dale JK, Gray RS. Transplantation of the parathyroid glands: current status. *Surg Clin North Am*. 1979;59:167–77.
4. Packman KS, Demeure MJ. Indications for parathyroidectomy and extent of treatment for patients with secondary hyperparathyroidism. *Surg Clin North Am*. 1995;75:465–82.
5. Sokoll LJ, Drew H, Udelsman R. Intraoperative parathyroid hormone analysis: a study of 200 consecutive cases. *Clin Chem*. 2000;46:1662–8.
6. Weber KJ, Misra S, Lee KJ, Wilhelm SW, DeCresce R, Prinz RA. Intraoperative PTH monitoring in parathyroid hyperplasia requires stricter criteria for success. *Surgery*. 2004;136:1154–9.
7. Santos RO, Ohe M, Carvalho ABC, Neves MC, Kunii I, Lazaretti Castro M, et al. Total parathyroidectomy with presternal intramuscular autotransplantation in renal patients: a prospective study of 66 patients. *J Osteoporos*. 2012;2012 [serial online], Article ID 631243, 6 pp.
8. Tominaga Y, Uchida K, Haba T, Katayama A, Sato T, Hibi Y, et al. More than 1,000 cases of total parathyroidectomy with forearm autograft for renal hyperparathyroidism. *Am J Kidney Dis*. 2001;38 4 Suppl. 1:S168–71.
9. Tominaga Y, Matsuoka S, Sato T. Surgical indications and procedures of parathyroidectomy in patients with chronic kidney disease. *Ther Apher Dial*. 2005;9:44–7.
10. Hampl H, Steinmuller T, Stabell U, Klingenberg HJ, Schnoy N, Neuhaus P. Recurrent hyperparathyroidism after total parathyroidectomy and autotransplantation in patients with long-term hemodialysis. *Miner Electrolyte Metab*. 1991;17:256–60.
11. Arnold A, Brown MF, Ureña P, Gaz RD, Sarfati E, Drüek TB. Monoclonality of parathyroid tumors in chronic renal failure and in primary parathyroid hyperplasia. *J Clin Invest*. 1995;95:2047–53.
12. Neyer U, Hoerandner H, Haid A, Zimmermann G, Niederle B. Total parathyroidectomy with autotransplantation in renal hyperparathyroidism: low recurrence rates after intraoperative tissue selection. *Nephrol Dial Transplant*. 2002;17:625–9.
13. Niederle B, Hoerandner H, Roka R, Woloszczuk W. Morphologic and functional studies to prevent graft-dependent recurrence in renal osteodystrophy. *Surgery*. 1989;106:1043–8.
14. Kidney Disease: Improving Global Outcomes (KDIGO) CKD-MBD Work Group: KDIGO clinical practice guideline for the diagnosis, evaluation, prevention and treatment of chronic kidney disease-mineral and bone disorder (CKD-MBD). *Kidney Int Suppl*. 2009;(113):S1–130.
15. Ohe MN, Santos RO, Kunii IS, Carvalho AB, Abrahão M, Cervantes O, et al. Usefulness of a rapid immunometric assay for intraoperative parathyroid hormone measurements. *Braz J Med Biol Res*. 2003;36:715–21.
16. Ohe MN, Santos RO, Kunii IS, Carvalho AB, Abrahão M, Cervantes O, et al. Usefulness of intraoperative PTH measurement in primary and secondary hyperparathyroidism: experience in 109 patients. *Arq Bras Endocrinol Metabol*. 2006;50:869–75.
17. Ohe MN, Santos RO, Kunii IS, Carvalho AB, Abrahão M, Neves MC, et al. Intraoperative PTH cutoff definition to predict successful parathyroidectomy in secondary and tertiary hyperparathyroidism. *Braz J Otorhinolaryngol*. 2013;79:494–9.
18. Gagné ER, Ureña P, Leite-Silva S, Zingraff J, Chevalier A, Sarfati E, et al. Short- and long-term efficacy of total parathyroidectomy with immediate autografting compared with subtotal parathyroidectomy in hemodialysis patients. *J Am Soc Nephrol*. 1992;3:1008–17.
19. Higgins RM, Richardson AJ, Ratcliffe PJ, Woods CG, Oliver DO, Morris PJ. Total parathyroidectomy alone or with autografty for renal hyperparathyroidism? *Q J Med*. 1991;79(288):323–32.
20. Tominaga Y, Nuomano M, Tanaka Y, Uchida K, Takagi H. Surgical treatment of renal hyperparathyroidism. *Semin Surg Oncol*. 1997;13:87–96.
21. Montenegro FL, Tavares MR, Cordeiro AC, Ferraz AR, Ianhez LE, Buchpiguel CA. Intrathyroidal supernumerary parathyroid gland in hyperparathyroidism after renal transplantation. *Nephrol Dial Transplant*. 2007;22:293–5.