



Computed tomography evaluation of fat infiltration ratio of the multifidus muscle in chronic low back pain patients

Marcel Prasetyo^{a,*}, Nadia Nindita^a, I Nyoman Murdana^b, Joedo Prihartono^c, Stefanus Imanuel Setiawan^a

^a Department of Radiology, Faculty of Medicine Universitas Indonesia – Dr. Cipto Mangunkusumo National Central General Hospital, Jakarta, Indonesia

^b Department of Physical Medicine and Rehabilitation, Faculty of Medicine Universitas Indonesia – Dr. Cipto Mangunkusumo National Central General Hospital, Jakarta, Indonesia

^c Departement of Community Medicine, Faculty of Medicine Universitas Indonesia, Jakarta, Indonesia

ARTICLE INFO

Keywords:

CT
Chronic low back pain
Fat infiltration ratio
Multifidus muscle

ABSTRACT

Background and objectives: Fat infiltration of multifidus muscle is an important parameter to assess the efficacy of spinal stabilization training in chronic low back pain (LBP) patients. As a CT scan shows a specific attenuation value for fat, it can be used as a ratio to evaluate fat infiltration of the muscle relative to its cross-sectional area. This study aims to compare the fat infiltration ratio of multifidus muscle between subjects with and without chronic LBP in Indonesia.

Methods: Comparative cross-sectional study of 20 subjects with chronic LBP and 20 subjects without LBP. Fat infiltration ratio calculation of the multifidus muscle was obtained from the database of abdominal CT at the level of the superior and inferior endplate of L4 and L5 vertebral body.

Results: The fat infiltration ratio of multifidus muscle in the chronic LBP subjects group was significantly higher than the subjects group without NPB ($p < 0.05$). The cut-off value of the fat infiltration ratio at the level of the inferior endplate of L4 was 0.125 (75 % sensitivity and 80 % specificity).

Conclusion: The calculation of the multifidus muscle fat infiltration ratio at the inferior endplate L4 using CT is a potential method to evaluate multifidus muscle quality in chronic LBP patients.

1. Introduction

Based on the *Global Burden of Disease* (GBD) research, low back pain (LBP) placed first as the leading cause of disability [1]. Lumbar instability acts as an important cause of chronic LBP [2]. Therefore, the assessment of paraspinal muscle morphology, especially the multifidus, becomes the focus in evaluating the etiology, prognosis and management of chronic LBP [3,4]. The examination of the total cross-sectional area of the multifidus muscle using Computed Tomography (CT) scan and Magnetic Resonance Imaging (MRI) have been used in evaluating the effectivity of selective spinal stabilization exercise of the chronic LBP patients. Previous studies by Chung et al. (2013) and Kim et al. (2014) showed a significant increment of the multifidus muscle cross-sectional area after eight weeks of spinal stabilization exercise compared to the

condition before the exercise [5,6].

In evaluating muscle fat infiltration, the MRI has become the favored modality due to its superiority in the identification of muscle volume and fat content [7,8]. Moreover, the MRIs do not use radiation, but utilizing the radio waves and magnetic field [9]. Initially, the semi-quantitative methods, the Goutallier classification, were used in evaluating intramuscular fat infiltration [10,11]. However, this method relies on subjective visual observation and has the potency to fail in detecting a small amount of intramuscular fat infiltration [12]. The other alternative method in assessing fat infiltration is the estimation of muscle cross-sectional area without fat component by determining the area of interest surrounding the multifidus using the free-hand technique [13]. Nevertheless, this technique requires high precision and long processing time which makes it less effective and prone to

Abbreviations: LBP, Low Back pain; CT, Computed Tomography; MRI, Magnetic Resonance Imaging; GBD, Global Burden of Disease; HU, Hounsfield Unit; BMI, body mass index; ODI, Oswestry Disability Index; ROC, Receiving Operating Characteristic; AUC, area under the curve.

* Corresponding author at: Jl. Diponegoro No.71, Jakarta Pusat, DKI Jakarta, 10430, Indonesia.

E-mail addresses: prasetyo.ui.ac@gmail.com, marcel71@ui.ac.id (M. Prasetyo).

<https://doi.org/10.1016/j.ejro.2020.100293>

Received 22 October 2020; Received in revised form 24 November 2020; Accepted 24 November 2020

2352-0477/© 2020 The Author(s). Published by Elsevier Ltd. This is an open access article under the CC BY-NC-ND license

(<http://creativecommons.org/licenses/by-nc-nd/4.0/>).

variations in calculating the results, notably in the atrophic muscle. This technique allows an automatic calculation of fat infiltration based on the difference between the signal intensity of the paraspinal muscles [14]. However, it requires additional software, which is considered costly and ineffective, especially in assessing the multifidus periodically.

CT scan, as an alternative modality of the paraspinal muscle imaging, offers a shorter time of examination compared to the MRIs. CT scan could differentiate the muscle and fat accurately based on their density in the unit of Hounsfield unit (HU). Keller et al. (2003) found that CT has good reliability in evaluating the cross-sectional area and the density of paraspinal muscles [15]. A previous study by Hu et al. (2011) showed that both CT and MRI performed equally in evaluating the atrophy of the multifidus and assessing the fat infiltration in chronic LBP patients [16]. Moreover, by using the software provided in the CT workstation utilizing the principal in depicting the fat based on its density, CT scan could estimate the fat infiltration in the multifidus thus the examination could be done semi-automatically without requiring additional software. In terms of radiation dose, by restricting the evaluation at a certain level of vertebrae, for example at the level of L4 superior endplate, CT scan only produces about 0.52 mSv, a smaller amount of radiation compared to conventional lumbar radiography [17–19]. The evaluation of the multifidus using the CT scan performed in the previous study was done by measuring the total cross-sectional area and the functional cross-sectional area of the multifidus [16]. Both of these values can be obtained by utilizing the difference between the pixel intensity in the CT scan to differentiate fat and muscle [20]. Meanwhile, the estimation of the fat infiltration ratio in this study utilized the difference of intensity (in HU) between fat and muscle based on the software in the CT workstation. No study has assessed the fat infiltration ratio of the multifidus in chronic LBP using the CT scan in Indonesia. This study aimed to analyze the difference between the multifidus fat infiltration ratio of the patients with chronic LBP and the normal population and to assess the cut-off value of the fat infiltration ratio in chronic LBP patients which could be used as an alternative in the routine evaluation of chronic LBP.

2. Materials and methods

A comparative cross-sectional study using abdominal CT scan data of both patients with LBP symptoms and patients without LBP. This study was conducted in the Department of Radiology, Dr. Cipto Mangunkusumo National Central General Hospital from December 2017 to March 2018. The inclusion criteria for the LBP group were patients aged 18–40 years old with normal body mass index (BMI) (17–25 kg/m²) and having persistent or recurrent LBP symptoms for more than 3 months. The inclusion criteria for the control group were patients aged 18–40 years old with normal BMI, having no LBP history and fulfill the minimal disability criteria of the Oswestry Disability Index (ODI). The exclusion criteria were patients with congenital abnormality of the spine (for example spina bifida, hemivertebrae, butterfly vertebrae and block vertebrae), lumbar scoliosis, an anatomical variant of the spine (for example lumbosacral transitional vertebrae), fracture of the vertebral body, spondylolisthesis, spondylosis, infection of the spine, malignancy or metastases of the spine, a history of the spine surgery and patients with a history of rehabilitation and physiotherapy related to the spine. Based on these criteria, a total of 24 subjects were included in the chronic LBP group and 20 subjects were included in the non-LBP group. This study was approved by the local Research and Ethics Committee. Each of the participants was given written informed consent and the patient data were kept anonymously and confidential.

The measurement of the multifidus cross-sectional area reaches its maximum value at the level of L4 superior endplate [12,20,21]. Furthermore, other studies showed that intramuscular fat infiltration increased in conjunction with the lower level of the lumbar [22,23]. By considering these results, the evaluation of fat infiltration ratio in the multifidus in this study was conducted at the level of L4-L5 endplate. In determining the fat cross-sectional area of the multifidus muscle in the

CT workstation, we built a reference area with a diameter of 1 cm at the back subcutaneous fat for determining the range between maximal and minimal fat density. We also set the range of interest (ROI) of the multifidus using the free-hand technique by drawing the ROI onto the fascia of multifidus at a level of the L4-L5 endplate. Automatically, the CT workstation would calculate the volume of the intramuscular fat content in the multifidus based on the range of fat density (HU). The fat cross-sectional area of the multifidus was calculated by dividing the intramuscular fat volume with the ROI (Fig. 1).

To determine the total cross-sectional area of the multifidus, we drawn the ROI onto the fascia of the multifidus at a level of L4-L5 endplate using the free-hand technique (Fig. 2). To prevent bias in the results, we conduct the measurements three times for each of the total and fat cross-sectional areas. Based on the results, we also calculate the ratio of the fat infiltration of the multifidus by dividing the fat cross-sectional area with the total cross-sectional area.

The validated data were entered into IBM SPSS 20 software for further analysis. The analysis for the normality was done by using the Shapiro Wilk test. For analyzing the difference between the multifidus fat infiltration ratio of the patients with chronic LBP and the normal population, we use the independent *t*-test analysis if the numerical data were distributed normally and the Mann Whitney test otherwise. The cut-off point of the fat infiltration ratio between the LBP group and the control group was determined by creating the Receiving Operating Characteristic Curve (ROC curve).

3. Results

A total of 24 subjects were included in the chronic LBP group and 20 subjects were included in the non-LBP group with the characteristic of the subjects described in Table 1. The Shapiro-Wilk normality test of the age, fat infiltration ratio and body mass index (BMI) variable showed a *P*-value less than 0.05 interpreted as a rejection of the null hypothesis that the data are normally distributed. Therefore, both numerical data was further analyzed in the form of the median. The median of the subject's age was 35.5 (18–39) years old in the chronic LBP group and significantly different (*P* < 0.05) compared to the non-LBP group which was 28 (18–39) years old. We also found a significant difference (*P* < 0.05) between the BMI median of the LBP group and the non-LBP group which was 20.6 (17.7–24.8) and 22.9 (17.4–24.9) kg/m² respectively.

The fat infiltration ratio at the level of L4 superior endplate and inferior endplate was significantly higher in the chronic LBP group compared to the control group (Table 2). We found the median of fat infiltration ratio at the level of L4 superior endplate was 0.11 (0.03–0.27) in the chronic LBP group and 0.18 (0.03–0.39) in the level of L4 inferior endplate. Further analysis showed a significant difference between the superior and inferior endplate fat infiltration ratio (*P* < 0.01).

The cut-off points of the fat infiltration ratio of the superior and the inferior endplate of the L4 vertebrae between the chronic LBP group and the control group were determined by creating the ROC curve. From the ROC curve, as shown in Fig. 3, we found the cut-off point of 0.075 at the level of the superior endplate of the L4 vertebrae with a sensitivity of 79.2 % and specificity of 65 % and 0.125 at the level of the inferior endplate with a sensitivity of 75 % and specificity of 80 %. The area under the curve (AUC) of 0.78 and 0.77 was shown at the superior endplate of the L4 and the inferior endplate respectively.

The fat infiltration ratio at the level of L5 superior-posterior endplate and inferior-posterior endplate also showed a significantly higher value in the chronic LBP group compared to the control group (Table 3). We found a significant difference between the superior-posterior and inferior-posterior endplate fat infiltration ratio (*P* = 0.041).

We determined the cut-off points of the fat infiltration ratio of the superior-posterior and the inferior-posterior endplate of the L5 vertebrae between the chronic LBP group and the control group using the

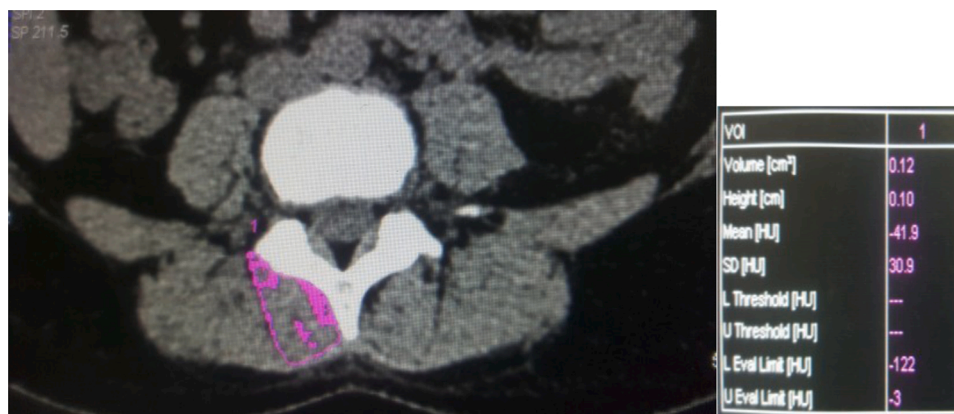

Fig. 1. An example of intramuscular fat volume measurement using the software in CT workstation.

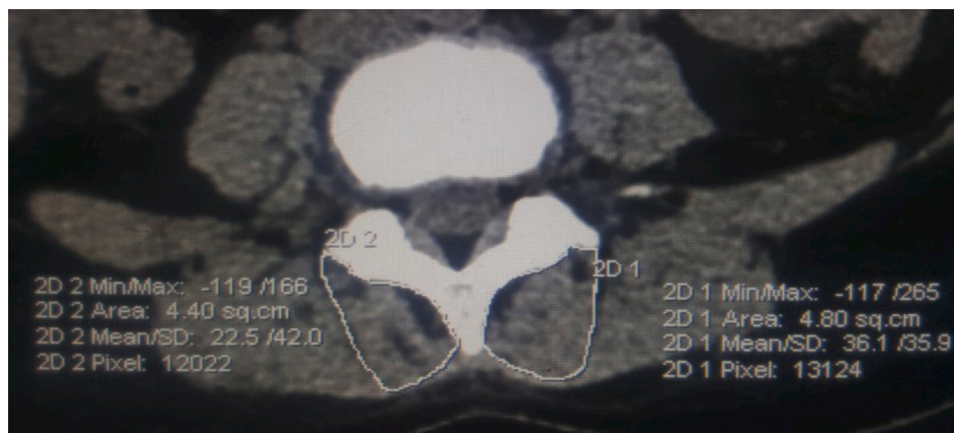

Fig. 2. An example of ROI determination to measure the total cross-sectional area of the multifidus.

Table 1
The characteristics of studied individuals.

Characteristics	Groups		P-value
	Chronic LBP N (%)	Non-LBP N (%)	
Gender			
Male	9 (37.5)	15 (62.5)	0.029
Female	15 (75.0)	5 (25.0)	
Age group			
18–30 years old	7 (35.0)	13 (65.0)	0.038
31–40 years old	17 (70.8)	7 (29.2)	
Body mass index (BMI)			
Underweight (<18.5 kg/m ²)	3 (75.0)	1 (25.0)	0.324
Normal (18.5–22.9 kg/m ²)	15 (60.0)	10 (40.0)	
Overweight (23–24.9 kg/m ²)	6 (40.0)	9 (60.0)	

Table 2
The median of fat infiltration ratio at the level of L4 vertebrae.

Fat infiltration ratio	Chronic LBP (n = 24) Median	Non-LBP (n = 20) Median	P-value
Superior endplate of the L4 vertebrae	0.11 (0.03–0.27)	0.07 (0.02–0.15)	0.001
Inferior endplate of the L4 vertebrae	0.18 (0.03–0.39)	0.08 (0.05–0.20)	0.002

ROC curve. The AUC of 0.81 and 0.76 were shown at the superior-posterior endplate of the L5 and the inferior-posterior endplate respectively. The cut-off points of 0.115 at the level of the superior-posterior endplate of the L5 was observed with a sensitivity of 75 % and specificity of 80 %. At the level of the inferior-posterior endplate of the L5, we found a cut-off point of 0.125 with a sensitivity of 66.7 % and specificity of 75 % (Fig. 4).

4. Discussion

From a total of 44 subjects, about 24 men and 20 women were included in this study with a higher number of women compared to men who suffered the chronic LBP with a ratio of 0.6:1 (Table 1). On other hand, the Global Burden of Disease 2010 data disagrees with our findings which found the prevalence rate of LBP higher in men compared to women due to physical activity and work-related factors [1]. However, Crawford et al. in 2016 showed that the degeneration of the multifidus marked by the increment of intramuscular fat accumulation and the decline of muscle volume more commonly found in women compared to men caused by the differences in body fat proportion and composition [13].

We divided the age variable into two groups, 18–30 years old and 31–40 years old. The incidence of chronic LBP was found higher in the 31–40 years old group compared to the younger group (Table 1). This results in line with a previous study by Hoy et al. which found the prevalence of LBP increasing with age and peaked at 80 years old [1]. Kjaer et al. (2007) and Vohra et al. (2016) also found that LBP related to fat infiltration in the multifidus is more commonly found in the adult age, especially in the age group of 31–40 years old [24,25].

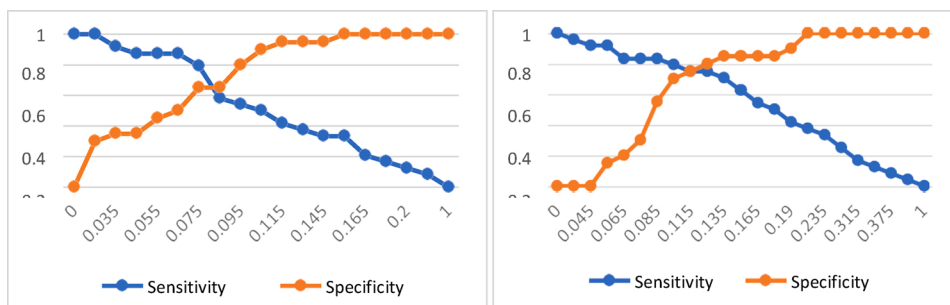


Fig. 3. ROC curve of the fat infiltration ratio of the multifidus at the level of the superior endplate of the L4 vertebrae (left) and the inferior endplate (right).

Table 3

The median of fat infiltration ratio at the level of L5 vertebrae.

Fat infiltration ratio	Chronic LBP (n = 24) Median	Non-LBP (n = 20) Median	P-value
Superior-posterior endplate of the L5 vertebrae	0.17 (0.05–0.43)	0.10 (0.03–0.17)	<0.001
Inferior-posterior endplate of the L5 vertebrae	0.19 (0.05–0.49)	0.12 (0.02–0.23)	0.003

There was no significant difference between the BMI of both the chronic LBP group and the non-LBP group (Table 1). This finding corresponds with other several studies that showed no correlation between body weight, body height, and BMI to the incidence of LBP [24,26].

4.1. The analysis of fat infiltration ratio of the patient with chronic LBP

We found a significantly higher fat infiltration ratio of the multifidus in the chronic LBP population on both the L4 and L5 levels of vertebrae endplate. Several previous findings correspond with this result [21,24,27,28]. These studies used MRI in evaluating the fat infiltration in the multifidus with additional software in calculating the total cross-sectional area and the fat cross-sectional area, whereas our study used a different modality, the CT scan, in assessing the intramuscular fatty infiltration. The ratio between the fat and the total cross-sectional area could be used in assessing functional muscle atrophy related to fat infiltration which further described the severity of the fatty infiltration.

However, several studies found no correlation between higher intramuscular fat infiltration in the LBP population. Herbert et al. (2014) evaluated quantitatively the fat infiltration of the multifidus using MRI and showed a non-consistent correlation between fat infiltration and LBP due to variation of the patient’s symptoms duration, from the acute phase to the chronic phase (≥ 30 days). To avoid this potential bias, we only include patients with a history of chronic LBP. The mechanism of intramuscular fat deposition in LBP patients is not well known, but it was hypothesized that the denervation and

inflammation of the paraspinal muscles are related to the differentiation of the fibroblast and pre-adipocyte which increase the accumulation of intramuscular fat content [29]. Kamath et al. (2008) found a progressive increment of muscle fat infiltration and atrophy weeks after denervation of the muscle and showed an alteration of signaling intensity resembling the edema process of the paraspinal muscles [30]. Another similar study by Danneels et al. (2000) using a histogram CT software showed no significant differences between fat infiltration of the chronic LBP population and the control group [20]. The evaluation method was different from what we use in this study by using a relative fat cross-sectional area obtained by the gap between the total and the fat cross-sectional area. Besides, the study by Danneels et al. involved chronic LBP patients with minimal disability, therefore the process of muscle disuse has not happened.

4.2. The analysis of fat infiltration ratio at the level of L4 and L5 endplate

The fat infiltration ratio at the level of L4 superior endplate and inferior endplate was significantly higher in the chronic LBP group compared to the control group (Table 2). Besides, we found the fat infiltration ratio cut-off point of 0.125 at the level of the inferior endplate with a sensitivity of 75 % and specificity of 80 %, which further classify the fat infiltration ratio into mild stage and moderate-severe stage (Fig. 5), and a significant difference between the superior and inferior endplate fat infiltration ratio ($P < 0.01$). Based on Crawford et al. (2016) study, the paraspinal intramuscular fat component at the level of L4 vertebrae represents the whole intramuscular fat component of the lumbar segment of the vertebrae [23]. Another study by Danneels et al. (2000) showed that at the level of the inferior endplate of L4, the cross-sectional area of the multifidus represents about one-third of the total cross-sectional area of the paraspinal muscles [20]. Based on these findings, the L4 vertebrae level, especially the endplate inferior of the L4 becomes the optimal location in determining the fat infiltration ratio.

The fat infiltration ratio at the level of L5 superior-posterior endplate and inferior-posterior endplate also showed a significantly higher value in the chronic LBP group compared to the control group (Table 3). These findings were concordance with several previous studies which showed

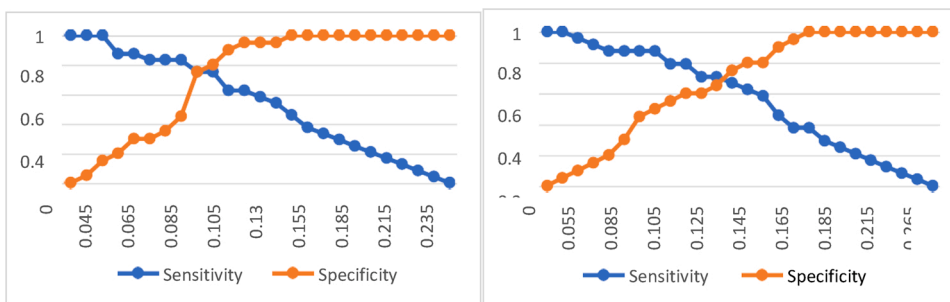


Fig. 4. ROC curve of the fat infiltration ratio of the multifidus at the level of the superior-posterior endplate of the L5 vertebrae (left) and the inferior-posterior endplate (right).

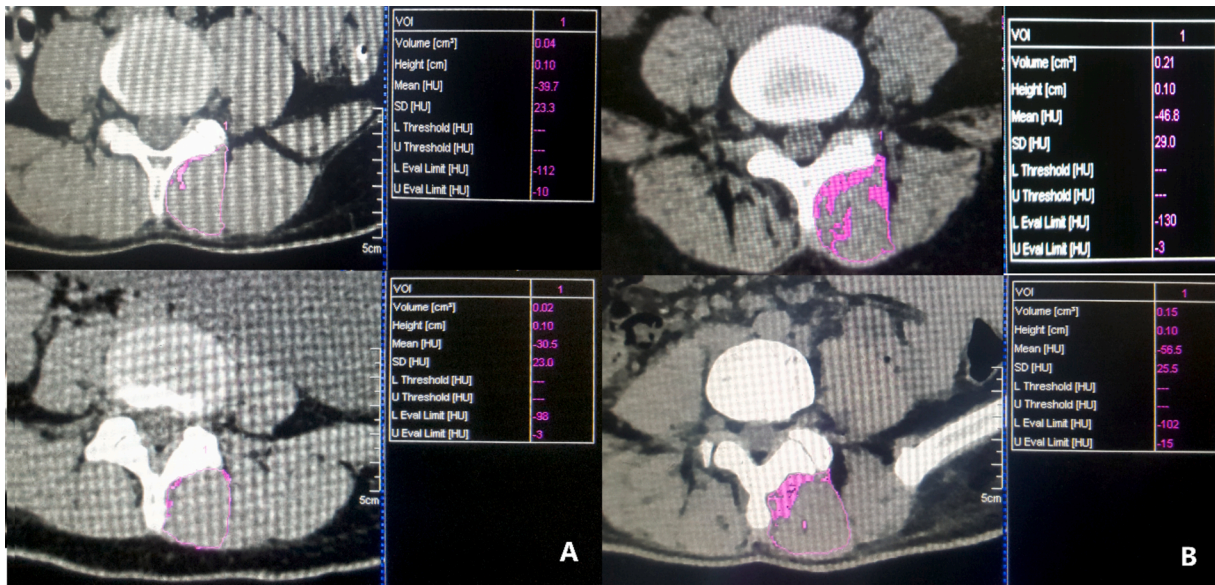


Fig. 5. Various degrees of fat infiltration ratio of the multifidus at the level of the inferior endplate of the L4 vertebrae. A. Mild degree of multifidus fat infiltration ratio. B. Moderate-severe degree of multifidus fat infiltration ratio.

an increment of both cross-sectional areas of the multifidus and fat infiltration volume at the lower level of the lumbar [12,20,24,31,32]. We found the fat infiltration ratio cut-off points of 0.115 at the level of the L5 superior-posterior endplate with a sensitivity of 75 % and

specificity of 80 %, higher compared to the inferior-posterior endplate. Several studies evaluated the fat content of the paraspinal muscles by assessing the intervertebral disc, endplate of the vertebral body or middle portion of the vertebrae after the determination of the

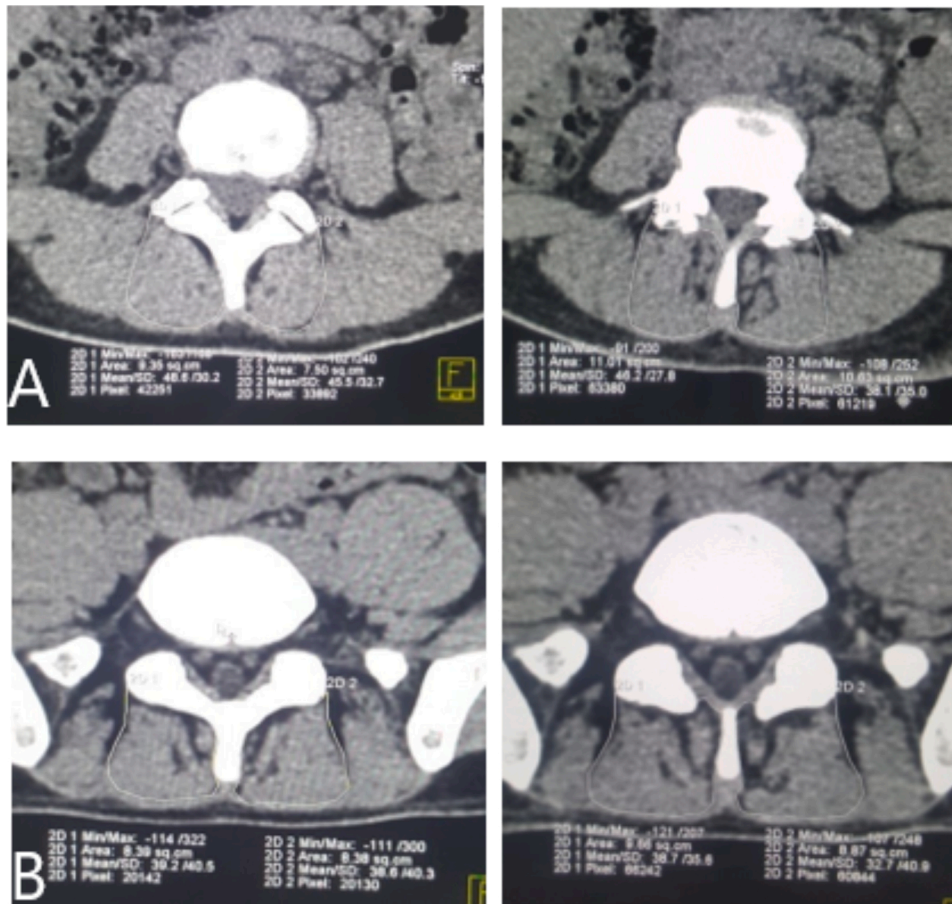


Fig. 6. The determination of ROI of the multifidus at the level of L5 vertebrae. A. Superior endplate of the L5 (left) and posterior-superior endplate of the L5 vertebrae (right). B. Inferior endplate of the L5 (left) and posterior-inferior endplate of the L5 vertebrae (right).

anatomical border as the standard of ROI determination [33]. However, at the level of L5, there was a variance in the slope at L5 which made most of the studies did not include the L5 level of the vertebrae in analysis and replaced it with L4 inferior endplate or the level of L4-L5 intervertebral disc. The CT scan has a limitation in adjusting the slope at the L5 vertebrae and could only evaluate the cross-sectional area perpendicular to the body axis. Therefore, our study evaluated the portion of L5 at the posterior-superior endplate and posterior-inferior endplate. Furthermore, due to the variance in the slope of L5 vertebrae, the determination of the anatomical border as the standard of ROI became not consistent and had the potential in lowering the reliability of the fat infiltration ratio at the level of L5 (Fig. 6).

We used secondary data of the patient with chronic LBP. Therefore, we cannot homogenize the patient's position during the CT scan examination to prevent the differences in the slope of the L5. For further study, the supination position with flexion of the hip and knee joint could be considered to reduce the degree of lumbar lordosis which further reduces the slope of the L5 vertebrae [20].

In this study, we also evaluate the correlation between the fat infiltration ratio with the degree of disability of the chronic LBP group using the classification of ODI. Patients with moderate-severe disability (8 (33.3 %) subjects) tend to have a higher fat infiltration ratio compared to the mild disability group (16 (66.7 %) subjects) but not statistically significant ($P > 0.05$). This finding was in line with Vohra et al. (2016) study which found a higher fat infiltration of the paraspinal according to the severity of the LBP [25].

5. Conclusion

Based on the results, the fat infiltration ratio at the level of both L4 and L5 vertebrae were significantly higher in the chronic LBP group compared to the control group. We found the fat infiltration ratio cut-off point of 0.125 at the level of the inferior endplate with a sensitivity of 75 % and specificity of 80 % could predict the incidence of chronic LBP. Further studies are needed, especially in assessing the fat infiltration ratio as the instrument in evaluating rehabilitative therapeutic results and other studies comparing the fat ratio with other frequently used methods such as Goutallier classification.

Ethical statements

This study was approved by the Research and Ethics Committee from the Faculty of Medicine Universitas Indonesia (Ethics number: 0192/UN2.F1/ETIK/2018) and Dr. Cipto Mangunkusumo Hospital. Each of the participants was given written informed consent and the patient data were kept anonymously and confidential. Patient data used in this study were kept anonymously and confidential.

The author(s) declare that this manuscript has not been published previously and not under consideration for publication elsewhere.

Funding statement

The author(s) received no financial support for the research, authorship, and/or publication of this article.

CRediT authorship contribution statement

Marcel Prasetyo: Conceptualization, Methodology, Writing - review & editing, Visualization, Supervision, Project administration. **Nadia Nindita:** Conceptualization, Data curation, Investigation, Writing - original draft. **I Nyoman Murdana:** Methodology, Investigation, Supervision. **Joedo Prihartono:** Formal analysis, Software, Supervision. **Stefanus Imanuel Setiawan:** Software, Data curation, Writing - review & editing, Project administration.

Declaration of Competing Interest

The authors report no declarations of interest.

References

- [1] D. Hoy, L. March, P. Brooks, F. Blyth, A. Woolf, C. Bain, et al., The global burden of low back pain: estimates from the Global Burden of Disease 2010 study, *Ann. Rheum. Dis.* 73 (2014) 968–974.
- [2] L.A. Danneels, A.M. Cools, G.G. Vanderstraeten, D.C. Cambier, E.E. Witvrouw, J. Bourgeois, et al., The effects of three different training modalities on the cross-sectional area of the paravertebral muscles, *Scand. J. Med. Sci. Sport* 11 (February) (2001) 335–341.
- [3] M. Fortin, L.G. Macedo, Multifidus and paraspinal muscle group cross-sectional areas of patients with low back pain and control patients: a systematic review with a focus on blinding, *Phys. Ther.* Sport 93 (7) (2013) 1–16.
- [4] M.D. Freeman, A. Woodham, M.D. Freeman, M.A. Woodham, A.W. Woodham, The role of the lumbar multifidus in chronic low back pain: a review, *Phys. Med. Rehabil. J.* 2 (2) (2010) 142–146.
- [5] S. Chung, J. Lee, J. Yoon, Effects of stabilization exercise using a ball on multifidus cross-sectional area in patients with chronic low back pain, *J. Sport Sci. Med.* 12 (March) (2013) 533–541.
- [6] S. Kim, H. Kim, J. Chung, Effects of spinal stabilization exercise on the cross-sectional areas of the lumbar multifidus and psoas major muscles, pain intensity, and lumbar muscle strength of patients with degenerative disc disease, *J. Phys. Ther. Sci.* 26 (4) (2014) 579–582.
- [7] J. Phoenix, D. Betal, N. Roberts, Objective quantification of muscle and fat in human dystrophic muscle by magnetic resonance image analysis, *Muscle Nerve* 19 (March) (1996) 302–310.
- [8] X.Y. Ruan, D. Gallagher, T. Harris, J. Albu, P. Kuznia, S. Heshka, Estimating whole body intermuscular adipose tissue from single cross-sectional magnetic resonance images, *J. Appl. Physiol.* 102 (2) (2009) 748–754.
- [9] T. Dill, Contraindications to magnetic resonance imaging, *Heart* 94 (2008) 943–948.
- [10] P.J. Battaglia, Y. Maeda, A. Welk, B. Hough, N. Kettner, Reliability of the goutallier classification quantifying muscle fatty degeneration in the lumbar multifidus using magnetic resonance imaging, *J. Manipul. Physiol. Ther.* 37 (3) (2014) 190–197.
- [11] B. Upadhyay, A.P. Toms, CT and MRI evaluation of paraspinal muscle degeneration. *European Congress of Radiology*, 2015, pp. 1–15.
- [12] J.C. Lee, J. Cha, Y. Kim, Y. Kim, Quantitative analysis of back muscle degeneration in the patients with the degenerative lumbar flat back using a digital image analysis comparison with the normal controls, *Spine* 33 (3) (2008) 318–325.
- [13] R.J. Crawford, J. Cornwall, R. Abbott, J.M. Elliott, Manually defining regions of interest when quantifying paravertebral muscles fatty infiltration from axial magnetic resonance imaging: a proposed method for the lumbar spine with anatomical cross-reference, *BMC Musculoskelet. Disord.* (2017).
- [14] D. Roseline, B. Cagnie, G. Crombez, G. Vanderstraeten, M. Dolphens, Increased intramuscular fatty infiltration without differences in lumbar muscle cross-sectional area during remission of unilateral recurrent low back pain, *Man. Ther.* [Internet] 17 (6) (2012) 584–588.
- [15] A. Keller, R. Gunderson, O. Reikerås, J.I. Brox, Reliability of computed tomography measurements of paraspinal muscle cross-sectional area and density in patients with chronic low back pain, *Spine* 28 (13) (2003) 1455–1460.
- [16] Z. Hu, S. Fan, An assessment of the intra- and inter-reliability of the lumbar paraspinal muscle parameters using CT scan and magnetic resonance imaging, *Spine (Phila Pa 1976)* 36 (13) (2011) 868–874.
- [17] J.A. Christner, J.M. Kofler, C.H. McCollough, Estimating effective dose for CT using dose-length product compared with using organ doses: consequences of adopting international commission on radiological protection publication 103 or dual-energy scanning, *Am. J. Radiol.* 194 (April) (2010) 881–889.
- [18] J.E. Costello, N.D. Cecava, J.E. Tucker, J.L. Bau, CT radiation dose: current controversies and dose reduction strategies, *Am. J. Radiol.* 201 (December) (2013) 1283–1290.
- [19] F.A. Mettler, W. Huda, T.T. Yoshizumi, M. Mahesh, Effective doses in radiology and diagnostic nuclear medicine: a catalogue, *Radiology* 248 (1) (2008) 254–263.
- [20] L.A. Danneels, G.G. Vanderstraeten, D.C. Cambier, E.E. Witvrouw, J. Bourgeois, W. Dankaerts, et al., Effects of three different training modalities on the cross sectional area of the lumbar multifidus muscle in patients with chronic low back pain, *Br. J. Sports Med.* 35 (2001) 186–191.
- [21] R. D'Hooge, B. Cagnie, G. Crombez, G. Vanderstraeten, M. Dolphens, L. Danneels, Increased intramuscular fatty infiltration without differences in lumbar muscle cross-sectional area during remission of unilateral recurrent low back pain, *Man. Ther.* 17 (6) (2012) 584–588.
- [22] K.L. Barker, D.R. Shamley, D. Jackson, Changes in the cross-sectional area of multifidus and psoas in patients with unilateral back pain the relationship to pain and disability, *Spine* 29 (22) (2004) 515–519.
- [23] X.R.J. Crawford, X.L. Filli, X.J.M. Elliott, X.D. Nanz, X.M.A. Fischer, X.M. Marcon, et al., Age- and level-dependence of fatty infiltration in lumbar paravertebral muscles of healthy volunteers, *Am. J. Neuroradiol.* 37 (April) (2016) 742–748.
- [24] P. Kjaer, T. Bendix, J.S. Sorensen, L. Korsholm, C. Leboeuf-yde, Are MRI-defined fat infiltrations in the multifidus muscles associated with low back pain? *BioMed. Cent. Med.* 5 (2) (2007) 1–10.

- [25] P. Vohra, V.P. Kasana, R.K. Arya, Role of MRI and ultrasonography in evaluation of multifidus muscle in chronic low back pain patients, *Int. J. Res. Med. Sci.* 4 (12) (2016) 5302–5309.
- [26] M. Kamaz, D. Kiresi, H. Oguz, D. Emlik, F. Levendoglu, CT measurement of trunk muscle areas in patients with chronic low back pain, *Diagn. Interv. Radiol.* 13 (18) (2007) 2007.
- [27] M.C. Battie, R. Niemelainen, L.E. Gibbons, S. Dhillon, Is level- and side-specific multifidus asymmetry a marker for lumbar disc pathology? *Spine J.* 12 (2012) 932–939.
- [28] B. Mengiardi, M.R. Schmid, N. Boos, C.W.A. Pfirrmann, F. Brunner, Fat content of lumbar paraspinal muscles in patients with chronic low back pain and in asymptomatic volunteers: quantification with MR spectroscopy, *Radiology* 240 (3) (2006) 786–792.
- [29] S. Kamath, N. Venkatanarasimha, M.A. Walsh, P.M. Hughes, MRI appearance of muscle denervation, *Skeletal Radiol.* 37 (2008) 397–404.
- [30] J.J. Hebert, P. Kjaer, J.M. Fritz, B.F. Walker, The relationship of lumbar multifidus muscle morphology to previous, current, and future low back pain, *Spine (Phila Pa 1976)* 39 (17) (2014) 1417–1425.
- [31] R. Neimelainen, M.-M. Briand, M.C. Battie, Substantial asymmetry in paraspinal muscle cross-sectional area in healthy adults questions its value as a marker of low back pain and pathology, *Spine (Phila Pa 1976)* 36 (25) (2011) 2152–2157.
- [32] S.J. Hyun, Y.B. Kim, Y.B.S. Kim, S.W. Park, T.K. Nam, H.J. Hong, et al., Postoperative changes in paraspinal muscle volume: comparison between paramedian interfascial and midline approaches for lumbar fusion, *J. Korean Med. Sci.* 22 (2007) 646–651.
- [33] R.J. Crawford, J. Cornwall, R. Abbott, J.M. Elliott, Manually defining regions of interest when quantifying paravertebral muscles fatty infiltration from axial magnetic resonance imaging: a proposed method for the lumbar spine with anatomical cross- reference, *BMC Musculoskelet. Disord.* 18 (25) (2017) 1–11.