

Contents lists available at [ScienceDirect](http://www.sciencedirect.com)

## International Journal of Surgery Case Reports

journal homepage: [www.casereports.com](http://www.casereports.com)

# A late unusual complication after an open cholecystectomy: Amputation neuroma of the CBD causing obstructive jaundice

Youssef A. Sleiman<sup>a</sup>, Ziad A. Hassoun<sup>a</sup>, Haydar A. Nasser<sup>a,\*</sup>, Leila Abs<sup>b</sup>, Mustafa Allouch<sup>a</sup>

<sup>a</sup> Nini Hospital, Department of General and Digestive Surgery, Tripoli, Lebanon

<sup>b</sup> Nini Hospital, Department of Radiology, Tripoli, Lebanon

## ARTICLE INFO

## Article history:

Received 9 January 2017

Received in revised form 19 July 2017

Accepted 19 July 2017

Available online 25 July 2017

## Keywords:

CBD

Amputation neuroma about a case report  
Cholecystectomy

## ABSTRACT

**INTRODUCTION:** Cholecystectomy is one of the most frequently done procedures in general surgery. There are few reports of amputation neuromas following this procedure. This presentation describes a case of obstructive jaundice due to amputation neuroma in a patient with a history of cholecystectomy.

**CASE PRESENTATION:** We report about a 53 y o lady who presented with obstructive jaundice, 8 years following open cholecystectomy. Paraclinical investigations were in favor of cholangiocarcinoma, however the final pathology revealed an amputation neuroma of the CBD.

**DISCUSSION:** Amputation neuromas are rarely seen in the era of laparoscopic cholecystectomy. They are benign reparative lesions of the CBD following surgery or manipulation of the extra hepatic biliary tree. It is very difficult to diagnose them pre-operatively. Surgical resection is the first choice of treatment.

**CONCLUSION:** Traumatic neuromas should always be among the differential diagnosis, when assessing a CBD mass in patients with a previous history of open cholecystectomy or surgery to the gastrointestinal tract.

© 2017 The Author(s). Published by Elsevier Ltd on behalf of IJS Publishing Group Ltd. This is an open access article under the CC BY-NC-ND license (<http://creativecommons.org/licenses/by-nc-nd/4.0/>).

## 1. Introduction

Amputation neuroma or traumatic neuroma is a benign and rare cause of cholangitis [1,2]. It develops usually in patients with a history of surgery to the biliary tract [1–3,5–10]. Dealing with this condition is challenging, since preoperative diagnosis remains a difficult task [5]. Surgery is the best treatment option, with good long-term results [7]. We present here a case of a 53 y-o lady who presented with an obstructive jaundice, 8 years following an open cholecystectomy. Cholangiocarcinoma was suspected, and patient underwent bile duct resection with Roux-en-Y hepaticojejunostomy. It's noteworthy mentioning that this work has been reported in line with the SCARE criteria [11].

## 2. Case report

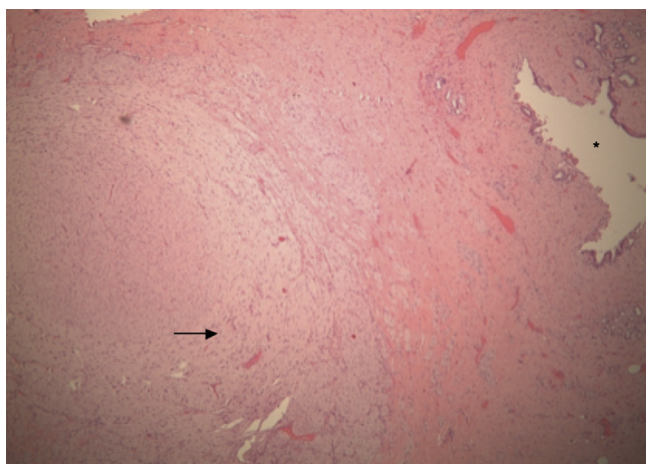
A 53-year-old woman presented with a 10-day history of progressive jaundice associated with right upper quadrant pain and Fever. History of previous illness includes an open cholecystectomy for cholecystitis 8 years ago. Physical examination revealed

icteric sclerae and a right sub-costal scar. Liver function tests were as following: Total bilirubin 41.72 mg/dL; direct bilirubin 23.6 umol/L; SGPT and SGOT were within normal limits. We started by IV hydration with empiric antibiotherapy. Transabdominal ultrasound imaging of the abdomen showed dilation of intra hepatic bile ducts, however the CBD was not visualized due to bowel distention. MR cholangiopancreatography revealed multiple lymph nodes in the porta-hepatis with evidence of an irregular stricture of the CBD, highly suggestive of malignancy (Fig. 1). Injected Ct scan of the abdomen and pelvis revealed dilated intra and extra hepatic bile ducts with aerobilia; Multiple supracentemetric Lymph nodes were seen at the level of the porta-hepatis, causing compression of the CBD. Few infracentimetric celiac lymph nodes were also visualized (Fig. 2a and b). Cholangiocarcinoma was highly suspected preoperatively.

Exploratory laparotomy was discussed with the patient, for which she signed the informed consent, the night before the procedure. At Laparotomy, the lymph nodes were identified as a whitish solid mass, about 1 cm in diameter and situated 3 cm distal to the hepatic ducts bifurcation. Intraoperative frozen section showed inflammatory cells, with no evidence of malignancy. The CBD was resected en bloc with the whitish mass, and a Roux-en-Y hepaticojejunostomy was then performed. The postoperative course was uneventful, and the patient was discharged 7 days after surgery.

\* Corresponding author.

E-mail addresses: [Youssef.ab.sleiman@gmail.com](mailto:Youssef.ab.sleiman@gmail.com) (Y.A. Sleiman), [zizou.l.90@hotmail.com](mailto:zizou.l.90@hotmail.com) (Z.A. Hassoun), [derdyail@hotmail.com](mailto:derdyail@hotmail.com) (H.A. Nasser), [allouchmustafa@gmail.com](mailto:allouchmustafa@gmail.com) (M. Allouch).



**Fig. 1.** Haphazard proliferation of nerve fibers (black arrow). The black asterisk identifies the CBD lumen.

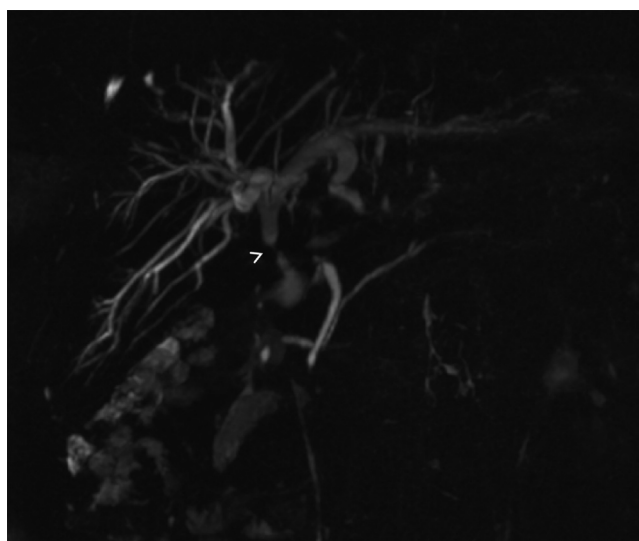Histopathological studies were consistent with an amputation neuroma of the CBD (Fig. 3).

### 3. Discussion

Amputation Neuroma (AN) is a rare condition that usually occurs following trauma, surgical manipulation or infection of the extra-hepatic biliary tree [1–10]. In nearly all reported cases, there was a previous history of cholecystectomy [1–3,5–10]. In one patient, amputation neuroma developed following bile duct resection for a bismuth type 1 cholangiocarcinoma [6].

Amputation Neuromas were described at the level of the cystic duct, CBD and CHD [7]. In one case, AN affected the gallbladder, however, there was a history of severe cholecystitis with a cholecysto-colonic fistula [8]. Theoretically, any type of biliary surgery, could lead to an amputation neuroma. However in the majority of cases, patients have had a history of an Open Cholecystectomy (G). In only 2 papers, Laparoscopic cholecystectomy was mentioned, but it has been converted to open cholecystectomy due to severe cholecystitis [5,8].

It's noteworthy mentioning that bile duct injury (BDI) sustained during laparoscopic cholecystectomy (LC), differ from those sustained during open cholecystectomy (OC) [9]. BDI following open cholecystectomy remain asymptomatic for a long period of time. Once strictures develop, patients present with a picture of obstructive jaundice [9,10]. Similarly, neuromas of the bile ducts became symptomatic, months to years following surgery [6,7]. This could explain the fact why all cases of bile ducts neuromas, were reported in the era of open cholecystectomy [7].

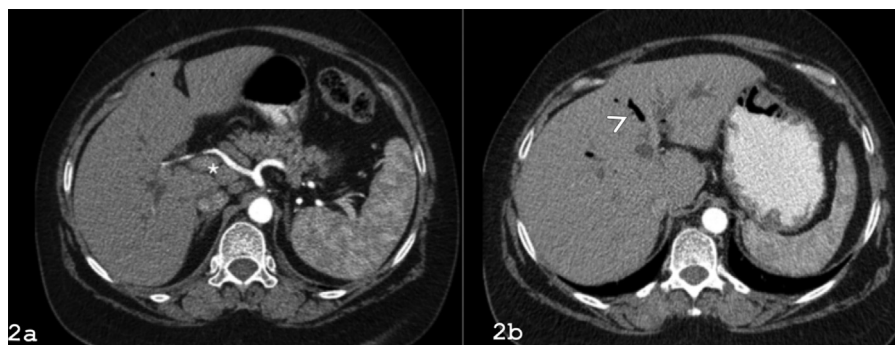


**Fig. 3.** MRCP showing a stricture at the level of the porta-hepatis (arrowhead).

The incidence of AN is unknown since all patients remain asymptomatic. In a cadaveric dissection study, 11 out of 40 patients who have had a history of cholecystectomy, presented histopathological features consistent with amputation neuromas [5].

Amputation Neuroma is a chronic proliferation of nerve fibers, as a reparative response after injury [4,6]. Normally, these are neuro-vegetative fibers that converge around the CBD. Division of Parasympathetic fibers is solely responsible for the generation of dyspeptic symptoms, whereas alteration in sympathetic axonal endings could lead to severe abdominal pain [1,2,4]. Preoperative diagnosis is difficult, even impossible.

Imaging studies could evoke cholangiocarcinomas, peri-ampullary tumors or metastatic Lymph nodes at the level of the hilum [5]. Surgery is the best treatment option with excellent long term outcomes [7]. Intraoperative frozen section could be helpful to ensure the diagnosis [5]. Few similar cases have been reported, in all of whom Roux-en-Y hepaticojejunostomy was adopted. Regarding our patient, frozen section was consistent with inflammatory cells, and fortunately we ended up with a rare benign disease. It has been 6 months since surgery, and the patient is free of symptoms. Such cases are challenging for the physicians, in front of a frustrated suffering patient. Despite optimal surgical management, Roux-en-Y hepaticojejunostomy is a heavy procedure and patients are always subject to delayed complications. That's why surgeons should be aware of eventual post-cholecystectomy syndrome, that could manifest as a benign amputation neuroma, and perhaps with appropriate preoperative diagnosis, a less invasive procedure could be offered for such patients.



**Fig. 2.** (a) CT-scan showing a group of lymph nodes at the level of the proximal CBD (asterisk), (b) white arrowhead showing aerobilia.

**Conflicts of interest**

The authors, Sleiman YA, Hassoun ZA, Nasser HA, Abs L and Allouch M have nothing to disclose.

**Funding**

None.

**Ethical approval**

Nini hospital ethical committee.

**Consent**

No identifying details appearing in the paper. Informed consent written and signed was obtained.

**Author contribution**

Sleiman YA and Nasser HA : paper concept, design, data collection and interpretation.

Sleiman YA, Nasser HA, Hassoun Za and Allouch M : writing the manuscript.

Abs L and Hassoun ZA : reviewing and editing.

**Guarantor**

Nasser H.A. and Sleiman Y.A.

**References**

- [1] R.H. Zeff, R.B. Pfeffer, P.X. Adams, M. Ruoff, Reoperation for amputation neuroma of the cystic duct, *Am. J. Surg.* 131 (1976) 369–370.
- [2] A. De Rosa, D. Gomez, A.M. Zaitoun, I.C. Cameron, Neurofibroma of the bile duct: a rare cause of obstructive jaundice, *Ann. R. Coll. Surg. Engl.* 95 (2013) e38–e40.
- [3] D.M. Larson, K.A. Storsteen, Traumatic neuroma of the bile ducts with intrahepatic extension causing obstructive jaundice, *Hum. Pathol.* 15 (1984) 287–289.
- [4] B. Peison, B. Benisch, Traumatic neuroma of the cystic duct in the absence of previous surgery, *Hum. Pathol.* 16 (1985) 1168–1169.
- [5] M. Apovilla, T. Lazure, I. Lorand, E. Carton, L. Rocher, G. Pelletier, J. Cucherousset, P. Bedossa, Post-cholecystectomy amputation neuroma of the common bile duct with obstructive jaundice, *Gastroenterol. Clin. Biol.* 29 (2005) 79–81.
- [6] Y. Cheng, Q. Jia, X. Xiong, N. Cheng, Traumatic bile duct neuroma after resection of hilar cholangiocarcinoma, *Clin. Res. Hepatol. Gastroenterol.* 38 (2014) 127–128, <http://dx.doi.org/10.1016/j.clinre.2013.12.007>.
- [7] D. Cimaschi, V. De Cesare, G. Pulcini, E. Cervi, M. Belloni, B. Liserre, G.C. Cervi, A case of amputation neuroma of the bile duct following video-laparoscopic cholecystectomy, *G. Chir.* 27 (January–February (1–2)) (2006) 31–36.
- [8] S. Janes, P.H. Renaut, M.K. Gordon, Traumatic (or amputation) neuroma, *ANZ J. Surg.* 74 (August (8)) (2004) 701–702.
- [9] L. Kaman, S. Sanyal, A. Behera, R. Singh, R.N. Katariya, Comparison of major bile duct injuries following laparoscopic cholecystectomy and open cholecystectomy, *ANZ J. Surg.* 76 (September (9)) (2006) 788–791.
- [10] A. Chaudhary, M. Manisegran, A. Chandra, A.K. Agarwal, A.K. Sachdev, How do bile duct injuries sustained during laparoscopic cholecystectomy differ from those during open cholecystectomy? *J. Laparoendosc. Adv. Surg. Tech. A* 11 (August (4)) (2001) 187–191.
- [11] R.A. Agha, A.J. Fowler, A. Saetta, I. Barai, S. Rajmohan, D.P. Orgill, The SCARE Group, The SCARE Statement: consensus-based surgical case report guidelines, *Int. J. Surg.* 34 (2016) 180–186.

**Open Access**

This article is published Open Access at [sciedirect.com](http://sciedirect.com). It is distributed under the [IJSCR Supplemental terms and conditions](#), which permits unrestricted non commercial use, distribution, and reproduction in any medium, provided the original authors and source are credited.