



Bone Trough Lateral Meniscal Allograft Transplantation: The Tapered Teardrop Technique

Michael A. Zacchilli, M.D., Amos Z. Dai, B.S., Eric J. Strauss, M.D., Laith M. Jazrawi, M.D., and Robert J. Meislin, M.D.

Abstract: The meniscus plays a vital role in knee biomechanics, and its physical absence or functional incompetence (e.g., irreparable root or radial tear) leads to unacceptably high rates of joint degeneration in affected populations. Meniscal allograft transplantation has been used successfully to treat patients with postmeniscectomy syndrome, and there is early laboratory and radiographic evidence hinting at a potential prophylactic role in preventing joint degeneration. We present a technique for lateral meniscal allograft transplantation using the CONMED Meniscal Allograft Transplantation system.

The menisci play a critical role in knee stability, load absorption, and load transfer. Long-term studies of adolescents after total meniscectomy clearly show their importance, with a resultant 4-fold increased risk of osteoarthritis and a 132-fold increased rate of total knee arthroplasty compared with control knees at 40 years.¹ Even partial meniscectomies can devastate normal biomechanics and lead to premature degenerative changes.² Ten-year follow-up studies have shown progression of unilateral degeneration in 39% of patients after partial lateral meniscectomies and 22.3% after partial medial meniscectomy.³ In addition to this radiographic decline, patients with lateral compartment meniscal deficiency show higher rates of functional decline.^{1,4} The management of meniscal deficiency in young and active patients, particularly in the lateral compartment, is therefore of particular importance for surgeons focused on joint preservation (Table 1).

Traditionally, the treatment of postmeniscectomy syndrome was focused on symptomatic control (acetaminophen, nonsteroidal anti-inflammatory drugs, etc.) or definitive management after degeneration (arthroplasty) as anatomy failed. In addition, unloading osteotomies have been applied successfully to alternative anatomy and biomechanics, shifting load away from the injured compartment. Meniscal allograft transplantation (MAT), alone or in concert with other procedures, has emerged over 2 decades as a surgical option to restore more normal anatomy and treat symptomatic patients with meniscal deficiency and mild-to-moderate degeneration.⁵ Laboratory and clinical evidence hinting at the chondroprotective properties of MAT, with improved outcomes and decreased cartilage degradation in early compared with delayed transplantation, exists supporting the chondroprotective role of MAT.⁵⁻⁷ These findings suggest the potential prophylactic utility of this surgery in the future if optimized.

Despite the enthusiasm for its potential, MAT remains a challenging and complex surgery with a significant risk for failure (10.6% at 4.8 years) and associated morbidity (13.9% complication rate at 4.7 years).⁵ Numerous factors including graft sizing, graft positioning, surgical technique, and patient variables play a significant role in determining the efficacy of this surgery and have clearly affected the earlier case series. Available instrumentation is variable and rapidly evolving. It is therefore vital that surgeons seeking expertise in this area must become familiar with the relative strengths and pitfalls of each technique. This Technical Note presents our technique and recommendations for the bone bridge lateral MAT using the CONMED Meniscal Allograft Transplantation instrumentation system (M2015528; CONMED, Utica, NY) (Video 1).

From the Department of Orthopaedic Surgery, Division of Sports Medicine, NYU Hospital for Joint Diseases, New York, New York, U.S.A.

The authors report the following potential conflicts of interest or sources of funding: R.M. receives consultancy fees from CONMED. Full ICMJE author disclosure forms are available for this article online, as [supplementary material](#).

Received April 1, 2017; accepted August 14, 2017.

Address correspondence to Amos Z. Dai, B.S., NYU Hospital for Joint Diseases, 301 E 17th Street, Suite 1500, New York, NY 10003, U.S.A. E-mail: amos.z.dai@gmail.com

© 2017 by the Arthroscopy Association of North America. Published by Elsevier. This is an open access article under the CC BY-NC-ND license (<http://creativecommons.org/licenses/by-nc-nd/4.0/>).

2212-6287/17499

<https://doi.org/10.1016/j.eats.2017.08.041>

Table 1. Patient Selection for Bone Bridge Lateral Meniscal Allograft Transplantation

Indications	
•	Total, subtotal, or equivalent meniscectomy (e.g., high grade segmental loss, radial tear, irreparable root)
•	Lateral joint line pain, particularly when activity related and with associated effusion
•	Failed trial of conservative therapy
Contraindications	
•	Outerbridge grade IV chondromalacia of lateral compartment (unless focal and corrected)
•	End-stage degenerative changes in patellofemoral or medial compartments
•	Valgus malalignment (unless previously or simultaneously corrected)
•	Ligamentous instability (unless corrected)
•	Patient unwilling to comply with postoperative rehabilitation or restrictions
•	Open physes
•	Inflammatory arthritis (relative)
•	Obesity (relative)

Surgical Technique

Graft Sizing^{8,9}

Graft sizing is a crucial preoperative step for any transplantation and should be considered part of the surgical technique for MAT. Undersized grafts reproduce normal forces at the articular surface but higher forces across the meniscus with a tendency toward failure. Oversized grafts, too broad to engage the condyle, allow for increased force across articular cartilage. Based on cadaveric biomechanical studies, lateral meniscus allografts must fall within $\pm 10\%$ of the original meniscus size to reproduce contact forces

within the range of intact knees. Magnetic resonance imaging sizing and the Yoon radiographic method show similar inherent error of $|6.4\% \text{ to } 8.8\%|$ for the lateral meniscus, whereas the Pollard radiograph method tends to overestimate both width and length. As such, only grafts within 1 mm ($\sim 2.7\% \text{ to } 3.7\%$) of the magnetic resonance imaging- or Yoon-calculated ideal graft size will reliably fall within the $\pm 10\%$ range recommended. Oversized grafts are preferred to undersized grafts within or, if necessary, above this ideal ± 1 mm range due to differences in failure risk.

Positioning

The patient is positioned supine on the operating table with the legs dropped. A ring-type leg holder (Acufex) is placed flush to the distal aspect of the bed. The patient is moved distally and the operative thigh is secured with the ring-type leg holder 4 fingerbreadths above the proximal patellar pole. The contralateral leg is carefully padded and positioned in an abducted position per surgeon preference, ensuring sufficient space to achieve a figure-4 position with adequate varus stress (Table 2).

Knee Preparation

Diagnostic arthroscopy of the knee is performed (Fig 1). The lateral portal is placed approximately 1.5 to 2 cm lateral to the edge of the patellar tendon to improve access and visualization of the lateral meniscus roots and to distance the portal from the more central arthrotomy. The lateral compartment is assessed in a figure-4 position with the ankle supported by an assistant or on a padded Mayo stand. The lateral compartment chondral surfaces are carefully evaluated

Table 2. Surgical Dos and Don'ts

	Do	Don't
Positioning	Abduct the nonoperative leg to allow for an adequate figure-4 position Use a ring thigh holder on the operative leg to assist with varus stress Use a padded Mayo to support the operative leg in figure-4/varus if only 1 assistant	Short yourself: space between the knee flexion crease and leg holder/bed is vital for suture passage, instrumentation, and visualization posterolaterally Attempt graft passage or fixation without varus stress
Graft preparation	Isolate both meniscal roots and confirm Cut No. 1 and No. 3 positions before sawing	Oversize: if Cut No. 2 is made >10 mm below the roots, the trapezoidal angles make the block too wide
Knee arthroscopy	Maintain a rim: 1-2 mm of native meniscus will improve fixation with suturing Perform 2-3 mm notchplasty in a figure-4 position to facilitate passage	Maintain meniscal roots: they will prevent proper guide placement, particularly posteriorly Compromise the femoral anterior cruciate ligament footprint with notchplasty
Trough preparation	Use 18 G needle localization to plan axial alignment from anterior to posterior roots Use a patella tendon split to match patient anatomy and decrease extrusion ¹⁰	Leave a prominent spine between the roots: it will deflect the guide and cause a shallow or sloped trough Use parapatellar arthrotomy: axial obliquity and laterally offset bone bridges correlate with graft extrusion ¹¹
Graft implantation	Maintain moderate traction on passage sutures while sliding bridge into trough Fully seat the bone bridge to the back wall	Attempt to independently pass the bone bridge and meniscus Use clamps or graspers on the meniscus because this may compromise the meniscal roots
Graft fixation	Set position and tension by placing the first inside-out stitch just anterior to popliteus	Begin fixation at the posterior root or anterior horn

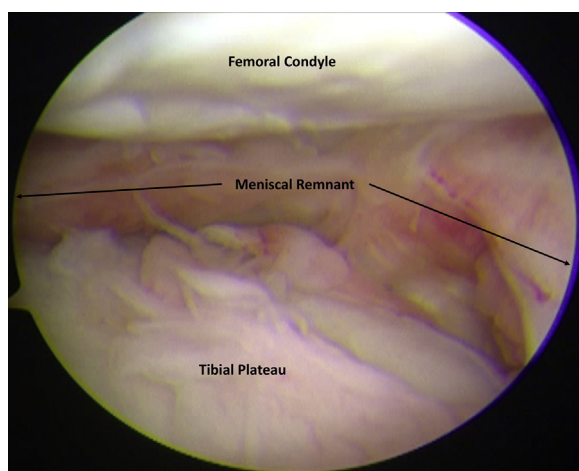


Fig 1. The lateral compartment of the left leg is assessed in a figure-4 position with the ankle supported by an assistant or on a padded Mayo stand. The lateral compartment chondral surfaces are carefully evaluated and meniscal deficiency is confirmed. View is from the inferomedial arthroscopic portal.

and meniscal deficiency is confirmed. Chondral health is assessed and focal lesions may be treated in a standard fashion. If microfracture or matrix-based augmentation procedures are performed, they are delayed until transplantation is complete. Diffuse grade IV disease is an absolute contraindication and grade III a relative contraindication to transplantation. Residual meniscus is debrided, retaining a 1- to 2-mm rim for fixation (Fig 2). Residual posterior root fibers are debrided to facilitate posterior passage of the hooked trough guide. Limited lateral notchplasty is performed, taking care to avoid the anterior cruciate ligament (ACL). The ability to directly visualize the anterior horn is also confirmed. At this time, a standard posterolateral approach to the knee is performed and the graft is prepared. The presence of 2 surgeons facilitates efficiency at this stage.

Graft Preparation

The graft is opened after confirming dimensions and patient match. The roots are examined and excess soft tissues removed to clearly expose the true meniscal insertion. The graft is clamped to the preparation tray with the anterior and posterior roots aligned to the labeled laser line axis. Ideally, the plane of the allograft plateau should grossly match the plane of the preparation tray and table. If significant obliquity in the coronal or sagittal dimensions is identified, examine the allograft's axial cut and remove any prominent spurs/ridges or cortical edges. Cut No. 1 and Cut No. 3 sagittal cutting guides are sequentially placed on the preparation table, and the saw position is visually inspected to ensure preservation of the meniscal roots before any cuts are performed (Fig 3 A and B).

The Cut No. 1 cutting fence (medial sagittal cut) is reattached to the preparation tray. The saw is placed through cutting fence No. 1 ensuring protection of the roots, and the cut is performed using a 25 mm × 90 mm × 1 mm saw blade (CONMED). The Cut No. 2 cutting fence is aligned for the axial plane cut, with the superior edge of the guide aligned at or slightly higher than the subchondral bone at the meniscal root insertions, ensuring a bone bridge no deeper than 10 mm (Fig 3C). Once the desired slope is obtained, the cutting fence nuts are tightened and the axial cut is performed to a depth of 15 to 20 mm (short of the clamp footing). Maintaining cutting fence No. 2 on the preparation rods for added stability, the meniscus is retracted perpendicular to the graft plateau, and the Cut No. 3 cutting fence is attached. Safety of the roots is ensured and the cut is performed. Note that the sagittal cuts (No. 1 and No. 3) each flare outward at 5°, creating a 10° trapezoidal shape in cross section with a wider base (Fig 3 A, B, and D). Accordingly, it is critical that the axial cut (No. 2) is not performed too deep, as the resulting bone block will not only be too tall but also too wide for the recipient trough. Keeping in mind this trapezoidal shape, the bone bridge is manually slid into the “Set Rounding Depth” slot and the shaver handle is firmly attached. The keeled handle is fit into the slot on Shaver No. 1, and the bone bridge is rasped back and forth until a smooth motion is achieved (Fig 4). Rasping in a single direction during the first several repetitions can help to overcome initial resistance. Repeating this process in Shaver No. 2 will round out the bottom of the bone block, creating a “tapered teardrop” bone block (Fig 3D). The block is removed from the shaver handle and slid into the calibrated trial slot in the preparation tray. A smooth fit confirms that appropriate shape has been achieved and allows for bone block length measurement.

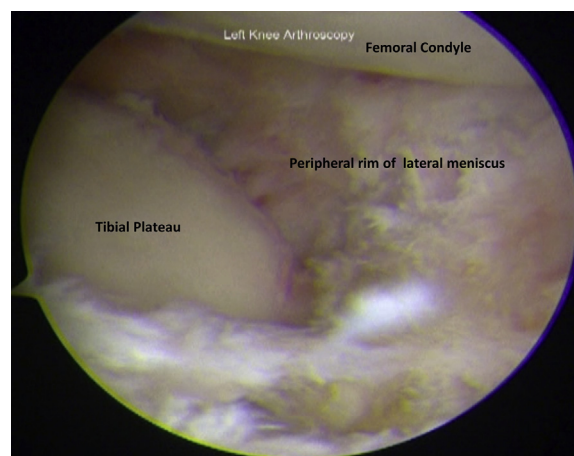


Fig 2. Residual meniscus is debrided, retaining a 1- to 2-mm rim for fixation. Residual posterior root fibers are debrided to facilitate posterior passage of the hooked trough guide. View is from the inferomedial arthroscopic portal.

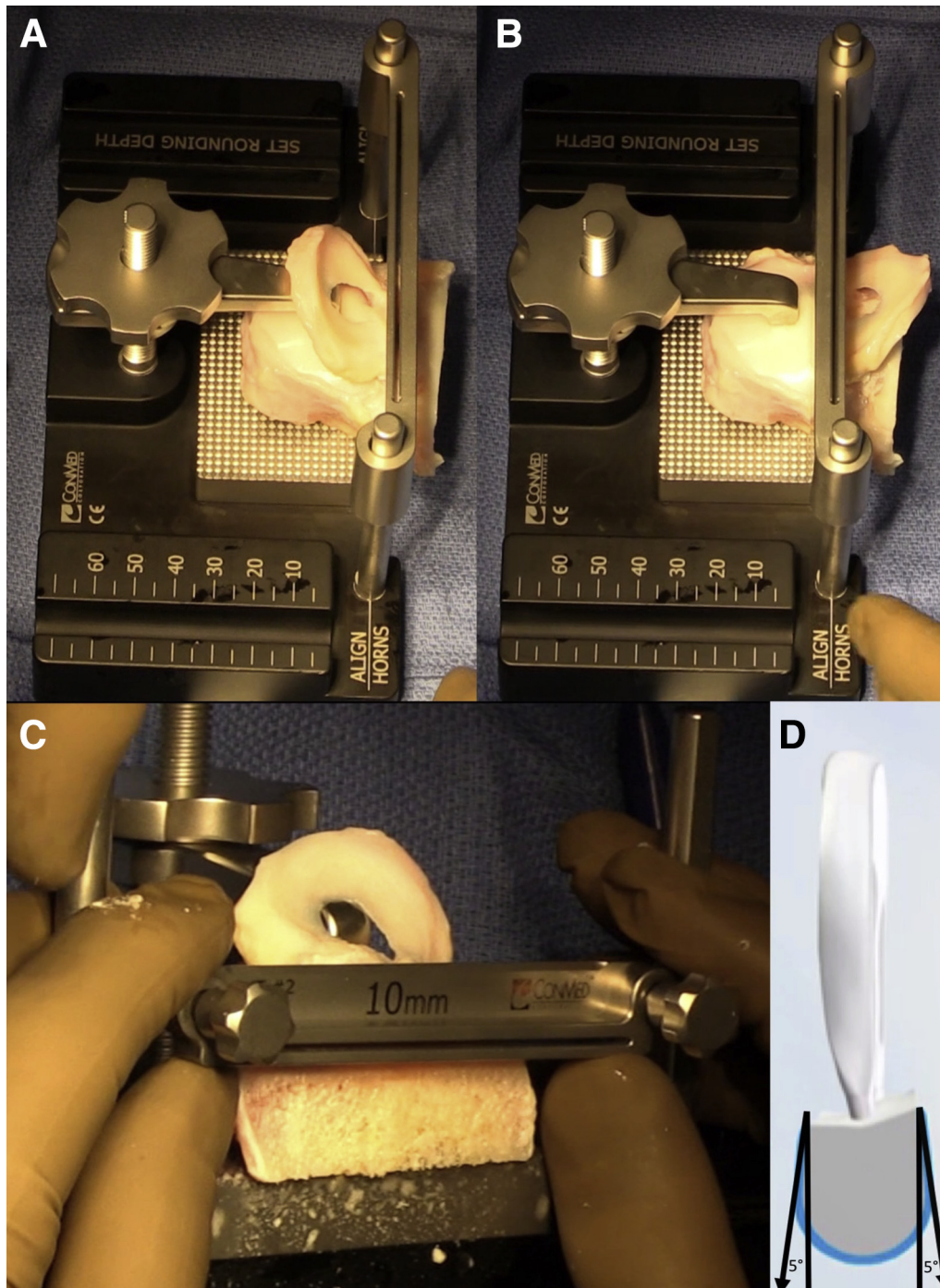


Fig 3. The lateral meniscal allograft transplantation system (CONMED) provides a controlled process for creating a tapered teardrop bone bridge. (A) The allograft is aligned with the anterior and posterior roots along the laser line. (A and B) Provisional placement of Cut No. 1 and Cut No. 2 cutting guides allows the surgeon to confirm preservation of the native allograft meniscal roots before performing either of these sagittal cuts. (D) Once performed these cuts each angle 5° outward distally, creating an overall 10° flair to the proximal aspect of the tapered teardrop to help establish an interference fit. (C) The Cut No. 3 guide is carefully aligned level with the subchondral plate at both the anterior and posterior meniscal root, creating a 10-mm-deep bone block. It is vital that this cut is not performed deeper than 10 mm to avoid graft mismatch with a wide base. (D) Sequential rasping on 2 jigs will round the base of the trapezoidal block, creating a tapered teardrop.




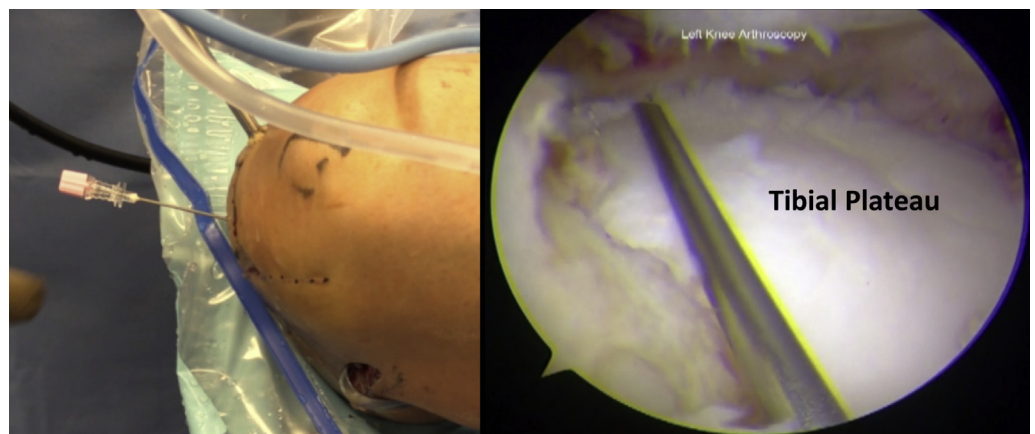
Fig 4. The bone bridge is manually slid into the “Set Rounding Depth” slot and the shaver handle is firmly attached. The keeled handle is fit into the slot on Shaver No. 1, and the bone bridge is rasped back and forth until a smooth motion is achieved. Rasping in a single direction during the first several repetitions can help to overcome initial resistance. The rasping process is repeated with Shaver No. 2.

Trough Preparation

The ideal arthrotomy position and plane is localized with an 18 G spinal needle: (1) at the level of the joint line, (2) aligned with the anterior and posterior roots, and (3) parallel to the tibial slope (Fig 5). Fulfilling these criteria generally requires a transpatellar tendon position. The skin is incised longitudinally beginning 1 to 2 cm proximal to the joint line and extending 4 cm distally. The tendon is split in line with its fibers to the level of the tibial tubercle, exposing the anterior shoulder of the tibial plateau. A 4.5-mm shaver (Dyonics Bonecutter Platinum, Smith & Nephew, Andover, MA) is inserted through the arthrotomy, aligned with the roots, and a provisional chondral trough is created to the level of subchondral bone at the roots (Fig 6). Special care is taken to resect the lateral tibial spine along this line until an even, shallow, linear

trough connects the meniscal root insertion sites. Failure to do so can impact trough size and slope, and may adversely affect the graft position. The hooked trough guide is inserted through the arthrotomy. The hook is rotated parallel to the lateral plateau, passed under the posterior horn/root, and then derotated in line with the arthrotomy. The transverse portion of the guide is placed parallel to the tibial slope within the chondral trough, equalizing anterior and posterior contact. The guide should contact the subchondral plate at both the anatomic anterior and posterior root positions (Fig 7A). Performed correctly, this will direct the guide pin parallel to the meniscal roots, matching their slope, at a depth of 10.31 mm from the subchondral bone at the insertions (Fig 7A). If excessive slope is placed on the guide hook, it will result in creation of a shallow and anteriorly foreshortened trough. If insufficient slope is placed on the hook guide, the resulting posterior apex of the trough will be both shallow and anterior. This position is maintained under direct visualization during guide fixation. Light traction on the guide will provisionally set the pin. Retraction of the tendon split exposes the anterior plateau. Under direct visualization, the handle/clamp device is advanced on its worm gear until the teeth engage the anterior tibial cortex (Fig 7A). Direct visualization confirms guide position, and any necessary adjustments are made at this time. Once satisfied the locking collar is tightened clockwise. The drill bit is advanced through the guide handle locking collar until the autocalibrated rubber stop engages the end of the hook guide, ensuring a 5-mm back wall (Fig 7A). Digital palpation through the posterolateral incision provides additional confidence in pin depth. The drill is removed and the calibrated blunt guide pin is inserted until the visible laser line is flush with the end of the hook guide. The locking collar is removed and the 10-mm cannulated reamer is advanced until the positive stop is engaged, again maintaining a 5-mm back wall for the trough. The reamer and pin are

Fig 5. The ideal arthrotomy position and plane is localized with an 18 G spinal needle at the level of the joint line, aligned with the anterior and posterior roots and parallel to the tibial slope.



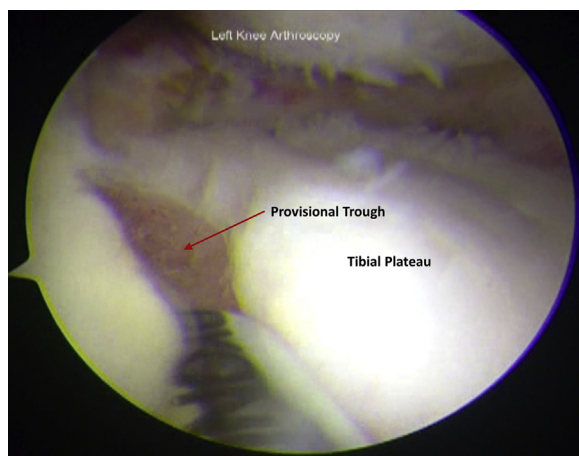


Fig 6. The tendon is split in line with its fibers to the level of the tibial tubercle, exposing the anterior shoulder of the tibial plateau. A 4.5-mm shaver is inserted through the arthrotomy, aligned with the roots, and a provisional chondral trough is created to the level of subchondral bone at the roots. Special care is taken to resect the lateral tibial spine along this line until an even, shallow, linear trough connects the meniscal root insertion sites. View is from the inferomedial arthroscopic portal.

removed. The 10-mm calibrated guide rod is inserted with the flat surface parallel to the joint surface (Fig 8). The hook guide and handle are disengaged and removed. Provisional trough length is obtained with arthroscopic visualization of the guide rod at the anterior plateau. Taking care to maintain the flat surface of the guide rod parallel to the joint, the H-osteotome is seated onto the rod and gently impacted until the positive stop is engaged (Fig 9). Direct arthroscopic visualization allows for confirmation of osteotome alignment and depth, as well as continual monitoring of the ACL and lateral condyle cartilage to avoid iatrogenic injury. After the positive stop is reached, both osteotome and guide rod are removed. A combination of the pituitary rongeur, 4.5-mm full radius shaver, and if necessary, judicious use of a burr (Dyonics ELITE 5.5-mm Acromionizer, Smith & Nephew) are used to debride any residual roof on the trough posteriorly without compromising the back wall. The calibrated trough rasp is inserted under direct visualization and used for final trough preparation (Fig 10). Calibrations confirm final trough length and the graft is measured and truncated accordingly, preferentially removing any excess posterior bone first (Fig 11). The entrance to the trough is evaluated, and obstructing soft tissues are debrided to ensure clear entry.

Graft Passage

Zone-specific meniscal repair cannulas (Linvatec) are placed through the arthrotomy incision and used to pass a single 2-0 FiberWire Meniscus Repair Needle (Arthrex, Naples, FL) just anterior to the popliteus hiatus and is retrieved through the posterolateral incision

in a standard fashion. Neurovascular structures are protected with the use of a spoon retractor. The graft is carefully transported to the field. The second needle is removed, and the suture is used to shuttle the previously placed graft passage sutures before graft insertion. A strong varus stress is applied to the knee. Moderate tension is maintained on the graft passage sutures as the bone bridge is inserted into the trough under direct visualization (Fig 12). Firm digital pressure is usually sufficient for passage of the bone bridge. Occasionally, the posterior horn or body of the meniscal graft will capture between the condyle and plateau and fail to completely reduce posterolaterally. In such cases, reduction is assisted by gentle direct pressure in a sweeping motion with a blunt arthroscopic cannula trochar or switching stick.

Graft Fixation

Sufficient bony interference fit is usually achieved with the 10° “tapered teardrop” bone bridge design and can be confirmed with probing. If desired, a small (≤ 6 mm) PEEK (polyether ether ketone) interference screw may be added. Final graft fixation is achieved with an inside-out technique along the superior and inferior graft surfaces, beginning around the edges of the popliteus tendon (Fig 13). Inside-out sutures are retrieved from the posteromedial incision and are clamped along the arthroscopy drape to avoid incarceration of any during final tying. The inside-out technique can be extended all the way to the anterior horn, with stitches retrieved through the arthrotomy skin flaps. Alternately, a traditional outside-in technique using the Meniscus Mender II (Smith & Nephew) may be used. Final arthroscopic evaluation of the meniscal allograft is performed, ensuring adequate fixation (Fig 14).

Postoperative Rehabilitation

Postoperative rehabilitation progresses in 4 phases. Phase I (0-8 weeks) is designed to provide foundational rehabilitation while protecting the transplant. Phase II (8-12 weeks) focuses on regaining neuromuscular control with avoidance of highest risk activities (weightbearing deep knee flexion, impact activities). Phase III (12-16 weeks) provides gradual onset of full range of motion (ROM) resistance training and early sports-specific movements. Phase IV (4-6 months) is a graduated return to sport program with incorporation of sport-specific preventative rehabilitation and maintenance programs.

Phase I (0-8 weeks): no weightbearing with flexion $>90^\circ$ for 8 weeks:

Weightbearing:

Weeks 1-4: crutches, partial foot flat weightbearing (25%), brace locked in extension, no pivoting.

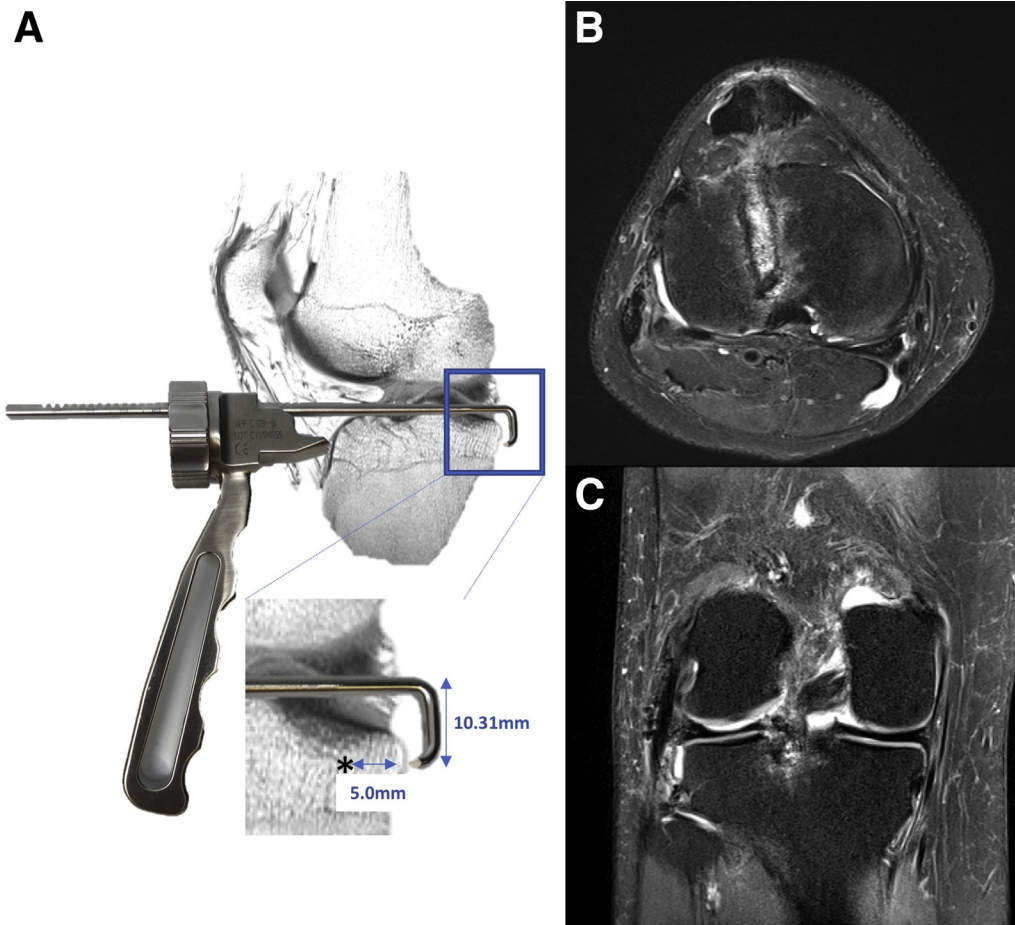


Fig 7. The tibial drill guide (A) comprises a tibial hook and a toothed handle with a worm gear. The guide is placed through a patellar tendon split (B) allowing alignment of the trough directly over the anterior and posterior meniscal roots at an angle parallel to the plateau slope. (A) Portions of the spine, seen here as they overlap the guide, must be removed along this axis to allow appropriate positioning. The worm gear secures guide teeth to the anterior plateau and creates a stable platform for trough preparation. Using this guide, the tip of the tibial drill, guide pin, and reamer will allow for maintenance of a 5-mm back wall with a depth 10.31 mm below the subchondral plate. Axial and coronal magnetic resonance imaging images (B and C) performed 2 weeks postoperatively show the anatomic position of the anterior and posterior roots of an allograft implanted with this technique. Note the absence of any significant extrusion on the coronal view (C).

Weeks 4-8: progress to weightbearing as tolerated, discontinue crutches when gait is normal.

Knee brace (drop lock):

Week 1: locked in full extension for ambulation and sleeping—remove for hygiene.

Weeks 2-4: locked in full extension for ambulation—remove for hygiene and sleeping.

Weeks 4-8: set to range from 0° to 90° for ambulation—remove for hygiene and sleeping.

ROM: passive ROM, active assist ROM, active ROM as tolerated within parameters.

Weeks 1-4: nonweightbearing 0° to 90°, locked in extension for weightbearing.

Weeks 4-6: nonweightbearing and weightbearing 0° to 90°.

Exercises (in brace for first 6 weeks):

Weeks 0-2: quadriceps sets, heel slides, straight leg raises, patellar mobilizations, cocontractions.

Weeks 2-6: add heel raises and terminal knee extensions.

Weeks 6-8: add wall sits at flexion angles <90°.

Activities in brace for first 6 weeks—then without brace.

Phase II (8-12 weeks):

Weightbearing: as tolerated.

Knee brace: discontinue when patient achieves full knee extension without lag.

ROM: full active ROM.

Exercises: progress to closed chain extension exercises, hamstring strengthening, lunges 0 to 90, negative

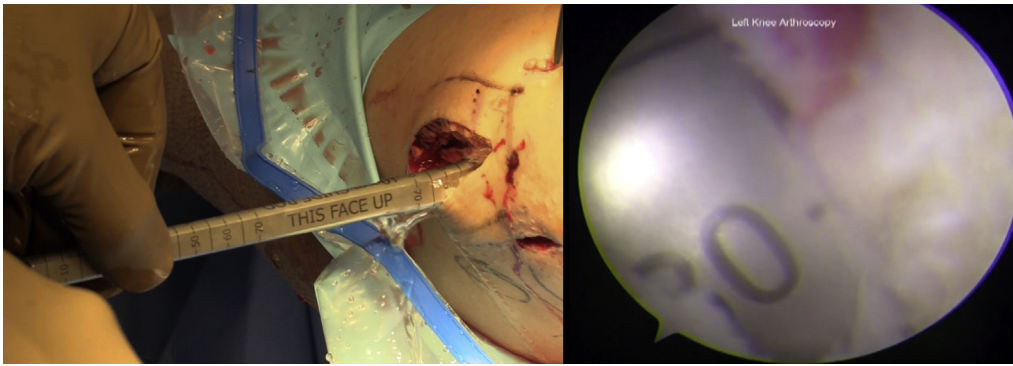


Fig 8. The 10-mm calibrated guide rod is inserted with the flat surface parallel to the joint surface. Provisional trough length is obtained with arthroscopic visualization of the guide rod at the anterior plateau.

set leg press (0 to 90, no extension), proprioceptive exercises, stationary bike.

Phase III (12-16 weeks):

Weightbearing: full weightbearing with normal gait.

ROM: full/painless ROM.

Exercises: continue quadriceps and hamstring strengthening, progress to full motion and isolated single leg press, begin straight line jogging/running, initiate sports-specific drills (add pivoting and jumping last).

Phase IV (4-6 months):

Gradual return to athletic activity as tolerated, continue strength and endurance maintenance program and sport-specific prehabilitation.

Discussion

Patients with meniscal deficiency often suffer from postmeniscectomy syndrome, with pain and recurrent effusions. The progressive joint degeneration that inevitably occurs often exacerbates these symptoms.

MAT is a surgical option for meniscal-deficient patients that can decrease pain and improve joint biomechanics, with some early evidence supporting potential chondroprotective effects. In a 2008 cadaveric study, McDermott et al.¹² showed that MAT can recreate more normal tibiofemoral contact pressures using a bone bridge technique compared with independent root fixation. The tapered teardrop technique described here employs a bone block with inherently stable geometry and an interference fit, obviating the need for bone block fixation, preserving complex allograft meniscus root insertions, and maintaining graft geometry. By restoring normal anatomy and biomechanics, surgeons can theoretically optimize the potential chondroprotective benefits of this procedure.

The tapered teardrop technique has specific advantages and disadvantages compared with other MAT techniques (Table 3). All bone bridge techniques have significant advantages over independent root fixation (soft tissue only or bone plug techniques). The large bone bridge optimizes healing and leaves complex meniscal root architecture intact. The graft preserves

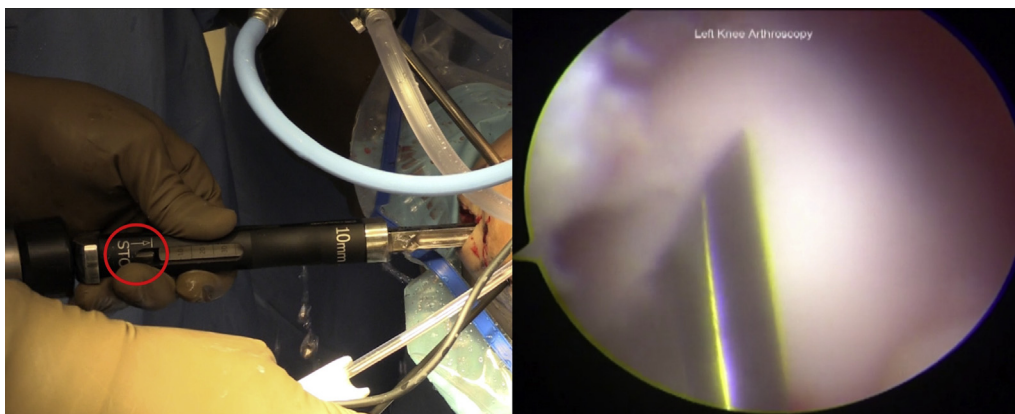
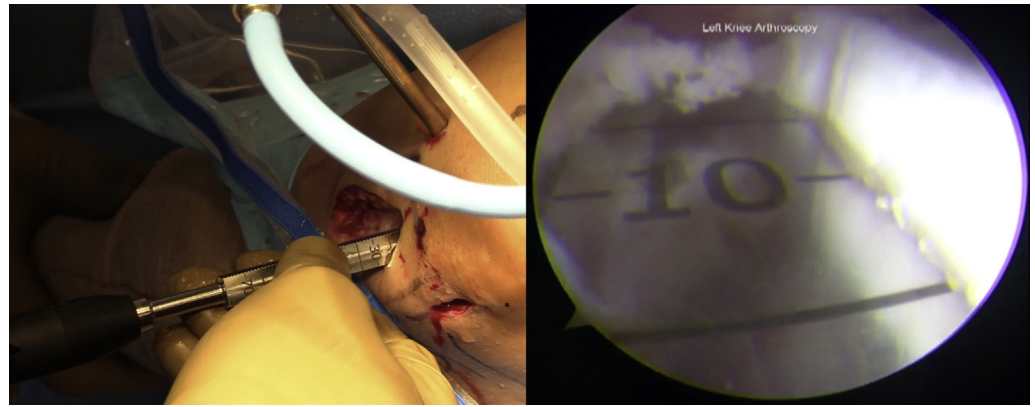


Fig 9. Taking care to maintain the flat surface of the guide rod parallel to the joint, the H-osteotome is seated onto the rod and gently impacted until the positive stop is engaged (red circle). Direct arthroscopic visualization allows for confirmation of osteotome alignment and depth as well as continual monitoring of the anterior cruciate ligament and lateral condyle cartilage to avoid iatrogenic injury. This step is performed with the knee in a figure-4 position and maximal varus stress applied.

Fig 10. The calibrated trough rasp is inserted under direct visualization and used for final trough preparation. Calibrations confirm final trough length and the graft is measured.



the length-tension relation of the meniscus, and as a result maintains the meniscal hoop stress phenomenon. Finally, the bone bridge morphology and interference fit provide inherent construct stability. These advantages do, however, come at a cost to flexibility. Similar to other bone bridge techniques, the tapered teardrop does not tolerate significant graft mismatch or graft preparation errors, and is less malleable to intra-operative adjustments than independent root fixation. Patient anatomy, specifically the relative position of the anterior root and the tibial ACL footprint, can pose technical challenges. Finally, the use of a large tibial trough can increase difficulty or risk when performing MAT in conjunction with other procedures. Relative to the square bone bridge or round keyhole techniques, the tapered teardrop geometry is inherently more stable. To achieve this stability, a more complicated graft preparation is required. The highly engineered graft preparation instrumentation in this technique reliably shapes the bone bridge despite this increased complexity. These same considerations apply to tibial trough preparation. The worm gear tibial guide hook

and sleeve, along with the positive stop reaming system, allows for enhanced control of axial alignment, trough depth/slope, and posterior wall preservation. We believe that this is an improvement over less constrained systems, particularly for surgeons with a limited number of assistants, but requires a higher level of familiarity from the surgeon.

Regardless of the meniscal transplant technique, an ideal transplantation attempts to restore normal anatomy and biomechanics. Graft extrusion is generally considered a surrogate radiographic measure of anatomic reconstruction, although its clinical significance has been questioned.¹³ Unsurprisingly, accurate bone bridge positioning (axial, medial-lateral, and proximal-distal) plays a critical role in limiting extrusion. In 2 separate studies of the parapatellar keyhole lateral MAT, a laterally positioned bone block was found to correlate with larger degrees of graft extrusion.^{14,15} Additional studies have shown that the axial trough angle also correlates with absolute and relative percentage extrusion of the graft.^{10,11,16} Amongst these studies, the lowest reported median extrusion

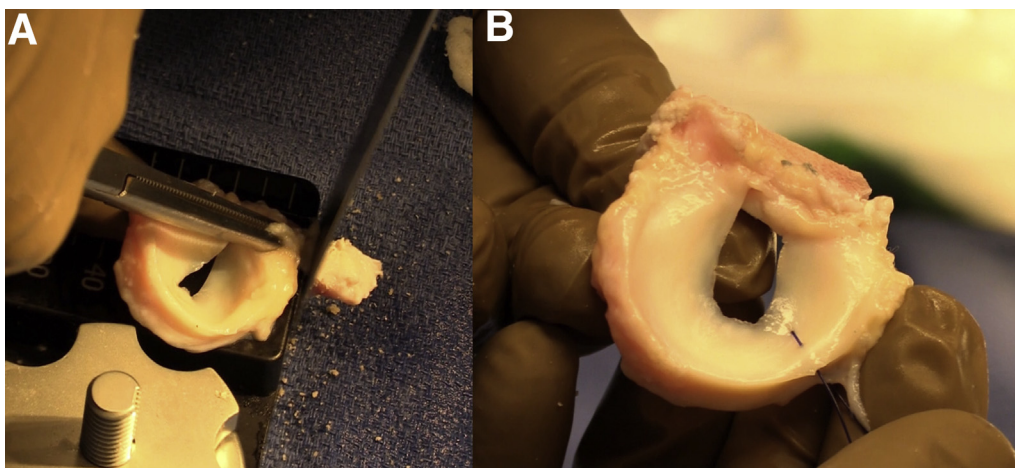


Fig 11. (A) Based on the measurements obtained from the trough rasp, the graft is truncated accordingly, preferentially removing any excess posterior bone first. (B) A passing stitch is placed at the posterior horn/body junction.

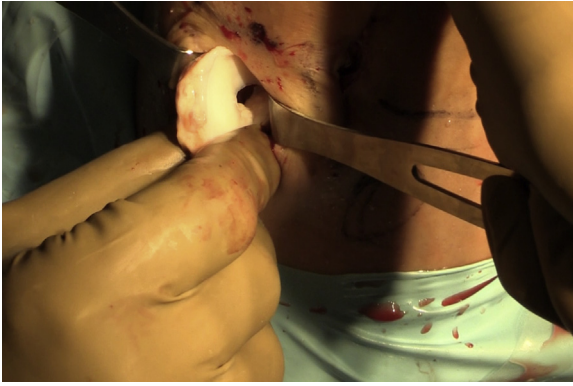

Fig 12. Zone-specific meniscal repair cannulas are placed through the arthrotomy incision and used to pass a single Meniscus Repair Needle just anterior to the popliteus hiatus and is retrieved through the posterolateral incision in a standard fashion. Neurovascular structures are protected with the use of a spoon retractor. The graft is carefully transported to the field. The second needle is removed, and the suture is used to shuttle the previously placed graft passage sutures before graft insertion. A strong varus stress is applied to the knee. Moderate tension is maintained on the graft passage sutures as the bone bridge is inserted into the trough under direct visualization. Firm digital pressure is usually sufficient for passage of the bone bridge.

(1.6 mm) was obtained in the only series using a transpatellar tendon approach, similar to our presented technique.¹⁰ Use of the described tibial guide instrumentation through a patellar tendon split helps to control the trough position variables while simultaneously protecting the extensor mechanism during guide pin placement and reaming (Table 3).

Dozens of papers have described the clinical outcomes of meniscal transplantation since its first report in the 1970s, with generally encouraging results. Notably, most outcomes studies are small Level IV case series,

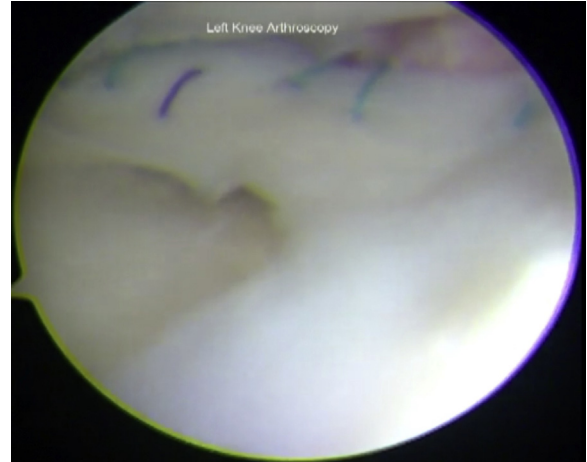


Fig 14. Final view of the lateral meniscal allograft transplantation.

often with significant variation in graft type, surgical technique, and fixation even within a single study population. ElAttar et al.¹⁷ performed a systematic review summarizing the results of 1,136 transplants including 458 lateral menisci with primarily short- to medium-term outcomes (mean 4.6 years) and 89% satisfaction rates. Comparing preoperative with the latest follow-up, they described an average Lysholm score increase from 44 to 77, overall Tegner activity score increase from 3 to 5, and overall visual analog scale decrease from 4.8 to 1.7 with a tendency to slowly decrease over time. They did not perform the analysis of lateral meniscal transplant alone. A more recent and expansive meta-analysis showed similar overall findings. The authors also described an inverse linear relation between survivorship and postoperative follow-up with survival rates just over 60% at 15 years postoperatively.¹⁸

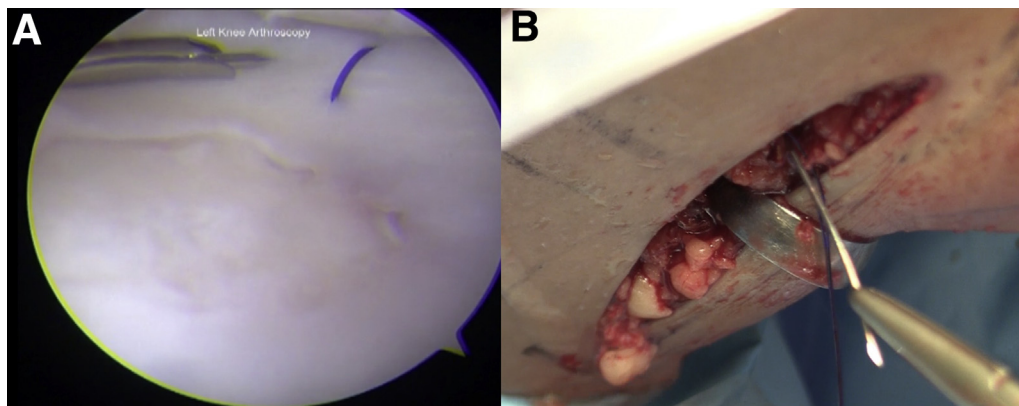


Fig 13. (A) Final graft fixation is achieved with an inside-out technique along the superior and inferior graft surfaces, beginning around the edges of the popliteus tendon. (B) Inside-out sutures are retrieved from the posterolateral incision and are clamped in order along the arthroscopy drape to avoid incarceration of any during final tying. Alternatively, a traditional outside-in technique may be used.

Table 3. Advantages and Disadvantages of the Tapered Teardrop Technique

Phase	Advantages		Disadvantages
	Vs Non-Bone Bridge	Vs Other Bone Bridge	
Graft	Maintained root relation, meniscal geometry Large surface bony healing	Tolerates more variable root anatomy (vs key hole) Interference fit (vs square bridge)	Less forgiving to graft mismatch as graft size/geometry is fixed Does not tolerate significant errors in graft preparation
Trough	N/A	Controlled bone bridge prep Patellar tendon protected by guide during reaming Controlled trough depth Positive stop guide and reamers protect the posterior wall	More steps for bone bridge prep Violates articular surface (vs plugs) Rarely, patellar tendon insertion may interfere with trough (e.g., proximal or Osgood-Schlatter)
Implantation	Secure bony interference fit Roots secured before peripheral stitches placed	Screw/suture fixation of bridge not required (vs square bridge)	Less forgiving than bone plug or soft tissue techniques Graft or trough preparation errors affect interference fit

Clinical outcome studies specifically addressing the “tapered teardrop” bone bridge are not yet available. The outcomes of other lateral bone bridge MAT have been reported in an isolated fashion but are generally limited to small series. In 2006, Sekiya et al.¹⁹ reported the results of lateral keyhole MAT in 25 patients (17 with a bone bridge technique) at 3.3-year mean follow-up. They reported a 93% satisfaction rate, 5 normal and 15 near normal by International Knee Documentation Committee classification, with improvements in Lysholm, Knee Outcome Survey, and Short Form-36 scores. Preoperative joint space narrowing was found to correlate significantly with inferior postoperative outcomes. Notably, only 43% of patients were able to participate in moderate or strenuous activity without pain. In 2010, LaPrade et al.²⁰ reported 2.5-year mean follow-up for 15 patients after a trapezoidal bone bridge lateral MAT, showing significant improvements in the Cincinnati score (57.8 to 77.9, $P < .001$) and subjective International Knee Documentation Committee (57.6 to 76.6, $P < .001$). The authors reported no differences between patients undergoing isolated MAT versus combined procedures.

Conclusions

Patients with meniscal deficiency are at risk for progressive joint degeneration and are frequently symptomatic. MAT is a surgical option for these patients that can decrease pain and improve function, regardless of technique. Meniscal transplant will not universally stop or slow joint degeneration, particularly when it is present at the time of transplantation. However, early radiographic and advanced imaging studies provide some evidence suggesting that transplant can decrease joint space narrowing and improve cartilage signal. Cadaveric studies have shown that bone bridge MATs more closely reconstitute native biomechanics in

cadaver models when compared with independent root fixation. The transpatellar tendon “tapered teardrop” technique, as described here, facilitates implantation of a consistent bone bridge allograft with accurate positioning.

References

1. Pengas IP, Assiotis A, Nash W, Hatcher J, Banks J, McNicholas MJ. Total meniscectomy in adolescents: A 40-year follow-up. *J Bone Joint Surg Br* 2012;94:1649-1654.
2. Petty CA, Lubowitz JH. Does arthroscopic partial meniscectomy always cause arthritis? *Sports Med Arthrosc Rev* 2012;20:58-61.
3. Chatain F, Adeleine P, Chambat P, Neyret P; Société Française d'Arthroscopie. A comparative study of medial versus lateral arthroscopic partial meniscectomy on stable knees: 10-year minimum follow-up. *Arthroscopy* 2003;19:842-849.
4. McNicholas MJ, Rowley DI, McGurty D, et al. Total meniscectomy in adolescence. A thirty-year follow-up. *J Bone Joint Surg Br* 2000;82:217-221.
5. Smith NA, Parkinson B, Hutchinson CE, Costa ML, Spalding T. Is meniscal allograft transplantation chondroprotective? A systematic review of radiological outcomes. *Knee Surg Sports Traumatol Arthrosc* 2016;24:2923-2935.
6. Aagaard H, Jørgensen U, Bojsen-Møller F. Immediate versus delayed meniscal allograft transplantation in sheep. *Clin Orthop Relat Res* 2003;(406):218-227.
7. Jiang D, Ao YF, Gong X, Wang YJ, Zheng ZZ, Yu JK. Comparative study on immediate versus delayed meniscus allograft transplantation: 4- to 6-year follow-up. *Am J Sports Med* 2014;42:2329-2337.
8. Dienst M, Greis PE, Ellis BJ, Bachus KN, Burks RT. Effect of lateral meniscal allograft sizing on contact mechanics of the lateral tibial plateau: An experimental study in human cadaveric knee joints. *Am J Sports Med* 2007;35:34-42.
9. Kaleka CC, Netto AS, Silva JC, et al. Which are the most reliable methods of predicting the meniscal size for transplantation? *Am J Sports Med* 2016;44:2876-2883.

10. Yoon JR, Kim TS, Lee YM, Jang HW, Kim YC, Yang JH. Transpatellar approach in lateral meniscal allograft transplantation using the keyhole method: Can we prevent graft extrusion? *Knee Surg Sports Traumatol Arthrosc* 2011;19:214-217.
11. Lee DH, Kim JM, Lee BS, Kim KA, Bin SI. Greater axial trough obliquity increases the risk of graft extrusion in lateral meniscus allograft transplantation. *Am J Sports Med* 2012;40:1597-1605.
12. McDermott ID, Lie DTT, Edwards A, Bull AJM, Amis AA. The effects of lateral meniscal allograft transplantation techniques on tibio-femoral contact pressures. *Knee Surg Sports Traumatol Arthrosc* 2008;16:553-560.
13. Verdonk PC, Demurie A, Almqvist KF, Veys EM, Verbruggen G, Verdonk R. Transplantation of viable meniscal allograft: Survivorship analysis and clinical outcome of one hundred cases. *J Bone Joint Surg Am* 2005;87:715-724.
14. Lee SY, Yoon J, Cho YS, et al. Various factors contribute to graft extrusion in lateral meniscus allograft transplantation. *Knee Surg Sports Traumatol Arthrosc* 2017;25:374-382.
15. Choi NH, Yoo SY, Victoroff BN. Position of the bony bridge of lateral meniscal transplants can affect meniscal extrusion. *Am J Sports Med* 2011;39:1955-1959.
16. Ahn JH, Kang HW, Yang TY, Lee JY. Multivariate analysis of risk factors of graft extrusion after lateral meniscus allograft transplantation. *Arthroscopy* 2016;32:1337-1345.
17. ElAttar M, Dhollander A, Verdonk R, Almqvist KF, Verdonk P. Twenty-six years of meniscal allograft transplantation: Is it still experimental? A meta-analysis of 44 trials. *Knee Surg Sports Traumatol Arthrosc* 2011;19:147-157.
18. DeBruycker M, Verdonk PCM, Verdonk RC. Meniscal allograft transplantation: A meta-analysis. *SICOT J* 2017;3:33.
19. Sekiya JK, West RV, Groff YJ, Irrgang JJ, Fu FH, Harner CD. Clinical outcomes following isolated lateral meniscal allograft transplantation. *Arthroscopy* 2006;22:771-780.
20. LaPrade RF, Wills NJ, Spiridonov SI, Perkinson S. A prospective outcomes study of meniscal allograft transplantation. *Am J Sports Med* 2010;38:1804-1812.