



Case report

Retrorectal schwannoma in a middle-aged female: A case report

Diptee Poudel^a, Suraj Shrestha^a, Elisha Poddar^a, Prarthana Pacchai^b, Bishnu Prasad Kandel^{b,*}, Paleswan Joshi Lakhey^b

^a Maharajgunj Medical Campus, Institute of Medicine, Maharajgunj, Nepal

^b Department of Surgical Gastroenterology, Tribhuvan University Teaching Hospital, Maharajgunj, Nepal

ARTICLE INFO

Keywords:

Laparoscopy
Presacral
Retrorectal
Schwannoma

ABSTRACT

Introduction and importance: Primary sacral and presacral lesions are uncommon and pose a significant diagnostic dilemma. Retrorectal schwannoma is a benign primary presacral lesion that is extremely rare and presents with non-specific symptoms.

Case presentation: A 42-years-old, female patient was admitted for lower-back pain for seven days. The retrorectal mass was detected on imaging, and she underwent laparoscopic excision. Pathological examination revealed a rare retrorectal schwannoma.

Clinical discussion: Retrorectal location of schwannomas is rare and the preoperative diagnosis is very difficult as the clinical features and the radiological features are non-specific. In addition, these tumors can be found incidentally on routine rectal or pelvic examinations. As these tumors are benign, encapsulated, and non-invasive, this entity has an excellent prognosis. Despite the tumors' rarity and variety, we concur with the literature that surgical management is required to obtain a clear diagnosis and avoid consequences such as malignant transformation.

Conclusion: Retrorectal Schwannoma presents a diagnostic and therapeutic challenge. Identification is important because surgical excision, either open or laparoscopic, is curative.

1. Introduction

Primary sacral and presacral lesions are considered very uncommon with an estimated incidence of benign lesions of 0.01 cases per 100,000 general population and are common in the older age group, often more than 70 years of age [1]. Retrorectal schwannoma is a benign primary presacral lesion that is extremely rare and often misdiagnosed before the pathological diagnosis is made [2]. Only about 0.5–5% of all schwannomas occur in the retrorectal space and represent 1 in 250 of all retrorectal tumors [3,4].

Herein, we report a case of a 42-year-old female who presented with lower back pain, imaging revealed a mass lesion in the pelvic region, and the diagnosis of schwannoma was confirmed after the histopathological examination of the excised mass. This case has been reported in line with SCARE criteria [5].

2. Case presentation

We present a case of a 42-year-old female patient who presented to

us with a complaint of insidious-onset, continuous, and non-radiating lower back pain for a week. She had no history of nausea, vomiting, hematochezia/melena, abdominal distension, weight loss, or trauma to the back. She was also diagnosed with hypertension and was under medication. Her bowel and bladder habits were normal with no tenesmus, and she had no significant family history of malignancy.

On examination, the patient was afebrile, hemodynamically stable, and fully conscious. Her abdomen was soft and non-tender with normal bowel sounds, and a digital rectal examination revealed no abnormalities. Examination of all other systems was normal. Blood counts were within normal ranges, and liver and renal function tests were unremarkable. The serum levels of carcinoembryonic antigen (CEA) and cancer antigen (CA) 19.9 were within normal limits. Transabdominal ultrasonography of the pelvis showed a well-defined hypoechoic lesion with dimensions of 10 cm × 5.4 cm × 7.2 cm in the pouch of Douglas. A subsequent contrast-enhanced computed tomography (CECT) scan was done which revealed a well-defined heterogenic enhancing oval lobulated soft tissue density mass of 10.5 cm × 9.2 cm × 6.8 cm with calcification in the presacral region and mild heterogeneous

* Corresponding author at: Department of Surgical Gastroenterology, Tribhuvan University Teaching Hospital, P.O. Box: 1524, Maharajgunj, Nepal.

E-mail address: drkandel@hotmail.com (B.P. Kandel).

enhancement in the post-contrast images; features suggestive of benign presacral mass (Fig. 1). The patient was scheduled for laparoscopic excision of the mass by a team of experienced gastrointestinal surgeons. The patient was placed in a lithotomy position and laparoscopy was done via camera port on the umbilicus and working ports on the right side of the umbilical port and right iliac fossa. There was a mass in the retrorectal region firmly adherent to the rectum and laparoscopic dissection was difficult. Surgery was thus converted to open surgery via a lower midline incision and the mass was completely excised. Intraoperatively, approximately 10 cm × 15 cm solid mass was seen in the retrorectal region (Fig. 2). The histopathological examination of the resected mass revealed hypercellular Antoni A and hypocellular Antoni B areas with areas of calcification, hyalinized vessels, lymphoid aggregates, and foamy macrophages without any necrosis. Mitotic figures constituted a 2/10 high power field (Fig. 3). Histopathological features were evident of benign schwannoma. The postoperative period was uneventful. At the time of discharge, she was in good health and her pain had subsided significantly. A one-year follow-up examination showed no recurrence and the patient is doing well.

3. Discussion

The retrorectal space is limited anteriorly by the rectum, by the sacrum posteriorly, the ureters, iliac vessels, and sacral nerve roots on each side, it extends superiorly to the peritoneal reflection and the levator musculature inferiorly [6]. Retrorectal location of schwannomas is considered rare as these benign encapsulated neoplasms are most commonly found in the head, neck, and extremities [7].

These tumors are often asymptomatic. Moreover, preoperative diagnosis is very difficult as the clinical features and the radiological features are non-specific. In addition, these tumors can be found incidentally on routine rectal or pelvic examinations. Symptoms generally appear when they reach a size large enough to cause pressure symptoms. Similar to our case, clinical presentations are typically non-specific, including abdominal or pelvic pain or discomfort. The most common symptoms are radicular pain, followed by lower back pain, digestive symptoms, constipation, and abdominal pain. Rare cases of urinary disturbances, paresthesia, and alteration of bowel habits have also been reported in the literature [8].

Although many imaging modalities have been tried to diagnose retrorectal tumors and establish treatment plans, CT scans and MRI have been the most important means of evaluating sacral lesions and planning the operative approach in conjunction with preoperative angiographic and urological scans [9]. MRI of the pelvis in the identification of retrorectal schwannoma demonstrates a T2 hyperintense, T1-hypointense mass with smooth, well-defined margins, and enhancement on post-

contrast fat-suppressed T1-weighted sequences [10]. In our case, only a CECT was done as the patient couldn't afford further MRI investigation and surgical excision of the tumor was planned. Though the imaging analysis can improve the diagnostic accuracy of presacral schwannoma, histopathological examination is required for the definitive diagnosis. However, a preoperative biopsy of pelvic tumors is contraindicated as it may cause seeding of malignant cells, and an infection may ensue even in a cystic lesion. Thus, complete surgical excision is considered the best biopsy [11].

Grossly, schwannomas can resemble GI stromal tumors (GISTs) as they are tan to white and well-circumscribed with a fibrous capsule [12]. However, the histopathological picture can sometimes mimic other mesenchymal tumors such as GIST, leiomyoma, and leiomyosarcoma and these can be differentiated by the help of immunohistochemical (IHC) staining [13]. Histologically, schwannoma is positive for S-100 and negative for CD117, desmin, and actin [14,15]. Microscopically, there is a proliferation of spindle-shaped cells with oval nuclei and tapered ends, with eosinophilic cytoplasm with fuzzy boundaries. The tumor cells are arranged in compact bundles (Antoni zone A) or looser bundles (Antoni zone B) [16]. As classic histopathological features of schwannoma were present in our case, no further immunohistochemical analysis was performed.

As these tumors are benign, encapsulated, and non-invasive, complete surgical resection of the schwannoma is considered curative and no adjuvant treatment is recommended. Also, once excised completely, recurrence of benign schwannomas is not expected [17–19]. Various approaches including anterior, posterior, or combined 360-degree approaches have been used for the resection of retrorectal schwannomas depending on surgeons' experience as well as the morphology of the lesion [19]. Roughly 40% of reported lesions have been treated via open anterior approaches and 35% via posterior approaches, with the remaining 25% split evenly between staged anterior-posterior and endoscopic anterior approaches [10]. Our patient was planned for laparoscopic anterior resection of the tumor but was later converted to a laparotomy considering dense adhesions between the tumor and rectal area. A study has shown that no significant difference exists between en bloc resection and gross-total resection ($p = 0.25$), or among the surgical approaches ($p = 0.66$). However, postoperative complications were seen more in anterior versus posterior approaches ($p = 0.04$) [8]. As the schwannomas originate from the sacral plexus or the obturator nerve, great care must be taken while enucleating the tumor off the nerves and if the nerve is to be excised en bloc with the tumor, transient to permanent neuropathy is to be expected, and should be discussed preoperatively [20]. In general, benign tumors which can be completely excised have an excellent prognosis without recurrence or long-term morbidity and the long-term survival of 100% without recurrence has

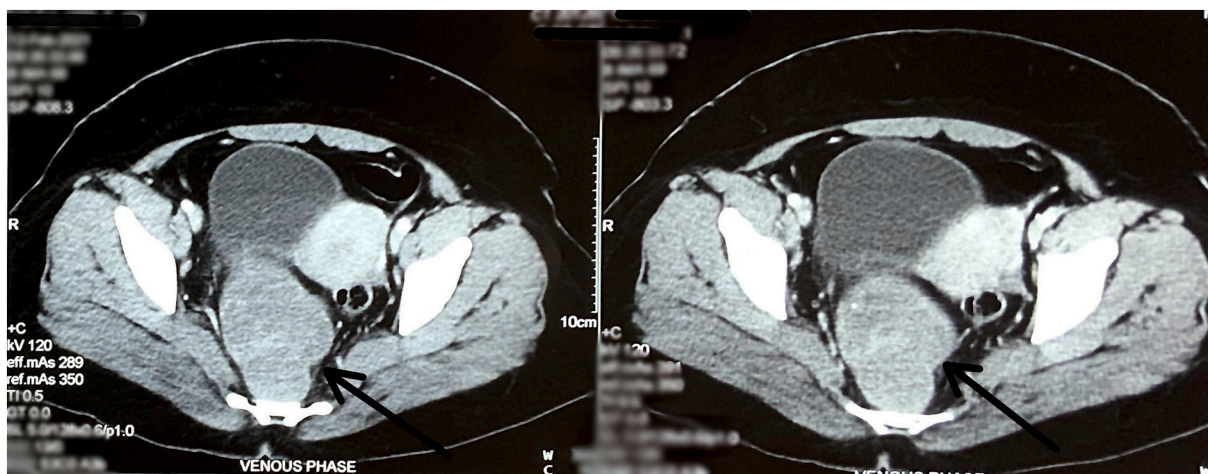


Fig. 1. Contrast-enhanced CT scan of the pelvis shows well-defined heterogeneously enhancing oval lobulated soft tissue density in the presacral region (arrows).

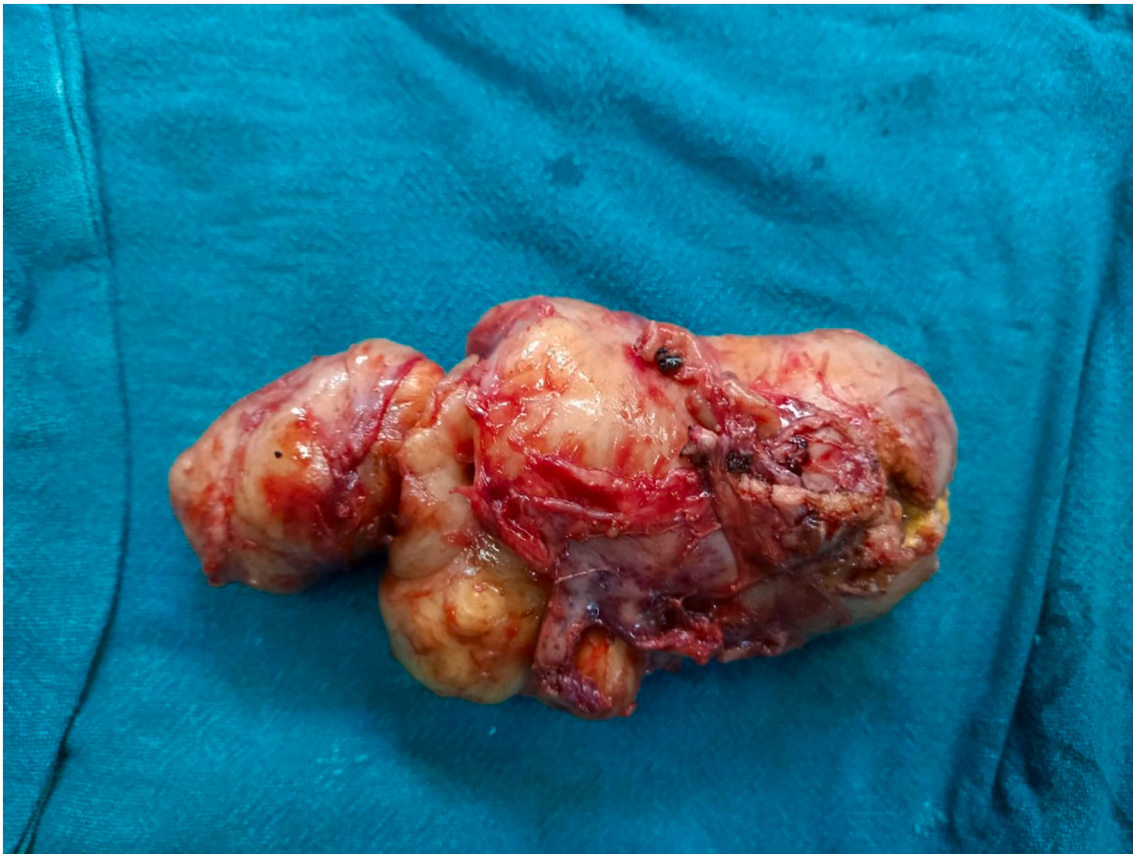

Fig. 2. Gross specimen of the resected pelvic mass.

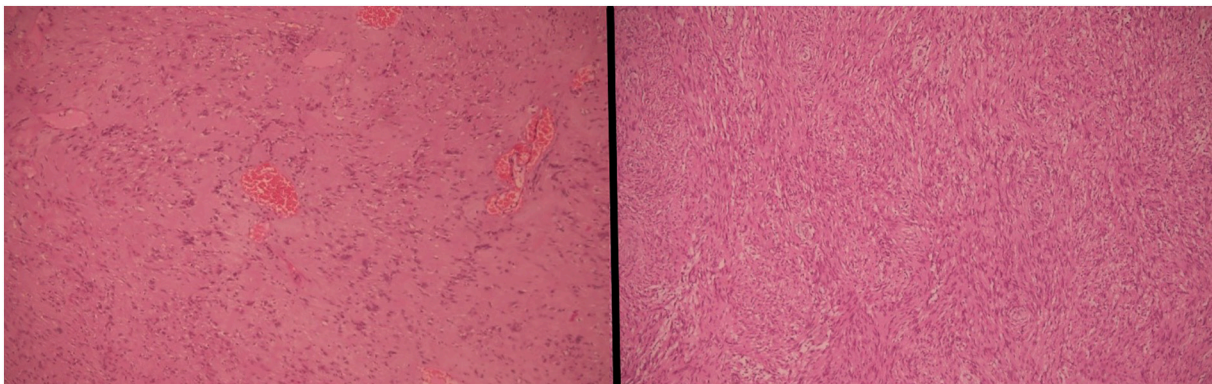


Fig. 3. Histopathological section from the excised mass shows tumors shows arranged in Antoni A and Antoni B areas suggestive of schwannoma.

been reported [20].

4. Conclusion

Tumors in the retrorectal present a diagnostic and therapeutic challenge. Surgery remains the main treatment modality and requires careful planning to obtain optimum results. Identification is important because surgical excision, either open or laparoscopic, is curative.

Funding

None.

Ethical approval

Not required.

Consent for publication

Written informed consent was obtained from the patient for publication of this case report and accompanying images. A copy of the written consent is available for review by the Editor-in-Chief of this journal on request.

Registration of research studies

Not Applicable.

Guarantor

Suraj Shrestha.

Provenance and peer review

Not commissioned, externally peer-reviewed.

CRedit authorship contribution statement

Bishnu Kandel (BK) and Paleswan Joshi Lakhey (PJJ) = Study concept, Data collection, and surgical therapy for the patient.

Diptee Poudel (DP), Suraj Shrestha (SS), and Elisha Poddar (EP) = Writing- original draft preparation.

Diptee Poudel (DP), Suraj Shrestha (SS), Elisha Poddar (EP), and Prarthana Pacchai (PP) = Editing and writing.

BK = senior author and manuscript reviewer.

All the authors read and approved the final manuscript.

Declaration of competing interest

None.

Acknowledgment

We would like to acknowledge Dr. Sansar Babu Tiwari.

References

- [1] S. Sohn, J. Kim, C.K. Chung, N.R. Lee, M.J. Sohn, S.H. Kim, A nation-wide epidemiological study of newly diagnosed primary spine tumor in the adult Korean population, 2009–2011, *J. Korean Neurosurg Soc.* 60 (2) (2017) 195–204, <https://doi.org/10.3340/jkns.2016.0505.011>.
- [2] O. Benzekri, M. El Absi, S. El Mouhadi, et al., Schwannome présacré: à propos d'un cas, *Afr. J. Cancer* 2 (3) (2010) 186–189, <https://doi.org/10.1007/s12558-010-0099-8>.
- [3] C. Santiago, P.A. Lucha, Atypical presentation of a retrorectal ancient Schwannoma: a case report and review of the literature, *Mil. Med.* 173 (8) (2008) 814–816, <https://doi.org/10.7205/milmed.173.8.814>.
- [4] F. Marino, I. Giani, G. Clerico, et al., An uncommon finding: a retrorectal Schwannoma, *Color. Dis.* 9 (9) (2007) 851–852, <https://doi.org/10.1111/j.1463-1318.2007.01249.x>.
- [5] R.A. Agha, T. Franchi, C. Sohrabi, G. Mathew, A. Kerwan, SCARE Group, The SCARE 2020 guideline: updating consensus Surgical CASE REport (SCARE) guidelines, *Int. J. Surg.* 84 (2020) 226–230, <https://doi.org/10.1016/j.ijsu.2020.10.034>.
- [6] J.A. Neale, Retrorectal tumors, *Semin Colon Rectal Surg.* 26 (2) (2015) 73–83, <https://doi.org/10.1053/j.scrs.2015.01.005>.
- [7] I.F. Abdelwahab, G. Hermann, A. Stollman, D. Wolfe, M. Lewis, J. Zawin, Case report 564: Giant intraosseous Schwannoma, *Skelet. Radiol.* 18 (6) (1989) 466–469, <https://doi.org/10.1007/BF00368618>.
- [8] Z. Pennington, E.M. Westbroek, A.K. Ahmed, et al., Surgical management of giant presacral schwannoma: systematic review of published cases and meta-analysis, *J. Neurosurg. Spine* (2019) 1–12, <https://doi.org/10.3171/2019.4.SPINE19240>. Published online July 5.
- [9] B.H. Kye, H.J. Kim, H.M. Cho, H.M. Chin, J.G. Kim, Clinicopathological features of retrorectal tumors in adults: 9 years of experience in a single institution, *J. Korean Surg. Soc.* 81 (2) (2011) 122–127, <https://doi.org/10.4174/jkss.2011.81.2.122>.
- [10] Z. Pennington, C. Reinshagen, A.K. Ahmed, et al., Management of presacral schwannomas—a 10-year multi-institutional series, *Ann. Transl. Med.* 7 (10) (2019) 228, <https://doi.org/10.21037/atm.2019.01.66>.
- [11] S.W. Jao, R.W. Beart Jr., R.J. Spencer Jr., H.M. Reiman Jr., D.M. Ilstrup Jr., Retrorectal tumors. Mayo Clinic experience, 1960–1979, *Dis. Colon Rectum* 28 (9) (1985) 644–652, <https://doi.org/10.1007/BF02553440>.
- [12] T. Wiech, A. Walch, M. Werner, Histopathological classification of nonneoplastic and neoplastic gastrointestinal submucosal lesions, *Endoscopy* 37 (7) (2005) 630–634, <https://doi.org/10.1055/s-2005-870127>.
- [13] S.K. Mohanty, K. Jena, T. Mahapatra, et al., Gastric GIST or gastric schwannoma—a diagnostic dilemma in a young female, *Int. J. Surg. Case Rep.* 28 (2016) 60–64, <https://doi.org/10.1016/j.ijscr.2016.09.026>.
- [14] Y. Daimaru, H. Kido, H. Hashimoto, M. Enjoji, Benign schwannoma of the gastrointestinal tract: a clinicopathologic and immunohistochemical study, *Hum. Pathol.* 19 (3) (1988) 257–264, [https://doi.org/10.1016/s0046-8177\(88\)80518-5](https://doi.org/10.1016/s0046-8177(88)80518-5).
- [15] E.B. Stelow, R. Lai, R.H. Bardales, B.M. Linzie, S. Mallery, M.W. Stanley, Endoscopic ultrasound-guided fine-needle aspiration cytology of peripheral nerve-sheath tumors, *Diagn. Cytopathol.* 30 (3) (2004) 172–177, <https://doi.org/10.1002/dc.10274>.
- [16] C. Bouvier, A. Maues de Paula, P.H. Roche, C. Chagnaud, D. Figarella-Branger, Tumeurs du système nerveux périphérique, *EMC - Neurol.* 10 (1) (2013) 1–11, [https://doi.org/10.1016/s0246-0378\(12\)58206-0](https://doi.org/10.1016/s0246-0378(12)58206-0).
- [17] M. Huang, H. Qian, J. Wang, Q. Zhao, T. Jiang, 'an., Giant presacral schwannoma in man: report of a case with emphasis on imaging findings, *World Neurosurg.* 133 (2020) 14–16, <https://doi.org/10.1016/j.wneu.2019.09.074>.
- [18] O.S. Schindler, J.H. Dixon, P. Case, Retroperitoneal giant schwannomas: report on two cases and review of the literature, *J. Orthop. Surg.* 10 (1) (2002) 77–84, <https://doi.org/10.1177/230949900201000114>.
- [19] B.H. Lee, S.J. Hyun, J.H. Park, K.J. Kim, Single stage posterior approach for total resection of presacral giant Schwannoma: a technical case report, *Korean J. Spine* 14 (3) (2017) 89–92, <https://doi.org/10.14245/kjs.2017.14.3.89>.
- [20] S. Shenoy, Diagnosis and management of presacral (retrorectal) tumors, *J. Gastrointest. Cancer* 49 (3) (2018) 373–378, <https://doi.org/10.1007/s12029-018-0111-6>.