

## Retrospective Study

# Prevalence of hypercoagulable states in stented thrombotic iliac vein compression syndrome with comparison of re-intervention and anticoagulation regimens

Peyton Cramer, Cheryl Mensah, Maria DeSancho, Anuj Malhotra, Ronald Winokur, Andrew Kesselman

**ORCID number:** Peyton Cramer 0000-0003-1048-3555; Cheryl Mensah 0000-0001-5305-8618; Maria DeSancho 0000-0001-9239-5131; Anuj Malhotra 0000-0002-8464-2857; Ronald Winokur 0000-0002-7366-7530; Andrew Kesselman 0000-0002-5286-7912.

**Author contributions:** Cramer P and Kesselman A designed the research study and performed the research; Cramer P, Mensah C, DeSancho M, Malhotra A, Winokur R, and Kesselman A analyzed the data and wrote the manuscript; all authors have read and approve the final manuscript.

**Institutional review board statement:** The study was reviewed and approved by the Weill Cornell Medicine Institutional Review Board, No. 20-03021729.

**Informed consent statement:** Informed consent was waived for this study by the institutional review board.

**Conflict-of-interest statement:** There is no conflict-of-interest.

**Data sharing statement:** No additional data available.

**Peyton Cramer, Anuj Malhotra, Andrew Kesselman,** Department of Radiology, Division of Interventional Radiology, New York Presbyterian Hospital/Weill Cornell Medicine, New York, NY 10065, United States

**Cheryl Mensah, Maria DeSancho,** Department of Medicine, Division of Hematology-Oncology, New York Presbyterian Hospital/Weill Cornell Medicine, New York, NY 10065, United States

**Ronald Winokur,** Department of Radiology, Division of Interventional Radiology, Thomas Jefferson University Hospital, Philadelphia, Pennsylvania 19107, United States

**Corresponding author:** Peyton Cramer, MD, Doctor, Department of Radiology, Division of Interventional Radiology, New York Presbyterian Hospital/Weill Cornell Medicine, No. 501 Payson Pavilion 25 E. 68th St., New York, NY 10065, United States. [pmc9010@nyp.org](mailto:pmc9010@nyp.org)

## Abstract

### BACKGROUND

Endovascular therapy is playing an increasing role in the treatment of iliofemoral venous disease. Iliac stent patency is multifactorial, and current management is based on best clinical practices, varying by institution.

### AIM

To evaluate how thrombophilia influences management and outcomes of patients who undergo venous stenting for thrombotic iliac vein compression syndromes.

### METHODS

A retrospective observational analysis was performed on 65 patients with thrombotic iliac vein compression syndrome that underwent common iliac vein (CIV) stenting between December 2013 and December 2019 at a large academic center. Search criteria included CIV stenting and iliac vein compression. Non-thrombotic lesions and ilio caval thrombosis and/or occlusions were excluded. A total of 65 patients were selected for final analysis. Demographic information, procedural data points, and post-procedural management and outcomes were collected. Statistical analyses included Fisher's exact and Chi-square tests to compare discrete variables and the Wilcoxon rank-sum test to compare continuous variables between thrombophilia positive and negative patients.

**Country/Territory of origin:** United States

**Specialty type:** Radiology, nuclear medicine and medical imaging

**Provenance and peer review:** Unsolicited article; Externally peer reviewed.

**Peer-review model:** Single blind

**Peer-review report's scientific quality classification**

Grade A (Excellent): 0

Grade B (Very good): 0

Grade C (Good): C

Grade D (Fair): 0

Grade E (Poor): 0

**Open-Access:** This article is an open-access article that was selected by an in-house editor and fully peer-reviewed by external reviewers. It is distributed in accordance with the Creative Commons Attribution NonCommercial (CC BY-NC 4.0) license, which permits others to distribute, remix, adapt, build upon this work non-commercially, and license their derivative works on different terms, provided the original work is properly cited and the use is non-commercial. See: <http://creativecommons.org/licenses/by-nc/4.0/>

**Received:** February 10, 2021

**Peer-review started:** February 10, 2021

**First decision:** October 17, 2021

**Revised:** November 25, 2021

**Accepted:** December 9, 2021

**Article in press:** December 9, 2021

**Published online:** December 28, 2021

**P-Reviewer:** Nayak S

**S-Editor:** Wang JL

**L-Editor:** A

**P-Editor:** Wang JL



## RESULTS

65 patients underwent successful balloon angioplasty and CIV stenting. Of these patients, 33 (50.8%) underwent thrombophilia testing, with 16 (48.5%) testing positive. Stent patency on ultrasound did not significantly differ between thrombophilia positive and negative patients at 1 mo (92.3% *vs* 81.3%,  $P = 0.6$ ), 6 mo (83.3% *vs* 80%,  $P > 0.9$ ), or 12 mo (77.8% *vs* 76.9%,  $P = 0.8$ ). Immediately after stent placement, thrombophilia patients were more likely to be placed on dual therapy (aspirin and anticoagulation) or triple therapy (aspirin, clopidogrel, and anticoagulation) (50% *vs* 41.2%,  $P > 0.9$ ), and remain on dual therapy at 6 mo (25% *vs* 12.5%,  $P = 0.5$ ) and 12 mo (25% *vs* 6.7%,  $P = 0.6$ ). There was no significant difference in re-intervention rates (25% *vs* 35.3%,  $P = 0.7$ ) or number of re-interventions (average 2.3 *vs* 1.3 per patient,  $P = 0.4$ ) between thrombophilia positive and negative patients.

## CONCLUSION

Half of patients with stented thrombotic iliac vein compression syndrome and thrombophilia testing were positive. The presence of thrombophilia did not significantly impact stent patency or re-intervention rates.

**Key Words:** Thrombophilia; Iliac vein compression syndrome; Iliac vein stent; May Thurner; Anticoagulation; Endovascular

©The Author(s) 2021. Published by Baishideng Publishing Group Inc. All rights reserved.

**Core Tip:** Endovascular therapy is playing an increasing role in the treatment of iliofemoral venous disease. Iliac stent patency is multifactorial, and current management is based on best clinical practices. Despite an underlying anatomic venous abnormality, half of our patient cohort with stented thrombotic iliac vein compression syndrome tested positive for thrombophilia. The presence of thrombophilia did not demonstrate a statistically significant difference in stent patency rates or re-intervention rates.

**Citation:** Cramer P, Mensah C, DeSancho M, Malhotra A, Winokur R, Kesselman A. Prevalence of hypercoagulable states in stented thrombotic iliac vein compression syndrome with comparison of re-intervention and anticoagulation regimens. *World J Radiol* 2021; 13(12): 371-379

**URL:** <https://www.wjgnet.com/1949-8470/full/v13/i12/371.htm>

**DOI:** <https://dx.doi.org/10.4329/wjr.v13.i12.371>

## INTRODUCTION

Iliofemoral vein thrombosis accounts for approximately 25% of all deep vein thrombosis and is associated with an increased risk of embolic and post-thrombotic complications[1]. Anticoagulation is the standard of care for the treatment of symptomatic acute deep vein thrombosis. However, despite appropriate anticoagulant therapy, the post-thrombotic syndrome (PTS) remains a frequent complication seen in 30% to 50% of patients diagnosed with iliofemoral deep vein thrombosis. The clinical manifestations of PTS include pain, swelling, heaviness, fatigue, itching, or cramping of the affected leg[1-3]. To reduce the burden of post-thrombotic symptoms, endovascular approaches with thrombolysis, thrombectomy, balloon angioplasty and stenting are being increasingly utilized in centers with expertise in these procedures[4-7]. The current C-TRACT trial is further investigating the role of endovascular intervention for chronic iliac vein obstruction. Guidelines for therapeutic anticoagulation after ilioacaval stent placement remain variable by institution, however long-term anticoagulation is often recommended in patients with underlying thrombophilia[8].

Thrombophilia is an inherited or acquired condition that predisposes a person to develop a thrombotic event. Thrombophilia screening should only be done if the discovery of the thrombophilia will require extending the duration of the anticoagulation treatment. Conversely, if a thrombotic event occurred in the presence of a major

transient risk factor, thrombophilia screening should not be performed. Whether or not the presence of an underlying thrombophilia increases the risk of recurrent thrombosis, particularly in-stent thrombosis in patients that have undergone venous interventional procedures, remains unknown[9]. Therefore, we sought out to identify the prevalence of thrombophilias in patients with thrombotic iliac vein compression syndrome who underwent venous stenting. We also compared if the presence of thrombophilia influenced post-procedure antithrombotic regimens, stent patency and re-intervention rates.

## MATERIALS AND METHODS

The institutional review board approved this study with waiver of informed consent. We performed a retrospective review of electronic medical records at a large academic medical center from December 2013 to December 2019. Search criteria included common iliac vein (CIV) stenting and iliac vein compression. Non-thrombotic lesions and ilio caval thrombosis and/or occlusions were excluded. A total of 65 patients were selected for final analysis.

Medical records were reviewed for demographic information, procedural data points, and post-procedural management and outcomes. Procedural data points included pre-intervention venous patency, stent location, stent type and diameter, and any additional endovascular procedures performed at that time. Post-procedural outcomes included subjective clinical symptom improvement, medication regimen and duration, stent patency on imaging, and re-intervention requirement. Types of antithrombotic therapy included antiplatelet, anticoagulation, single antiplatelet and anticoagulation (dual therapy), or dual antiplatelet agents and anticoagulation (triple therapy). Hematology consultations with or without thrombophilia evaluations were also reviewed. Statistical analyses included Fisher's exact and Chi-square tests to compare discrete variables and the Wilcoxon rank-sum test to compare continuous variables between thrombophilia positive and negative patients.

## RESULTS

Baseline demographics are summarized in **Table 1**. Our patient population included 38 (58.5%) males and 27 (41.5%) females. Clinical symptoms included lower extremity swelling ( $n = 57$ , 87.7%), pain ( $n = 44$ , 67.7%), venous stasis ulceration ( $n = 7$ , 10.8%), varicose veins ( $n = 3$ , 4.6%), and pelvic pain ( $n = 2$ , 3.1%). Venous thromboembolism histories were reviewed for high risk features suspicious for thrombophilia; 24 (36.9%) experienced their first venous thrombosis (VTE) at a young age (less than 40 years old), 12 (18.5%) had a strong family history of thrombosis, and 16 (24.6%) were unprovoked.

A total of 33 (50.8%) underwent thrombophilia testing, with 16 (48.5%) testing positive. There were ten patients with Factor V Leiden heterozygous mutations (G1691A), four with antiphospholipid antibodies (three lupus anticoagulant, one anticardiolipin antibody), one prothrombin gene mutation G20210A, one antithrombin deficiency, and one protein S deficiency. Only one patient had two concomitant thrombophilias, comprising Factor V Leiden and lupus anticoagulant.

## Procedure Details

Procedure details are summarized in **Table 2**. All 65 subjects included in this study underwent venography, balloon angioplasty, and CIV stenting. The majority of interventions were left-sided ( $n = 50$ , 76.9%) with stenting extending into the external iliac vein ( $n = 54$ , 83.1%) and common femoral vein ( $n = 45$ , 69.2%).

## Procedure Outcomes

Technical success, defined by CIV stent placement and clearance of thrombus burden, was achieved in 65 (100%) patients. Clinical success, defined by patient reported symptom improvement, was achieved in 14 (87.5%) thrombophilia positive, 12 (70.6%)

**Table 1** Baseline demographics

Variable	Summary (n = 65)
Median age in years (interquartile range)	54 (41-63)
Median BMI in kg/m <sup>2</sup> (interquartile range)	28 (25.1-32.7)
Gender	
Male	38 (58.5%)
Female	27 (41.5%)
Clinical symptoms	
Lower extremity swelling	57 (87.7%)
Lower extremity pain	44 (67.7%)
Venous stasis ulceration	7 (10.8%)
Varicose veins	3 (4.6%)
Pelvic pain	2 (3.1%)
Symptomatic side	
Left	49 (75.4%)
Right	14 (21.5%)
Bilateral	2 (3.1%)
Thrombophilia risk factor	
Young age (< 40 yr)	24 (35.9%)
Family history	12 (18.5%)
Unprovoked	16 (24.6%)
VTE provoking factor	
Prolonged immobilization	15 (23.1%)
Malignancy	13 (20.0%)
Recent surgery	5 (7.7%)
Trauma	5 (7.7%)
Pregnancy	7 (14.6%)
Hormonal supplement	4 (6.2%)
None	16 (24.6%)

BMI: Body mass index; VTE: Venous thrombosis.

thrombophilia negative, and 21 (65.6%) untested. Median follow-up duration was 14 mo.

Antithrombotic regimens were reviewed at post-procedure day 1 (*n* = 65), 6 mo (*n* = 61), and 12 mo (*n* = 57). The day after stent placement, 2 (3.1%) patients were on single antiplatelet, 34 (52.3%) patients were on anticoagulation, 17 (26.2%) patients were on dual therapy, 11 (16.9%) patients were on triple therapy, and 1 (1.5%) patient was off antithrombotic medication. At 6 mo, 3 (4.9%) patients were on single antiplatelet, 34 (55.7%) patients were on anticoagulation, 17 (27.9%) patients were on dual therapy, 0 (0%) patients were on triple therapy, and 7 (11.5%) patients were off antithrombotic medication. At 12 mo, 11 (19.3%) patients were on single antiplatelet, 26 (45.6%) were on anticoagulation, 9 (15.8%) patients were on dual therapy, 0 (0%) patients were on triple therapy, and 11 (19.3%) patients were off antithrombotic medication.

Post-stenting antithrombotic regimens are broken down by thrombophilia testing in Figures 1 and 2. Immediately after stent placement, thrombophilia patients were more likely to be placed on dual or triple therapy (50% *vs* 41.2%, *P* > 0.9) and remain on dual therapy at 6 mo (25% *vs* 12.5%, *P* = 0.5) and 12 mo (25% *vs* 6.7%, *P* = 0.6) compared to thrombophilia negative patients. Stent patency on ultrasound did not significantly differ between thrombophilia positive and negative patients at 1 mo (92.3% *vs* 81.3%, *P*

Table 2 Procedure details

Variable	Summary (n = 65)
Pre-procedure CIV patency	
Stenosis	47 (72.3%)
Occlusion	16 (24.6%)
In-stent thrombosis	2 (3.1%)
Stent location	
Left CIV	50 (76.9%)
Right CIV	11 (16.9%)
Bilateral CIV	4 (6.2%)
Stent type	
Wallstent	51 (78.5%)
Venovo	9 (13.8%)
Smart	2 (3.1%)
Vici	3 (4.6%)
CIV stent balloon dilation diameter (mm)	
12	1 (1.5%)
14	14 (21.5%)
16	28 (43.1%)
18	19 (29.2%)
20	3 (4.6%)
Additional stented segments	
External iliac vein	54 (83.1%)
Common femoral vein	45 (69.2%)
Simultaneous endovascular interventions	
Thrombolysis	25 (38.5%)
Thrombectomy	17 (26.2%)
CIV filter retrieval	3 (4.6%)

CIV: Common iliac vein.

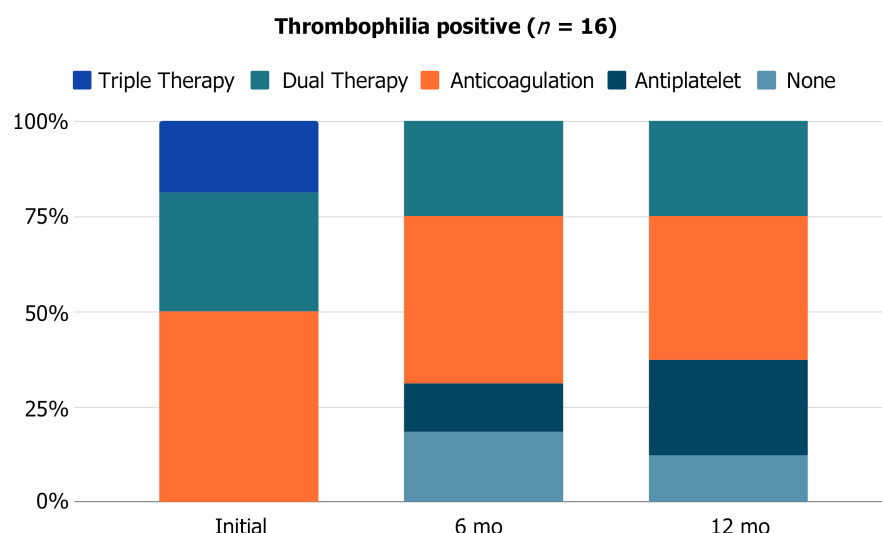
= 0.6), 6 mo (83.3% *vs* 80%,  $P > 0.9$ ), or 12 mo (77.8% *vs* 76.9%,  $P = 0.8$ ).

Stent thrombosis occurred in 2 (12.5%) thrombophilia positive and 4 (23.5%) thrombophilia negative patients. The median time to stent thrombosis was longer in thrombophilia patients (1.1 mo *vs* 0.5 mo). At the time of stent thrombosis, 3 (50%) patients were on anticoagulation, 1 (16.7%) patient was on dual therapy, and 2 (33.3%) patients were off antithrombotic medication. Following thrombosis, all patients were transitioned to anticoagulation alone ( $n = 3$ ) or dual therapy ( $n = 3$ ). Anticoagulation therapies included full-dose direct oral anticoagulants, half-dose direct oral anticoagulants, and enoxaparin. There was no significant difference in re-intervention rates (25% *vs* 35.3%,  $P = 0.7$ ) or number of re-interventions (average 2.3 *vs* 1.3 per patient,  $P = 0.4$ ) between thrombophilia positive and negative patients, as seen in Table 3.

Bleeding complications from antithrombotic medications were seen in 14 (21.5%) patients, including ecchymoses, hematuria, rectal bleeding, epistaxis, and menorrhagia. None of these events required medication cessation or intervention. Of the patients that experienced bleeding complications, 7 (50.0%) were on anticoagulation, 4 (28.6%) were on dual therapy, and 3 (21.4%) were on triple therapy.

**Table 3 Complications by thrombophilia testing**

Thrombophilia work-up (n = 33)	Positive (n = 16)	Negative (n = 17)
Clinical success		
Stent patency	14 (87.5%)	12 (70.6%)
1 mo	12 of 13 (92.3%)	13 of 16 (81.3%)
6 mo	10 of 12 (83.3%)	12 of 15 (80%)
12 mo	7 of 9 (77.8%)	10 of 13 (76.9%)
Stent thrombosis	2 (12.5%)	4 (23.5%)
Anticoagulated during stent thrombosis	1 of 2 (50%)	2 of 4 (50%)
Re-intervention rates	4 (25%)	6 (35.3%)
Number of re-interventions		
1	50%	67%
2	0%	33%
3	25%	0%
4	25%	0%

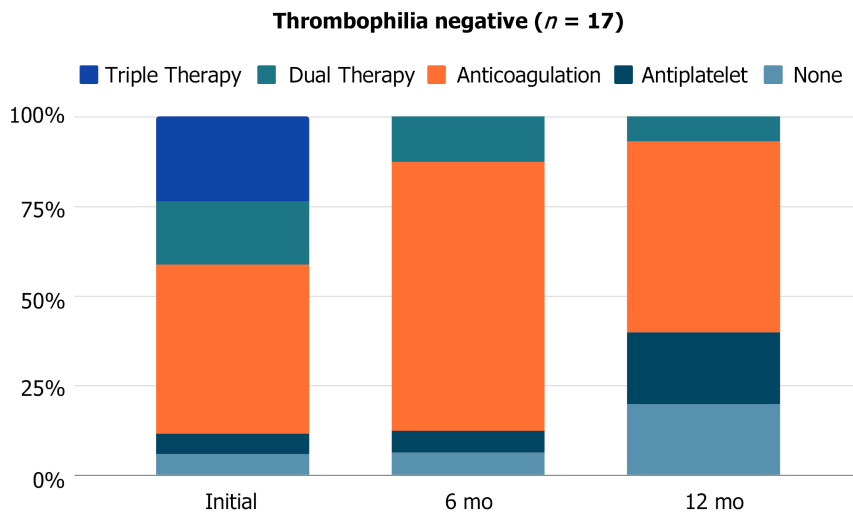
**Figure 1 Post-stenting antithrombotic regimens in thrombophilia positive patients at day 1 (n = 16), 6 mo (n = 16), and 12 mo (n = 16).**

## DISCUSSION

Endovascular therapy is playing an increasing role in the treatment of iliofemoral venous disease. Iliac stent patency is multifactorial, and current management is based on best clinical practices, varying by institution[11].

Diagnostic thrombophilia testing is recommended in patients with idiopathic or recurrent VTE, first VTE at a young age (< 40 years), VTE in the setting of a strong family history or VTE in atypical locations. There is no single laboratory test available to identify all thrombophilias and results can be affected by a variety of clinical conditions and drugs. Based on this premise, thrombophilia testing should only be performed by a coagulation specialist who knows when to do the screening, provide accurate interpretation of the results and educate the patient[9]. Our cohort demonstrated that despite having an anatomic consideration for increased thrombosis risk, 48.5% of patients who undergo venous stenting for thrombotic iliac vein compression syndrome had an underlying thrombophilia when testing was performed. This result is higher than the 32% rate of positive thrombophilia identified in 4494 patients with symptomatic VTE in the RIETE registry[12] and similar to other studies ranging from 55% to 61%[13,14]. Therefore, the decision for thrombophilia testing should be discussed by a multidisciplinary team and considered only when it





**Figure 2** Post-stenting antithrombotic regimens in thrombophilia negative patients at day 1 (*n* = 17), 6 mo (*n* = 16), and 12 mo (*n* = 15).

will impact post-procedural medical management.

The extent of influence of inherited thrombophilia on the risk of VTE recurrence remains controversial[10]. In our cohort, stent patency and re-intervention rates were not significantly different between thrombophilia positive and negative patients. In all patients with thrombotic iliac vein compression syndrome, antithrombotic compliance and close imaging follow-up are necessary to optimize stent patency and prevent or delay re-intervention. The median time to stent thrombosis was less than one month, emphasizing the importance of the immediate post-procedural period. Immediately after stent placement, thrombophilia patients were more likely to be placed on dual or triple therapy and remain on dual therapy at 6 mo and 12 mo, although this finding was not statistically significant given the smaller sample size. Following thrombosis, all patients were transitioned to long-term anticoagulation or dual therapy, including full-dose or half-dose direct oral anticoagulants.

There is controversy around whether venous stent patency is best maintained by combined antiplatelet and anticoagulation therapy *vs* anticoagulation alone[15]. Antiplatelet agents did not appear to significantly increase the bleeding risk in our study, with almost half of thrombophilia patients remaining on long term antiplatelet medications and more than half on anticoagulation. The long-term management following venous stenting in thrombotic iliac vein compression syndrome is complex and patient specific. Because there was no significant difference in stent patency or re-intervention rates amongst thrombophilia positive and negative patients, the need for thrombophilia testing should be individualized and only considered when it will impact post-procedural medical management.

This study has several limitations. First it is a single center retrospective design; second, there is provider bias in choosing antithrombotic regimens based on their presumed risk of thrombosis; and third, venous stent type and extent varied, introducing confounders. Moreover, given our small sample size, our study was underpowered to obtain statistical significance for subgroups and antithrombotic regimens. Future studies focusing on anticoagulation related to venous stenting in larger cohorts would be helpful. Larger prospective randomized control trials are needed.

## CONCLUSION

Despite an underlying anatomic venous abnormality, in our cohort of patients that underwent thrombophilia testing in the setting of stented common iliac thrombosis, half tested positive for thrombophilia. The presence of thrombophilia did not demonstrate a statistically significant difference in stent patency rates or re-intervention rates. The need for thrombophilia workup should be individualized and discussed by multidisciplinary teams and considered only when it will impact post-procedural medical management.

## ARTICLE HIGHLIGHTS

### Research perspectives

The long-term management following venous stenting in thrombotic iliac vein compression syndrome is complex and patient specific. Because there was no significant difference in stent patency or re-intervention rates amongst thrombophilia positive and negative patients, the need for thrombophilia testing should be individualized and only considered when it will impact post-procedural medical management. Future studies focusing on anticoagulation related to venous stenting in larger cohorts would be helpful.

### Research conclusions

Half of patients with stented thrombotic iliac vein compression syndrome and thrombophilia testing were positive. The presence of thrombophilia did not demonstrate a significant difference in stent patency or re-intervention rates.

### Research results

65 patients underwent successful balloon angioplasty and common iliac vein (CIV) stenting. Stent patency on ultrasound did not significantly differ between thrombophilia positive and negative patients at 1 mo (92.3% *vs* 81.3%,  $P = 0.6$ ), 6 mo (83.3% *vs* 80%,  $P > 0.9$ ), or 12 mo (77.8% *vs* 76.9%,  $P = 0.8$ ). Immediately after stent placement, thrombophilia patients were more likely to be placed on dual therapy (aspirin and anticoagulation) or triple therapy (aspirin, clopidogrel, and anticoagulation) (50% *vs* 41.2%,  $P > 0.9$ ), and remain on dual therapy at 6 mo (25% *vs* 12.5%,  $P = 0.5$ ) and 12 mo (25% *vs* 6.7%,  $P = 0.6$ ). There was no significant difference in re-intervention rates (25% *vs* 35.3%,  $P = 0.7$ ) or number of re-interventions (average 2.3 *vs* 1.3 per patient,  $P = 0.4$ ) between thrombophilia positive and negative patients.

### Research methods

A retrospective observational analysis was performed on 65 patients with thrombotic iliac vein compression syndrome that underwent CIV stenting at a large academic center. Non-thrombotic lesions and ilio caval thrombosis and/or occlusions were excluded. Demographic information, procedural data points, and post-procedural management were compared between thrombophilia positive and negative patients.

### Research objectives

To evaluate the prevalence and compare how thrombophilia influences management and outcomes of patients who undergo venous stenting for thrombotic iliac vein compression syndromes.

### Research motivation

Guidelines for therapeutic anticoagulation after ilio caval stent placement remain variable by institution, however long-term anticoagulation is often recommended in patients with underlying thrombophilia. Whether or not the presence of an underlying thrombophilia increases the risk of recurrent thrombosis, particularly in-stent thrombosis in patients that have undergone venous interventional procedures, remains unknown.

### Research background

Iliofemoral vein thrombosis accounts for approximately 25% of all deep vein thrombosis and is associated with an increased risk of embolic and post-thrombotic complications. Anticoagulation is the standard of care for the treatment of symptomatic acute deep vein thrombosis. However, despite appropriate anticoagulant therapy, the post-thrombotic syndrome remains a frequent complication seen in 30% to 50% of patients diagnosed with iliofemoral deep vein thrombosis. To reduce the burden of post-thrombotic symptoms, endovascular therapy is playing an increasing role in the treatment of iliofemoral venous disease.

## ACKNOWLEDGEMENTS

We would like to thank Charlene Thomas for her support with our statistical analysis.



## REFERENCES

- 1 **Nyamekye I**, Merker L. Management of proximal deep vein thrombosis. *Phlebology* 2012; **27**: 61-72 [PMID: [22457306](#) DOI: [10.1258/phleb.2012.012s37](#)]
- 2 **Kahn SR**, Comerota AJ, Cushman M, Evans NS, Ginsberg JS, Goldenberg NA, Gupta DK, Prandoni P, Vedantham S, Walsh ME, Weitz JI; American Heart Association Council on Peripheral Vascular Disease, Council on Clinical Cardiology, and Council on Cardiovascular and Stroke Nursing. The postthrombotic syndrome: evidence-based prevention, diagnosis, and treatment strategies: a scientific statement from the American Heart Association. *Circulation* 2014; **130**: 1636-1661 [PMID: [25246013](#) DOI: [10.1161/CIR.0000000000000130](#)]
- 3 **Vedantham S**, Goldhaber SZ, Julian JA, Kahn SR, Jaff MR, Cohen DJ, Magnuson E, Razavi MK, Comerota AJ, Gornik HL, Murphy TP, Lewis L, Duncan JR, Nieters P, Derfler MC, Filion M, Gu CS, Kee S, Schneider J, Saad N, Blinder M, Moll S, Sacks D, Lin J, Rundback J, Garcia M, Razdan R, VanderWoude E, Marques V, Kearon C; ATTRACT Trial Investigators. Pharmacomechanical Catheter-Directed Thrombolysis for Deep-Vein Thrombosis. *N Engl J Med* 2017; **377**: 2240-2252 [PMID: [29211671](#) DOI: [10.1056/NEJMoa1615066](#)]
- 4 **Kahn SR**, Julian JA, Kearon C, Gu CS, Cohen DJ, Magnuson EA, Comerota AJ, Goldhaber SZ, Jaff MR, Razavi MK, Kindzelski AL, Schneider JR, Kim P, Chaer R, Sista AK, McLafferty RB, Kaufman JA, Wible BC, Blinder M, Vedantham S; ATTRACT Trial Investigators. Quality of life after pharmacomechanical catheter-directed thrombolysis for proximal deep venous thrombosis. *J Vasc Surg Venous Lymphat Disord* 2020; **8**: 8-23 [PMID: [31843251](#) DOI: [10.1016/j.jvsv.2019.03.023](#)]
- 5 **Kuettling D**, Luetkens J, Wolter K, Faron A, Kania A, Thomas D. Catheter-directed thrombectomy for highly symptomatic patients with iliofemoral deep venous thrombosis not responsive to conservative treatment. *Cardiovasc Intervent Radiol* 2020; **43**: 556-564 [DOI: [10.1007/s00270-020-02415-7](#)]
- 6 **Mabud TS**, Cohn DM, Arendt VA, Jeon GS, An X, Fu J, Souffrant AD, Sailer AM, Shah R, Wang D, Sze DY, Kuo WT, Rubin DL, Hofmann LV. Lower Extremity Venous Stent Placement: A Large Retrospective Single-Center Analysis. *J Vasc Interv Radiol* 2020; **31**: 251-259 [PMID: [31542273](#) DOI: [10.1016/j.jvir.2019.06.011](#)]
- 7 **Razavi MK**, Jaff MR, Miller LE. Safety and Effectiveness of Stent Placement for Iliofemoral Venous Outflow Obstruction: Systematic Review and Meta-Analysis. *Circ Cardiovasc Interv* 2015; **8**: e002772 [PMID: [26438686](#) DOI: [10.1161/CIRCINTERVENTIONS.115.002772](#)]
- 8 **Mahnken AH**, Thomson K, de Haan M, O'Sullivan GJ. CIRSE standards of practice guidelines on ilio caval stenting. *Cardiovasc Intervent Radiol* 2014; **37**: 889-897 [PMID: [24633533](#) DOI: [10.1007/s00270-014-0875-4](#)]
- 9 **Nakashima MO**, Rogers HJ. Hypercoagulable states: an algorithmic approach to laboratory testing and update on monitoring of direct oral anticoagulants. *Blood Res* 2014; **49**: 85-94 [PMID: [25025009](#) DOI: [10.5045/br.2014.49.2.85](#)]
- 10 **Rybstein MD**, DeSancho MT. Hypercoagulable States and Thrombophilias: Risks Relating to Recurrent Venous Thromboembolism. *Semin Intervent Radiol* 2018; **35**: 99-104 [PMID: [29872244](#) DOI: [10.1055/s-0038-1642037](#)]
- 11 **Attaran RR**, Ozdemir D, Lin IH, Mena-Hurtado C, Lansky A. Evaluation of anticoagulant and antiplatelet therapy after ilio caval stenting: Factors associated with stent occlusion. *J Vasc Surg Venous Lymphat Disord* 2019; **7**: 527-534 [PMID: [31203859](#) DOI: [10.1016/j.jvsv.2019.01.058](#)]
- 12 **Roldan V**, Lecumberri R, Muñoz-Torrero JF, Vicente V, Rocha E, Brenner B, Monreal M; RIETE Investigators. Thrombophilia testing in patients with venous thromboembolism. Findings from the RIETE registry. *Thromb Res* 2009; **124**: 174-177 [PMID: [19101711](#) DOI: [10.1016/j.thromres.2008.11.003](#)]
- 13 **Caprini JA**, Goldshteyn S, Glase CJ, Hathaway K. Thrombophilia testing in patients with venous thrombosis. *Eur J Vasc Endovasc Surg* 2005; **30**: 550-555 [PMID: [16055356](#) DOI: [10.1016/j.evs.2005.05.034](#)]
- 14 **Signorelli S**, Fiore V, Puccia G, Mastrosimone G, Anzaldi M. Thrombophilia in patients with lower limb deep vein thrombosis (LVDT) results of a monocentric survey on 103 consecutive outpatients. *Clin Appl Thromb Hemost* 2014; **20**: 589-593 [DOI: [10.1177/1076029612474716](#)]
- 15 **Endo M**, Jahangiri Y, Horikawa M, Kaufman JA, Schenning RC, Kolbeck KJ, Barton RE, Ohuchi Y, Liang KW, Farsad K. Antiplatelet Therapy is Associated with Stent Patency After Iliocaval Venous Stenting. *Cardiovasc Intervent Radiol* 2018; **41**: 1691-1698 [PMID: [30120531](#) DOI: [10.1007/s00270-018-2062-5](#)]



Published by **Baishideng Publishing Group Inc**  
7041 Koll Center Parkway, Suite 160, Pleasanton, CA 94566, USA

**Telephone:** +1-925-3991568

**E-mail:** [bpgoffice@wjgnet.com](mailto:bpgoffice@wjgnet.com)

**Help Desk:** <https://www.f6publishing.com/helpdesk>

<https://www.wjgnet.com>

