

SURGICAL VIDEO

Modified Banding of Arteriovenous Fistulas for the Treatment of Vascular Access Induced Digital Ischaemia[☆]

Yana Etkin^{a,*}, Jeffrey Silpe^a, Firas F. Mussa^a, Sonia Talathi^b, Melissa Garuthara^a, Gregg S. Landis^a

^aDivision of Vascular and Endovascular Surgery, Department of Surgery, Zucker School of Medicine at Hofstra/Northwell, Hempstead, NY, USA

^bDivision of Vascular Surgery, Department of Surgery, Montefiore Medical Centre, Bronx, NY, USA

Objective: Vascular access induced digital ischaemia is an uncommon complication of haemodialysis access procedures and is difficult to manage. Several techniques have been described to treat this phenomenon, with variable long term success. Although all of these procedures have been shown to work, they have a significant failure rate, such as persistent high vascular access flow or loss of access. One of the major technical limitations of these techniques is the lack of quantitative data gathered during the procedure to ensure treatment success. In this study, the aim was to describe a novel technique that can improve the success of banding in preserving access and eliminating digital ischaemia.

Technique: A modified method for arteriovenous fistula banding that incorporates measurements of distal arterial pressure to improve the success of the procedure is described.

Results: Sixteen patients with vascular access induced digital ischaemia and high-flow vascular access were treated using the technique. All procedures were technically successful. At 30 days, complete symptomatic relief (clinical success) was seen in 81% (n = 13) of patients. There was no access thrombosis or infection in any of the patients at the 30 day follow up. Six month follow up data were available in seven patients. There was no loss of access patency or recurrence of symptoms observed at six months.

Conclusion: This novel technique is simple and effective and can be used safely as first line therapy for the management of vascular access induced digital ischaemia.

© 2021 The Author(s). Published by Elsevier Ltd on behalf of European Society for Vascular Surgery. This is an open access article under the CC BY-NC-ND license (<http://creativecommons.org/licenses/by-nc-nd/4.0/>).

Article history: Received 14 April 2021, Revised 3 July 2021, Accepted 20 October 2021,

Keywords: Dialysis access, Fistula banding, Vascular access induced ischaemia

INTRODUCTION

An estimated 30 million Americans are affected by chronic kidney disease and approximately 500 000 patients are currently receiving maintenance haemodialysis treatments.¹ In 2003 the Fistula First Breakthrough Initiative was introduced by the Centers for Medicare & Medicaid Services (CMS) and End Stage Renal Disease (ESRD) Network with the goal of increasing the use of arteriovenous fistulas (AVF) for haemodialysis patients. Since this program was established, AVF use has increased from 33% in 2005 to 63% in 2018.^{1,2} As the number of patients undergoing dialysis access procedures increase, surgeons have to manage the concordant increase in access related complications.

Vascular access (VA) induced digital ischaemia after AVF creation is an uncommon complication but can have devastating consequences, including chronic pain, decreased sensation and motor function of the hand, as well as digital ischaemia and gangrene. Four stages of this spectrum of ischaemia have been defined: slight coldness and numbness with pale skin but no pain (stage 1); loss of sensation, pain during haemodialysis or exercise (stage 2); rest pain (stage 3); and tissue loss affecting the distal parts of the limb, usually the digits (stage 4).³

The degree of physiological steal depends on the level of fistula creation. The incidence of steal syndrome is higher with fistulas based on upper arm arterial inflow than forearm inflow.³

Symptomatic steal may develop in 10%–25% of brachiocephalic and basilic AVFs vs. 1%–1.8% of radiocephalic AVFs.⁴ Other risk factors include peripheral vascular disease, diabetes, age >60 years, sex (women > men), previous ipsilateral AVFs, and high flow AVFs.⁴

Several options for the management of VA induced ischaemia have been described, including banding, fistula ligation, distal radial artery ligation or embolisation, distal revascularisation interval ligation (DRIL), creation of a new

[☆] This study was presented in the plenary session as a video presentation at the 2019 Vascular Annual Meeting of the Society for Vascular Surgery, National Harbor, MD, June 12–15, 2019.

* Corresponding author. 1999 Marcus Ave, Suite 106B, Lake Success, NY 11042, USA.

E-mail address: yetkin@northwell.edu (Yana Etkin).

2666-688X/© 2021 The Author(s). Published by Elsevier Ltd on behalf of European Society for Vascular Surgery. This is an open access article under the CC BY-NC-ND license (<http://creativecommons.org/licenses/by-nc-nd/4.0/>).

<https://doi.org/10.1016/j.ejvsf.2021.10.017>

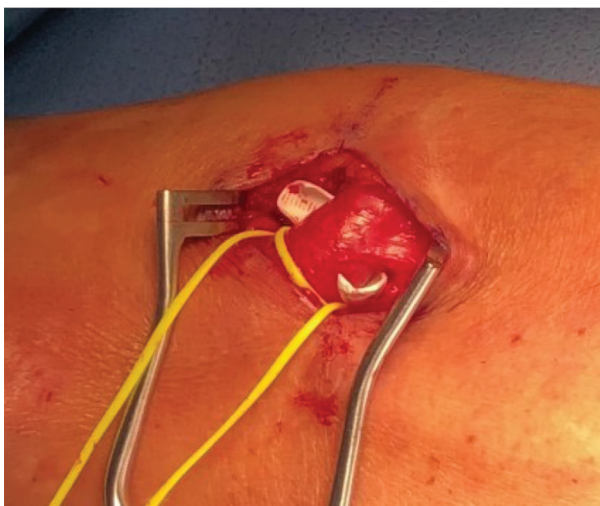

Figure 1. Polytetrafluoroethylene band is placed around a fistula.

proximal arteriovenous anastomosis (PAVA), and revision using distal inflow.³ Banding aims to increase the resistance in the fistula thereby diverting flow down the native artery. Although technically uncomplicated, banding procedures have previously been demonstrated to have lower rates of access preservation and higher rates of persistent symptoms.⁵ Intra-operative digital plethysmography or flow monitoring may increase the success of the banding procedure, and have been used with varying success.^{6,7}

In this study, the aim was to describe a novel technique that can improve the success of banding in preserving access and eliminating digital ischaemia.

TECHNIQUE

All procedures were performed in the operating room under local or regional anaesthesia. The fistula is exposed and circumferentially dissected just above the arteriovenous anastomosis. A 1–2 cm thick band is created using a polytetrafluoroethylene (PTFE) graft, which is placed around the venous outflow (Fig. 1). A 20 G angiocath is placed through the fistula into the distal arterial system. It is connected to a transducer in order to measure the arterial pressure in the hand, distal to the anastomosis (Fig. 2). The baseline arterial pressure in the hand is obtained and compared with the systemic blood pressure based on blood pressure cuff reading in the contralateral arm. The band is gradually constricted using Hemoclips (Teleflex Medical, Wayne, PA, USA) until the distal arterial pressure is raised as close as possible to the systolic blood pressure in the contralateral arm without occluding the fistula (Fig. 3). The goal is to raise the systolic pressure in the affected arm within 20 mmHg of the baseline systolic pressure measured in the contralateral arm. Polypropylene interrupted sutures are then placed above the Hemoclips to secure the band in place. The angiocath is then removed and access site is closed with a Prolene suture. The technical details of the procedure are demonstrated in the video provided.

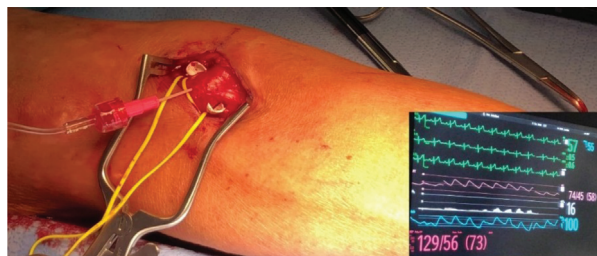


Figure 2. A 20 G angiocath is placed through the fistula into the distal arterial system and the arterial pressure is measured in the hand.

The Northwell Health Institutional Review Board approved this case series as minimal risk research using data collected for routine clinical practice and waived the requirement for informed consent.

RESULTS

Between January 2016 and December 2020, 16 patients with a mean \pm standard deviation (SD) age of 65 ± 16 years with VA induced ischaemia and high-flow vascular access were treated using this technique: eight patients with brachiocephalic, six with brachio basilic, and two with radiocephalic fistulas. Nine (56%) of patients were women, 15 (94%) had diabetes mellitus, and 7 (44%) had peripheral vascular disease. The mean \pm SD volume flow in the fistulas was $2\,400 \pm 1\,699$ mL/minute. All patients had stage 3 or stage 4 ischaemia. All procedures were technically successful and all AVFs were banded until desired pressure goals, as defined above, were obtained in the affected arm. The mean \pm SD systolic pressure in the effected arm before banding was 75 ± 26 mmHg and increased to 108 ± 20 mmHg after banding. A less than 20 mmHg difference was achieved between the systemic blood pressure and pressure in the effected arm in all of the cases while maintaining fistula patency.

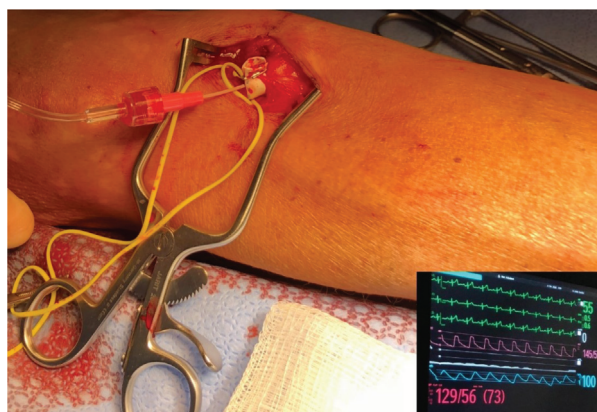


Figure 3. The band is constricted until the distal arterial pressure is raised as close as possible to the systolic blood pressure in the contralateral arm.

At 30 days, complete symptomatic relief (clinical success) was seen in 81% (n = 13) of patients. All six patients who initially presented with rest pain (stage 3 ischaemia) had resolution of symptoms. Of the 10 patients who presented with tissue necrosis (stage 4 ischaemia), seven had complete healing of their ulcers, and three had persistent ischaemia with digital gangrene. One of these patients was treated by fistula ligation and the other two underwent proximalisation of the arterial inflow (PAI). There was no access thrombosis or infection in any of the patients at the 30 day follow up. Three month follow up data were available in 12 patients and six month follow up data were available in seven patients. There was no loss of access patency or recurrence of symptoms observed at three or six months.

DISCUSSION

VA induced digital ischaemia occurs secondary to inflow arterial stenosis, a large arteriovenous anastomosis, and/or lack of vascular adaptation (increase in brachial artery flow rates) with creation of the AVF. The incidence of vascular access induced limb ischaemia is <1% in forearm fistulas and up to 5%–10% in upper arm fistulas.³ In the present cohort, 14 of 16 patients had an upper arm AVF, which are associated with increased risk of VA induced ischaemia vs. forearm fistulas. These patients also had the typical risk factors associated with VA induced ischaemia, including advanced age (>60 years), prevalence of diabetes and peripheral vascular disease, female sex, and high flow AVFs. This series therefore supports the existing literature, and even more so the notion that technically easy and effective procedures should exist to treat this complication.

Several treatment options have been described previously. Dialysis access AVF banding was first described in the 1970s,⁸ and the technical aspects of this procedure continue to improve. Based on the literature, banding has been associated with increased loss of access and more complications relative to other methods used to treat VA induced ischaemia. In one retrospective review, banding had a 30 day complication rate of 47% (33% continued steal, 11% thrombosis, and 2.8% infection).⁵ Thirty day complication rates of ligation, DRIL, revision using distal inflow, PAI, and distal radial artery ligation were 8.2%, 7.1%, 37%, 44%, and 0%, respectively.⁵ Several technical methods for banding have been described, including, but not limited to, the minimally invasive limited ligation endoluminal assisted revision (MILLER) technique,⁹ T banding,¹⁰ use of intra-operative flow monitoring,^{3,8} and photoplethysmography.⁶ Various clinical success rates have been described with these procedures, ranging from 89% with the MILLER technique to 72% with T banding.^{9,10}

The presented novel technique is simple and effective. Banding is a minimally invasive revascularisation technique and it can be used safely as first line therapy. It is an acceptable method to reduce flow in high flow induced steal with VA induced ischaemia according to the European Society for Vascular Surgery 2018 Vascular Access

guidelines.³ This technique worked well in the present cohort as the mean vascular access flow was >2 000 mL/minute. However, in patients with diseased arterial inflow and reduced flow in their access (<600 mL/minute), banding would not be a useful technique and other treatment options such as proximalisation of inflow, DRIL or access ligation should be considered.³ The authors use a PTFE band because it is less stretchable than suture plication or using other materials, such as a pericardial patch or Dacron graft, making it a more durable repair. The demonstration of success in 13 of 16 patients contrasts with previous findings of increased complications. This may be the result of invasive monitoring during the procedure, which aids in creating the band based on the quantitative data, rather than visual estimation of vein size.

Limitations to this case series include the small sample size, lack of direct comparison between the technique and other intra-operative monitoring, and the relatively short duration of follow up. Unfortunately, dialysis access patients are notorious for poor follow up and the population in this case series demonstrated the same pattern, with <50% having follow up at six months. Further studies comparing this method with traditional banding techniques with a longer follow up should be done to ensure a clinically meaningful improvement.

CONCLUSION

This novel method for AVF banding in patients suffering from stage 3 and stage 4 VA induced ischaemia can be useful for future management of this uncommon but serious complication. It provides objective intra-operative physiological data that serve as a helpful adjunct to standard banding techniques. This novel technique is simple and effective and can be used safely as a first line therapy for the management of VA induced ischaemia.

APPENDIX A. SUPPLEMENTARY DATA

Supplementary data to this article can be found online at <https://doi.org/10.1016/j.ejvsf.2021.10.017>.

REFERENCES

- 1 United States Renal Data System. *2019 USRDS Annual Data Report: Epidemiology of kidney disease in the United States*. Bethesda, MD: National Institutes of Health, National Institute of Diabetes and Digestive and Kidney Diseases; 2019.
- 2 Lee T. Fistula First Initiative: historical impact on vascular access practice patterns and influence on future vascular access care. *Cardiovasc Eng Technol* 2017;**83**:244–54.
- 3 Schmidli J, Widmer MK, Basile C, de Donato G, Gallieni M, Gibbons CP, et al. Vascular access: 2018 clinical practice guidelines of the European Society for Vascular Surgery (ESVS). *Eur J Vasc Endovasc Surg* 2018;**55**:757–818.
- 4 Tordoir JHM, Dammers R, Van der Sande FM. Upper extremity ischemia and hemodialysis vascular access. *Eur J Vasc Endovasc Surg* 2004;**27**:1–5.
- 5 Leake AE, Winger DG, Leers SA, Gupta N, Dillavou ED. Management and outcomes of dialysis access-associated steal syndrome. *J Vasc Surg* 2015;**61**:754–61.

- 6 Odland MD, Kelly PH, Ney AL, Andersen RC, Bubrick MP. Management of dialysis-associated steal syndrome complicating upper extremity arteriovenous fistulas: use of intraoperative digital photoplethysmography. *Surgery* 1991;**110**:664–9.
- 7 Zanow J, Petzold K, Petzold M, Krueger U, Scholz H. Flow reduction in high-flow arteriovenous access using intraoperative flow monitoring. *J Vasc Surg* 2006;**44**:1273–8.
- 8 Fee HJ, Golding AL. Lower extremity ischemia after femoral arteriovenous bovine shunts. *Ann Surg* 1978;**183**:42–5.
- 9 Miller GA, Goel N, Friedman A, Khariton A, Jotwani MC, Savransky Y, et al. The MILLER banding procedure is an effective method for treating dialysis-associated steal syndrome. *Kidney Int* 2010;**77**:359–66.
- 10 Schneider CG, Gawad KA, Strate T, Pfalzer B, Izbicki JR. T-banding: a technique for flow reduction of a hyperfunctioning arteriovenous fistula. *J Vasc Surg* 2006;**43**:402–5.