



# Drug-eluting balloon (DEB) versus plain old balloon angioplasty (POBA) in the treatment of failing dialysis access: A prospective randomized trial

Torbjörn Fransson<sup>1,6</sup> , Anders Gottsäter<sup>2,6</sup> ,  
Mohammad Abdulrasak<sup>2,6</sup>, Martin Malina<sup>3</sup> and  
Timothy Resch<sup>4,5</sup>

## Abstract

**Objective:** To compare the efficacy of angioplasty using drug-eluting balloons (DEB) compared with plain old balloon angioplasty (POBA) to reduce the rate of restenosis.

**Methods:** This prospective, single-centre, single-blinded, 1:1 randomized, clinical trial enrolled patients that had primary or restenotic lesions in native upper extremity arteriovenous (AV) fistulas or at the graft-venous anastomosis. Patients were randomized to angioplasty with a POBA or a DEB. The primary effectiveness endpoints were freedom from target lesion revascularization (TLR) and functional status of access circuit at 12 months.

**Results:** A total of 42 (28 male, 14 female; age range, 42–83 years) patients were enrolled. Patients were followed for 12 months. No significant differences were detected between the POBA and DEB groups regarding total number of TLR procedures (31 versus 36, respectively), freedom from TLR (3 versus 4, respectively) and functional status of the access circuit at 12 months (14 of 20 patients [70%] versus 17 of 22 patients [77%], respectively).

**Conclusion:** This clinical trial did not demonstrate any significant differences between DEB angioplasty and standard balloon angioplasty when treating dysfunctional haemodialysis access.

<sup>1</sup>Department of Thoracic and Vascular Surgery, Skåne University Hospital, Malmö, Sweden

<sup>2</sup>Department of Internal Medicine, Skåne University Hospital, Malmö, Sweden

<sup>3</sup>West London Vascular and Interventional Centre, Northwick Park University Hospital, Harrow, UK

<sup>4</sup>Department of Vascular Surgery, Rigshospitalet, Copenhagen, Denmark

<sup>5</sup>Department of Clinical Medicine, Faculty of Health and Medical Sciences, University of Copenhagen, Denmark

<sup>6</sup>Department of Clinical Sciences, Faculty of Medicine, Lund University, Malmö, Sweden

## Corresponding author:

Torbjörn Fransson, Department of Thoracic and Vascular Surgery, Skåne University Hospital, Ruth Lundskogs gata 10, 205 02 Malmö, Sweden.

Email: torbjorn.fransson@med.lu.se



## Keywords

Drug-eluting balloon, angioplasty, haemodialysis, stenosis, paclitaxel, arteriovenous fistula

Date received: 24 August 2021; accepted: 2 February 2022

## Introduction

In accordance with the Kidney Disease Outcomes Quality Initiative guidelines, patients in haemodialysis care frequently receive an upper extremity arteriovenous (AV) fistula or graft,<sup>1–3</sup> in conjunction with the idea of choosing the ‘right access at the right time for the right patient’. With continuous regular use, these circuits will develop significant stenosis.<sup>4,5</sup> Stenoses of AV fistulas and grafts are a common problem that often compromise optimal dialysis. Haemodialysis patients are usually intensely monitored and when a malfunction of the access is noticed, further investigations and interventions are undertaken. Currently, the standard treatment is balloon angioplasty with standard, or often, high-pressure balloons.<sup>1</sup> Unfortunately, there are limitations with this treatment because primary patency is limited and the rate of restenosis is high.<sup>6–12</sup> Studies show an approximate 50% reintervention rate within 6 months with plain old balloon angioplasty (POBA).<sup>6,8,10,13–15</sup> One option that may reduce the number of repeat angioplasties and extend treatment intervals is to use drug-eluting balloons (DEB). These balloons are coated with an antiproliferative drug, paclitaxel; and have documented effects on reducing the rate of restenosis when treatments are performed in other vascular territories.<sup>16–26</sup> Two randomized clinical trials,<sup>27,28</sup> as well as many smaller series,<sup>29–49</sup> have been published on this topic reporting conflicting results. Whereas treatment is considered safe,<sup>27,50,51</sup> some studies have shown positive effects on

primary patency and reduced number of reinterventions,<sup>27,31,33,35–37,39,40,45,47,52</sup> whereas others have not.<sup>28,29,32,41,44,53,54</sup>

This prospective randomized clinical trial compared the efficacy of angioplasty using DEB compared with POBA to reduce the rate of restenosis in patients that had primary or restenotic lesions in native upper extremity AV fistulas or at the graft-venous anastomosis.

## Patients and methods

### Study population

This prospective, single-centre, single-blinded, 1:1 randomized, clinical trial, evaluated angioplasty with an Advance<sup>®</sup> 18 PTX Drug-Eluting PTA Balloon Dilatation Catheter (paclitaxel-coated balloon; Cook Medical, Bloomington, IN, USA) compared with an Advance<sup>®</sup> 18LP – Low Profile PTA Balloon Dilatation Catheter (identical, non-coated, standard balloon; Cook Medical). The study enrolled patients in the Department of Thoracic and Vascular Surgery, Skåne University Hospital, Malmö, Sweden between March 2014 and July 2017. The inclusion criteria were as follows: (i) adult >18 years; (ii) active dialysis with mature upper extremity dysfunctional haemodialysis access; (iii) primary stenosis or nonstented restenosis in a native AV fistula or at graft-venous location; (iv) target vessel diameter 3–8 mm. The exclusion criteria were as follows: (i) thrombosed access; (ii) in-stent restenosis; (iii) pregnancy; (iv) ≤18 years.

The study participants were treated with percutaneous transluminal angioplasty (PTA) using the study balloon as described below.

The trial protocol was approved by the regional research ethics committee in Lund, Sweden (Dnr: 2012/305). In error, the trial was not prospectively registered, but has been registered retrospectively at ClinicalTrials.gov (registration no. NCT05173857). The trial was conducted in accordance with the Declaration of Helsinki and all participants provided written informed consent. The reporting of this study conforms with the CONSORT statements.<sup>55</sup>

### ***Definition of dysfunctional access***

Dysfunctional access was defined in two ways in this study. First, clinically-evident dysfunctions that occur when there are repeated problems with performing the haemodialysis procedure. The reasons for this type of dysfunctional access can be multifactorial including inflow problems, with low flow and corresponding low quality (k/tV) dialysis and recirculation, or outflow problems, with high venous pressures and corresponding prolonged bleeding times at the end of the haemodialysis session. Some circuits also have additional problems with accessing the circuits or leakage. It is not uncommon for this type of dysfunction to result from a combination of problems. Secondly, there was an option for treatment as defined by a possible pre-emptive strategy, i.e. 'physiological' or 'subclinical' malfunction. In these circumstances, circuits did not display any clinical problems, but were identified by large access flow reductions (>50%), i.e. reductions in the volume flow between two consecutive registrations. Some patients with flow reductions, approaching the 'low flow window' and at risk for thrombosis (<500 ml/min), were

also further investigated with duplex ultrasonography as described below.

All patients identified as having dysfunctional circuits were examined with duplex ultrasonography (Philips iU22 system; Philips Healthcare B.V, Best, the Netherlands) so that significant stenoses (>50%) could be detected before any endovascular treatment was scheduled. An access circuit stenosis was judged significant if >50% binary stenosis was subsequently detected on the actual angiogram (Siemens ArtisQ; Siemens Healthcare GmbH, Erlangen, Germany). Access circuit extension was defined from the juxta-anastomotic arterial inflow to the axillary vein outflow before the thoracic outlet region.

### ***Randomization procedure***

Trial participants were randomized in a 1:1 ratio using a blinded envelope method (POBA or DEB) in two blocks of 25 + 25 tickets. The patients were randomized in blocks to compensate for inclusion skewness if the study inclusion was extended over time. The staff at the angiographic suite performed this randomization procedure after the lesion was crossed with a guidewire. Only the treating physician and staff, not the patients, were aware of the choice of treatment (i.e. single-blinded).

### ***PTA procedure***

The lesion was crossed with a guidewire and then after randomization the lesion underwent a direct dilatation with one of the study balloons. The balloon was matched to the reference vessel diameter in an approximate 1:1 sizing. Inflation time was set to 90 s. If the primary dilatation was judged unsuccessful, further treatment was initiated at the discretion of the operator. In the case of multiple stenoses in the circuit, all of the stenoses received the same

treatment according to the patient's study allocation. On the rare occurrence of a long lesion, when more than one angioplasty balloon was used, the trial protocol emphasized the importance of adequate dilatation and treatment of the overlapping regions and minimization of the risk for skipping regions, in order to optimize drug delivery.

### **Follow-up procedure**

The prespecified trial protocol dictated a follow-up period of 12 months. At the haemodialysis unit, monthly recordings of volume flow (Transonic HD03 Hemodialysis Monitor; Transonic Systems Inc., Ithaca, NY, USA) were undertaken as part of routine care. If large flow reductions were noticed (i.e. >50% as prespecified), a duplex ultrasound examination was performed (Philips iU22 system; Philips Healthcare). Ultrasound was also performed when clinical haemodialysis access related problems were detected regardless of volume flow measurements. When duplex ultrasound indicated a significant stenosis or restenosis, corresponding to clinical or functional issues, the patient was scheduled for a new endovascular procedure. No regularly timed prespecified investigations were performed, other than volume flow measurements, as was the standard clinical practice.

### **Primary and secondary endpoints**

The prespecified primary endpoints were as follows: (i) freedom from target lesion revascularization (TLR) at 6 and 12 months; (ii) freedom from access circuit revascularization at 6 and 12 months; (iii) functional access at 12 months. The prespecified secondary endpoints were as follows: (i) time to first TLR; (ii) survival at 12 months; (iii) procedural- and access-related complications; (iv) procedural technical performance. Endpoint censorship occurred in following situations: (i) deceased patient;

(ii) access thrombosis; (iii) surgically ligated access after placement of a new access or a change of renal replacement strategy, i.e. usually a kidney transplant.

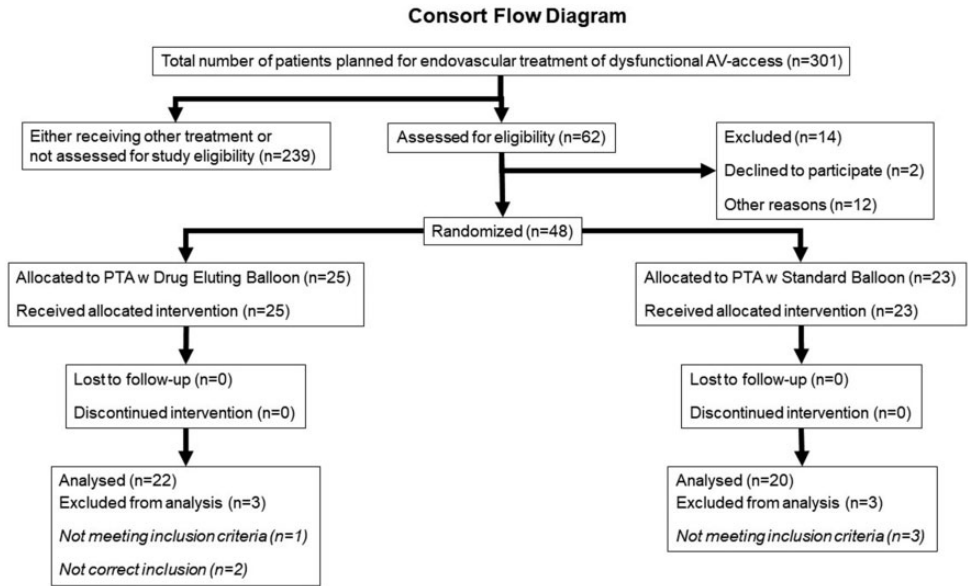
### **Statistical analyses**

The initial null hypothesis was that PTA with DEB performed at least 50% better than PTA with POBA, regarding primary patency and freedom from reintervention during 12 months of follow-up. This calculation specified an alpha level of 5% and a power of 90% to show clinical superiority. The prespecified enrolment was set to 50 patients in each group according to pre-trial calculations. At the time of the trial set up, previous research was investigated to provide an idea of a reasonable cut-off value regarding efficacy.<sup>52</sup>

All statistical analyses were performed using IBM SPSS Statistics for Windows, Version 25.0 (IBM Corp., Armonk, NY, USA). Normal distribution was not assumed. Continuous data are presented at median (interquartile range) and compared using Mann–Whitney *U*-test. Categorical data are presented as *n* of patients (%) and compared using  $\chi^2$ -test and Fisher's exact test. Kaplan–Meier survival curves were used to present time-to-event data and any differences compared with log-rank test. The survival data are presented with values  $\pm$  standard error in %. A *P*-value <0.05 was considered statistically significant.

### **Results**

A total of 42 patients (28 male, 14 female; age range, 42–83 years) were included in the trial (Figure 1). The inclusion period lasted for 40 months and during this time 301 patients in total were treated for dysfunctional haemodialysis access with an endovascular method. For different reasons, mostly administrative shortcomings,



**Figure 1.** Flow diagram showing the progress through enrolment, randomization and analysis of patients that underwent percutaneous transluminal angioplasty (PTA) with plain old balloon angioplasty or drug-eluting balloon. AV, arteriovenous.

14 patients had signed written informed consent but failed inclusion on the day of the intervention. Two patients were included twice and only the primary inclusion was ratified in the post-trial analysis. Four patients were actually treated for outflow in-stent restenosis and were excluded from the post-trial analysis according to the study protocol. Of the 42 patients finally included in the trial, 22 patients were assigned to treatment with a DEB and 20 with a POBA. All treatments were performed at the same institution. The baseline demographic and clinical characteristics of the study population are shown in Table 1. Other than the side of access ( $P=0.041$ ), there were no significant differences between the two groups in terms of age, sex, medical comorbidities, access circuit history and use of antiplatelet/anticoagulant drugs before or after the index intervention. The majority of patients in both groups had a previous endovascular

treatment for a dysfunctional AV fistula (17 of 20 patients [85%] in the POBA group versus 17 of 22 patients [77%] in the DEB group).

With regard to AV fistula and lesion characteristics (Table 2), there were no significant differences between the two groups, although there were three dialysis grafts included in total, all in the POBA group. There was a small difference, although not significant, regarding lesion location, with more proximal vein lesions in the DEB group compared with the POBA group. There was also a higher frequency of lower arm fistulas in the DEB group, although this was not significant. The median lesion length was similar in the POBA and DEB groups (46 mm versus 36 mm, respectively). The need for procedural complementary retreatment with high pressure balloon or standard PTA was similar in both groups; and 13 of 20 patients (65%) in the POBA group versus

**Table 1.** Baseline demographic and clinical characteristics of patients ( $n = 42$ ) that underwent percutaneous transluminal angioplasty with plain old balloon angioplasty (POBA) or drug-eluting balloon (DEB).

Characteristic	POBA $n = 20$	DEB $n = 22$
Age, years	62 (57–77)	68 (59–76)
Sex, male	13 (65)	15 (68)
Diabetes mellitus	9 (45)	11 (50)
Hyperlipidaemia	13 (65)	12 (55)
Hypertension	16 (80)	17 (77)
Cardiovascular disease, cardiac or cerebral	11 (55)	8 (36)
First access	11 (55)	17 (77)
Previous endovascular treatment	17 (85)	17 (77)
Median number of previous endovascular treatments	2 (1–6)	2 (1–8)
Previous surgical treatment	2 (10)	2 (9)
Side of access, left	13 (65)	20 (91)*
Old access, >24 months	9 (45)	11 (50)
Antiplatelet therapy, aspirin	12 (60)	12 (55)
Anticoagulant therapy	1 (5.0)	2 (9)

Data presented as median (interquartile range) or  $n$  of patients (%).

\* $P = 0.041$  between-group comparison; all other between-group comparisons were not significant ( $P \geq 0.05$ ); continuous data were compared using Mann–Whitney  $U$ -test and categorical data were compared using  $\chi^2$ -test and Fisher's exact test.

**Table 2.** Arteriovenous (AV) fistula and lesion characteristics of patients ( $n = 42$ ) that underwent percutaneous transluminal angioplasty (PTA) with plain old balloon angioplasty (POBA) or drug-eluting balloon (DEB).

	POBA $n = 20$	DEB $n = 22$
Graft	3 (15)	0 (0)
Proximal vein fistula	7 (35)	5 (23)
Distal vein fistula	10 (50)	17 (77)
Clinical inflow dysfunction	3 (15)	5 (23)
Clinical outflow dysfunction	3 (15)	3 (14)
Reduction of volume flow >50%	4 (20)	4 (18)
Other access related problems, not classified as inflow or outflow dysfunction	10 (50)	11 (50)
Proximal vein lesion	7 (35)	14 (64)
Puncture zone lesion	6 (30)	8 (36)
AV anastomosis lesion	7 (35)	12 (55)
Graft-venous lesion	3 (15)	0 (0)
Venous outflow lesion	9 (45)	8 (36)
Venous outflow treated	8 (40)	6 (27)
Arterial inflow treated	2 (10)	3 (14)
Post-PTA treatment	11 (55)	11 (50)
High pressure balloon angioplasty	3 (15)	3 (14)
Total lesion length, mm	46 (24–81)	36 (31–62)

Data presented as median (interquartile range) or  $n$  of patients (%).

No between group comparisons were significant ( $P \geq 0.05$ ); continuous data were compared using Mann–Whitney  $U$ -test and categorical data were compared using  $\chi^2$ -test and Fisher's exact test.

13 of 22 (59%) patients in the DEB group received this adjunctive treatment. One patient in the DEB group received a rescue stent for suboptimal angioplasty and this circuit were later surgically ligated due to arm oedema.

The median size of the angioplasty balloon was 6 mm in both groups (Table 3). The maximal percentage stenosis pretreatment and post-treatment were similar in both groups. The clinical procedural success was 100% in both groups, while the corresponding radiological procedural success was rated lower, but not significantly different between the POBA and DEB groups (11 of 20 patients [55%] versus 15 of 22 patients [68%], respectively).

Nine patients in total had multiple, separate stenoses in the access circuit and all stenoses received the same allocated treatment. Five patients received treatment with DEB and four patients with POBA. In total, 53 stenoses were treated. Regarding these 53 locations, no significant differences in TLR procedures were noted (17 of 25 lesions [68%] in the POBA group versus 17 of 28 lesions [61%] in the DEB group).

No patients were lost to follow-up. Flow measurement data were partially incomplete in 19 patients. One patient suffered a

thrombosed access in the follow-up period, without successful treatment, and consequently there were no secondary patent circuits.

In terms of the primary endpoints, there were no significant differences regarding freedom from TLR or access circuit primary patency at 12 months between the two groups (Table 4) (Figures 2 and 3). The proportion of patients with functional access at 12 months was similar between the two groups. Two circuits were lost, one in each group.

In terms of the secondary endpoints, the median time to TLR was similar in both groups (Table 4). There were no access-related serious adverse events and no difference in mortality at 12 months between the two groups. The median number of interventions and the number of TLR-specific interventions were similar in both groups.

## Discussion

This current prospective, single-blinded, randomized clinical trial detected no significant differences between DEB and standard POBA in the treatment of dysfunctional haemodialysis circuits. Superior primary patency, longer retreatment intervals or a higher

**Table 3.** Arteriovenous fistula treatment characteristics of patients ( $n = 42$ ) that underwent percutaneous transluminal angioplasty with plain old balloon angioplasty (POBA) or drug-eluting balloon (DEB).

	POBA $n = 20$	DEB $n = 22$
Technical procedural success	20 (100)	22 (100)
Radiological procedural success	11 (55)	15 (68)
Pretreatment maximal stenosis, outflow reference <sup>a</sup>	70 (55–80)	71 (48–79)
Pretreatment maximal stenosis, inflow reference <sup>a</sup>	61 (50–68)	59 (50–70)
Post-treatment maximal stenosis, outflow reference <sup>a</sup>	43 (29–60)	44 (28–56)
Post-treatment maximal stenosis, inflow reference <sup>a</sup>	30 (8–42)	17 (0–25)
Treatment balloon diameter, mm	6 (5–7)	6 (5–7)

Data presented as median (interquartile range) or  $n$  of patients (%).

<sup>a</sup>Calculation was undertaken with both outflow and inflow access diameter as baseline reference.

No between group comparisons were significant ( $P \geq 0.05$ ); continuous data were compared using Mann–Whitney  $U$ -test and categorical data were compared using  $\chi^2$ -test and Fisher's exact test.

**Table 4.** Primary and secondary endpoints of patients ( $n = 42$ ) that underwent percutaneous transluminal angioplasty with plain old balloon angioplasty (POBA) or drug-eluting balloon (DEB).

	POBA $n = 20$	DEB $n = 22$
Mortality at 12 months	2 (10)	3 (14)
Access-related serious adverse event at 12 months	0 (0)	0 (0)
Access circuit thrombosis at 12 months	1 (5)	0 (0)
Any access-related complication at 12 months	4 (20)	1 (5)
Freedom from TLR at 12 months <sup>a</sup>	3 (16 ± 9)	4 (24 ± 10)
Freedom from TLR at 6 months <sup>a</sup>	10 (54 ± 11)	10 (48 ± 11)
Access circuit primary patency at 12 months <sup>a</sup>	2 (11 ± 7)	4 (24 ± 10)
Access circuit primary patency at 6 months <sup>a</sup>	8 (44 ± 11)	10 (48 ± 11)
Functional access at 12 months	14 (70)	17 (77)
Number of TLR interventions at 12 months	1 (1–2)	1 (0–3)
Number of access circuit interventions at 12 months	2 (1–3)	2 (1–3)
Time to first TLR, days	125 (57–261)	140 (6–294)
Number of duplex scans at 12 months	3 (1–5)	3 (1–5)

Data presented as median (interquartile range) or  $n$  of patients (%).

<sup>a</sup>Life table data are presented with numbers and (% ± SE).

No between group comparisons were significant ( $P \geq 0.05$ ); continuous data were compared using Mann–Whitney  $U$ -test and categorical data were compared using  $\chi^2$ -test and Fisher's exact test.

TLR, target lesion revascularization.

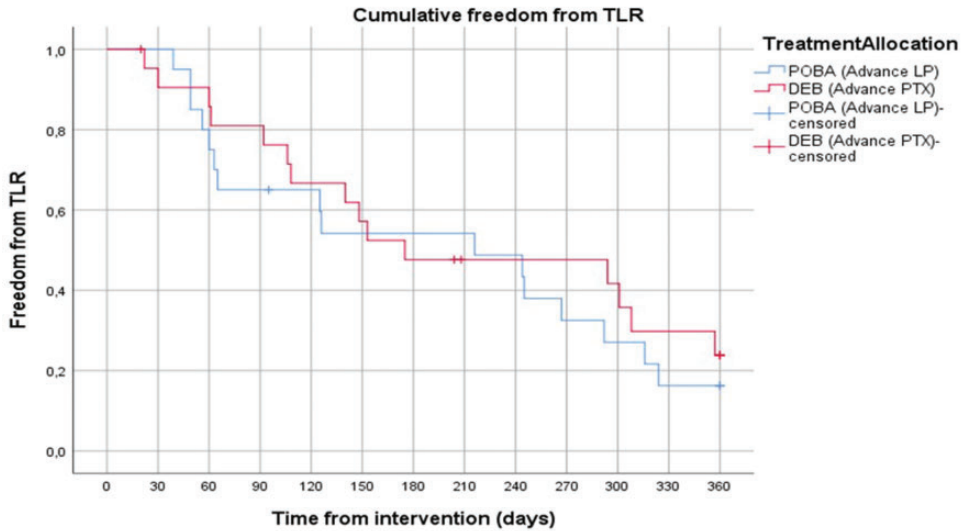
degree of freedom from TLR were not demonstrated when using drug-eluting technology.

The benefits of deposition of antiproliferative drugs (in this case paclitaxel) in certain angioplasty settings have been described for some time. For example, there is a considerable amount of scientific evidence supporting a possible anti-restenotic effect in various vascular territories.<sup>16–26,28,30,31,33,35–47,49,56</sup> However, these procedures have not been fully adopted as standard care and safety issues have been discussed in recent years.<sup>57</sup> In particular, a meta-analysis from 2018 suggested an increase in late mortality in the cohort receiving drug-eluting therapy, so the use of this technology was heavily questioned.<sup>57</sup> Mortality differences have not been evident in more recent publications on the use of antiproliferative drugs in the endovascular treatment of surgery-created arteriovenous fistulas.<sup>27,50</sup> A similar safety conclusion was drawn from a recent

publication from the SWEDEPAD registry, which evaluated patients treated for lower limb ischaemia with drug-eluting devices.<sup>51</sup> Drug-eluting treatment is currently considered to be safe in terms of late mortality issues.<sup>27,50,51</sup>

Regarding the local anti-restenotic effects after endovascular treatment of haemodialysis access, publications to date have shown conflicting results.<sup>8,27,29,31–33,35–37,39–41,44,45,47,52–54</sup> No definite signs of superior efficacy were demonstrated for a long period of time.<sup>8,29,32,41,44,53,54</sup> The recent large IN.PACT AV Access multicentre randomized trial showed significantly better target lesion primary patency at 6 months when patients were treated with drug-eluting balloon angioplasty.<sup>27</sup> These results represent an important advance in the field of endovascular treatment of dysfunctional AV fistulas.<sup>27</sup> When analysing subgroups at 2 years in the randomized Lutonix AV trial, there was an observed positive effect with significantly longer retreatment intervals





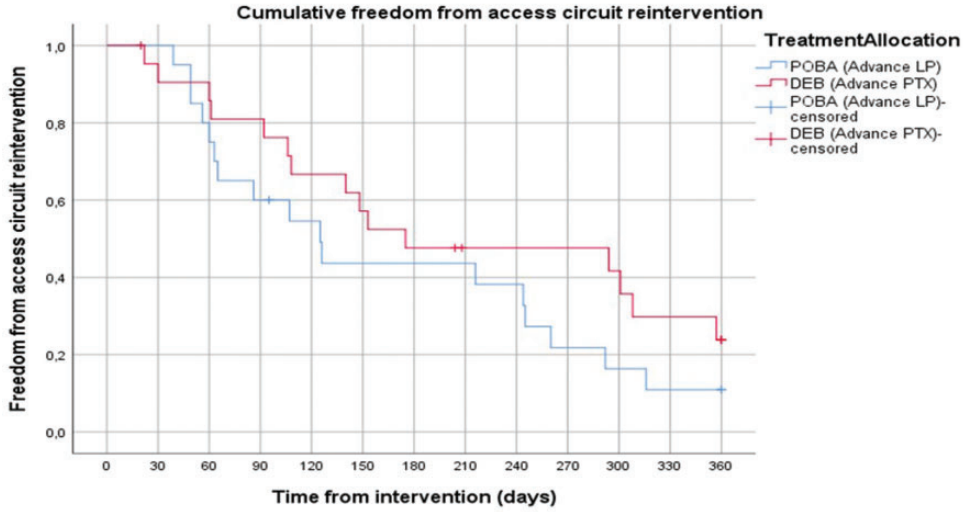
	1 months	3 months	6 months	9 months	12 months
POBA	20 (100 ± 0)	13 (65 ± 11)	10 (54 ± 11)	9 (33 ± 11)	3 (16 ± 9)
DEB	20 (95 ± 5)	17 (81 ± 9)	10 (48 ± 11)	8 (48 ± 11)	4 (24 ± 10)
	<i>P</i> = 0.49	<i>P</i> = 0.50	<i>P</i> = 1.00	<i>P</i> = 0.75	<i>P</i> = 1.00

**Figure 2.** Kaplan–Meier curve analysis showing cumulative freedom from target lesion revascularization (TLR) in patients ( $n = 42$ ) that underwent percutaneous transluminal angioplasty (PTA) with plain old balloon angioplasty (POBA) or drug-eluting balloon (DEB). The corresponding table presents the number of patients at risk ( $\% \pm \text{SE}$ ) at certain time-points and *P*-values for each time-point. The colour version of this figure is available at: <http://imr.sagepub.com>.

when using DEB.<sup>28</sup> Despite this, the trial failed to reach its primary endpoint of a superior target lesion primary patency at 6 and 24 months for DEB, although superiority could be shown at 9 and 12 months.<sup>28</sup> The recently published multicentre prospective randomized PAVE study, which enrolled 212 patients, did not show any difference between standard treatment with POBA and DEB angioplasty when treating dysfunctional AV access.<sup>58</sup>

There were no significant differences in the baseline demographic and clinical characteristics between the two groups in the current study. Although there was a significantly higher proportion of patients with AV fistulas on the left arm in the DEB

group compared with the POBA group, there was no obvious theoretical explanation for this difference and it was presumably the result of pure chance. There was a small difference, although not significant, regarding lesion location, with proximal vein lesions being more frequent in the DEB group compared with the POBA group. Based on this difference and in conjunction with the limited number of patients enrolled, it could be argued that those in the DEB group had a worse outcome as shown by a previous study.<sup>59</sup> This aforementioned study showed that the location of the main treated lesion close to the arteriovenous anastomosis may be a predictor of poorer long-term patency.<sup>59</sup> A higher frequency of



	1 months	3 months	6 months	9 months	12 months
POBA	20 (100 ± 0)	12 (60 ± 11)	8 (44 ± 11)	4 (22 ± 10)	2 (11 ± 7)
DEB	20 (95 ± 5)	17 (81 ± 9)	10 (48 ± 11)	8 (48 ± 11)	4 (24 ± 10)
	<i>P</i> = 0.49	<i>P</i> = 0.32	<i>P</i> = 0.76	<i>P</i> = 0.31	<i>P</i> = 0.66

**Figure 3.** Kaplan–Meier curve analysis showing cumulative freedom from access circuit reintervention in patients (*n* = 42) that underwent percutaneous transluminal angioplasty (PTA) with plain old balloon angioplasty (POBA) or drug-eluting balloon (DEB). The corresponding table presents the number of patients at risk (% ± SE) at certain time-points and *P*-values for each time-point. The colour version of this figure is available at: <http://imr.sagepub.com>.

lower arm fistulas in the DEB group, although not significant, may have an implication on the interpretation of data due the limited number of patients.

There have been similar, small, randomized studies regarding AV fistulas treated with DEB or POBA that did not show any differences in TLR or patency,<sup>32,41,60</sup> as shown in the current study. In contrast, there are also similar small studies that demonstrated significant differences between the two groups.<sup>14,36,38</sup> A retrospective study from our institution in 2014 that analysed 159 patients treated between 2008–2009 reported a primary patency after standard PTA of 61% at 6 months and 42% at 12 months.<sup>6</sup>In comparison with this, the overall effect of PTA in the

current study was inferior at 12 months, with an overall primary patency rate of 14% (six of 42 patients). These current findings were at the lower end of the wide range of results from similar studies presenting POBA primary patency rates of 5–55% at 12 months.<sup>8,31,33,37,39–41,45</sup>

The radiological success shown in the current study was not optimal although similar in both groups. The reason is that the post-interventional analysis with detailed measurements was sometimes not performed in line with the procedure. When viewing all of the images in the post-trial analysis, some of the treated stenoses, judged and treated correctly at the intervention, still had low grade residual stenoses (>30%). The figures based on the

more relevant inflow reference diameters showed median (interquartile range) residual stenosis values of 30% (8–42) in POBA versus 17% (0–25) in DEB.<sup>8–42</sup> There were not enough patients to perform a relevant subgroup analysis regarding this issue.

This current study had several limitations. First, the heterogeneity regarding lesion location might have caused potential bias, but this could not be significantly shown with the limited number of study patients. Secondly, the technical procedure protocol with direct angioplasty might be a possible mechanism for suboptimal DEB results. The standard procedure currently implements a strategy with predilatation and vessel preparation, with the frequent use of high-pressure balloons, before drug delivery. The reasons for treatment with direct angioplasty in the current trial was the limited scientific knowledge concerning DEB performance at the time of the study initiation and the intention to simplify treatment as much as possible. This study was planned in the early era of drug-eluting angioplasty for dysfunctional haemodialysis access, and at that time, complete knowledge regarding the technical performance of these new balloons had not been established. In this situation, the current study opted for a strategy with direct PTA because study protocols with similar features were being used in ongoing studies at the time.<sup>33,38,56,61,62</sup> In the end, most patients in the current study received post-treatment angioplasty due to suboptimal primary PTA, with another standard PTA balloon or high-pressure PTA balloon, at the discretion of the performing interventionalist. Consequently, 13 of 20 patients (65%) in the POBA group versus 13 of 22 (59%) patients in the DEB group got this adjunctive treatment to finally receive a good clinical angioplasty result. Thirdly, a considerable number of AV fistula treatments were performed outside of the study

protocol during the trial's extended time-frame. All of these factors could introduce potential bias, although obvious signs of such systemic bias could not be detected in the post-trial analysis. Finally, the study became underpowered as it was stopped before the planned inclusions were achieved, making investigation of the pretrial hypothesis suboptimal. The reason for stopping the trial was a slow inclusion rate and a company-initiated withdrawal of the product from the market for financial and company-related structural reasons. There were no safety or efficacy issues behind this decision. There are other similar studies that have shown significant differences in treatment efficacy with a similar number of randomized participants.<sup>52</sup> Although the study product was withdrawn, the active substance (paclitaxel) is still widely used in the clinic for the treatment of both dysfunctional haemodialysis fistulas and lesions in other vascular territories.

In conclusion, this current randomized trial demonstrated no clinically significant advantages with DEB angioplasty compared with POBA when treating stenoses in dysfunctional upper extremity AV fistulas.


### **Declaration of conflicting interest**

The authors declare that there are no conflicts of interest.

### **Funding**

The authors disclosed receipt of the following financial support for the research, authorship, and publication of this article: The trial was conducted with limited unrestricted support from Cook Medical, Bloomington, IN, USA. With this agreement, treatment with DEB was cost neutral compared with standard care. The trial was initiated and conducted regarding design, follow-up, performance, data analysis and manuscript preparation solely by the investigators. The authors and the corresponding institution are solely responsible for data collection and interpretation.

**ORCID iDs**

Torbjörn Fransson  <https://orcid.org/0000-0001-6479-4733>

Anders Gottsäter  <https://orcid.org/0000-0003-0865-0000>

**References**

1. Lok CE and Moist L. KDOQI 2019 Vascular Access Guidelines: What Is New? *Adv Chronic Kidney Dis* 2020; 27: 171–176.
2. Wasse H. Catheter-related mortality among ESRD patients. *Semin Dial* 2008; 21: 547–549.
3. Ravani P, Palmer SC, Oliver MJ, et al. Associations between hemodialysis access type and clinical outcomes: a systematic review. *J Am Soc Nephrol* 2013; 24: 465–473.
4. Roy-Chaudhury P, Sukhatme VP and Cheung AK. Hemodialysis vascular access dysfunction: a cellular and molecular viewpoint. *J Am Soc Nephrol* 2006; 17: 1112–1127.
5. Lee T and Roy-Chaudhury P. Advances and new frontiers in the pathophysiology of venous neointimal hyperplasia and dialysis access stenosis. *Adv Chronic Kidney Dis* 2009; 16: 329–338.
6. Bountouris I, Kristmundsson T, Dias N, et al. Is Repeat PTA of a Failing Hemodialysis Fistula Durable? *Int J Vasc Med* 2014; 2014: 369687.
7. Manou-Stathopoulou S, Robinson EJ, Harvey JJ, et al. Factors associated with outcome after successful radiological intervention in arteriovenous fistulas: A retrospective cohort. *J Vasc Access* 2019; 20: 716–724.
8. Kim WS, Pyun WB and Kang BC. The primary patency of percutaneous transluminal angioplasty in hemodialysis patients with vascular access failure. *Korean Circ J* 2011; 41: 512–517.
9. Malka KT, Flahive J, Csizinszky A, et al. Results of repeated percutaneous interventions on failing arteriovenous fistulas and grafts and factors affecting outcomes. *J Vasc Surg* 2016; 63: 772–777.
10. Saleh HM, Gabr AK, Tawfik MM, et al. Prospective, randomized study of cutting balloon angioplasty versus conventional balloon angioplasty for the treatment of hemodialysis access stenoses. *J Vasc Surg* 2014; 60: 735–740.
11. Kim SM, Ko HK, Noh M, et al. Factors Affecting Patency following Successful Percutaneous Intervention for Dysfunctional Hemodialysis Vascular Access. *Ann Vasc Surg* 2018; 47: 54–61.
12. Neuen BL, Gunnarsson R, Baer RA, et al. Factors associated with patency following angioplasty of hemodialysis fistulae. *J Vasc Interv Radiol* 2014; 25: 1419–1426.
13. Bountouris I, Kritikou G, Degermetzoglou N, et al. A Review of Percutaneous Transluminal Angioplasty in Hemodialysis Fistula. *Int J Vasc Med* 2018; 2018: 1420136.
14. Cildag MB, Koseoglu OF, Akdam H, et al. The primary patency of drug-eluting balloon versus conventional balloon angioplasty in hemodialysis patients with arteriovenous fistula stenoses. *Jpn J Radiol* 2016; 34: 700–704.
15. Kariya S, Tanigawa N, Kojima H, et al. Primary patency with cutting and conventional balloon angioplasty for different types of hemodialysis access stenosis. *Radiology* 2007; 243: 578–587.
16. Werk M, Albrecht T, Meyer DR, et al. Paclitaxel-coated balloons reduce restenosis after femoro-popliteal angioplasty: evidence from the randomized PACIFIER trial. *Circ Cardiovasc Interv* 2012; 5: 831–840.
17. Liistro F, Porto I, Angioli P, et al. Drug-eluting balloon in peripheral intervention for below the knee angioplasty evaluation (DEBATE-BTK): a randomized trial in diabetic patients with critical limb ischemia. *Circulation* 2013; 128: 615–621.
18. Fanelli F, Cannavale A, Corona M, et al. The “DEBELLUM”–lower limb multilevel treatment with drug eluting balloon–randomized trial: 1-year results. *J Cardiovasc Surg (Torino)* 2014; 55: 207–216.
19. Zeller T, Baumgartner I, Scheinert D, et al. Drug-eluting balloon versus standard balloon angioplasty for infrapopliteal arterial revascularization in critical limb ischemia: 12-month results from the IN.PACT DEEP randomized trial. *J Am Coll Cardiol* 2014; 64: 1568–1576.
20. Scheinert D, Schulte KL, Zeller T, et al. Paclitaxel-releasing balloon in femoropopliteal

- lesions using a BTHC excipient: twelve-month results from the BIOLUX P-I randomized trial. *J Endovasc Ther* 2015; 22: 14–21.
21. Tepe G, Schnorr B, Albrecht T, et al. Angioplasty of femoral-popliteal arteries with drug-coated balloons: 5-year follow-up of the THUNDER trial. *JACC Cardiovasc Interv* 2015; 8: 102–108.
  22. Zeller T, Beschorner U, Pilger E, et al. Paclitaxel-Coated Balloon in Infrapopliteal Arteries: 12-Month Results From the BIOLUX P-II Randomized Trial (BIOTRONIK'S-First in Man study of the Passeo-18 LUX drug releasing PTA Balloon Catheter vs. the uncoated Passeo-18 PTA balloon catheter in subjects requiring revascularization of infrapopliteal arteries). *JACC Cardiovasc Interv* 2015; 8: 1614–1622.
  23. Scheinert D, Schmidt A, Zeller T, et al. German Center Subanalysis of the LEVANT 2 Global Randomized Study of the Lutonix Drug-Coated Balloon in the Treatment of Femoropopliteal Occlusive Disease. *J Endovasc Ther* 2016; 23: 409–416.
  24. Krishnan P, Faries P, Niazi K, et al. Stellarex Drug-Coated Balloon for Treatment of Femoropopliteal Disease: Twelve-Month Outcomes From the Randomized ILLUMENATE Pivotal and Pharmacokinetic Studies. *Circulation* 2017; 136: 1102–1113.
  25. Brodmann M, Werner M, Meyer DR, et al. Sustainable Antirestenosis Effect With a Low-Dose Drug-Coated Balloon: The ILLUMENATE European Randomized Clinical Trial 2-Year Results. *JACC Cardiovasc Interv* 2018; 11: 2357–2364.
  26. Micari A, Brodmann M, Keirse K, et al. Drug-Coated Balloon Treatment of Femoropopliteal Lesions for Patients With Intermittent Claudication and Ischemic Rest Pain: 2-Year Results From the IN.PACT Global Study. *JACC Cardiovasc Interv* 2018; 11: 945–953.
  27. Lookstein RA, Haruguchi H, Ouriel K, et al. Drug-Coated Balloons for Dysfunctional Dialysis Arteriovenous Fistulas. *N Engl J Med* 2020; 383: 733–742.
  28. Trerotola SO, Saad TF, Roy-Chaudhury P, et al. The Lutonix AV Randomized Trial of Paclitaxel-Coated Balloons in Arteriovenous Fistula Stenosis: 2-Year Results and Subgroup Analysis. *J Vasc Interv Radiol* 2020; 31: 1–14.e5.
  29. Bjorkman P, Weselius EM, Kokkonen T, et al. Drug-Coated Versus Plain Balloon Angioplasty In Arteriovenous Fistulas: A Randomized, Controlled Study With 1-Year Follow-Up (The Drecorest Ii-Study). *Scand J Surg* 2019; 108: 61–66.
  30. Hongsakul K, Bannangkoon K, Rookkapan S, et al. Paclitaxel-Coated Balloon Angioplasty for Early Restenosis of Central Veins in Hemodialysis Patients: A Single Center Initial Experience. *Korean J Radiol* 2018; 19: 410–416.
  31. Irani FG, Teo TKB, Tay KH, et al. Hemodialysis Arteriovenous Fistula and Graft Stenoses: Randomized Trial Comparing Drug-eluting Balloon Angioplasty with Conventional Angioplasty. *Radiology* 2018; 289: 238–247.
  32. Kim JW, Kim JH, Byun SS, et al. Paclitaxel-Coated Balloon versus Plain Balloon Angioplasty for Dysfunctional Autogenous Radiocephalic Arteriovenous Fistulas: A Prospective Randomized Controlled Trial. *Korean J Radiol* 2020; 21: 1239–1247.
  33. Kitrou PM, Katsanos K, Spiliopoulos S, et al. Drug-eluting versus plain balloon angioplasty for the treatment of failing dialysis access: final results and cost-effectiveness analysis from a prospective randomized controlled trial (NCT01174472). *Eur J Radiol* 2015; 84: 418–423.
  34. Kitrou PM, Katsanos K, Spyridonidis I, et al. Use of Drug-Coated Balloons in Dysfunctional Arteriovenous Dialysis Access Treatment: The Effect of Consecutive Treatments on Lesion Patency. *J Vasc Interv Radiol* 2019; 30: 212–216.
  35. Kitrou PM, Papadimitos P, Spiliopoulos S, et al. Paclitaxel-Coated Balloons for the Treatment of Symptomatic Central Venous Stenosis in Dialysis Access: Results from a Randomized Controlled Trial. *J Vasc Interv Radiol* 2017; 28: 811–817.
  36. Kitrou PM, Spiliopoulos S, Katsanos K, et al. Paclitaxel-coated versus plain balloon angioplasty for dysfunctional arteriovenous fistulae: one-year results of a prospective

- randomized controlled trial. *J Vasc Interv Radiol* 2015; 26: 348–354.
37. Kocaaslan C, Oztekin A, Bademci MS, et al. A retrospective comparison analysis of results of drug-coated balloon versus plain balloon angioplasty in treatment of juxta-anastomotic de novo stenosis of radiocephalic arteriovenous fistulas. *J Vasc Access* 2020; 21: 596–601.
  38. Lai CC, Fang HC, Tseng CJ, et al. Percutaneous angioplasty using a paclitaxel-coated balloon improves target lesion restenosis on inflow lesions of autogenous radiocephalic fistulas: a pilot study. *J Vasc Interv Radiol* 2014; 25: 535–541.
  39. Liao MT, Lee CP, Lin TT, et al. A randomized controlled trial of drug-coated balloon angioplasty in venous anastomotic stenosis of dialysis arteriovenous grafts. *J Vasc Surg* 2020; 71: 1994–2003.
  40. Lucev J, Breznik S, Dinevski D, et al. Endovascular Treatment of Haemodialysis Arteriovenous Fistula with Drug-Coated Balloon Angioplasty: A Single-Centre Study. *Cardiovasc Intervent Radiol* 2018; 41: 882–889.
  41. Maleux G, Vander Mijnsbrugge W, Henroteaux D, et al. Multicenter, Randomized Trial of Conventional Balloon Angioplasty versus Paclitaxel-Coated Balloon Angioplasty for the Treatment of Dysfunctional Autologous Dialysis Fistulae. *J Vasc Interv Radiol* 2018; 29: 470–475.e3.
  42. Massara M, Finocchiaro P, Volpe A, et al. Percutaneous drug-eluting balloon angioplasty to treat dialysis access stenosis. *Semin Vasc Surg* 2017; 30: 67–69.
  43. Massmann A, Fries P, Obst-Gleditsch K, et al. Paclitaxel-coated balloon angioplasty for symptomatic central vein restenosis in patients with hemodialysis fistulas. *J Endovasc Ther* 2015; 22: 74–79.
  44. Moreno-Sanchez T, Moreno-Ramirez M, Machancoses FH, et al. Efficacy of Paclitaxel Balloon for Hemodialysis Stenosis Fistulae After One Year Compared to High-Pressure Balloons: A Controlled, Multicenter, Randomized Trial. *Cardiovasc Intervent Radiol* 2020; 43: 382–390.
  45. Patane D, Failla G, Coniglio G, et al. Treatment of juxta-anastomotic stenoses for failing distal radiocephalic arteriovenous fistulas: Drug-coated balloons versus angioplasty. *J Vasc Access* 2019; 20: 209–216.
  46. Patane D, Giuffrida S, Morale W, et al. Drug-eluting balloon for the treatment of failing hemodialytic radiocephalic arteriovenous fistulas: our experience in the treatment of juxta-anastomotic stenoses. *J Vasc Access* 2014; 15: 338–343.
  47. Swinnen JJ, Hitos K, Kairaitis L, et al. Multicentre, randomised, blinded, control trial of drug-eluting balloon vs Sham in recurrent native dialysis fistula stenoses. *J Vasc Access* 2019; 20: 260–269.
  48. Swinnen JJ, Zahid A and Burgess DC. Paclitaxel drug-eluting balloons to recurrent in-stent stenoses in autogenous dialysis fistulas: a retrospective study. *J Vasc Access* 2015; 16: 388–393.
  49. Tozzi M, Franchin M, Savio D, et al. Drug-coated balloon angioplasty in failing haemodialysis arteriovenous shunts: 12-month outcomes in 200 patients from the Aperto Italian registry. *J Vasc Access* 2019; 20: 733–739.
  50. Dinh K, Limmer AM, Paravastu SCV, et al. Mortality After Paclitaxel-Coated Device Use in Dialysis Access: A Systematic Review and Meta-Analysis. *J Endovasc Ther* 2019; 26: 600–612.
  51. Nordanstig J, James S, Andersson M, et al. Mortality with Paclitaxel-Coated Devices in Peripheral Artery Disease. *N Engl J Med* 2020; 383: 2538–2546.
  52. Katsanos K, Karnabatidis D, Kitrou P, et al. Paclitaxel-coated balloon angioplasty vs. plain balloon dilation for the treatment of failing dialysis access: 6-month interim results from a prospective randomized controlled trial. *J Endovasc Ther* 2012; 19: 263–272.
  53. Chong TT, Yap HY, Tan CS, et al. Use of Paclitaxel Coated Drug Eluting Technology to Improve Central Vein Patency for Haemodialysis Access Circuits: Any Benefit? *Vasc Specialist Int* 2020; 36: 21–27.
  54. Yildiz I. The Efficacy of Paclitaxel Drug-Eluting Balloon Angioplasty Versus Standard Balloon Angioplasty in Stenosis

- of Native Hemodialysis Arteriovenous Fistulas: An Analysis of Clinical Success, Primary Patency and Risk Factors for Recurrent Dysfunction. *Cardiovasc Intervent Radiol* 2019; 42: 685–692.
55. Schulz KF, Altman DG, Moher D, et al. CONSORT 2010 statement: updated guidelines for reporting parallel group randomised trials. *BMJ* 2010; 340: c332.
  56. Schroeder H, Meyer DR, Lux B, et al. Two-year results of a low-dose drug-coated balloon for revascularization of the femoropopliteal artery: outcomes from the ILLUMENATE first-in-human study. *Catheter Cardiovasc Interv* 2015; 86: 278–286.
  57. Katsanos K, Spiliopoulos S, Kitrou P, et al. Risk of Death Following Application of Paclitaxel-Coated Balloons and Stents in the Femoropopliteal Artery of the Leg: A Systematic Review and Meta-Analysis of Randomized Controlled Trials. *J Am Heart Assoc* 2018; 7: e011245.
  58. Karunanithy N, Robinson EJ, Ahmad F, et al. A multicenter randomized controlled trial indicates that paclitaxel-coated balloons provide no benefit for arteriovenous fistulas. *Kidney Int* 2021; 100: 447–456.
  59. Manninen HI, Kaukanen ET, Ikaheimo R, et al. Brachial arterial access: endovascular treatment of failing Brescia-Cimino hemodialysis fistulas—initial success and long-term results. *Radiology* 2001; 218: 711–718.
  60. Bjorkman P, Weselius EM and Venermo M. No difference in mid- to long-term mortality after vascular paclitaxel exposure. *Ann Vasc Surg* 2021; 72: 253–260.
  61. Schroeder H, Meyer DR, Lux B, et al. A Pilot Study of Femoropopliteal Artery Revascularisation with a Low Dose Paclitaxel Coated Balloon: Is Predilatation Necessary? *Eur J Vasc Endovasc Surg* 2017; 54: 348–355.
  62. Rajan DK, Sidhu A, Noel-Lamy M, et al. Elastic Recoil after Balloon Angioplasty in Hemodialysis Accesses: Does It Actually Occur and Is It Clinically Relevant? *Radiology* 2016; 279: 961–967.