

An Exploratory Electrical Stimulation Protocol in the Management of an Infant With Spina Bifida: A Case Report

Gerti Motavalli, MPT¹, Jan J. McElroy, PT, PhD, PCS², and Gad Alon, PhD, PT³

Abstract

An infant with myelomeningocele and underdevelopment of the thoracic spinal cord was treated with 2 protocols of electrical stimulation: functional electrical stimulation and transcutaneous spinal cord electrical stimulation. The protocols were incorporated into the infant's outpatient early intervention home programs. Prior to initiation of electrical stimulation treatment at age 6 months, the infant exhibited complete loss of sensation below the level of T8 and muscular paralysis below the level of T10. The unexpected emergence of somatosensory responses and spontaneous movements in the trunk and lower extremities are described, focusing on the electrical stimulation protocols. Spinal cord electrical stimulation protocols were not previously described in the medical literature regarding the management of children with spina bifida. Both functional and spinal cord electrical stimulation protocols used with this infant proved safe and well tolerated. The experience gained over 12 months of treatment is the subject of this case report.

Keywords

Meningomyelocele, functional, spinal cord, electrical stimulation

Received December 17, 2018. Received revised February 1, 2019. Accepted for publication February 09, 2019.

Each year in the United States, close to 1500 infants are born with congenital malformations of the neural tube, collectively termed spina bifida.¹ Neural tube deficits often adversely affect the function of the neuromuscular and sensory systems, substantially modifying the normal development of the infants. Contemporary neurosurgery, in utero or postnatal, can minimize the neurological damage but fails to restore normal innervation.² Spina bifida may be associated with additional congenital deformities, such as kyphosis, spinal malformations, hip dislocations, and clubfeet. Congenital deformities combine with acquired deformities due to muscle imbalance and altered reaction forces significantly alter the development of the child. Thus, these infants and their families are faced with life-long medical, physical, and social challenges.³ The degree of acquired deformities and diminished mobility of the growing child have been associated with motor and sensory losses as determined by the level and distribution of the spinal cord lesion.

Development of the skills which enable the infant to rise from the floor, stand upright, and walk is a therapeutic goal that only 43% of children born with spina bifida are expected

to achieve. Many will require orthotics and assistive devices to ambulate.⁴ As these children mature, many experience mobility decline due to acquired deformities and weight gain necessitating wheelchair use. Restriction of mobility has been shown to increase the incidence of long-term medical complications. Current neurosurgical procedures are inadequate to restore sufficient innervation and connectivity within the damaged spinal cord to support normal independent ambulation. Thus, newborns with spina bifida are referred for pediatric intervention services specializing in sensory motor development. Typical intervention programs include functional facilitation techniques combined with various tools and

¹ Columbia, MO, USA

² Department of Physical Therapy, University of Missouri, Columbia, MO, USA

³ University of Maryland School of Medicine, Baltimore, MD, USA

Corresponding Author:

Gad Alon, PhD, PT, University of Maryland School of Medicine, 100 Penn Street, Baltimore, MD 21201, USA.

Email: galon@som.umaryland.edu



adaptive equipment. The use of functional or neuromuscular electrical stimulation, a common intervention following spinal cord injury,^{5,6} is surprisingly absent when the diagnosis is spina bifida.

For years, the rationale for applying neuromuscular electrical stimulation following spinal cord injury has been guided by the ability to electrically induce muscle contraction in otherwise paralyzed muscles, provided that the peripheral motor nerves below the spinal lesion remained intact. The objectives of the electrically induced contractions have been to minimize sarcopenia, augment peripheral circulation, minimize loss of joint range of motion, and bone loss. Conceptionally, the objective has been to concurrently promote recovery of neural connectivity within the damaged spinal cord via the afferent pathways originating in the periphery and terminating at the cortical regions of the brain. Successful achievement of augmenting muscle strength and peripheral blood and lymph flow and improving cardiorespiratory function has been supported by numerous peer-reviewed publications and summarized by Bickel et al.⁵ In contrast, promoting recovery of neural connectivity within the spinal cord using electrically induced muscle contraction has failed.⁷

Researchers recently reported a novel, noninvasive “over the lesioned spinal cord” stimulation as a means of enhancing neural connectivity in the damaged region.⁸⁻¹¹ Specifically, Sayenko and colleagues¹² placed electrodes over the spinous processes of L2 and S1 segments with the return electrodes placed over the iliac crest bilaterally. This unconventional stimulation protocol was used in a study with 2 groups of children with cerebral palsy.⁸ The experimental group received transcutaneous spinal cord stimulation at 2 spinal levels (over T11 and L2 spinous processes), combined with locomotor treadmill training, whereas the control group received locomotor treadmill training without stimulation. After spinal cord stimulation, the experimental group demonstrated an incremental increase in knee torque, whereas in the control group, this effect was absent. In addition, a decrease of coactivation of muscles of the lower extremities was observed in the experimental group. The authors concluded that locomotor function of the studied sample of children was improved significantly with the combination of locomotion training and transcutaneous spinal cord stimulation.⁸

There are fundamental physiologic, etiologic, and clinical differences contributing to the expression of motor and sensory deficits among individuals with brain injuries (such as cerebral palsy), traumatic spinal cord injuries, and myelomeningocele. Such factors made direct application of previous basic science and noninvasive spinal cord stimulation research difficult when considering transcutaneous spinal cord stimulation for a child with myelomeningocele. The reported safe application and facilitation of a stepping response in other populations provided the basis to examine the effect of transcutaneous spinal cord stimulation in an infant with myelomeningocele. We report herein our surprising positive findings.

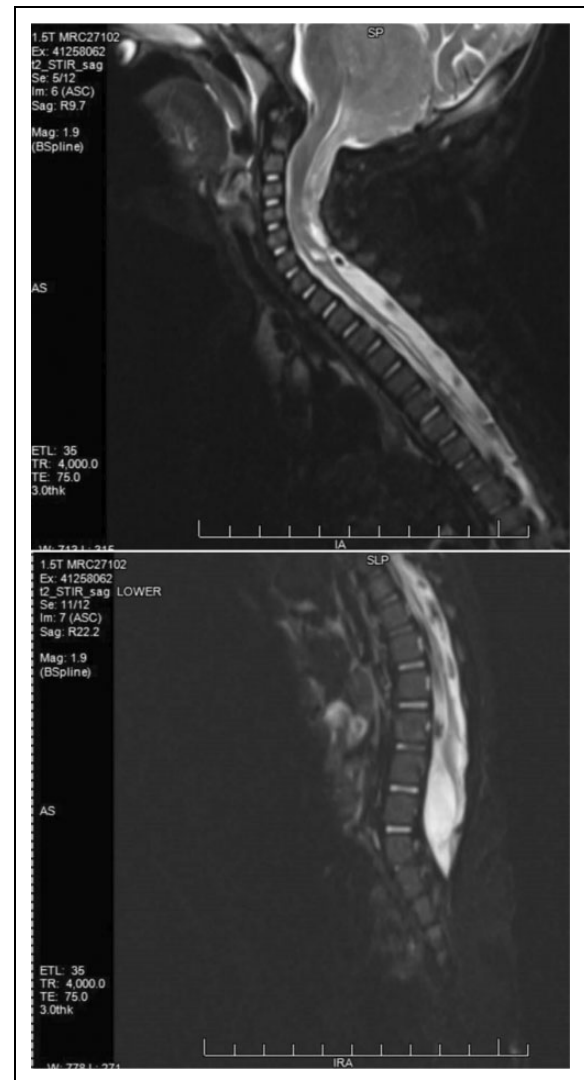


Figure 1. Magnetic resonance imaging taken at 6 months.

Patient Information

A 6-month-old boy was seen for physical therapy in our early intervention program secondary to a diagnosis of myelomeningocele. Although he had received physical therapy consisting of positioning and range of motion since birth, his parents felt he had not made any changes and were seeking other approaches.

The infant was born at 38 6/7 weeks' gestation via caesarian delivery with Apgar scores of 1 and 10. His myelomeningocele was repaired on day of life 1 with a reported defect extending from L2 to L5. Nerve roots were reported to be present within the defect. Magnetic resonance imaging–based summaries reported severe Chiari II malformation with caudal displacement of the hindbrain. Head circumference at birth was 35 cm. Surgical insertion of a right ventriculoperitoneal shunt stabilized his hydrocephalus on day of life 4. Magnetic resonance imaging taken at 6 months reconfirmed the diagnosis (Figure 1). The upper thoracic spinal cord was underdeveloped and

tapered off to a thin ribbon. A small short segment syring was noted in the upper cervical cord. Between 2 and 4 months of age, his head circumference increased from 41.8 to 46.9 cm and a shunt revision was performed. At 6.5 months of age, his head circumference was 48 cm and another shunt revision was performed. Head circumference continued to be stable at 48 cm through 20 months of age. He was followed medically for neurogenic bowel and bladder issues.

Hospital records from birth and subsequent hospitalizations did not report any subjective or objective sensory assessments. Anecdotal reports were found stating that no lower extremity movement was observed during any of the hospitalizations and during physical therapy visits in the early intervention program. No formal muscle testing was included in any of the medical records.

Assessment findings at 6 months revealed significant sensory and motor deficits inconsistent with his known neurologic level of injury of L2-L5. Sensation was present at the T6 level and above with spotty sensation to the T8 level. No light/deep pressure or pinprick sensation was noted below the T8 level (Figure 2). Lower extremities were flaccid with a functional motor level of T10. Lower extremity range of motion was normal with the exception of slight end-range resistance to full hip extension on the right and plantarflexion on the left. Mild positional tightness of the iliotibial band was noted bilaterally. These findings were consistent with previous physician and therapist reports since birth.

By 6 months, this infant demonstrated difficulty lifting and sustaining his head when prone. His head control was poor and he exhibited a posteriorly tilted pelvis and significant thoracolumbar kyphosis in supported sitting. No functional motor skills were noted in the trunk or lower extremities.

Therapeutic Intervention

Early intervention physical therapy services were delivered 2 to 3 times weekly in a clinic setting with a daily home program. Intervention consisted of conventional positioning/assistive devices and an electrical stimulation program. Conventional positioning/assistive devices included nighttime rice bags to limit hip abduction, an adapted highchair, a stander using ankle foot orthoses, and a dynamic trunk orthosis with an orthoplast back support. As developmentally appropriate, mobility devices were introduced for prone and sitting wheeled mobility. The electrical stimulation program consisted of 2 different interventions: functional electrical stimulation and spinal stimulation.

Functional Electrical Stimulation Protocol

The functional electrical stimulation protocol was initiated to strengthen the muscles of the back/lower extremities and support peripheral arterial, venous, and lymphatic flow. Two 2-channel stimulators (EMPI Continuum) were utilized for the functional electrical stimulation. Electrode sizes varied from 5 × 5 cm to 5 × 9 cm, depending on muscle size. Initially gluteals, quadriceps,

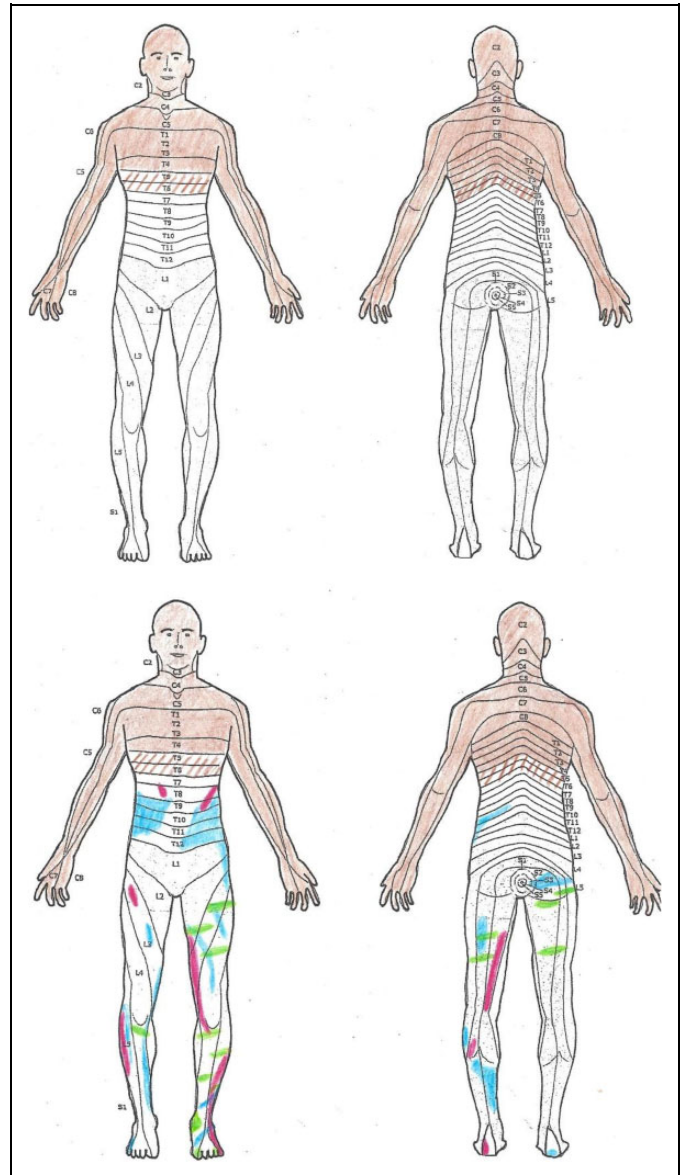


Figure 2. Sensation charts. Top, Initial sensation at 6 months. Bottom, Sensation at 18 months post, a 12-month intervention with spinal and functional electrical stimulation. Red = pin prick, Green = pressure, Blue = temperature (ice).

and gastrocnemius were stimulated bilaterally (Figure 3). After 6 weeks, back extensors were added to the protocol (Figure 3). Stimulation was 15 to 30 minutes 2 times daily administered in the clinic or at home by the parents. Functional positions during stimulation progressed from supine and sitting to sit-to-stand and standing as appropriate for his age.

Six to 18 months of age. The objective was to induce visible, strong tetanic muscle contractions. Electrical stimulator settings were as follows: (1) phase duration 200 to 300 microseconds, (2) pulse rate 14 to 18 pulses per second (pps), (3) duration 7 to 10 seconds ON, 5-7 seconds OFF (after 1 month 15 seconds ON 15 seconds OFF).

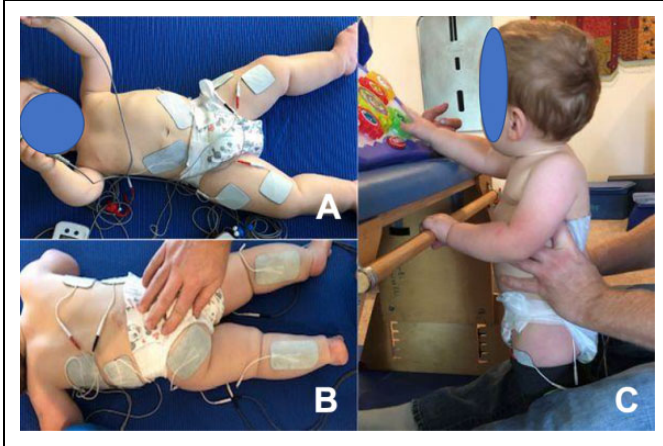


Figure 3. Functional electrical stimulation electrode placement. A, Anterior view, abdominal and quadriceps electrode placement. B, Posterior view, latissimus, gluteals, and gastrocnemius electrode placement. C, Sit to stand functional electrical stimulation activity for isometric, concentric, and eccentric muscle activation.

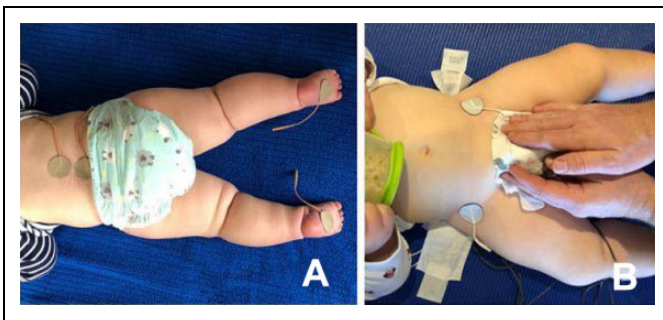


Figure 4. Electrode placement lower spine. A, Posterior view, electrodes at T12-L2 and plantar surface of feet bilaterally. B, Anterior view, bilateral iliac crests.

Transcutaneous Spinal Cord Stimulation Protocol

Spinal cord stimulation (transcutaneous spinal cord stimulation) was added as a second electrical stimulation protocol to see if it would improve the infant's trunk posture in sitting. The transcutaneous spinal cord stimulation was a noninvasive (surface) electrical stimulation following the method of Sayenko and colleagues.¹² One two-channel stimulator (EMPI Continuum TENS mode) was used with either 3.1 cm (later changed to 5 cm) round electrodes or 5 × 5 cm over the spine at T12-L2 and 5 × 5 cm return electrodes placed over either the iliac crest or the plantar surface of the foot (Figure 4). At 17 months of age, electrode placement over the spine at C7 to T12 was added to explore the possibility that his upper spinal abnormality could be addressed for increased trunk and respiratory function (Figure 5). The transcutaneous spinal cord stimulation protocol was administered daily (2 × daily at 17 months) for 30 minutes by the parents with the infant in a supportive sitting or standing device.

Seven and 1/2 to 11 months of age. The objective was to stimulate the spinal cord to develop emerging movements in the

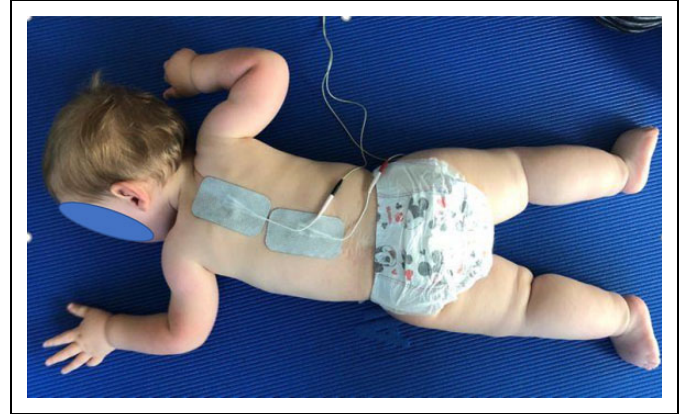


Figure 5. Electrodes placement for transcutaneous spinal cord stimulation C7 to T12 using one channel.

lower extremities and back extensors. Electrical stimulator settings were as follows: TENS mode, (1) phase duration 300 microseconds, (2) pulse rate 150 pps, (3) cycling time 12 seconds.

The leads for channel 1 connected the T12 level electrode and the electrode over the right iliac crest, while the leads for channel 2 connected the L2 level electrode and the electrode over the left iliac crest. The leads were switched after 15 minutes so the T12 level electrode was connected to the left iliac crest and vice versa for the L2 level electrode. As the program continued, the 2 return electrodes were moved from the iliac crests to the plantar surface of the feet (Figure 4).

Eleven to 18 months of age. The protocol continued as in 7.5 to 11 months of age except the return electrode placement was changed from the iliac crests to the plantar surface of the feet.

Fifteen to 18 months of age. Electrical stimulator settings were changed as follows: TENS (1) phase duration 300 microseconds, (2) pulse rate 10 to 15 pps, (3) cycling time 12 seconds.

Seventeen to 18 months of age. A second electrode location was introduced, with the previous placement being used daily in the mornings and the second placement being used daily in the afternoon. Electrode placement for the thoracic transcutaneous spinal cord stimulation consisted of two 5 × 9 cm electrodes being placed over the spine from C7 to T12 (Figure 5). The same device and stimulation parameters were used for both morning and afternoon protocols.

Follow-Up and Outcomes

Consistent with outcomes reported in the literature for individuals with a diagnoses of spinal cord injury and cerebral palsy, we hoped to see changes in muscle activation and strength of the trunk and lower extremities after functional electrical stimulation and transcutaneous spinal cord stimulation in our infant with myelomeningocele. Changes observed in our case

report over the first 12-month intervention period were seen in 3 areas: sensation, circulation, and muscle activation/strength.

Sensation

The most dramatic and unexpected changes in this infant were in emerging sensation. At 6 months of age, the infant demonstrated no response to pressure, temperature, or pinprick below T10. One month after initiation of transcutaneous spinal cord stimulation, the infant responded to pinprick in a portion of the L5/S1 dermatome. The next month, he responded to deep pressure above the knee in the L4 dermatome on the left, below the knee on the right, as well as his first response to cold in the T8/9 dermatome. His sensation, though slow and spotty, continued to emerge through the 12-month intervention period. Currently, he consistently responds to scattered patches of sensation in all dermatomes through S2, more responses on his left than his right (Figure 2). Pressure, temperature, and pinprick responses do not present in the same areas. Parents observed that he had better anal closure and less smearing.

Circulation

Initially this infant's feet were constantly cold to the touch and pale regardless of room temperature or foot coverings. At 8 months of age, the infant's right foot was noted to be consistently warm to the touch. At 10 months of age, both feet were warm, right more than left. Both feet were consistently warm and pink by 16 months of age.

Muscle Activation

Prior to functional electrical stimulation and transcutaneous spinal cord stimulation interventions, the infant was flaccid below the T10 level. Electrically induced muscle contractions were noted for the first time during the initial functional electrical stimulation session. Hip flexion–extension and knee extension twitches and occasional tetanic contractions were observed. Over the next 4 months, muscle contractions became stronger and movements included hip flexion/extension, hip abduction/adduction, knee flexion/extension, ankle plantar flexion, and toe wiggling during stimulation. However, spontaneous lower extremity movements did not occur outside the stimulation periods until back extensors functional electrical stimulation and transcutaneous spinal cord stimulation were initiated. Strength and duration of the muscle contractions have increased over the 12-month intervention period; however, the movements without stimulation continue to be intermittent throughout the day, spontaneous, but not used purposefully for function.

Recently, the infant's abdominals have shown increased activation. His right abdominals activated first causing significant trunk asymmetry, then symmetry returned as his left abdominal muscle tone improved. Improved trunk posture in sitting and standing is the most significant functional outcome currently derived from his improved muscle activation and strength.

Adverse Events

No adverse events were experienced during functional electrical stimulation. Mild skin breakdown occurred initially during transcutaneous spinal cord stimulation. After about 1 month of daily stimulation, 2 to 3 blisters 1.5 mm in diameter occurred at the upper edge of the iliac crest electrodes. The blisters healed by the next day. The protocol using 3.1-cm-diameter electrodes on the iliac crest was changed to 5 × 5-cm electrodes placed more laterally on the iliac crest. The change resulted in elimination of blister formation during stimulation.

Transient redness lasting for 15 to 20 minutes was noted under the spinal electrodes, particularly around the scars, daily post transcutaneous spinal cord stimulation. This issue was reduced by changing the 3.1-cm round electrodes to 5 × 5-cm square electrodes and replacing frequently with new, fresh electrodes. Otherwise, both protocols were well tolerated by the infant.

Discussion

Augmenting muscle strength, peripheral blood, and lymph flow and improving cardiorespiratory function induced by means of neuromuscular electrical stimulation or functional electrical stimulation have become common intervention practices in the management of patients with spinal cord injury.⁵ This provided the rationale to apply functional electrical stimulation as part of the physical therapy intervention program in the current case. Despite the known pathophysiological and age differences between adults with spinal cord injury and an infant with myelomeningocele, this infant responded well to the functional electrical stimulation protocol. As expected, the functional electrical stimulation protocol for the trunk and lower extremities did not lead to new spontaneous movements.

Introduction of a noninvasive spinal cord stimulation protocol (transcutaneous spinal cord stimulation) with an infant with spina bifida was not only novel but absent of electrophysiological rationale. The hypothetical clinical efficacy was derived from a proof-of-concept pilot study of children with cerebral palsy.⁸ The immediate response to transcutaneous spinal cord stimulation was surprising. Both lower extremities demonstrated minimal, transient movement during stimulation from the first session on. Similar responses were not previously reported in the medical literature. The unexpected emergence of movement provided the motivation to continue the transcutaneous spinal cord stimulation protocol, first over the T12-L2 spinal levels and later adding the C7 to T12 spine levels to better focus the stimulation over the underdeveloped spinal cord in the thoracic region. The addition of the transcutaneous spinal cord stimulation protocol to the functional electrical stimulation protocol coincided with the rapid emergence of repeated daily spontaneous movements of both lower extremities without stimulation as well as the emergence of spotty sensory awareness.

Any attempt to elucidate the mechanism that may explain the observed clinical responses is premature. Nonetheless,

anatomically based plausible speculation may be offered whereby the transcutaneous spinal cord stimulation causes excitation of the spinal nerve dorsal roots which in turn propagate action potentials along the internuncial pool of connecting nerve fibers within the spinal cord. Such excitation continues to propagate via the anterior horn along the entire area of stimulation, causing multisegmental excitation of motor nerve fibers, leading to spontaneous muscle contraction.

The encouraging, albeit slow clinical progress, and the transient, easily managed, adverse skin irritation provides sufficient information to consider further exploration of the functional electrical stimulation/transcutaneous spinal cord stimulation protocol combination for other infants with spina bifida. At the same time, it behooves all involved not to raise expectations for improvement based on a single case in which an infant showed initial development of sensory and motor responses. Interventions continue with this toddler and further changes, both positive and negative, will be reported.

Conclusion

The application of functional electrical stimulation and noninvasive spinal cord electrical stimulation (transcutaneous spinal cord stimulation) protocols to a 6-month old infant with myelomeningocele has not been previously reported in the medical literature. The observed gradual development of previously absent sensory and motor responses in this infant was novel, surprising, and encouraging. Functional electrical stimulation and spinal cord electrical stimulation are well tolerated and have minimal, transient adverse events when applied to infants with spina bifida. The initial positive outcomes and safety of the novel application of electrical stimulation for this case infant provide a basis for further research into a new intervention approach which could enhance development for infants born with spina bifida.

Acknowledgments

The authors are grateful to the Moreland family for being an integral part of delivering the stimulation programs and for the generosity of sharing their son's experience. They also acknowledge Rez Farid, MD, for his editorial assistance.

Author Contributions

GM provided the physical therapy-neurodevelopmental assessments and treatment, and contributed to the writing of the manuscript. JJM provided neurodevelopmental assessments and guidance to the evolving treatment, and was a primary writer of the rough draft manuscript. GA provided the rationale and methods for instituting the different stimulation protocols and was the primary writer of the submitted manuscript.

Declaration of Conflicting Interests

The authors declared no potential conflicts of interest with respect to the research, authorship, and/or publication of this article.

Funding

The authors received no financial support for the research, authorship, and/or publication of this article.

Ethical Approval

This case was treated in a non-institutional, licensed private pediatric clinic that does not require specific ethical approval statement.

References

1. Canfield MA, Honein MA, Yuskiv N, et al. National estimates and race/ethnic-specific variation of selected birth defects in the United States, 1999-2001. *Birth Defects Res A Clin Mol Teratol.* 2006;76(11):747-756.
2. Copp AJ, Stanier P, Greene ND. Neural tube defects: recent advances, unsolved questions, and controversies. *Lancet Neurol.* 2013;12(8):799-810.
3. Piatt JH Jr. Adults with myelomeningocele and other forms of spinal dysraphism: hospital care in the United States since the turn of the millennium. *J Neurosurg Spine.* 2016;25(1):69-77.
4. Johnson KL, Dudgeon B, Kuehn C, Walker W. Assistive technology use among adolescents and young adults with spina bifida. *Am J Public Health.* 2007;97(2):330-336.
5. Bickel CS, Yarrar-Fisher C, Mahoney ET, McCully KK. Neuromuscular electrical stimulation-induced resistance training after SCI: a review of the Dudley protocol. *Top Spinal Cord Inj Rehabil.* 2015;21(4):294-302.
6. Jones ML, Evans N, Tefertiller C, et al. Activity-based therapy for recovery of walking in individuals with chronic spinal cord injury: results from a randomized clinical trial. *Arch Phys Med Rehabil.* 2014;95(12):2239-2246 e2232.
7. Gant K, Nagle K, Cowan R, et al. Body system effects of a multimodal training program targeting chronic, motor complete thoracic spinal cord injury. *J Neurotrauma.* 2017;35(3):411-423.
8. Solopova IA, Sukhotina IA, Zhvansky DS, et al. Effects of spinal cord stimulation on motor functions in children with cerebral palsy. *Neurosci Lett.* 2017;639:192-198.
9. Krucoff MO, Rahimpour S, Slutzky MW, Edgerton VR, Turner DA. Enhancing nervous system recovery through neurobiologics, neural interface training, and neurorehabilitation. *Front Neurosci.* 2016;10:584.
10. Gerasimenko Y, Gad P, Sayenko D, et al. Integration of sensory, spinal, and volitional descending inputs in regulation of human locomotion. *J Neurophysiol.* 2016;116(1):98-105.
11. Lee NG, Andrews E, Rosoklija I, et al. The effect of spinal cord level on sexual function in the spina bifida population. *J Pediatr Urol.* 2015;11(3):142 e141-142 e146.
12. Sayenko DG, Atkinson DA, Floyd TC, et al. Effects of paired transcutaneous electrical stimulation delivered at single and dual sites over lumbosacral spinal cord. *Neurosci Lett.* 2015;609:229-234.