

Case Report

Solitary extramedullary plasmacytoma of the tongue

Y Hama, M Uematsu, S Kusano

Accepted 13 August 2004

Solitary extramedullary plasmacytomas are uncommon malignant neoplasms accounting for 5-10% of all plasma cell malignancies.^{1,2} The majority of extramedullary plasmacytomas are seen in head and neck region and frequently arise from the upper aerodigestive tract.³ Solitary plasmacytoma of the tongue is extremely rare, with only a few cases having been reported in the English literature.⁴⁻⁷ But magnetic resonance (MR) imaging findings have not been described previously. We report a case of solitary plasmacytoma of the tongue in a 72-year-old man, and present the MR findings.

CASE REPORT A 72-year-old man presented with a three-month history of a tender swelling and ulceration in the tongue, which had been growing slowly. His past history and family history were not remarkable except for rheumatoid arthritis, pulmonary fibrosis and chronic renal failure which had been treated for six years. Physical examination revealed an elastic hard mass (4 x 1.5 cm) with an irregular surface and deep ulceration that affected the ventral surface of the tongue (*Fig. 1*). There was no cervical lymphadenopathy.

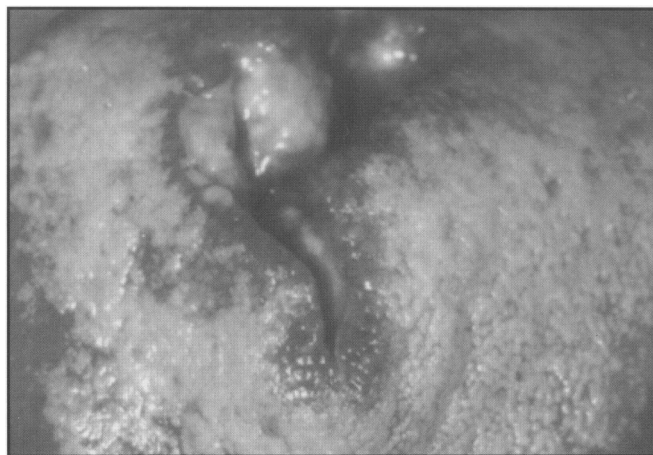


Fig 1. Photograph of the patient's tongue shows an irregular surface and deep ulceration.

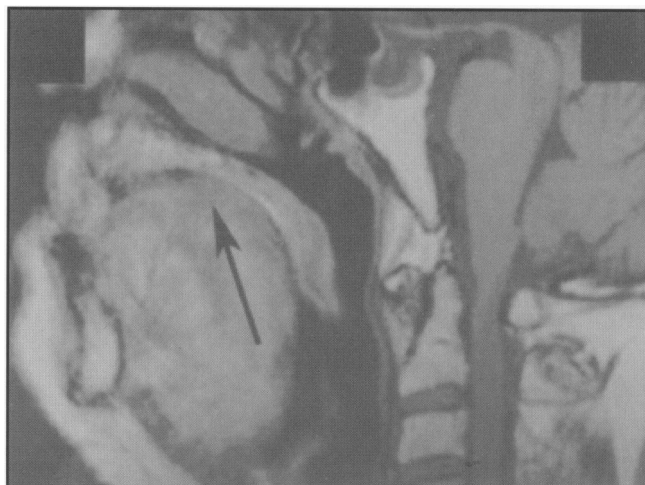


Fig 2a. Sagittal T1-weighted MR image demonstrates a hypointense mass in the tongue (*arrow*).

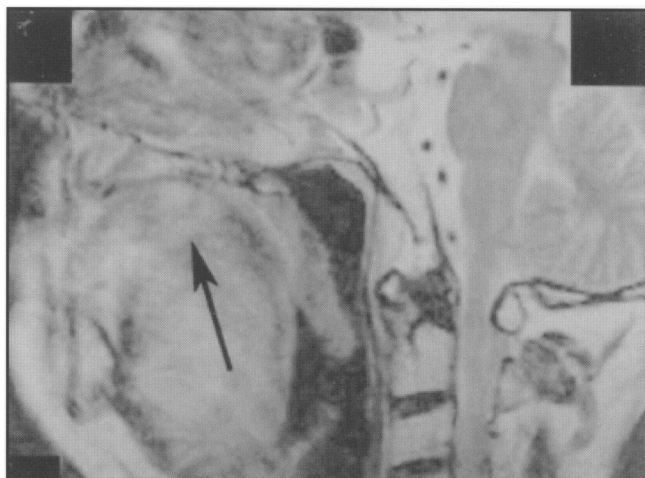


Fig 2b. Sagittal T2-weighted MR image demonstrates a hyperintense mass (*arrow*).

Department of Radiology, National Defense Medical College, 3-2 Namiki, Tokorozawa, Saitama, 359-0042, Japan

U Hama, MD

M Uematsu, MD

S Kusano, MD

Correspondence to Dr Hama

E-mail: yjhama@me.ndmc.ac.jp

MR image of the head and neck demonstrated a 3 x 3cm mass in the tongue. The mass is hypointense on the T1-weighted image and slightly hyperintense on the T2-weighted image with a hypointense rim (Figs 2a and 2b). Local and regional lymphadenopathies were not remarkable.

Histological examination revealed diffuse infiltration of immature plasma cells with mildly atypical nuclei. The nuclei were hyperchromatic and oval with no visible nucleoli. The neoplastic nature of the plasma cell infiltrate was confirmed by immunohistochemical studies.

Immunohistochemistry demonstrated light chain restriction. The tumor cells were positive for lambda light chains and negative for kappa light chains. The most tumor cells showed negative staining for the L-26 antigen. This indicated a clonal population leading to a diagnosis of plasma cell neoplasm.

The following examinations were undertaken to rule out multiple myeloma: skeletal survey, bone marrow biopsy, gallium scanning, sedimentation rate, electrolytes, complete blood count, beta-2-microglobulin, quantitative immunoglobulins, serum and urine protein electrophoresis, and Bence-Jones proteins in the urine. All of them were within normal limits. Thus, multiple myeloma was excluded and the final diagnosis of solitary extramedullary plasmacytoma of the tongue was made.

He was initially treated with radical radiotherapy and given a mid-plane dose of 34Gy in 17 fractions over a period of 22 days. But pulmonary fibrosis and chronic renal failure were exacerbated possibly by analgesics and hypnotics, and he died in the course of radiotherapy. The tumor disappeared macroscopically after the radiotherapy of 34Gy. Autopsy was not performed.

DISCUSSION

Extramedullary plasmacytoma is an immunoproliferative, monoclonal disease of the B-cell arising outside the bone marrow without clinical evidence of multiple myeloma.^{3,8} It originates as a clone of malignant transformed plasma cells. They usually migrate and return to establish themselves in the bone marrow. In rare instances, they also settle in soft tissue or in an extracellular connective tissue area.^{3,8} This is the origin for monoclonal plasma cell foci located

outside the bone marrow, called extramedullary plasmacytoma.³

The diagnosis of solitary extramedullary plasmacytoma should normally provoke investigation for disseminated disease and this should include a skeletal survey, serum and urinary protein electrophoresis, serum immunoglobulins and bone marrow biopsy.⁹ Immunohistochemical staining for light and heavy immunoglobulin chains is also necessary in documenting the nature of the plasma cell proliferation and in confirming the diagnosis.^{1,3,9}

Extramedullary plasmacytomas are highly radiosensitive, and they often respond to radiotherapy with complete clearance and, if there is no dissemination, these patients can be considered cured of disease.^{10,11} Thus it is important to assess the size and depth of tumor invasion, extension, and presence of enlarged lymph nodes to make high quality radiotherapy possible. Due to the limitation of clinical assessment by physical examination, MR imaging may play an important role in the assessment of plasmacytoma of the tongue. Owing to the rarity of cases, evaluation by MR imaging still warrants further investigations.

REFERENCES

1. Corwin J, Lindberg RD. Solitary plasmacytoma of bone vs extramedullary plasmacytoma and their relationship to multiple myeloma. *Cancer* 1979; 43(3): 1007-13.
2. Shih LY, Dunn P, Leung WM, Chen WJ, Wang PN. Localised plasmacytomas in Taiwan: comparison between extramedullary plasmacytoma and solitary plasmacytoma of bone. *Br J Cancer* 1995; 71(1): 128-33.
3. Alexiou C, Kau RJ, Dietzfelbinger H, Kremer M, Spiess JC, Schratzenstaller B, et al. Extramedullary plasmacytoma: tumor occurrence and therapeutic concepts. *Cancer* 1999; 85(11): 2305-14.
4. Samuel L, Candlish W, Stark A. Solitary extramedullary plasmacytoma. *New Engl J Med* 1997; 337(16): 1174.
5. Kole AC, Nieweg OE, Pruijm J, Hoekstra HJ, Koops HS, Roodenburg JL, et al. Detection of unknown occult primary tumors using positron emission tomography. *Cancer* 1998; 82(6): 1160-6.
6. Layton SA, Cook JN, Henry JA. Monoclonal plasmacytic ulcerative stomatitis. A plasma cell dyscrasia? *Oral Surg Oral Med Oral Pathol* 1993; 75(4): 483-7.

7. Webb CJ, Makura ZG, Jackson SR, Helliwell T. Primary extramedullary plasmacytoma of the tongue base. Case report and review of the literature. *ORLJ Otorhinolaryngol Relat Spec* 2002; 64: 278-80.
8. Potter M. Perspectives on the origins of multiple myeloma and plasmacytomas in mice. *Hematol Oncol Clin North Am* 1992; 6(2): 211-23.
9. Salmon SE, Cassady JR. Plasma cell neoplasms. In: *Cancer: principle and practice of oncology*. 5th ed. Philadelphia, PA, Lippincott-Raven; 1998. p2344-87.
10. Kapadia SB, Desai U, Cheng VS. Extramedullary plasmacytoma of the head and neck: A clinicopathologic study of 20 cases. *Medicine* 1982; 61(5): 317-29.
11. Woodruff RK, Whittle JM, Malpas JS. Solitary plasmacytoma. I: Extramedullary soft tissue plasmacytoma. *Cancer* 1979; 43(6): 2340-3.