

Computed Tomographic Characterization of Traumastem—A New Oxidized Cellulose Hemostatic Agent

Paul B. Lewis¹, Scott T. Wilson², Dustin R. Kentala², John Barry³, and Kevin M. Lewis³

¹Department of Radiology, Mercy Rockford Health System, Rockford, Illinois; ²MPI Research, Inc., Mattawan, Michigan; and ³Baxter Healthcare Corporation, Deerfield, Illinois

Corresponding Author:

Kevin M. Lewis, DVM

Baxter Healthcare Corporation, One Baxter Parkway,
Deerfield, IL 60015

E-mail: kevin_lewis@baxter.com

Key Words: oxidized cellulose, gossypiboma, diagnostic errors, computed tomography, surgical

Abbreviations: Oxidized regenerated cellulose (ORC), computed tomography (CT), oxidized nonregenerated cellulose (ONC), subcutaneous (SC), magnetic resonance imaging (MRI)

ABSTRACT

Oxidized regenerated cellulose (ORC) is a commonly used surgical hemostatic agent. When retained at the surgical site, it is frequently misdiagnosed on postoperative computed tomography (CT) images as an abscess or a recurrent tumor. Oxidized nonregenerated cellulose (ONC) is a new, more effective version of ORC. It is more effective because of its unorganized fiber structure and greater material density, which may also alter its appearance on CT images relative to ORC. This image report compares the CT characteristics of ONC and ORC. A rabbit's bilateral femoral arteries were punctured to model peripheral vascular surgery. ORC was used to treat 1 of the femoral artery punctures and ONC to treat the contralateral puncture. Noncontrast CT imaging was performed immediately following surgery (day 0) and on postoperative day 14. On day 0, both ORC and ONC were isoattenuating relative to muscle and hyperattenuating to fat, although ONC appears more homogenous. On day 14, neither ORC nor ONC was clearly identifiable. Thus, postoperative retention of ONC can obscure immediate postoperative CT interpretation and, similar to ORC, lead to an erroneous diagnosis of an abscess. By day 14, ONC retention may not obscure CT interpretation. In noncontrast CT imaging, ONC appears more homogeneous than ORC, but is otherwise indistinguishable. The greater homogeneity of ONC may be caused by the unorganized fiber structure or greater material density. Intraoperative use of ONC should be clinically investigated before radiographically diagnosing a postoperative abscess or recurrent tumor.

INTRODUCTION

The interpretation and diagnostic utility of postoperative computed tomography (CT) imaging can be complicated by the presence of absorbable biomaterials (1-5). A commonly misdiagnosed biomaterial is oxidized regenerated cellulose (ORC) (1).

ORC is a widely used hemostatic agent in nearly all surgical specialties. ORC induces hemostasis by means of a primary local hemostyptic action and secondary activation of platelets to form a temporary platelet plug (6). Although ORC can be removed once hemostasis is achieved, it can also be left at the surgical site and degraded through normal wound healing (7). In a recent prospective, blinded study investigating the interpretation of CT images of patients treated with ORC, only 2 of 18 patients (11%) were accurately diagnosed as being treated with ORC (8). Interpretation of the remaining 16 patients was inconclusive, or ORC was misdiagnosed as an abscess, a hematoma, a lymphocele or a collection with hydroaeric levels.

Oxidized nonregenerated cellulose (ONC) is an alternate form of oxidized cellulose that was first used clinically in 2011

(9). ONC lacks organized cellulose fibers and has higher material density, which can give it a different appearance from ORC on CT images. Unorganized cellulose fibers of ONC have been shown to provide superior hemostasis relative to ORC (6). As the use of ONC becomes more widespread in surgical procedures, understanding the imaging characteristics of ONC on CT will aid in accurate interpretation and diagnosis.

This image report describes the postoperative noncontrast CT appearance of ONC and compares it with that of ORC when used to treat a femoral artery needle puncture in a rabbit at 0 and 14 days after implantation.

MATERIAL AND METHODS

Oxidized Cellulose Hemostatic Agents

Tabotamp (Ethicon, Inc., Somerville, New Jersey), also known as Surgicel® in North America, is the ORC used in this study. Traumastem (Baxter Healthcare SA, Zurich, Switzerland), also known as Celstat in North America, is the ONC used in this study.

Animal Model

All animal activities were performed according to the United States Animal Welfare Act and The Guide for the Care and Use of Laboratory Animals in an institution accredited by the Association for Assessment and Accreditation of Laboratory Animal Care International following Institutional Animal Care and Use Committee Approval.

A rabbit femoral artery puncture model mimicking peripheral vascular surgery was performed in a 2.8-kg New Zealand White female rabbit (6). A fentanyl patch was placed 1 day before surgery. On the day of surgery, acepromazine (0.1 mg/kg, subcutaneously [SC]), glycopyrrolate (0.01 mg/kg, SC), and ketamine (25 mg/kg, SC) were administered to the animal. Following tracheal intubation, anesthesia was maintained using isoflurane.

The femoral arteries were exposed and isolated. An RB-1 curved tapered needle with 1-cm of 5-0 polyglactin 910 suture was passed through each artery in a proximal-to-distal direction. The needle entrance and exit holes were allowed to bleed freely for 6 seconds and then treated with a single application of 2 layers of 3- × 3-cm oxidized cellulose.

ORC was applied to the right femoral artery and ONC to the left femoral artery according to a randomization procedure using 30 seconds of digital pressure. Once hemostasis was achieved, the incisions were closed in an identical, routine fashion. The focus of this investigation was postoperative imaging, so hemostatic success was not measured.

Following postoperative imaging on the day of surgery (day 0), the animal was recovered and received meloxicam once daily for 3 days (0.2 mg/kg, intramuscularly). On day 14, the same anesthetic protocol was used for reimaging. After imaging, the animal was euthanized with pentobarbital (50 mg/kg, intravenously).

CT Imaging

With the rabbit in the dorsal position, noncontrast CT imaging was performed after surgery and 14 days postoperatively (Figure 1). These time points were selected based on previous research by Pampal et al. (10). A preoperative CT was not conducted, as the interest of this report was the appearance of the implanted material. CT imaging was performed using a multiple-detector-row CereTom™ scanner (NeuroLogica Corporation, Danvers, Massachusetts).

No intravenous contrast was administered so that the retained oxidized cellulose material can be identified without obscuration (ie, beam hardening or scatter) by the intimately adjacent intravascular iodine contrast (11). Contiguous 160-mm (day 14) and 260-mm (day 0) step-and-shoot data acquisition of the pelvis was conducted from the iliac crests to the feet with 140-kVp, 4-mAs, and a field of view radius of 126.656-mm. The images were acquired to minimize subject radiation dose to as low as reasonably achievable while maintaining diagnostic imaging quality. Coronal images were generated with 0.625-mm thickness.

RESULTS

On day 0, the oxidized cellulose hemostatic agents are seen medial to the femoral arteries with symmetrical beam attenua-

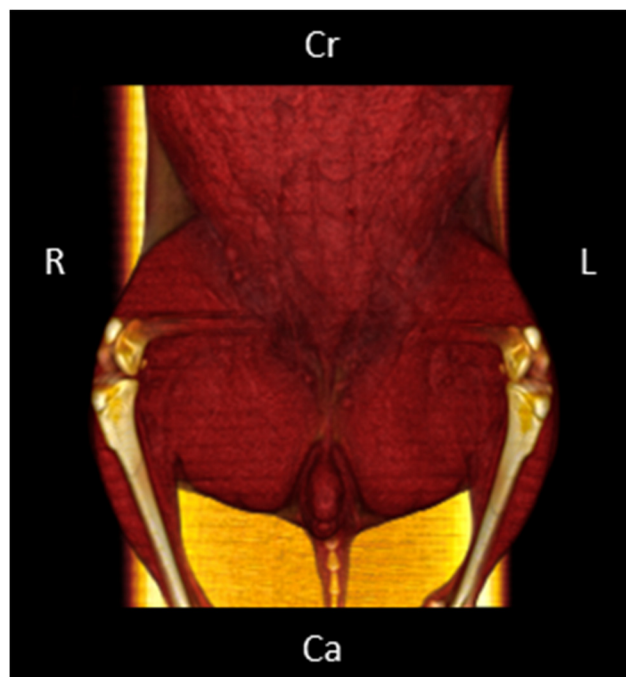


Figure 1. The animal was placed in dorsal recumbency, equivalent to the human supine position, for the noncontrast computed tomography (CT) imaging immediately following surgery and 14 days after surgery (Cr, Cranial; R, right; L, left; Ca, Caudal). The rabbit femurs are naturally positioned in a flexed, or orthogonal, position relative to that of humans.

tion and with the same attenuation as observed in the thigh muscles (Figure 2). The appearance of ORC in the right groin is more heterogeneous than that of ONC in the left groin. Surgical sutures are seen in both groins. There is minimal fat stranding and foci of air in the regions of interest, but these findings are to be expected in the immediate postoperative period with or without the use of hemostatic agents.

On day 14, neither of the oxidized cellulose hemostatic agents is definitively identifiable (Figure 3). No femoral pseudoaneurysms are appreciated in either groin. In comparison with the immediate postoperative images, there are expected changes of normal wound healing, including some skin thickening and reduction in local fat stranding. There are no foci of air along either femoral artery on the 14-day postoperative image. There are again focal hyperattenuating surgical sutures in both groins. No adverse tissue reactions are seen.

DISCUSSION

Based on this investigation, ONC has a more homogeneous appearance compared with ORC in noncontrast CT imaging immediately following surgery that is not identifiable on postoperative CT images on day 14. The difference between the oxidized cellulose on day 0 is likely because of the different density structures. The different presentations of oxidized cel-

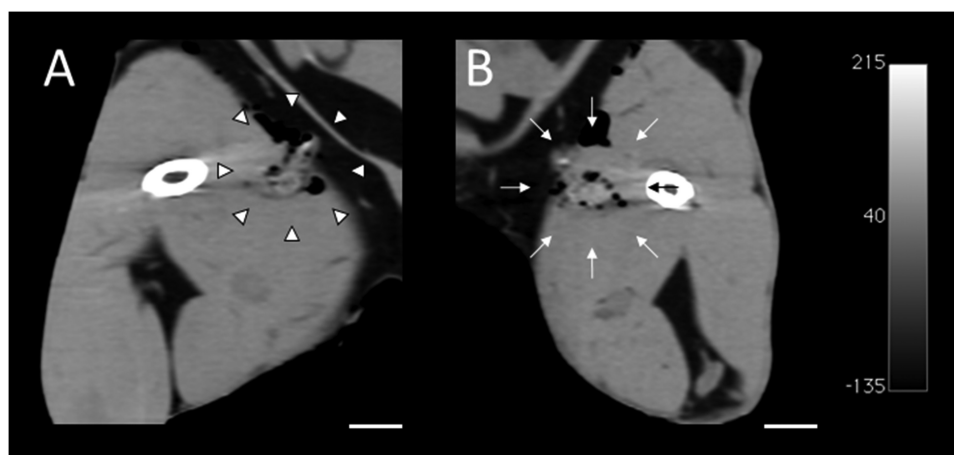


Figure 2. Tabotamp (A), oxidized regenerated cellulose (ORC), and Traumastem (B), oxidized nonregenerated cellulose (ONC), appear medial to the femurs with symmetrical density that is isodense to the surrounding muscle on CT images immediately following surgery. Coronal section of a rabbit with bilateral femoral artery needle punctures treated with Tabotamp (arrow heads) and Traumastem (arrows) (scale bar, 5-mm).

lulose over time, however, are not uncommon and represent their 2-phase degradation process. In the first phase, polyuronic acid is solubilized within 18 hours, whereas in the second phase, fibrous material is phagocytized and hydrolyzed by local macrophage within 4 weeks (6).

During the first phase, ORC can be misdiagnosed as a bowel leakage (12), obstructive mass (13), hematoma (14), mediastinitis (15) or, most frequently, abscess (16-19). These misdiagnoses are attributed to the appearance of ORC as a mixed- or low-attenuation mass with focal collections of gas that is absent of air-fluid levels and contrast enhancement in or near the operative site on immediate postoperative CT scans (1), which is similar to their appearance in this investigation. Given the comparable appearance to ORC, ONC can be misdiagnosed during the acute postoperative period. As oxidized cellulose is degraded or encapsulated, its appearance may vary. An interesting follow-up study should investigate its appearance more frequently in the postoperative period and in different anatomical locations (eg, intracranial, intrathoracic, or retroperitoneal

sites). Further, serial observations in multiple animals or clinical patients should be used to investigate its varying presentations.

During the second phase, oxidized cellulose degradation and wound healing can be delayed depending on the amount of material used, blood flow, and tissue bed. When delayed too long, ORC forms a fibrous-encapsulated sterile granuloma, that is, a gossypiboma or “Surgiceloma.” In this phase, ORC is misdiagnosed as a tumor (20-24). This misdiagnosis is attributed to the appearance of ORC as a heterogeneous soft tissue mass with or without rim enhancement and with variable to no contrast enhancement. In this study, the quantity of ORC and ONC used was insufficient to form a gossypiboma. Because a gossypiboma was not induced, this is a potential direction for further investigation. Similarly, the appearance of ONC in contrast-enhanced CT imaging or less conventional modalities for soft tissue postoperative imaging (eg, plain radiography, ultrasonography, and magnetic resonance imaging [MRI]) can be investigated.

Oxidized cellulose has lower attenuation than a hematoma and a simpler appearance. Abscesses generally have scattered,

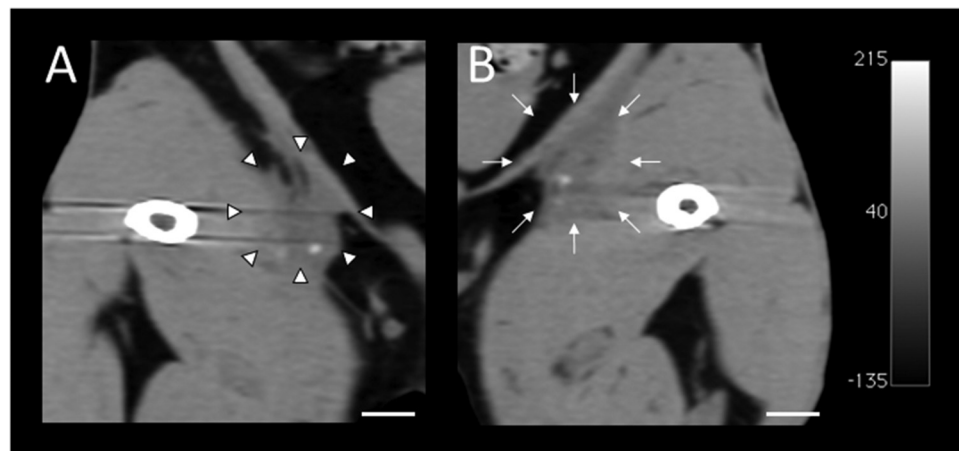


Figure 3. Neither Tabotamp (A), oxidized regenerated cellulose, nor Traumastem (B), oxidized nonregenerated cellulose, appear at the surgical site on CT images 14 days following surgery. Coronal section of a rabbit with bilateral femoral artery needle punctures treated with Tabotamp (arrow heads) and Traumastem (arrows) (scale bar, 5-mm).

variably sized, and patterned foci of gas with air–fluid levels and rim enhancement (25). Such distinguishing CT characteristics are suggestive but not confirmatory. Radiographic and sonographic examinations do not aid in the differentiation of oxidized cellulose from the above misdiagnoses (26, 27). Because of superior contrast between tissues, MRI may provide a more definitive diagnosis of oxidized cellulose postoperatively. Oto et al. described ORC to be hypointense in the early postoperative period on T2-weighted images, but variable thereafter (28).

Pampal et al. performed an exhaustive study comparing attenuation of ORC with normal tissue on CT and signal intensity on MRI within the intraperitoneal and retroperitoneal cavities of guinea pigs (10). Based on their CT findings, ORC is consistently hypoattenuating relative to paravertebral muscles and liver parenchyma when placed in the intraperitoneal space and hyperattenuating relative to fat when placed in the retro-

peritoneal space. In comparison with Pampal et al., this investigation shows that ORC is hyperattenuating to fat and overall isoattenuating to thigh musculature. The difference between the findings can be because of variation in the imaging technique, radiation dose, and anatomic location between the studies.

CONCLUSION

Although the CT imaging characteristics of ORC have been described over several years, this is the first report of the non-contrast CT imaging characteristics of ONC. This investigation characterized the appearance of ONC in noncontrast CT imaging as being similar to that of ORC. The only distinction between the two was that ONC appeared more homogenous. The homogeneity of ONC is likely because of the unorganized fiber structure or greater material density.

ACKNOWLEDGMENTS

This study was solely supported by Baxter Healthcare Corporation without influence on the study design; on the collection, analysis, and interpretation of data; on the writing of the manuscript; and on the decision to submit the manuscript for publication. The authors thank their technical and administrative staffs.

REFERENCES

- Young ST, Paulson EK, McCann RL, Baker ME. Appearance of oxidized cellulose (Surgicel) on postoperative CT scans: similarity to postoperative abscess. *AJR Am J Roentgenol.* 1993;160(2):275–277.
- Ruiz-Zafra J, Rodríguez-Fernández A, Sánchez-Palencia A, Cueto A. Surgical adhesive may cause false positives in integrated positron emission tomography and computed tomography after lung cancer resection. *Eur J Cardiothorac Surg.* 2013;43(6):1251–1253.
- Lauvin MA, Zemmoura I, Cazals X, Cottier JP. Delayed cauda equina compression after spinal dura repair with BioGlue: magnetic resonance imaging and computed tomography aspects of two cases of “glue-oma.” *Spine J.* 2015;15(1):e5–e8.
- Sandrasegaran K, Lall C, Rajesh A, Maglente DT. Distinguishing gelatin bioabsorbable sponge and postoperative abdominal abscess on CT. *Am J Roentgenol.* 2005;184(2):475–480.
- Kacher DF, Frerichs K, Pettit J, Campbell PK, Meunch T, Norbash AM. DuraSeal magnetic resonance and computed tomography imaging: evaluation in a canine craniotomy model. *Neurosurgery.* 2006;58(1 Suppl):ONS140–147.
- Lewis KM, Spazierer D, Urban MD, Lin L, Redl H, Goppelt A. Comparison of regenerated and non-regenerated oxidized cellulose hemostatic agents. *Eur Surg.* 2013;45:213–220.
- Hutchinson RW, George K, Johns D, Craven L, Zhang G, Shnoda P. Hemostatic efficacy and tissue reaction of oxidized regenerated cellulose hemostats. *Cellulose.* 2013;20(1):537–545.
- Frati A, Thomassin-Naggara I, Bazot M, Daraï E, Rouzier R, Chéreau E. Accuracy of diagnosis on CT scan of Surgicel® Fibrillar: results of a prospective blind reading study. *Eur J Obstet Gynecol Reprod Biol.* 2013;169(2):397–401.
- Habal P, Omran N, Mand’ák J, Simek J, Stetina M. Controlled hemostasis in thoracic surgery using drugs with oxidized cellulose. *Acta Medica (Hradec Kralove).* 2011;54(4):153–156.
- Pampal A, Ataç GK, Özen İO, Keskin ZS, Demiroğulları B, Gündoğdu S. Sponge in the belly: postoperative imaging findings of oxidised cellulose (Surgicel®). *Turk J Med Sci.* 2013;43:569–573.
- Boas FE and Fleischmann D. CT artifacts: causes and reduction techniques. *Imaging Med.* 2012;4(2):229–240.
- Janjan D, Dandolu V, Miller M, Dunton C. Oxidized regenerated cellulose presenting as a postoperative cyst: a case report. *J Reprod Med.* 2007;52(12):1109–1110.
- Syburra T, Weishaupt D, Graves K, Genoni M. Oxidized regenerated cellulose in cardiac computer tomography imaging. *Interact Cardiovasc Thorac Surg.* 2011;12(4):626–627.
- Stringer MD, Dasgupta D, McClean P, Davison S, Ramsden W. “Surgicel abscess” after pediatric liver transplantation: a potential trap. *Liver Transpl.* 2003;9(2):197–198.
- Alves Júnior L, Vicente WV, Ferreira CA, Manso PH, Arantes LR, Pinheiro KS, Luciano PM, Rodrigues AJ, Evora PR. Surgical packing and an erroneous diagnosis of mediastinitis in a neonate. *Tex Heart Inst J.* 2010;37(1):116–118.
- Arnold AC, Sodickson. Postoperative Surgicel mimicking abscesses following cholecystectomy and liver biopsy. *Emerg Radiol.* 2008;15(3):183–185.
- Royds J, Kieran S, Timon C. Oxidized cellulose (Surgicel) based reaction post thyroidectomy mimicking an abscess: A case report. *Int J Surg Case Rep.* 2012;3(7):338–339.
- Turley BR, Taupmann RE, Johnson PL. Postoperative abscess mimicked by Surgicel. *Abdom Imaging.* 1994;19(4):345–346.
- Ibrahim MF, Aps C, Young CP. A foreign body reaction to Surgicel mimicking an abscess following cardiac surgery. *Eur J Cardiothorac Surg.* 2002;22(3):489–490.
- Wang H, Chen P. Surgicel(R) (oxidized regenerated cellulose) granuloma mimicking local recurrent gastrointestinal stromal tumor: A case report. *Oncol Lett.* 2013;5(5):1497–1500.
- Sandhu GS, Elexpuru-Camiruaga JA, Buckley S. Oxidized cellulose (Surgicel) granulomata mimicking tumour recurrence. *Br J Neurosurg.* 1996;10(6):617–619.
- Somani BK, Kasthuri RS, Shave RM, Emtage LA. Surgicel granuloma mimicking a renal tumour. *Surgery.* 2006;139(3):451.
- Agarwal MM, Mandal AK, Agarwal S, Lal A, Prakash M, Mavuduru R, Singh SK. Surgicel granuloma: unusual cause of “recurrent” mass lesion after laparoscopic nephron-sparing surgery for renal cell carcinoma. *Urology.* 2010;76(2):334–335.
- Deger RB, LiVolsi VA, Noumoff JS. Foreign body reaction (gossypiboma) masking as recurrent ovarian cancer. *Gynecol Oncol.* 1995;56(1):94–96.
- Shah PA, Cunningham SC, Morgan TA, Daly BD. Hepatic gas: widening spectrum of causes detected at CT and US in the interventional era. *Radiographics.* 2011;31(5):1403–1413.
- Melamed JW, Paulson EK, Kliewer MA. Sonographic appearance of oxidized cellulose (Surgicel): pitfall in the diagnosis of postoperative abscess. *J Ultrasound Med.* 1995;14(1):27–30.
- Eltayar AR, Labruzzo C, Watson MJ, Hakim NS. Sonographic appearance of oxidised cellulose (Surgicel): pitfall in the diagnosis of renal vein thrombosis in a transplant kidney. *Int Surg.* 2000;85(3):270–271.
- Oto A, Remer EM, O’Malley CM, Tkach JA, Gill IS. MR characteristics of oxidized cellulose (Surgicel). *AJR Am J Roentgenol.* 1999;172(6):1481–1484.