



## Case Report

# Differential expression of estrogen receptor $\alpha$ and progesterone receptor in the normal and cryptorchid testis of a dog

Hyo Young Jung<sup>1,5</sup>, Dae Young Yoo<sup>1,5</sup>, Young Kwang Jo<sup>2,5</sup>, Geon A Kim<sup>2,5</sup>,  
Jin Young Chung<sup>3</sup>, Jung Hoon Choi<sup>4</sup>, Goo Jang<sup>2,5,6,7,\*</sup>, In Koo Hwang<sup>1,5,\*</sup>

<sup>1</sup>Department of Anatomy and Cell Biology, College of Veterinary Medicine, Seoul National University, Seoul 08826, Korea

<sup>2</sup>Laboratory of Theriogenology and Biotechnology, Department of Veterinary Clinical Sciences, College of Veterinary Medicine, Seoul National University, Seoul 08826, Korea

<sup>3</sup>Department of Veterinary Internal Medicine and Geriatrics, College of Veterinary Medicine, Kangwon National University, Chuncheon 24341, Korea

<sup>4</sup>Department of Anatomy, College of Veterinary Medicine, Kangwon National University, Chuncheon 24341, Korea

<sup>5</sup>BK21 PLUS Program for Creative Veterinary Science Research, and Research Institute for Veterinary Science, Seoul National University, Seoul 08826, Korea

<sup>6</sup>Institute of Green Bio Science & Technology, Seoul National University, Pyeong Chang, Kangwon do, Korea

<sup>7</sup>Emergence Center for Food-Medicine Personalized Therapy System, Advanced Institutes of Convergence Technology, Seoul National University, Gyeonggi-do, Korea

Descending of the testes is an important process for spermatogenesis and cryptorchidism is one of the most relevant genital defects in dogs. In a previous study, we observed abnormal morphology and proliferation of Sertoli cells in a cryptorchid testis. In the present study, we investigated the expression of estrogen and progesterone receptors in the normal and cryptorchid testis of a dog. Elective orchidectomy was performed on the dog's abdominal right testis (undescended, cryptorchid) and scrotal left testis (descended, normal). In the normal testis, estrogen receptor  $\alpha$  immunoreactivity was detected in Leydig cells alone, while estrogen receptor  $\alpha$  immunoreactivity in the cryptorchid testis was significantly prominent in the Sertoli cells as well. In addition, progesterone receptor immunoreactivity in the control testis was detected in the spermatids, but was not detected in the cryptorchid testis. This result suggests that unilateral cryptorchidism causes increases of estrogen receptor  $\alpha$  expression in Sertoli cells.

**Keywords:** Dog, estrogen receptor  $\alpha$ , progesterone receptor, Sertoli cells, unilateral cryptorchidism

Received 16 February 2016; Revised version received 27 April 2016; Accepted 26 May 2016

Descending of the testes is one of an important processes in the development of male reproductive organs. There is growing evidence from clinical and epidemiological studies in humans and dogs for an increasing incidence of male reproductive disorders including cryptorchidism. In dogs, the incidence of cryptorchidism is variable among breeds, but is most

relevant in Chihuahuas and Boxers with 20-30% incidence [1].

Abnormal estrogen levels can block transabdominal descent of testes and therefore are one of most important factors in this process [2-4] and abnormal estrogen action has been implicated as a possible cause for sporadic cryptorchidism in humans [5] and mice [6-8].

\*Corresponding authors: Goo Jang, Laboratory of Theriogenology and Biotechnology, Department of Veterinary Clinical Sciences, College of Veterinary Medicine, Seoul National University, Seoul 08826, Korea  
Tel: +82-2-8801280; E-mail: [snujang@snu.ac.kr](mailto:snujang@snu.ac.kr)  
In Koo Hwang, Department of Anatomy and Cell Biology, College of Veterinary Medicine, Seoul National University, Seoul 08826, Korea  
Tel: +82-2-8801271; E-mail: [vetmed2@snu.ac.kr](mailto:vetmed2@snu.ac.kr)

This is an Open Access article distributed under the terms of the Creative Commons Attribution Non-Commercial License (<http://creativecommons.org/licenses/by-nc/3.0>) which permits unrestricted non-commercial use, distribution, and reproduction in any medium, provided the original work is properly cited.

Estrogen is mainly produced in the adipose tissue, but its receptors (estrogen receptor  $\alpha$  and  $\beta$ ; ER $\alpha$  and ER $\beta$ ) are localized in most cell types in the body including in the testes [9], which suggests an important role for estrogen in regulating testicular cell function and reproductive events. Deletion of ER $\alpha$  causes infertility in male mice, while the disruption of ER $\beta$  does not yield infertile phenotypes, suggesting ER $\alpha$  is essential for male reproduction [10,11] but ER $\beta$  has a less important function in the testes [12-14].

It has been reported that ER $\alpha$  is present in the Sertoli cells of multiple species including hystricognath rodents, rats, cats, boars, pigs, and humans [15-23]. However, there is conflicting data about the expression of ER $\alpha$  in the testes and few studies have been conducted examining the localization of ER $\alpha$ -immunoreactive structures in the testes. In the present study, we investigated the localization of ER $\alpha$  and progesterone receptor (PR) immunoreactivity in the normal testis and cryptorchid testis of a dog.

An 18-month-old German Shepherd with unilateral cryptorchidism was referred to the Seoul National University Veterinary Teaching Hospital, South Korea for elective orchidectomy as explained in a previous study [24]. The left testis was present within the scrotum but the right testis was not palpable in the scrotum or inguinal area. Laparotomy revealed the cryptorchid testis in the right abdominal region. Both testes were surgically removed.

For histological analysis, both testes were fixed in neutral buffered formalin for 2 days and dehydrated with graded concentrations of alcohol before being embedded in paraffin. Paraffin-embedded tissues were sectioned into 3- $\mu$ m coronal sections using a microtome (Leica Microsystems GmbH, Wetzlar, Germany) and were mounted onto silane-coated slides (Muto Pure Chemicals Co., Ltd, Tokyo, Japan).

To ensure that the immunohistochemical data were comparable between control and cryptorchid testis, the sections were carefully processed under the same conditions. The sections were hydrated and treated with 0.3% hydrogen peroxide (H<sub>2</sub>O<sub>2</sub>) in phosphate-buffered saline (PBS) for 30 min. For antigen retrieval, the sections were placed in 400-mL jars filled with citrate buffer (pH 6.0) and heated in a 2100-retriever (Prestige Medical, Lancashire, UK). After antigen retrieval, slides were allowed to cool at room temperature and were washed in PBS. After washing, the sections were

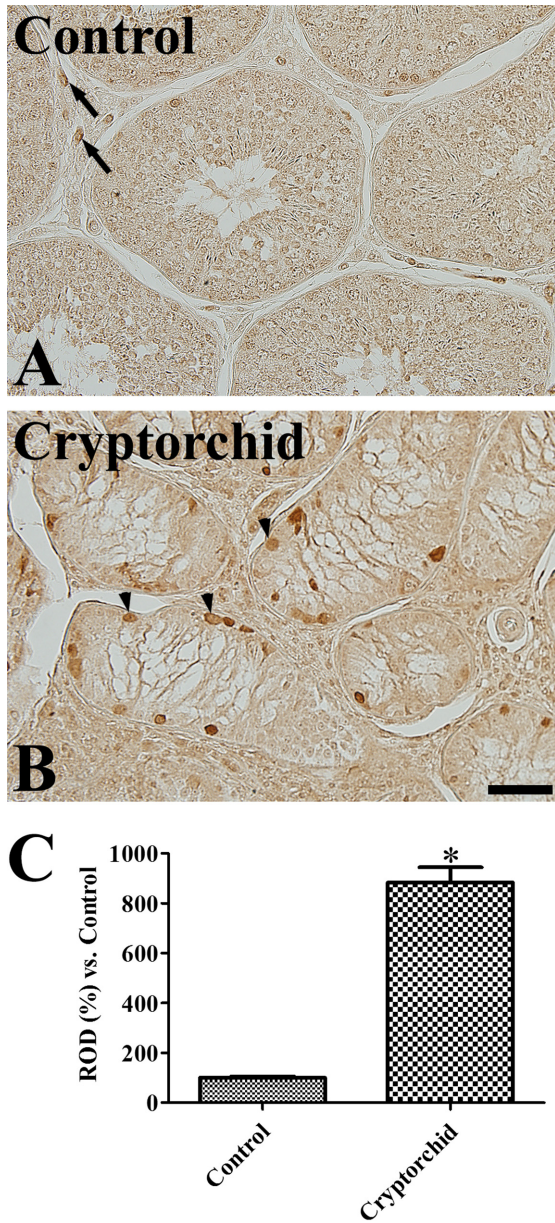
incubated in 10% normal goat serum in PBS for 30 min. They were then incubated with rabbit anti-ER $\alpha$  antibody (1:200; Abcam, Cambridge, UK) or mouse anti-PR antibody (1:200, Abcam) for 48 h at 4°C. They were subsequently exposed to biotinylated goat anti-rabbit IgG, or anti-mouse IgG (diluted 1:200, Vector Laboratories, Inc., Burlingame, CA, USA), and streptavidin peroxidase complex (diluted 1:200, Vector Laboratories). Thereafter, the sections were visualized with 3,3-diaminobenzidine tetrahydrochloride (Sigma, St. Louis, MO, USA) in 0.1 M Tris-HCl buffer (pH 7.4).

Analysis of the regions of interest in the testis was performed using an image analysis system. Images were calibrated into an array of 512 $\times$ 512 pixels corresponding to a tissue area of 140  $\mu$ m $\times$ 140  $\mu$ m (40 $\times$  primary magnification). Each pixel resolution was 256 gray levels. The intensity of ER $\alpha$  and PR immunoreactivity was evaluated by relative optical density (ROD), which was obtained after transformation of the mean gray level using the formula: ROD=log(256/mean gray level). ROD of background was determined in unlabeled portions and this value was subtracted for correction, yielding high ROD values in the presence of preserved structures and low values after structural loss using ImageJ software v. 1.50 (National Institutes of Health, Bethesda, MD, USA). A ratio of the ROD was calibrated as percentage compared to control.

In the control testis, ER $\alpha$  immunoreactivity was observed in the interstitial space of seminiferous tubules. Based on their location, ER $\alpha$  immunoreactive structures were thought to be Leydig cells of testis (Figure 1A). In the cryptorchid testis, ER $\alpha$  immunoreactivity was detected in the basal part of seminiferous tubules as well as in the interstitial space of tubules. These cells are judged to be Sertoli cells and Leydig cells, respectively, based on their morphology (Figure 1B). ER $\alpha$  immunoreactivity in the cryptorchid testis was significantly increased compared to the control testis (Figure 1C).

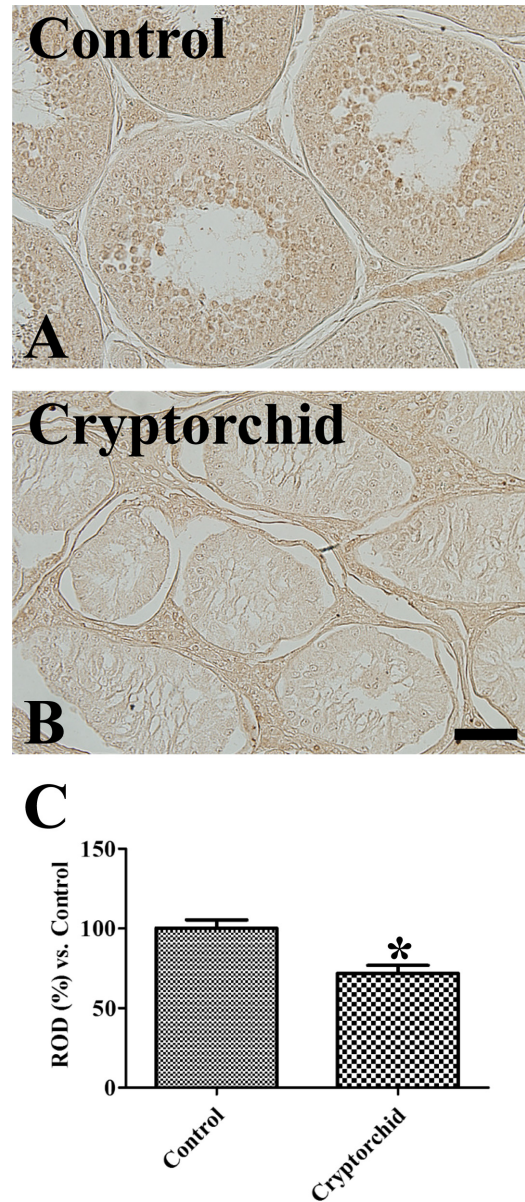
Weak PR immunoreactivity was observed in the spermatids of the control testis, but was not observed in any other structures (Figure 2A). In the cryptorchid testis, PR immunoreactivity was not detected in any structures (Figure 2B) and PR immunoreactivity was significantly decreased compared to the control testis (Figure 2C).

Spermatogenic failure is the one of the most serious complications in cryptorchidism. In a previous study, we identified morphological abnormalities in cryptorchid



**Figure 1.** Immunohistochemistry for ER $\alpha$  in the control (A) and cryptorchid (B) testis. Note that ER $\alpha$  immunoreactivity is found in the Leydig cells (arrows) of the control testis, while ER $\alpha$  immunoreactivity is also remarkably detected in the Sertoli cells (arrowheads) of the cryptorchid testis. Scale bar=50  $\mu$ m. (C) Relative optical density (ROD) of ER $\alpha$  immunoreactivity per section is expressed as percentage of control group (10 sections; \* $P$ <0.05, control vs. cryptorchid group). All data are represented as the mean  $\pm$  SEM.

testis and increased cell proliferation in cryptorchid Sertoli cells [24]. In the present study, we observed the localization of ER $\alpha$  and PR in the testis of control and cryptorchid testis belonging to the same dog. ER $\alpha$  immunoreactivity was weakly detected in the Leydig cells of control testis. However, we did not observe any



**Figure 2.** Immunohistochemistry for PR in the control (A) and cryptorchid (B) testis. Note that PR immunoreactivity is only detected in spermatids of control testis. Scale bar=50  $\mu$ m. (C) Relative optical density (ROD) of PR immunoreactivity per section is expressed as percentage of control group (10 sections; \* $P$ <0.05, control vs. cryptorchid group). All data are represented as the mean  $\pm$  SEM.

other structures with ER $\alpha$  immunoreactivity. There have been contradictory reports about the expression of ER $\alpha$  in human testes. Some studies showed ER $\alpha$  mRNA [25] and protein [26] were not detected in the human testis, nor in primates such as marmoset and macaque [26]. However, Pelletier and El-Alfy [27] observed ER $\alpha$  in human Leydig cells and Filipiak *et al.* [21] demonstrated that ER $\alpha$  immunostaining was found in the cytoplasm of

Sertoli and Leydig cells in humans. Differences we identified in the localization of ER $\alpha$  immunostaining in our study may be closely associated with the expression patterns of ER $\alpha$  in human testes. In the present study, we firstly reported comparison of ER $\alpha$  expressions in intact and cryptorchid testis of unilateral cryptorchid dog.

ER $\alpha$  immunoreactivity was prominently increased in the cryptorchid testis, especially in the Sertoli cells. Several lines of evidence demonstrate that ER $\alpha$  protein is present in the spermatids and Sertoli cells of descended rat testes [28], as well as in the mesothelial layer of paratesticular tissues of undescended human male testes [29]. In addition, estradiol levels were higher in the cryptorchid testes than in normal testes as measured by radioimmunological analysis of testicular tissue [28,30]. The increased levels of estradiol may upregulate ER $\alpha$  gene expression in the cryptorchid testis [28,31] and potentiate the effects of estradiol in Sertoli cells.

The role of ER $\alpha$  in the testis has not been fully elucidated. However, transplanted germ cells lacking ER $\alpha$  develop normally in wildtype seminiferous tubules, and can yield offspring by fertilizing oocytes [32,33]. ER $\alpha$  could help provide a favorable environment for gametes to develop and mature [10], and estrogen-dependent ER $\alpha$  action is required for germ cell survival, most likely involving the support of Sertoli cell function [10]. However, in the present study, ectopic expression of ER $\alpha$  in the Sertoli cells of cryptorchid testis may be closely related to the cell proliferation of Sertoli cells, which could progress to Sertoli cell tumors. This result was supported by a previous study that found ER $\alpha$  is frequently expressed in Sertoli-Leydig cell tumors [34].

In the present study, we did not find any significant differences in PR expression between the control testis and cryptorchid testis. This result was supported by a previous study that found cryptorchidism failed to express PR even though some of these procedures are known to induce progesterone receptor expression in estradiol-target tissues [35].

In conclusion, unilateral cryptorchidism significantly increases ER $\alpha$  immunoreactivity, not but PR immunoreactivity, in the Sertoli cells of the cryptorchid testis, and this increase may be associated with proliferation of Sertoli cells in the cryptorchid testis.

## Acknowledgments

This result was supported by BK21 PLUS Program for

Creative Veterinary Science Research, Research Institute for Veterinary Science and College of Veterinary Medicine, Seoul National University.

**Conflict of interests** The authors declare that there is no financial conflict of interests to publish these results.

## References

1. Yates D, Hayes G, Heffernan M, Beynon R. Incidence of cryptorchidism in dogs and cats. *Vet Rec* 2003; 152(16): 502-504.
2. Nef S, Parada LF. Cryptorchidism in mice mutant for *Insl3*. *Nat Genet* 1999; 22(3): 295-299.
3. Zimmermann S, Steding G, Emmen JM, Brinkmann AO, Nayernia K, Holstein AF, Engel W, Adham IM. Targeted disruption of the *Insl3* gene causes bilateral cryptorchidism. *Mol Endocrinol* 1999; 13(5): 681-691.
4. Hutson JM, Baker M, Terada M, Zhou B, Paxton G. Hormonal control of testicular descent and the cause of cryptorchidism. *Reprod Fertil Dev* 1994; 6(2): 151-156.
5. Gill WB, Schumacher GF, Bibbo M, Straus FH 2nd, Schoenberg HW. Association of diethylstilbestrol exposure in utero with cryptorchidism, testicular hypoplasia and semen abnormalities. *J Urol* 1979; 122(1): 36-39.
6. Grocock CA, Charlton HM, Pike MC. Role of the fetal pituitary in cryptorchidism induced by exogenous maternal oestrogen during pregnancy in mice. *J Reprod Fertil* 1988; 83(1): 295-300.
7. Hadziselimovic F, Girard J. Pathogenesis of cryptorchidism. *Horm Res* 1977; 8(2): 76-83.
8. Khan SA, Ball RB, Hendry WJ 3rd. Effects of neonatal administration of diethylstilbestrol in male hamsters: disruption of reproductive function in adults after apparently normal pubertal development. *Biol Reprod* 1998; 58(1): 137-142.
9. Akingbemi BT. Estrogen regulation of testicular function. *Reprod Biol Endocrinol* 2005; 3: 51.
10. Couse JF, Korach KS. Estrogen receptor null mice: what have we learned and where will they lead us? *Endocr Rev* 1999; 20(3): 358-417.
11. Walker VR, Korach KS. Estrogen receptor knockout mice as a model for endocrine research. *ILAR J* 2004; 45(4): 455-461.
12. Carreau S, Hess RA. Oestrogens and spermatogenesis. *Philos Trans R Soc Lond B Biol Sci* 2010; 365(1546): 1517-1535.
13. Couse JF, Hewitt SC, Bunch DO, Sar M, Walker VR, Davis BJ, Korach KS. Postnatal sex reversal of the ovaries in mice lacking estrogen receptors alpha and beta. *Science* 1999; 286(5448): 2328-2331.
14. Antal MC, Krust A, Chambon P, Mark M. Sterility and absence of histopathological defects in nonreproductive organs of a mouse ERbeta-null mutant. *Proc Natl Acad Sci U S A* 2008; 105(7): 2433-2438.
15. Royer C, Lucas TF, Lazari MF, Porto CS. 17Beta-estradiol signaling and regulation of proliferation and apoptosis of rat Sertoli cells. *Biol Reprod* 2012; 86(4): 108.
16. Ramesh R, Pearl CA, At-Taras E, Roser JF, Berger T. Ontogeny of androgen and estrogen receptor expression in porcine testis: effect of reducing testicular estrogen synthesis. *Anim Reprod Sci* 2007; 102(3-4): 286-299.
17. Cavaco JE, Laurentino SS, Barros A, Sousa M, Socorro S. Estrogen receptors alpha and beta in human testis: both isoforms are expressed. *Syst Biol Reprod Med* 2009; 55(4): 137-144.
18. Lucas TF, Pimenta MT, Pisolato R, Lazari MF, Porto CS. 17 $\alpha$ -estradiol signaling and regulation of Sertoli cell function. *Spermatogenesis*. 2011; 1(4): 318-324.
19. Lucas TF, Siu ER, Esteves CA, Monteiro HP, Oliveira CA, Porto CS, Lazari MF. 17beta-estradiol induces the translocation of the

- estrogen receptors ESR1 and ESR2 to the cell membrane, MAPK3/1 phosphorylation and proliferation of cultured immature rat Sertoli cells. *Biol Reprod* 2008; 78(1): 101-114.
20. Gunawan A, Kaewmala K, Uddin MJ, Cinar MU, Tesfaye D, Phatsara C, Tholen E, Looft C, Schellander K. Association study and expression analysis of porcine ESR1 as a candidate gene for boar fertility and sperm quality. *Anim Reprod Sci* 2011; 128(1-4): 11-21.
  21. Filipiak E, Suliborska D, Laszczynska M, Walczak-Jedrzejowska R, Oszukowska E, Marchlewska K, Kula K, Slowikowska-Hilczler J. Estrogen receptor alpha localization in the testes of men with normal spermatogenesis. *Folia Histochem Cytobiol* 2013; 50(3): 340-345.
  22. González CR, Muscársel Isla ML, Leopardo NP, Willis MA, Dorfman VB, Vitullo AD. Expression of androgen receptor, estrogen receptors alpha and beta and aromatase in the fetal, perinatal, prepubertal and adult testes of the South American plains Vizcacha, *Lagostomus maximus* (Mammalia, Rodentia). *J Reprod Dev* 2012; 58(6): 629-635.
  23. Schoen J, Sharbatí S, Ritter J, Jewgenow K. Feline gonads exhibit tissue specific alternative splicing of oestrogen receptor alpha (ESR1). *Reprod Domest Anim* 2012; 47 Suppl 6: 30-34.
  24. Moon JH, Yoo DY, Jo YK, Kim GA, Jung HY, Choi JH, Hwang IK, Jang G. Unilateral cryptorchidism induces morphological changes of testes and hyperplasia of Sertoli cells in a dog. *Lab Anim Res* 2014; 30(4): 185-189.
  25. Mäkinen S, Mäkelä S, Weihua Z, Warner M, Rosenlund B, Salmi S, Hovatta O, Gustafsson JA. Localization of oestrogen receptors alpha and beta in human testis. *Mol Hum Reprod* 2001; 7(6): 497-503.
  26. Saunders PT, Sharpe RM, Williams K, Macpherson S, Urquart H, Irvine DS, Millar MR. Differential expression of oestrogen receptor alpha and beta proteins in the testes and male reproductive system of human and non-human primates. *Mol Hum Reprod* 2001; 7(3): 227-236.
  27. Pelletier G, El-Alfy M. Immunocytochemical localization of estrogen receptors alpha and beta in the human reproductive organs. *J Clin Endocrinol Metab* 2000; 85(12): 4835-4840.
  28. Mizuno K, Kojima Y, Kurokawa S, Kamisawa H, Kohri K, Hayashi Y. Altered expression and localization of estrogen receptors alpha and beta in the testes of a cryptorchid rat model. *Urology* 2011; 77(1): 251.
  29. Hermanowicz A, Matuszczak E, Debek W, Dzienis-Koronkiewicz E, Komarowska M, Oksiuta M, Kowalewska J, Milewski R. Expression of estrogen receptors  $\alpha$  and  $\beta$  in paratesticular tissues in boys operated on for unilateral cryptorchidism between the 1st and 4th years of life. *Med Sci Monit* 2012; 18(10): CR630-CR634.
  30. Hejmej A, Bilińska B. The effects of cryptorchidism on the regulation of steroidogenesis and gap junctional communication in equine testes. *Endokrynol Pol* 2008; 59(2): 112-118.
  31. Robertson JA, Farnell Y, Lindahl LS, Ing NH. Estradiol up-regulates estrogen receptor messenger ribonucleic acid in endometrial carcinoma (Ishikawa) cells by stabilizing the message. *J Mol Endocrinol* 2002; 29(1): 125-135.
  32. Couse JE, Mahato D, Eddy EM, Korach KS. Molecular mechanism of estrogen action in the male: insights from the estrogen receptor null mice. *Reprod Fertil Dev* 2001; 13(4): 211-219.
  33. Mahato D, Goulding EH, Korach KS, Eddy EM. Spermatogenic cells do not require estrogen receptor-alpha for development or function. *Endocrinology* 2000; 141(3): 1273-1276.
  34. Farinola MA, Gown AM, Judson K, Ronnett BM, Barry TS, Movahedi-Lankarani S, Vang R. Estrogen receptor alpha and progesterone receptor expression in ovarian adult granulosa cell tumors and Sertoli-Leydig cell tumors. *Int J Gynecol Pathol* 2007; 26(4): 375-382.
  35. Dubé JY, Tremblay RR. Search for progesterone receptors in testes from various animal species. *Mol Cell Endocrinol* 1979; 16(1): 39-44.