

## A Case of Acute Rheumatic Fever With Henoch Schonlein Purpura

Ozlem Bostan Gayret,<sup>1</sup> Meltem Erol,<sup>1\*</sup> Ozgul Yigit,<sup>1</sup> Emine Kutanis,<sup>1</sup> Sinan Yavuz,<sup>1</sup> Ali Muhammedoglu,<sup>2</sup> and Ozgur Kasapcopur<sup>3</sup>

<sup>1</sup>Department of Pediatrics, Bagcilar Training and Research Hospital, Istanbul, Turkey

<sup>2</sup>Department of Pathology, Bagcilar Training and Research Hospital, Istanbul, Turkey

<sup>3</sup>Department of Pediatric Rheumatology, Istanbul University Cerrahpasa Faculty of Medicine, Istanbul, Turkey

\*Corresponding author: Meltem Erol, Department of Pediatrics, Bagcilar Training and Research Hospital, Istanbul, Turkey. Tel: +90-5324578397, Fax: +90-2124404242, E-mail: drmeltemerol@yahoo.com

Received 2015 March 15; Accepted 2015 May 9

### Dear Editor,

The relation of Henoch-Schonlein purpura (HSP) vasculitis with Acute rheumatic fever was defined by Gairdner firstly in 1948 (1). Both HSP and rheumatic fever can affect the joints and heart in a different way. In HSP arthritis is usually non migratory and heart involvement is usually appear as myocarditis. In rheumatic fever arthritis is usually migratory and heart involvement is manifest as valvulitis. Rheumatic fever may rarely develop during HSP. The role of group A beta-haemolytic streptococcus (GABHS) in the pathogenesis of rheumatic fever is well established. The presence of rheumatic fever, GABHS may sometimes have a pathogenic role in HSP (2). We present here a child admitted to our clinic as acute rheumatic carditis, who developed HSP vasculitis thereafter.

A 12-year-old male presented to our clinic with initially right ankle, followed by left knee and left ankle, pain, sensitivity, redness. His complaints had started 4 days ago. We learned that he had an upper respiratory infection 15 days ago and used antibiotic. At the time of admission axillary body temperature was 36.7°C; blood pressure was 90/60 mmHg. Erythema marginatum-like eruptions appeared on his body and upper extremities, which regressed within 1 hour during follow-up (Figure 1).

A cardiac auscultation revealed a grade 2/6 systolic murmur over the mitral region. He had hyperemia and swelled on the left knee and right leg, a pronounced diameter difference between the two ankles. Laboratory investigation showed hemoglobin 11.2 g/dL, WBC count  $7.6 \times 10^9/L$ , platelet count  $283 \times 10^9/L$ , C-reactive protein was elevated 79.9 mg/dL, erythrocyte sedimentation rate was elevated, 80 mm/hour. Antistreptolysin (ASO) titer was 180 Todd Units on admission. ASO was elevated 320 Todd Units during follow-up. The throat culture was negative. Antinuclear antibody was absent, rheumatoid factor was negative. Electrocardiography revealed a PR interval

of 0.20 seconds. Echocardiographic findings revealed minimal mitral, aortic, and tricuspid valve failure. The patient was diagnosed with ARF carditis, and treatment was started with 2 mg/kg/day prednisolone. Benzathine penicillin made intramuscular. During the second day of hospitalization patient developed purpuric rash on his lower extremities. Purpuric rash, did not become pale with pressure. The skin biopsy revealed leucocytoclastic vasculitis (Henoch-Schönlein purpura) (Figure 2).

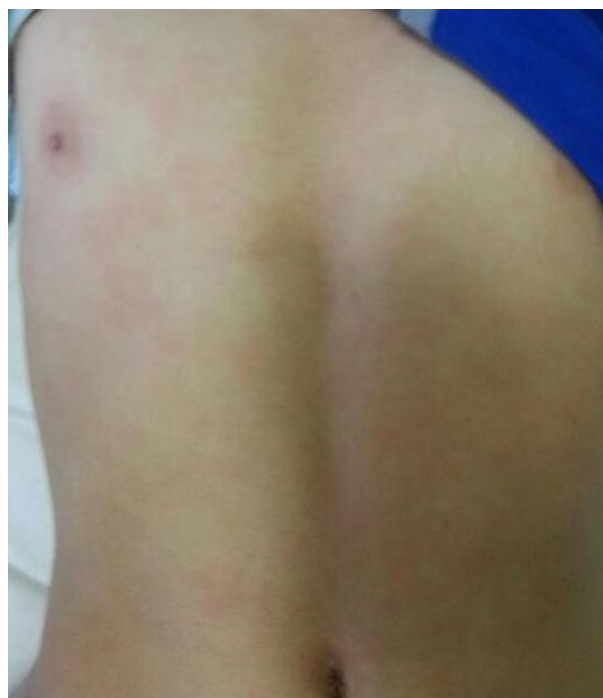

Figure 1. Marginatum-Like Eruptions on His Body

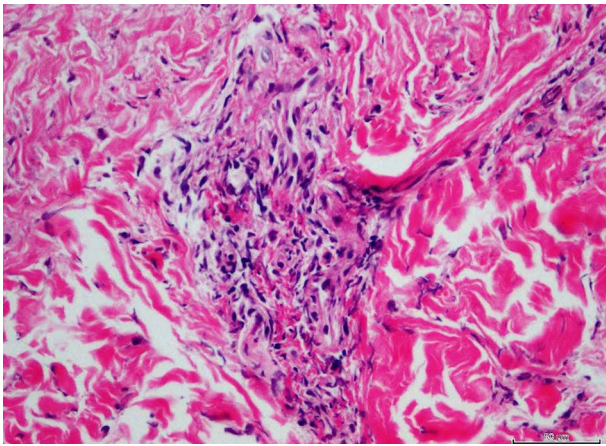


Figure 2. Skin Biopsy Image

His serum immune globulin A (IgA) level was elevated 324 mg/dL. Therefore, the steroid treatment was continued. During follow-up the signs and symptoms of vasculitis and carditis regressed.

Our patient had migratory arthritis. According to the Jones criteria, our case had three major diagnostic symptoms of rheumatic fever; arthritis, carditis, and erythema marginatum; therefore, a diagnosis of acute rheumatic fever was made. ASO, which is a supporting parameter of disease, was also high in our case. Ocal et al. (3) reported a case of HSP with rheumatic carditis with history of streptococcal infection 4 weeks ago. Our patient had history of upper respiratory infection before 2 weeks ago. Our patient's throat culture was negative for GABHS, but he used antibiotic. Elevated ASO titers suggested a recent streptococcus infection.

Immunologic mechanism underlying HSP and rheu-

matic fever are quite different. Cellular immune mechanism mediated by T lymphocytes to streptococcal M-proteins cause destruction cardiac tissues (4). In these patients elevated IgA levels and immune complexes have been described (5).

In previous reports during to HSP, developed acute rheumatic carditis thereafter (1, 3, 6). He is different from previous cases. In literature, the interval from onset of HSP to appearance of rheumatic fever was declared as 10 days to 12 weeks (2, 3, 6). Literatures are limited of HSP and acute rheumatic fever co-occurrence without time interval between these two diseases (6, 7). We presented this case due to that rheumatic fever appeared first, after 2 days purpuric rash occurred. Because of these two reasons our case is different from previous reports. We think that GABHS infections may trigger HSP as acute rheumatic fever.

## References

1. Gairdner D. The Schonlein-Henoch syndrome (anaphylactoid purpura). *Q J Med.* 1948;**17**(66):95-122.
2. Eisenstein EM, Navon-Elkan P. Acute rheumatic fever associated with Henoch-Schönlein purpura: report of three cases and review of the literature. *Acta Paediatrica.* 2007;**91**(11):1265-7.
3. Öcal B, Karademir S, Oğuz D, Erdoğan Ö, Öner A, Şenocak F. Acute rheumatic carditis in Henoch-Schönlein purpura. *Int J Cardiol.* 2000;**74**(1):97-8.
4. Rullan E, Sigal LH. Rheumatic fever. *Curr Rheumatol Rep.* 2001;**3**(5):445-52.
5. Saulsbury FT. Henoch-Schonlein purpura in children. Report of 100 patients and review of the literature. *Medicine (Baltimore).* 1999;**78**(6):395-409.
6. Guven H, Ozhan B, Bakiler AR, Salar K, Kozan M, Bilgin S. A case of Henoch-Schonlein purpura and rheumatic carditis with complete atrioventricular block. *Eur J Pediatr.* 2006;**165**(6):395-7.
7. Sen TA, Kundak AA, Guraksin O, Demir T, Narci A. Acute rheumatic carditis associated with Schoenlein-Henoch vasculitis. *Anadolu Kardiyol Derg.* 2010;**10**(5):465-6.