



Case Report

Periorbital *Dirofilaria repens* imported to Denmark: A human case report

Kristine Klintebjerg^{a,*}, Eskild Petersen^{a,b}, Natalia Yurievna Pshenichnaya^c, Larisa Alexandrovna Ermakova^d, Sergey Andreevich Nagorny^d, Carsten Schade Larsen^a

^a Department of Infectious Diseases, Aarhus University Hospital, Aarhus, Denmark

^b Department of Clinical Microbiology, Aarhus University Hospital, Aarhus, Denmark

^c Rostov State Medical University, Rostov-on-Don, Russia

^d Rostov Scientific Research Institute of Microbiology and Parasitology, Rostov-on-Don, Russia

ARTICLE INFO

Article history:

Received 25 November 2014

Received in revised form 2 December 2014

Accepted 2 December 2014

Keywords:

Dirofilaria repens

Travel

Denmark

Europe

Human

ABSTRACT

Dirofilaria repens, a filarial nematode of dogs and other carnivores, can accidentally infect humans. The infection occurs widely throughout Europe. We report a case of *D. repens* in a Danish woman who had been traveling to Crete. A nematode was visualized on examination and ELISA was positive for antibodies against *D. repens*.

© 2014 The Authors. Published by Elsevier Ltd. This is an open access article under the CC BY-NC-ND license (<http://creativecommons.org/licenses/by-nc-nd/3.0/>).

Introduction

Dirofilaria repens is a filarial nematode transmitted by mosquitoes that primarily affects dogs and other carnivores. The adult worms are found in the subcutaneous tissues of dogs and other animals and the adult filariae deposit microfilariae in the blood of the host. Mosquitoes ingest the first-stage larve with a blood meal from the infected host, which develop into the infective third-stage filariform larvae. When the third stage larva have matured and are found in the salivary glands of the mosquito, the infection can be transmitted to the next animal including humans from which the mosquito take the next blood meal. The incubation period in the vertebrate host is 6–8 months [1] (Fig. 1).

Incidental human infection can manifest as a single subcutaneous nodule. Migration of the worm may result in local swellings with changing localization. The majority of cases are found on the upper half of the body, mainly around the eyes [1]. Severe clinical manifestations have also been reported and may affect organs including the brain and lungs [2].

Infections have been reported from various regions of the world, mainly Europe, Africa, Middle East and Asia. Areas in Europe where *D. repens* has been solidly established include countries of the Mediterranean region where the warmer climate facilitates the development of infectious larvae in mosquitoes [3]. Studies from Russia and northern Germany found that the geographical distribution is expanding [1,4]. So far there are no data from Denmark.

Case report

A 39-year-old Danish woman was seen in January 2014 referred by an ophthalmologist on suspicion of a larval infestation around the right eye.

Symptoms began suddenly one week before referral. The patient had noticed a larvae moving under the skin around the right eye with redness and swelling of the skin. Periodically, the structure disappeared. Severe headache in the right temporal area occurred when the structure disappeared.

The patient had visited Crete in August 2013 and had never traveled outside Europe. In September 2013 the patient had noticed a subcutaneous nodule on her left leg. The patient lives on a farm and has a dog.

* Corresponding author at: Department of Infectious Diseases, Aarhus University Hospital, Brendstrupsgaardvej 100, 8200 Aarhus N, Denmark. Tel.: +45 22271961. E-mail address: Kristine_klintebjerg@hotmail.com (K. Klintebjerg).

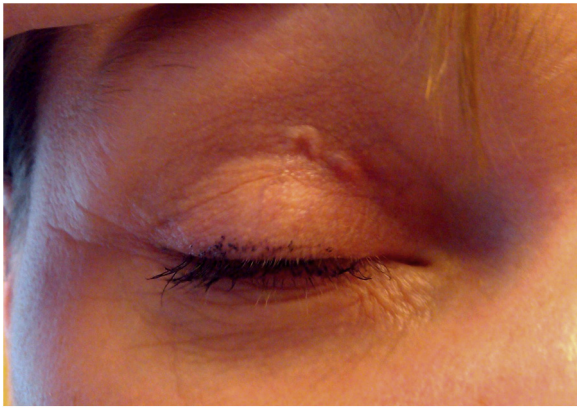


Fig. 1. The worm was seen at the upper eyelid on the day of admission.

On examination a larva was seen moving across the right upper eyelid. MRI of the right orbit did not demonstrate any abnormalities. The MRI was performed four days after the patient were first seen and after start of albendazole treatment. There was no eosinophilia and IgE was normal. Toxocara antibody titer was negative, but there was a positive filarial antibody titer, using *Dirofilaria immitis* as antigen.

Serum was sent to the Rostov Scientific Research Institute of Microbiology and Parasitology, Rostov-on-Don, Russia, for determination of specific antibodies against *D. repens*, which has developed an ELISA for the detection of *Dirofilaria*-specific antibodies based on purified somatic antigen of immature female *D. repens* removed from human cases [1]. The test was found positive for *D. repens*-specific antibodies. ELISA tests with echinococcus, toxocarosis and trichinellosis antigens were performed, and they were all negative. The patient's dog was tested negative for microfilariae in the blood.

Anthelmintic treatment with albendazole 400 mg twice daily orally for 5 days was initiated and the patient recovered rapidly.

On the day of admission we send the patient to an ophthalmologist for surgical removal of the worm. The diagnosis may be achieved parasitological when a living and intact worm can be extracted. Unfortunately it could not be removed.

Discussion

This is the first reported case of human infection with *D. repens* in Denmark, probably imported from Crete.

In Greece the prevalence of dirofilariasis in dogs caused by *D. repens* infection has been estimated to range between 6.7% and 22% [5]. During the last years cases of human dirofilariasis have also been reported from countries farther north, including Austria, Poland and Germany [6–8]. However, with the increasing prevalence of *D. repens* in northern Germany infection in Denmark is another possibility as *D. repens* may be present in Danish canines. In February 2014 dogs and mosquitoes have been found positive with *D. repens* in northern Germany and a case of human *D. repens* was reported [3,6]. The climate change and

increased translocation of dogs might be responsible for the spread to the north [9].

It is surprising that both the eosinophil count and IgE were normal, as these parameters are usually elevated in invasive nematode infections. However, we believe that it reflects that the patient only had a single nematode and that it caused modest local inflammation and thus failed to elicit eosinophilia and an increase IgE. Indeed in a large case series from Russia eosinophilia was found in only 38% of cases (IgE were not measured) [1].

Although this is the only case reported from Denmark, infection with *D. repens* probably occurs more frequently and is either unrecognized or misdiagnosed. In 2013 67.4% of the Danish population traveled by air outside Denmark [11,12]. Patients who traveling in Europe should consider limit their exposure to mosquitoes and protect themselves from bites.

In conclusion a subcutaneous dirofilariasis should be considered as a differential diagnosis in patients who presents with a subcutaneous nodules or a migrating larva.

Conflicts of interest

None of the authors have any conflicts of interest to declare.

Acknowledgments

The authors wish to thanks Rostov Scientific Research Institute of Microbiology and Parasitology in Russia for providing results of ELISA testing. The authors are grateful to the patient for letting us sharing her picture.

References

- [1] Ermakova LA, Nagorny SA, Krivorotova EY, Pshenichnaya NY, Matina ON. *Dirofilaria repens* in the Russian Federation: current epidemiology, diagnosis, and treatment from a federal reference center perspective. *Int J Infect Dis* 2014;23:47–52.
- [2] Poppert S, Hodapp M, Krueger A, Hefasy G, Niesen W, Kern WV, et al. *Dirofilaria repens* infection and concomitant meningoencephalitis. *Emerg Infect Dis* 2009;15:1844–5.
- [3] Genchi C, Kramer LH, Rivasi F. *Dirofilaria* infections in Europe. *Vector Borne Zoonotic Dis* 2011;11:1307–17.
- [4] Czajka C, Becker N, Jöst H, Poppert S, Schmidt-Chanasit J, Krüger A, et al. Stable transmission of *Dirofilaria repens* nematodes Northern Germany. *Emerg Infect Dis* 2014;20:329–31.
- [5] Tzanetou K, Gasteratos S, Pantazopoulou A, Gogou C, Konidaris D, Fragia K. Subcutaneous dirofilariasis caused by *Dirofilaria repens* in Greece: a case report. *J Cutan Pathol* 2009;36:892–5.
- [6] Tappe D, Plauth T, Muntau B, Diessel L, Tannich E, Herrmann-Trist P. A case of autochthonous human *Dirofilaria* infection, Germany March 2014. *Euro Surveill* 2014;19(17). pii=20790.
- [7] Cielecka D, Zarnowska-Prymek H, Masny A, Saalamatin R, Wesolowska M, Golab E. Human dirofilariosis in Poland: the first cases of autochthonous infections with *Dirofilaria repens*. *Ann Agric Environ Med* 2012;19:445–50.
- [8] Saalamatin RV, Pavlikovska TM, Sagach OS, Nikolayenko SM, Korniyushin VV, Kharchenko VO, et al. Human dirofilariasis due to *Dirofilaria repens* in Ukraine, an emergent zoonosis epidemiological report of 1465 cases. *Acta Parasitol* 2013;58:592–8.
- [9] Genchi C, Mortarino M, Rinaldi L, Cringoli G, Traldi G, Genchi M. Changing climate and changing vector-borne disease distribution: the example of *Dirofilaria* in Europe. *Vet Parasitol* 2011;176:295–9.
- [11] Statistics Denmark-statbank.dk. Population statistics; 2014, Available at: <http://www.dst.dk/pukora/epub/Nyt/2014/NR427.pdf> [accessed August 2014].
- [12] Nielsen US, Larsen CS, Howitz M, Petersen E. Hepatitis A among Danish travellers 1980–2007. *J Infect* 2009;58:47–52.