

Case report: a rare case of NOMA (cancrum oris) in a Malian woman

H. Traore¹, E. Sogodogo², A. Coulibaly¹, A. Toure¹, S. Thiocary¹, M. D. Sidibé¹, L. G. Timbiné², A. K. Sangaré², B. Y. Traoré², J. Ouedraogo², D. Sogodogo³ and B. Kouriba²

1) Centre National d'Odonto-Stomatologie (CNOS), 2) Centre d'infectiologie Charles-Mérieux (CICM) and 3) Centre Hospitalier Mère-enfant - Le Luxembourg, Bamako, Mali

Abstract

Noma or *cancrum oris* is a multi-bacterial and opportunistic infection that destroys soft tissue, as well as muscle and bone, and can be fatal. We present a rare case of Noma in a 32-year-old Malian woman, from whom we isolated an *Escherichia coli* extended-spectrum beta-lactamase.

© 2021 The Author(s). Published by Elsevier Ltd.

Keywords: Antibiotic, *cancrum oris*, *Escherichia coli*, Mali, Noma

Original Submission: 15 December 2020; **Revised Submission:** 12 May 2021; **Accepted:** 17 May 2021

Article published online: 29 May 2021

Corresponding author: E. Sogodogo, Centre d'Infectiologie Charles-Mérieux (CICM), Ex-base aérienne, BP E 2283, Bamako, Mali Bureau
E-mail: elisabethsogodogo@yahoo.fr

These authors equally contributed to this manuscript.

Case Presentation

A 32-year-old housewife with no known pathological history was admitted to the stomatology and maxillofacial surgery department of the National Centre of Odonto-Stomatology of Bamako. The patient was referred from a rural health centre. The onset of symptoms would go back 16 days before admission marked by pain and swelling of the left cheek, in a context of hyperthermia and lack of appetite. The patient had undergone traditional treatment based on herbal decoctions. The consultation in the health centre near the place of residence of the patient was motivated by the presence of a black border delimiting the future loss of substance and gangrene with a foul odour. She received treatment with antibiotics consisting of Metronidazole, ciprofloxacin, and gentamicin. On admission to the hospital, a clinical examination was performed. A loss of substance involving the left cheek was revealed on exo-oral examination. The wound was rounded, measuring 6 × 4 cm, and resulting in an orostoma through which denudation of the

mandibular bone was visible (Fig. 1). Laboratory investigations included a haemoglobin concentration of 7 g/dl, hyperleukocytosis and negative HIV serology. Noma in adults and the elderly has often been associated with immunosuppression [1,2]. A sterile swab was used to collect pus from the ulcer and discharged in a transport medium preserving methanogen and anaerobic bacteria viability [3]. This transport medium consisted of (per litre) KCl 0.2 g, CaCl₂ 0.1 g, MgCl₂ 0.1 g, KH₂PO₄ 0.2 g, Na₂HPO₄ 1.15 g, NaCl 3 g, ascorbic acid 1 g, uric acid 0.1 g, and glutathione 0.1 g [3].

The sample collected from the ulcer was cultured on different agar plates: Columbia agar with 5% sheep blood:non-selective agar (BioMerieux, Craaponne, France), Drigalski agar (Gram-negative selective agar), and Columbia and colistin plus nalidixic acid agar:Gram-positive selective agar (BioMerieux, Craaponne, France), for aerobic bacteria; chocolate agar with IsoVitalX (BioMerieux, Craaponne, France) under micro-aerophilic conditions (5% CO₂) for difficult microorganisms; Schaedler agar (BioMerieux, Craaponne, France), with added kanamycin plus vancomycin under anaerobic conditions for anaerobic microorganisms and Can 2 agar: selective yeast medium (BioMerieux, Craaponne, France).

Colonies of bacteria and fungi were subjected to phenotypic testing using the automated Vitek 2 system and software.

The bacteria were then reidentified by matrix-assisted laser desorption-ionisation time-of-flight mass spectrometry using a Microflex spectrometer (Bruker Daltonics, Bremen, Germany).

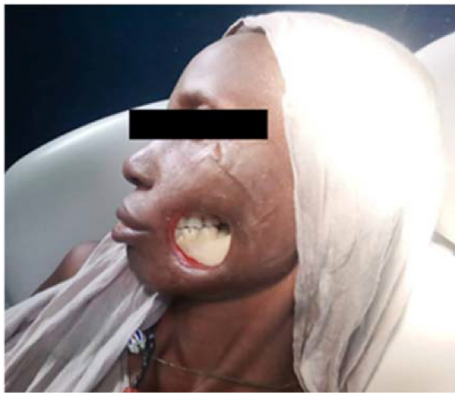

FIG. 1. Physical sequelae of Noma in a 32-year-old woman.

After analysis, we found a polymicrobial infection. Among these bacteria, we have isolated an *Escherichia coli* extended-spectrum beta-lactamase (ESBL). Double-disk synergy methods were used for detection of ESBL-producing strains. We observed a zone of inhibition enhanced by the action of two cephalosporin discs, Ceftriaxone and cefepime on the side facing amoxicillin + clavulanic acid was considered to produce ESBL (Fig. 2).

A study carried out in Mali in 2016 showed that nearly two-thirds (61.8%) of Enterobacteriaceae isolated from blood cultures were producers of ESBLs, including 27.5% of *Escherichia coli* [4]. Another recent study in Mali showed ESBL production rates of 24.81% in *Escherichia coli* [5]. In vitro susceptibility was assessed using the Vitek 2 antibiotic susceptibility testing card and by diffusion of antibiotic discs on Mueller Hinton agar. The zones of inhibition on Mueller Hinton agar were read by Scan 4000.

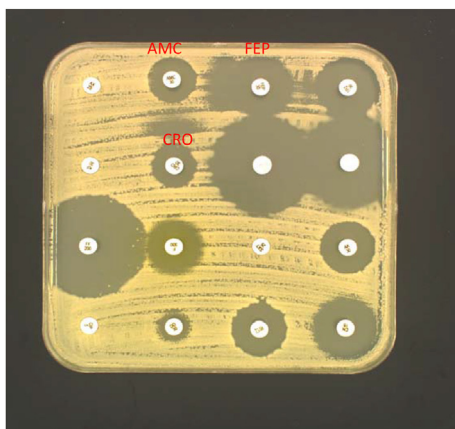


FIG. 2. Isolation of Extended-Spectrum β -lactamase (ESBL) producing *Escherichia coli*. The formation of a zone of inhibition between the three antibiotics is observed. **AMC:** amoxicillin/acid clavulanic; **FEP:** Cefepime, **CRO:** ceftriaxone.

TABLE 1. Antimicrobial susceptibilities of *Escherichia coli* isolate obtained from a 32-year-old woman

Antibiotics	Results
Imipenem	Sensitive
Ertapenem	Sensitive
Colistin	Sensitive
Fosfomicin	Sensitive
Gentamycin	Sensitive
Amikacin	Sensitive
Nitrofurantoin	Sensitive
Piperacillin/Tazobactam	Sensitive
Amoxicillin-clavulanic acid	Intermediate
Cefepime	Intermediate
Amoxicillin	Resistant
Trimethoprim-sulfamethoxazole	Resistant
Ceftriaxone	Resistant
Doxycycline	Resistant
Cefalotine	Resistant
Ciprofloxacin	Resistant

The results showed susceptibility to Imipenem, ertapenem, Colistin, Gentamicin, amikacin, nitrofurantoin, Piperacillin/Tazobactam, and fosfomicin (Table 1). Anaerobic cultures have remained sterile, although studies have shown, in most cases, the presence of *Prevotella intermedia* and *Fusobacterium necrophorum*, which are strictly anaerobic [6,7]. The microorganisms found in Noma are predominantly anaerobic, most of which are part of the normal oral microbiota [8]. Studies also have soil bacteria typical of gangrene, of animal origin that could greatly contribute to the infection [8]. The other isolated microorganisms are composed of *Kluyveromyces lactis*, *Candida tropicalis*, *Clavispora lusitanae*, and *Paenibacillus alvei*. The patient was already on antibiotic therapy before the microbiological analysis. The recovery of the patient with sequelae occurred after 10 days of hospitalisation. She had benefited from intense renutrition and 5 days of medical treatment consisting of three drugs: amoxicillin/clavulanic acid at a dose of 3 g/day, metronidazole 1.5 g/day, paracetamol 3 g/day, and treatment of parasitic diseases with albendazole 400 mg/day for 3 days. Sequestrectomy and local care helped heal the wounds. A follow-up of the nutritional state and a rehabilitation to prevent the installation of a permanent constriction of the jawbones are underway with a view to the future repair of the sequelae. The patient died a month later in her locality outside the hospital. The socio-economic factors of the patient did not allow her to benefit from a good follow-up of the sequelae of Noma. A study carried out in Mali in 2019 showed that a total of 348 antibiotics were prescribed in 204 patients in the internal medicine department of the University Hospital Hospital of "Point G" [9]. Among which 295 antibiotics have been prescribed as part of probabilistic antibiotic therapy. This study found that the most prescribed probabilistic antibiotics were amoxicillin + Clavulanic acid (38.6%), metronidazole (12.6%) and ceftriaxone (10.2%).

The emergence and dissemination of broad-spectrum beta-lactamases in Mali are linked to the use of broad-spectrum antibiotics both in hospitals and in self-medication.

Transparency declaration

The authors declare that they have no known competing financial interests or personal relationships that could have appeared to influence the work reported in this article.

Acknowledgements

The authors wish to acknowledge the support of Cooperation and Cultural Action Service of the French Embassy in Mali. The French embassy in Mali funded a scientific stay in a laboratory.

References

- [1] Masipa JN, Baloyi AM, Khammissa RAG, Altini M, Lemmer J, Feller L. Noma (cancrum oris): a report of a case in a young AIDS patient with a review of the pathogenesis. *Head Neck Pathol* 2012;7:188–92.
- [2] Ashok N, Tarakji B, Darwish S, Rodrigues JC, Altamimi MA. A review on noma: a recent update. *Glob J Health Sci* 2015;8:53–9.
- [3] Khelaifia S, Raoult D, Drancourt M. A versatile medium for cultivating methanogenic Archaea. *PLOS ONE* 2013;8:e61563.
- [4] Sangare SA, Maiga AI, Guindo I, Maiga A, Camara N, Dicko OA, et al. Prevalence of ESBL-producing Enterobacteriaceae isolated from blood cultures in Mali. *J Infect Dev Ctries* 2016;10:1059–64.
- [5] Sidibé M. Caractérisation des souches d'*Escherichia coli* et de *Klebsiella spp* multiresistantes isolées chez les humains, les animaux et dans l'environnement au laboratoire Rodolphe Mérieux de Bamako [Thesis] USTTB 2020. available on, <https://library.adhl.africa/handle/123456789/13913>.
- [6] Adeniyi SA, Awosan KJ. Pattern of noma (cancrum oris) and its risk factors in Northwestern Nigeria: a hospital-based retrospective study. *Ann Afr Med* 2019;18:17–22.
- [7] Enwonwu CO, Falkler WA, Phillips RS. Noma (cancrum oris). *The Lancet* 2006;368(9530):147–56.
- [8] García-Moro M, García-Merino E, Martín-Del-Rey A, García-Sánchez E, García-Sánchez JE. Noma/cancrum oris: a neglected disease. *Rev Espanola Quimioter Publ Soc Espanola Quimioter* 2015;28:225–34.
- [9] Adebo NAI. Analyse de la prescription des antibiotiques dans le service de Médecine Interne du Centre Hospitalier et Universitaire du Point G [Thesis] USTTB 2019. Available on: <https://www.bibliosante.ml/handle/123456789/3736>.