



## Case report

# Rapidly progressive interstitial lung disease due to anti-melanoma differentiation associated protein-5 requiring a bilateral lung transplant, and complicated by kennel cough

Andrew R. Deitchman<sup>a,\*</sup>, Or Kalchier-Dekel<sup>a</sup>, Nevins Todd<sup>a</sup>, Robert M. Reed<sup>a</sup>

<sup>a</sup> Division of Pulmonary and Critical Care Medicine, University of Maryland School of Medicine, Baltimore, MD, USA

## A B S T R A C T

The association between inflammatory myopathies anti-synthetase syndrome and interstitial lung disease has been recognized since the 1950s. Patients generally present with gradual onset of symptoms and slow progression of fibrosis over months to years. Herein, we describe a previously well 51-year-old man who presented with three months of progressive small joint arthritis, cough, dyspnea, and eventually hypoxemic respiratory failure following a viral prodrome. He continued to decompensate despite high dose corticosteroids and mycophenolate mofetil, ultimately requiring extracorporeal membranous oxygenation as a bridge to bilateral lung transplantation. Clinically amyopathic dermatomyositis (CADM) was confirmed through serum positivity for anti-Melanoma Differentiation Associated Protein-5 (MDA-5) antibody. Interestingly, his post-operative course was complicated by a zoonotic infection with *Bordetella bronchiseptica*. This case highlights the importance of identifying rare autoimmune diseases, and the utility of transfer to a lung transplant center.

## 1. Introduction

Herein, we present a case of a previously healthy individual who presented with interstitial pneumonia that progressed to fulminant respiratory failure. At the time of initial evaluation, the inciting etiology was not known, and a diagnosis of interstitial lung disease (ILD) with autoimmune features was thus assigned. A thorough evaluation, including novel serologic markers and tissue biopsy yielded the final diagnosis of anti-Melanoma Differentiation Associated Protein (MDA)-5-positive clinically amyopathic dermatomyositis (CADM). The patient received extra corporeal membranous oxygenation (ECMO) as bridge to bilateral lung transplant. Once home and recovering he developed bronchitis with a causative organism of *Bordetella bronchiseptica*, an unusual human pathogen.

This case illustrates how adjustment of diagnosis may inform patient prognosis and management, as the entity of MDA-5-positive anti-synthetase syndrome portends a relatively poor outcome. This emphasizes the need for continued evaluation of all interstitial pneumonias to identify high-risk disease. Additionally, we describe a first case of *B. bronchiseptica* bronchitis in a lung transplant recipient.

## 2. Case presentation

A 51-year-old previously healthy Caucasian man developed non-productive cough, mild shortness of breath, malaise, and occasional

chills two weeks following an early-winter hunting trip in the mountains of Western Maryland, USA. He had no prior history of tobacco smoking, illicit drug use, or known personal or family history of lung disease. His wife, who did not join the hunting trip, experienced similar symptoms at that time. While she recovered spontaneously, his symptoms persisted.

The patient reported no benefit after a short course of oral cephalexin and prednisone, prescribed by his primary care physician for possible “reactive airways”. One month into his illness he developed a violaceous rash involving his face and upper chest as well as pain and symmetric swelling of his proximal and distal interphalangeal joints in both upper and lower extremities. These symptoms progressed despite a course of oral azithromycin and prednisone. Two months into his illness, a third course of oral prednisone was prescribed and resulted in mild improvement in his arthritis, but no appreciable respiratory benefit. After three months of progressive deterioration he had become too short of breath to climb a flight of stairs and he was admitted to another institution.

## 3. Assessment

He was noted to be hypoxemic on admission, which corrected with 4.0 L/min of supplemental oxygen. Initial evaluation including serum blood testing, microbiologic testing, and bronchoscopy with bronchoalveolar lavage are summarized in [Table 1](#). Peripheral blood leukocyte

\* Corresponding author. 110 S. Paca St., 2nd floor, Baltimore, MD 21201, USA  
E-mail address: [Andrew.R.Deitchman@christianacare.org](mailto:Andrew.R.Deitchman@christianacare.org) (A.R. Deitchman).

<https://doi.org/10.1016/j.rmcr.2019.100886>

Received 6 June 2019; Received in revised form 13 June 2019; Accepted 13 June 2019

Available online 15 June 2019

2213-0071/© 2019 The Authors. Published by Elsevier Ltd. This is an open access article under the CC BY-NC-ND license (<http://creativecommons.org/licenses/by-nc-nd/4.0/>).

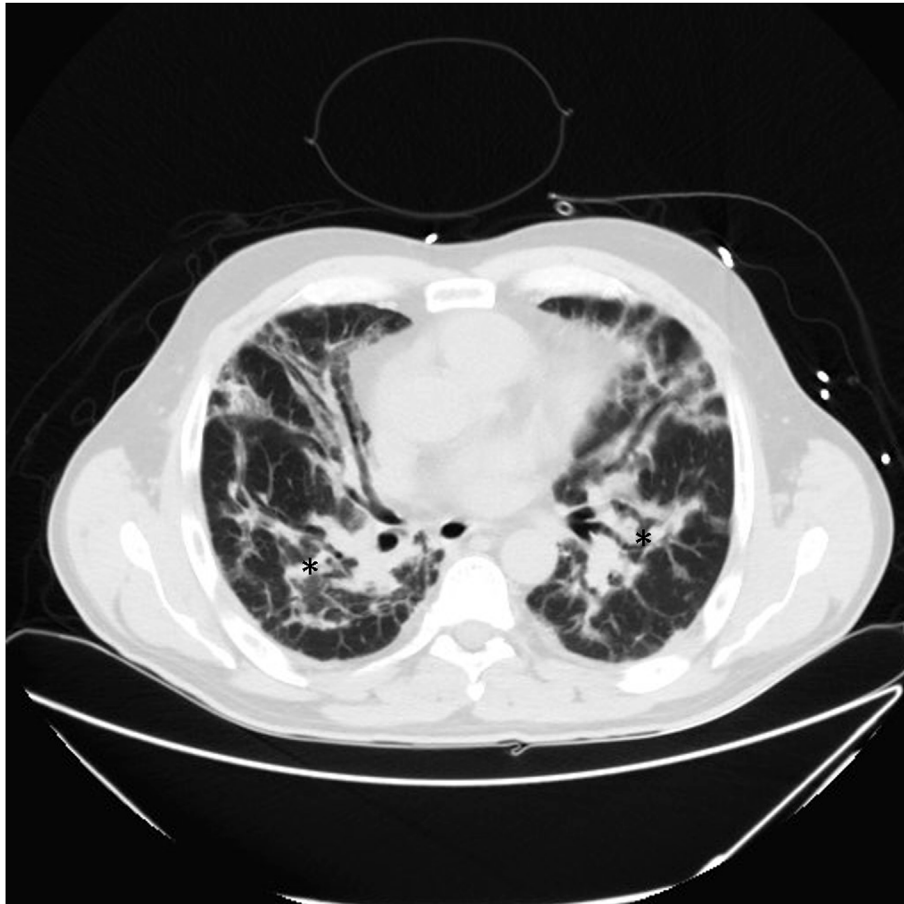
**Table 1**  
Initial laboratory work-up.

Investigations	Result (reference range)
Diagnostic test	Result (reference range)
Total leukocyte count (cells/ $\mu$ L)	18,100 (4500–11,000)
Erythrocyte sedimentation rate (mm/hour)	37 (0–20)
Creatine kinase (U/L)	77 (30–135)
Anti-tRNA synthase autoantibody panel (EJ, Jo1, Ku, Mi-2, Oj, PL-12, and PL-7)	Negative
cANCA, anti-PR3	Negative
pANCA, anti-MPO	Negative
ANA	Negative
Anti-CCP	Negative
RF	Negative
Anti-SS-A/SS-B	Negative
Anti-SCL-70	Negative
Anti-centromere	Negative
Anti-dsDNA	Negative
Blood culture	No growth
<i>Borrelia burgdorferi</i> IgG and IgM	Both negative
BAL fluid bacterial, mycobacterial, and fungal smears and cultures	Smears all negative; no growth of microorganisms in culture
<i>Pneumocystis jirovecii</i> antigen in BAL	Negative
Viral PCR panel in BAL (adenovirus, human metapneumovirus, influenza A&B, parainfluenza, rhinovirus, and respiratory syncytial virus)	Negative

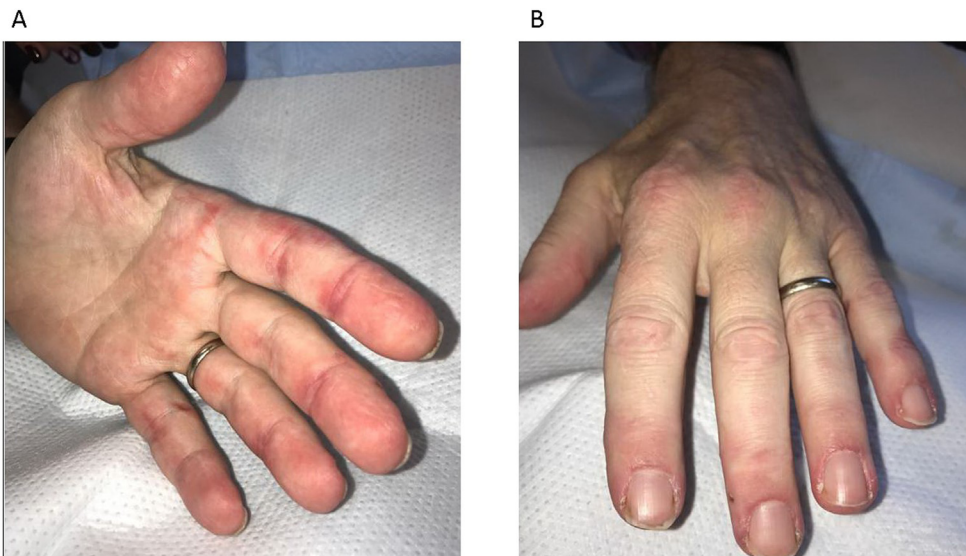
cANCA, cytoplasmic antineutrophil cytoplasmic antibodies; pANCA, perinuclear neutrophil cytoplasmic antibodies; ANA, antinuclear antibody; CCP, cyclic citrullinated peptide; RF, rheumatoid factor; SS-A, Sjögren's syndrome-related antigen A; SS-B, Sjögren's syndrome-related antigen B; SCL-70, scleroderma 70; dsDNA, double stranded DNA; BAL, bronchoalveolar lavage.

count was noted to be elevated; other laboratory tests were interpreted as negative or normal. Imaging tests included computed tomography (CT) of the thorax ([Image 1](#)). Antibiotic coverage with vancomycin, cefepime, and levofloxacin as well as high-dose corticosteroids were administered without significant clinical response. On hospital day 10 the patient was transferred to our institution for further evaluation and management.

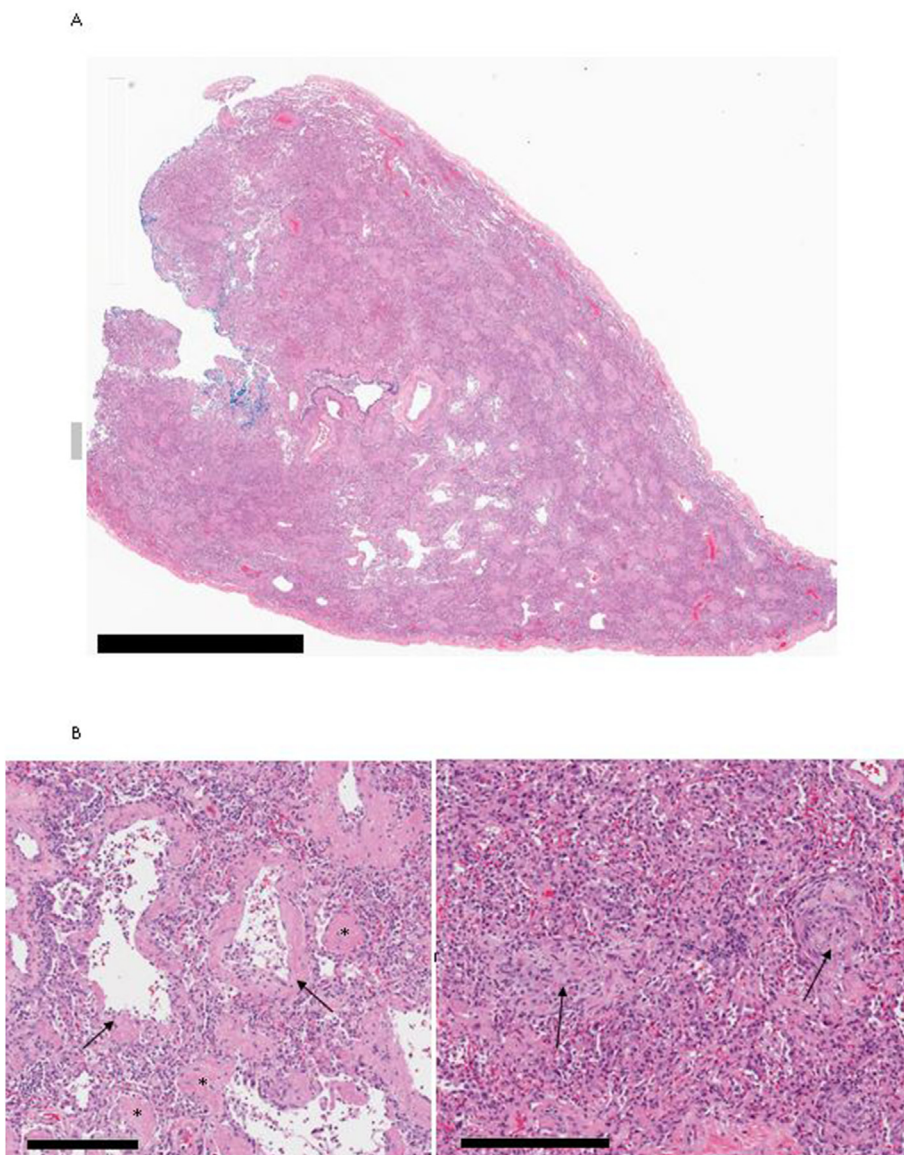
Upon presentation the patient was afebrile, with heart rate and blood pressure within the normal range. Tachypnea and oxygen desaturation of 89–91% were noted despite administration of 6.0 L/min of supplemental oxygen. Late-inspiratory bibasilar crackles were audible upon lung auscultation. The patient's hands were notable for peri-articular violaceous discoloration, compatible with reverse Gottron's papules, his fingertips were swollen and tender, with mild periungual erythema ([Image 2](#)). The skin of the face and chest was also noted to be ruddy in color without a heliotropic rash or shawl sign. No muscle weakness or tenderness were appreciable. A skin punch biopsy of his right second digit was non-diagnostic, and specifically lacked active vacuolar interface changes, and characteristic inflammation seen in dermatomyositis. He lacked clinical features of myositis, negating enthusiasm for a muscle biopsy and he was continued on methylprednisolone, vancomycin, and cefepime without significant improvement or a unifying diagnosis. After careful consideration, at our institutional multidisciplinary ILD conference, about the risk/benefit of a surgical lung biopsy in a patient at risk for deterioration caused by the biopsy, the decision was made to proceed to biopsy in order to inform decision-making between augmented immunosuppression versus lung transplantation. Specimens obtained via video-assisted thoracoscopic surgical biopsy demonstrated pathology consistent with organizing diffuse alveolar damage ([Image 3](#)).



**Image 1.** CT of the thorax Non-contrast enhanced computed tomography of the chest demonstrates ground glass opacities and consolidation in a peribronchiolar pattern (asterisk), with marked subpleural sparing. Septal lines are prominent and traction bronchiectasis and volume loss are present. The peribronchiolar distribution of disease with subpleural sparing suggests organization with fibrosis.



**Image 2.** Cutaneous manifestations on presentation A) Violaceous patches on the palmar aspects of the metacarpophalangeal, proximal, and distal interphalangeal joints of the hand, likely representing reverse Gottron's papules that have been recognized in association with CADM [4]. B) Paronychia, cracking, discoloration, and periungual erythema are all subtle features that can be seen in dermatomyositis.



**Image 3.** Surgical lung biopsy Panel A (low magnification) and B-C (high magnification) are representative tissue sections obtained with surgical lung biopsy, demonstrating acute and organizing diffuse alveolar damage (DAD). Low magnification image (A) demonstrates diffuse, widespread lung injury with only a few small areas of relatively preserved lung architecture. High magnification images demonstrate findings of acute lung injury (B) with widespread hyaline membranes (arrows) lining alveolar spaces as well as extensive numerous areas of focal accumulation of fibrin deposits (asterisk). Other regions of well-formed focal areas of organization (C, arrows) indicating a later phase of response to lung injury. Horizontal black bars in the lower left of panel (A) represent 3 mm and (panels B, C) 300 μm.

**Table 2**  
Differential diagnosis of bilateral infiltrates considered in this case.

Infectious	Non-Infectious
Viral Pneumonia	Cryptogenic organizing pneumonia (COP)
Community acquired bacterial pneumonia	Acute interstitial pneumonia (AIP)
Fungal infection	Interstitial lung disease secondary to autoimmune disease
Tick-borne illness	

#### 4. Differential diagnosis

This patient presented with a subacute onset of hypoxemic respiratory failure, with bilateral pulmonary infiltrates. The initial differential diagnosis can be considered in terms of infectious versus non-infectious causes (Table 2).

Infectious etiologies were deemed unlikely based on negative smear, culture, nucleic acid, and serologic data (Table 1). Furthermore, several board-spectrum courses of antibiotics did not result in significant improvement. The surgical lung biopsy demonstrated a diffuse lung injury pattern most consistent with acute and organizing diffuse alveolar damage (DAD). Imaging and pathology results were not consistent with a new presentation of usual interstitial pneumonia or non-specific interstitial pneumonia. Acute interstitial pneumonitis (AIP) could result in this degree of respiratory failure, however the time course for AIP is typically rapidly-progressive rather than subacute with respiratory failure occurring within one to three weeks of presentation [1,2]. Cryptogenic organizing pneumonia (COP) remained a consideration based on the clinical history and imaging, but the histopathology demonstrated DAD, findings inconsistent with the more patchy and focal abnormalities seen in COP. The lack of response to corticosteroids was also atypical for COP, in which moderate-dose corticosteroids (1.0–1.5 mg/kg) results in improvements in 80% of patients within 4–8 weeks [2,3]. The history, physical exam, imaging, and histopathology results were most consistent with a connective tissue disease-related interstitial lung disease (CTD-ILD). The final diagnosis was highly-suggested by the physical exam. Cutaneous findings, specifically reverse Gottron's papules, a finding previously described in anti-synthetase syndromes, including clinically amyopathic dermatomyositis CADM [4]. However, the negative results of the anti-tRNA synthase autoantibody panel (EJ, Jo, Ku, Mi-2, Oj, PL-12, PL-7) introduced a degree of diagnostic uncertainty.

#### 5. Management

Given a high degree of suspicion for CTD-ILD, mycophenolate mofetil was added to the steroid regimen. However, the patient's respiratory status continued to deteriorate, ultimately succumbing to respiratory failure, and extra-corporeal membranous oxygenation (ECMO) support was initiated. On hospital day 16 the patient underwent bilateral lung transplantation.

Approximately three weeks following lung transplant, a serum assay, initially drawn around the time of presentation, for an extended autoantibody panel returned positive for anti-Melanoma Differentiation Associated Protein-5 (MDA-5) at 67 units (norm: < 20 units), thus confirming the final diagnosis.

**Final diagnosis:** Rapidly-progressive interstitial lung disease and respiratory failure secondary to MDA-5 associated clinically amyopathic dermatomyositis.

##### 5.1. Follow up

This patient experienced an uneventful hospital course following lung transplantation and was discharged home 19 days post-transplant. Approximately four months after his transplant he developed new-onset

cough. CT scan of the thorax demonstrated bronchial wall thickening in all five lobes with inflammatory changes. Repeat testing showed his MDA-5 antibody titer was < 20 units. Bronchoscopic transbronchial lung biopsies was without evidence of acute cellular rejection or suggestion of recurrence of interstitial lung disease, however *Bordetella bronchiseptica* grew in the bronchoalveolar lavage culture. He was diagnosed with *B. bronchiseptica* bronchitis and was treated with oral ciprofloxacin and inhaled amikacin with clinical and microbiologic resolution on follow-up bronchoscopy. He remains well at 18 months following lung transplantation.

#### 6. Discussion

CADM is a distinct subset of dermatomyositis (DM) that lacks the typical myositis features, and often lacks the presence of the common myositis-specific antibodies. More recently, the MDA-5 autoantibody has been discovered to be specific for CADM. MDA-5 has been shown to play a role in the host innate immune response to viral pathogens, functioning as a key signaling molecule for induction of interferons and cytokines. In a murine model, MDA5-deficient mice exposed to paramyxovirus were shown to be more likely to succumb to their illness due to severe disease and overwhelming viral replication [5]. In the presented case, a viral prodrome preceded the onset of this patient's symptoms. While biologically plausible, it is not yet clear whether viral infections may act as a trigger for autoimmune response to MDA-5, or whether this is coincidental.

The presence of autoantibodies against MDA-5 has been shown to be an independent risk factor for rapidly-progressive disease that tends to be treatment-refractory with a poor prognosis [6–8]. Rapidly-progressive CADM-ILD, is characterized by the onset of pulmonary symptoms within three months of initial presentation [7]. Comparatively, ILD related to other anti-synthetase syndromes typically assumes a more chronic course. Additionally, when compared with other forms of CTD-ILD, rapidly-progressive ILD associated with CADM portends poor prognosis; mortality rates may be as high as 60% in the first year and response to treatment with corticosteroids and other immunomodulatory medications tends to be unsatisfactory [7]. Other treatment modalities for CADM-ILD, including calcineurin inhibitors, cyclophosphamide, plasma exchange, rituximab, and intravenous immunoglobulin, remain limited to case reports and small case series [8–12]. The patient presented above was rapidly transplanted and hence did not have an opportunity to undergo any of the above therapies. Whether the decline in MDA-5 titers after transplant reflects effects of post-transplant immunosuppression or removal of antigenic stimulation by removal of the native lungs is not clear.

Interestingly, this patient's recovery was complicated by *B. bronchiseptica* infection. This gram-negative bacillus is commonly implicated in canine tracheobronchitis known as “kennel cough”. While this is a common pathogen in other animals, it is a rare cause of infection in humans due to the bacterium's predilection for animal respiratory epithelium [13]. Cases of human infection mostly occur in immunocompromised hosts, patients with a chronic respiratory illness associated with impaired respiratory barriers such as cystic fibrosis, and the elderly [14–19]. Although previously reported in non-lung solid organ transplant recipients and in pediatric lung transplant recipients [16,18,19], to the best of our knowledge this is the first account of infection with *B. bronchiseptica* in an adult lung transplant recipient. The patient's dog was tested for *B. bronchiseptica* and was not proven carry the pathogen, however a neighbor's dog was diagnosed with kennel cough, which is the likely culprit.

#### Funding sources

None.

## Potential conflicts of Interest

No conflicts of interest from any authors.

## Affirmation of authorship

I affirm that all authors had access to the data, a role in writing the manuscript, and have approved the final version.

## Disclosures

No financial disclosures. Some aspects of this case were presented at the American Thoracic Society meeting 2018.

## Conflicts of interest

The authors have no conflicts of interest to declare.

## Acknowledgements

We'd like to thank the patient who has provided us with consent for this opportunity to share his case.

## References

- [1] G.Y. Suh, E.H. Kang, M.P. Chung, K.S. Lee, J. Han, M. Kitaichi, et al., Early intervention can improve clinical outcome of acute interstitial pneumonia, *Chest* 129 (3) (2006) 753–761.
- [2] W.D. Travis, U. Costabel, D.M. Hansell, T.E. King Jr., D.A. Lynch, A.G. Nicholson, et al., An official American Thoracic Society/European Respiratory Society statement: update of the international multidisciplinary classification of the idiopathic interstitial pneumonias, *Am. J. Respir. Crit. Care Med.* 188 (6) (2013) 733–748.
- [3] B. Bradley, H.M. Branley, J.J. Egan, M.S. Greaves, D.M. Hansell, N.K. Harrison, et al., Interstitial lung disease guideline: the British thoracic society in collaboration with the thoracic society of Australia and New Zealand and the Irish thoracic society, *Thorax* 63 (Suppl 5) (2008) v1–58.
- [4] D. Fiorentino, L. Chung, J. Zwerner, A. Rosen, L. Casciola-Rosen, The mucocutaneous and systemic phenotype of dermatomyositis patients with antibodies to MDA5 (CADM-140): a retrospective study, *J. Am. Acad. Dermatol.* 65 (1) (2011) 25–34.
- [5] L. Gitlin, L. Benoit, C. Song, M. Cella, S. Gilfillan, M.J. Holtzman, et al., Melanoma differentiation-associated gene 5 (MDA5) is involved in the innate immune response to paramyxoviridae infection in vivo, *PLoS Pathog.* 6 (1) (2010) e1000734.
- [6] S. Ikeda, M. Arita, M. Morita, S. Ikeo, A. Ito, F. Tokioka, et al., Interstitial lung disease in clinically amyopathic dermatomyositis with and without anti-MDA-5 antibody: to lump or split? *BMC Pulm. Med.* 15 (2015) 159.
- [7] T. Suda, T. Fujisawa, N. Enomoto, Y. Nakamura, N. Inui, T. Naito, et al., Interstitial lung diseases associated with amyopathic dermatomyositis, *Eur. Respir. J.* 28 (5) (2006) 1005–1012.
- [8] G. Ideura, M. Hanaoka, T. Koizumi, K. Fujimoto, Y. Shimojima, W. Ishii, et al., Interstitial lung disease associated with amyopathic dermatomyositis: review of 18 cases, *Respir. Med.* 101 (7) (2007) 1406–1411.
- [9] J.M. Cafardi, N. Sami, Intravenous immune globulin in amyopathic dermatomyositis - report of two cases and review of the literature, *Open Rheumatol. J.* 9 (2015) 77–81.
- [10] R.W. Hallowell, D. Amari, S.K. Danoff, Intravenous immunoglobulin as potential adjunct therapy for interstitial lung disease, *Ann. Am. Thoracic Soc.* 13 (10) (2016) 1682–1688.
- [11] K. Tokunaga, N. Hagino, Dermatomyositis with rapidly progressive interstitial lung disease treated with rituximab: a report of 3 cases in Japan, *Intern. Med.* 56 (11) (2017) 1399–1403.
- [12] Y. Koichi, Y. Aya, U. Megumi, K. Shunichi, S. Masafumi, M. Hiroaki, et al., A case of anti-MDA5-positive rapidly progressive interstitial lung disease in a patient with clinically amyopathic dermatomyositis ameliorated by rituximab, in addition to standard immunosuppressive treatment, *Mod. Rheumatol.* 27 (3) (2017) 536–540.
- [13] E.I. Tuomanen, J. Nedelman, J.O. Hendley, E.L. Hewlett, Species specificity of *Bordetella* adherence to human and animal ciliated respiratory epithelial cells, *Infect. Immun.* 42 (2) (1983) 692–695.
- [14] M. Ducours, P. Rispal, M.P. Danjean, Y. Imbert, E. Dupont, E.M. Traissac, et al., *Bordetella* bronchiseptica infection, *Med. Maladies Infect.* 47 (7) (2017) 453–458.
- [15] N. El Khatib, A. Ferroni, M. Le Bourgeois, F. Chedeveigne, M. Clairicia, H. Avril, et al., Persistent *Bordetella* bronchiseptica infection in a child with cystic fibrosis: relationship to bacterial phenotype, *J. Cyst. Fibros. Offic. J. Eur. Cystic Fibros. Soc.* 14 (5) (2015) E13–E15.
- [16] J.J. Gisel, L.M. Brumble, M.M. Johnson, *Bordetella* bronchiseptica pneumonia in a kidney-pancreas transplant patient after exposure to recently vaccinated dogs, *Transpl. Infect. Dis. Offic. J. Transplant. Soc.* 12 (1) (2010) 73–76.
- [17] E.S. Huebner, B. Christman, S. Dummer, Y.W. Tang, S. Goodman, Hospital-acquired *Bordetella* bronchiseptica infection following hematopoietic stem cell transplantation, *J. Clin. Microbiol.* 44 (7) (2006) 2581–2583.
- [18] Z. Ner, L.A. Ross, M.V. Horn, T.G. Keens, E.F. MacLaughlin, V.A. Starnes, et al., *Bordetella* bronchiseptica infection in pediatric lung transplant recipients, *Pediatr. Transplant.* 7 (5) (2003) 413–417.
- [19] H.R. Powers, K. Shah, *Bordetella* bronchiseptica bloodstream infection in a renal transplant patient, *Transpl. Infect. Dis. Offic. J. Transplant. Soc.* 19 (6) (2017).