

Prenatal Diagnosis of Ectrodactyly in the First Trimester by Three-Dimensional Ultrasonography

Matthew J. Blitz, MD, MBA¹ Burton Rochelson, MD¹

¹Division of Maternal-Fetal Medicine, Department of Obstetrics and Gynecology, Hofstra Northwell School of Medicine, North Shore University Hospital, Manhasset, New York

Address for correspondence Matthew J. Blitz, MD, MBA, Division of Maternal-Fetal Medicine, Hofstra Northwell School of Medicine, North Shore University Hospital, 300 Community Drive, Manhasset, NY 11030 (e-mail: mblitz@northwell.edu).

Am J Perinatol Rep 2016;6:e142–e144.

Abstract

Introduction Ectrodactyly, also known as split hand/foot malformation, is a rare developmental abnormality of the limbs that consists of absent central digits, a deep median cleft, and fusion of the remaining lateral digits, ultimately producing clawlike extremities. This case represents one of the earliest reported diagnoses of this anomaly to utilize three-dimensional (3D) ultrasonography.

Case A nulliparous woman presented at 13 weeks of gestation for first-trimester aneuploidy screening. On two-dimensional (2D) imaging, she was noted to have a fetus with a shortened right upper limb and a malformed right hand with no clearly visualized digits. The anomaly was then further evaluated with both transabdominal and transvaginal 2D and 3D ultrasonography with postprocessing visualization, revealing absent central digits. Neither the patient nor her husband reported any personal or family history of skeletal or other structural malformations.

Discussion Fetal limb abnormalities are being encountered at increasingly earlier gestational ages due to improvements in image quality and expanded use of ultrasound in the first trimester. Early identification of fetal limb malformations without a definitive diagnosis or a clear pattern of inheritance can present a challenging clinical scenario. Patients may opt for earlier termination of pregnancy rather than wait for additional information to guide decision-making.

Keywords

- ▶ ectrodactyly
- ▶ split hand malformation
- ▶ prenatal diagnosis
- ▶ 3D ultrasonography

Ectrodactyly, also known as split hand/foot malformation (SHFM), is a rare developmental abnormality of the limbs that consists of absent central digits, a deep median cleft, and fusion of the remaining lateral digits, ultimately producing clawlike extremities. It can occur as an isolated malformation or as part of various complex syndromes.¹ The estimated incidence of isolated ectrodactyly, in which only the limbs are affected, is 1 in 18,000 births.² Among this group, nearly 80% have only one affected limb with upper limb predominance. Here, we present a case of ectrodactyly diagnosed in the first trimester by two-dimensional (2D) and three-dimensional (3D) ultrasonography. Based on our review of the literature,

this case represents one of the earliest reported diagnoses of this anomaly to utilize 3D ultrasonography.^{3–6}

Case Report

A nulliparous woman presented at 13^{2/7} weeks of gestational age for first-trimester screening for aneuploidy. On 2D imaging, she was noted to have a fetus with a shortened right upper limb and a malformed right hand with no clearly visualized digits. Nuchal translucency was within normal limits, measuring 1.8 mm. The anomaly was then further evaluated with both transabdominal and transvaginal 2D and

received
December 9, 2015
accepted after revision
January 19, 2016

DOI <http://dx.doi.org/10.1055/s-0036-1579653>.
ISSN 2157-6998.

Copyright © 2016 by Thieme Medical Publishers, Inc., 333 Seventh Avenue, New York, NY 10001, USA.
Tel: +1(212) 584-4662.

License terms



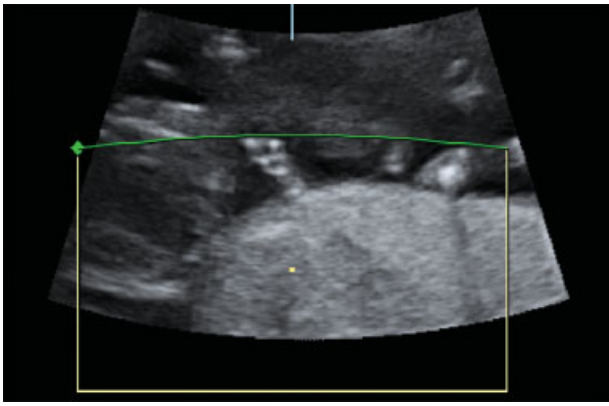


Fig. 1 Two-dimensional ultrasound view (orthogonal plane) of suspected ectrodactyly on right hand at 13^{2/7} weeks of gestational age.

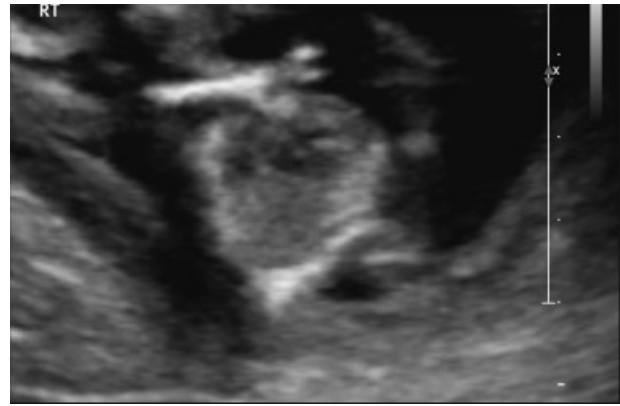


Fig. 3 Two-dimensional ultrasound view of ectrodactyly at 15^{2/7} weeks of gestational age on follow-up ultrasonography.

3D ultrasonography with postprocessing visualization, revealing absent central digits (►Figs. 1 and 2). The differential diagnosis was discussed with the patient, including the possibility of isolated or syndromic ectrodactyly, radial ray aplasia syndromes, Cornelia de Lange syndrome, and amniotic band syndrome. A follow-up ultrasound examination was planned for 2 weeks later. On subsequent imaging at 15^{2/7} weeks, the humerus was short, the forearm was essentially not present, and there was again a clawlike deformity of the right hand (►Figs. 3 and 4). A single umbilical artery was also noted. The visualized anatomy was otherwise normal but limited views of the face and kidneys were obtained, which was attributed to gestational age and maternal body habitus. Fetal biometry was consistent with last menstrual period and early ultrasound. Past medical, obstetrical, and surgical histories were unremarkable. Neither the patient nor her husband reported any personal or family history of skeletal or other structural malformations.

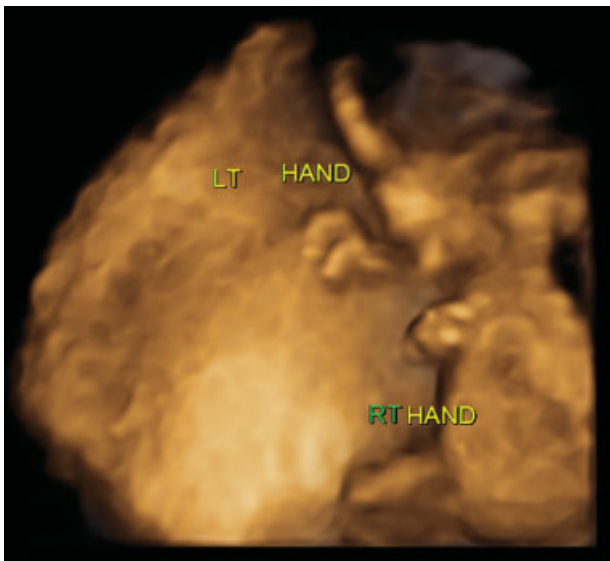


Fig. 2 Three-dimensional ultrasound visualization of absent central digits on right hand at 13^{2/7} weeks of gestational age.

After extensive counseling, the couple opted for termination of pregnancy, regardless of karyotype and other laboratory testing. For the benefit of future preconception counseling, amniocentesis was performed and amniotic fluid sent for testing. Alpha-fetoprotein (AFP), fluorescence in situ hybridization (FISH), comparative genomic hybridization (CGH), and karyotype (46,XX) were normal. A dilation and evacuation procedure was performed. Surgical pathology confirmed the clawlike deformity of the right hand and relatively short foot length for gestational age. The face was too disrupted to identify cleft lip or palate (►Fig. 5). Although the viscera were disrupted, the histology was unremarkable.

Discussion

The term ectrodactyly comes from the Greek words *ektroma* (abortion) and *daktylos* (finger). Other outdated and pejorative terminology is sometimes found in the literature.⁷ The condition results from aberrant development of the hand and/or foot plates during the seventh week of gestation. In normal development, five digital rays arise from the hand and foot plates, and the apical ectodermal ridge (AER) leads the growth and differentiation of each ray. The central rays, which

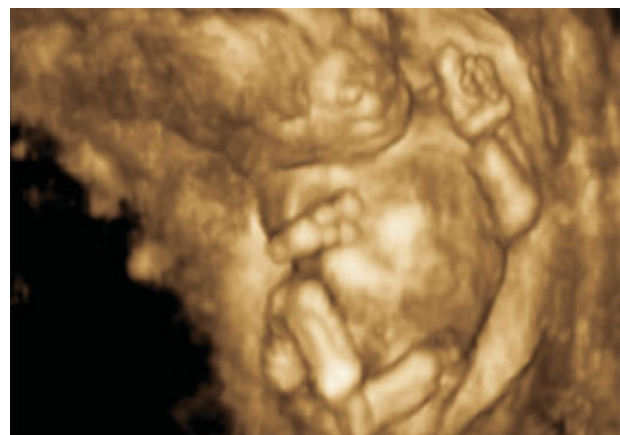

Fig. 4 Ectrodactyly at 15^{2/7} weeks of gestational age on follow-up three-dimensional ultrasonography.

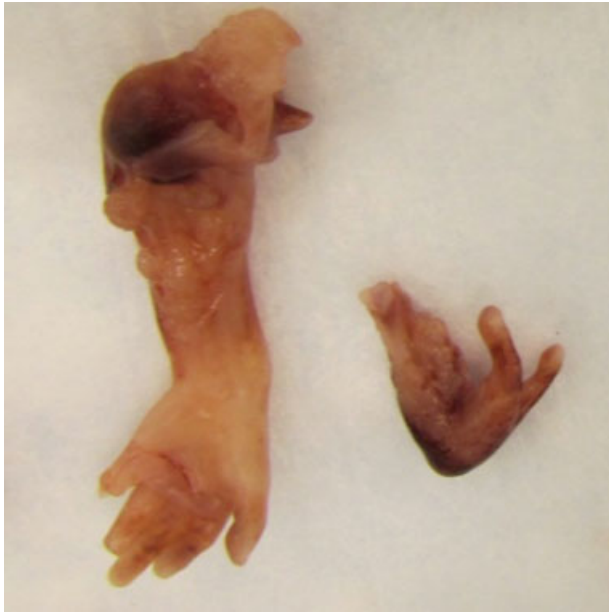


Fig. 5 Macroscopic appearance of normal left hand and abnormal right hand.

form the second, third, and fourth digits, differentiate at a different time from the preaxial (medial) and postaxial (lateral) rays. In cases of ectrodactyly, a central ray defect occurs such that the AER ceases to function normally.^{8,9}

Ectrodactyly may occur as an isolated, sporadic malformation or represent a single component in one of many genetic syndromes. These syndromes represent a genetically heterogeneous spectrum of disorders with wide variability in clinical expression. Five loci for ectrodactyly have been mapped to chromosomes 7q21 (SHFM1), Xq26 (SHFM2), 10q25 (SHFM3), 3q27 (SHFM4), and 2q31 (SHFM5).⁹ The most common mode of inheritance is autosomal dominant with reduced penetrance. Among the various syndromes, the ectrodactyly ectodermal dysplasia cleft palate syndrome is the best described, often occurring in conjunction with genitourinary abnormalities, hearing loss, and dysmorphic facies.

In the above case, it remains uncertain whether this was isolated ectrodactyly or a syndromic condition. Given the early identification of this limb anomaly and a termination procedure that did not provide an intact fetus, the presence or absence of certain sonographic and clinical features supporting either diagnosis could not be fully assessed. The patient was counseled that labor induction may be advantageous for pathologic and genetic evaluation but opted for a dilation and evacuation procedure. The presence of a single umbilical artery, which is associated with an increased incidence of structural and chromosomal anomalies, further supports the possibility of a syndrome but it is not conclusive. Furthermore, the normal results for karyotype, FISH, CGH, and AFP do not exclude the possibility of a syndrome. Given the wide variability in clinical expression of these syndromes, which may manifest as mild dental anomalies such as missing teeth, it was recommended that both parents be examined and that a complete family history be obtained. Early sonographic identification of a fetal malformation without a definitive

diagnosis or a clear pattern of inheritance can present a challenging scenario.

Fetal limb abnormalities are often discovered later in gestation at the time of second-trimester fetal anatomic ultrasound survey, but this is gradually changing due to the increasing prevalence of first-trimester ultrasonography and improvements in image quality. Assessment of fetal anatomy, including the extremities, will likely continue to occur at earlier gestational ages.¹⁰ Increased vigilance must be exercised in couples at high risk for these anomalies based on personal or family history. 3D ultrasonography, when available, may be a valuable adjunct to 2D ultrasonography in the first trimester, and may offer better delineation of complex malformations, particularly those involving the fetal hands and feet.^{11,12} Furthermore, 3D visualization may be helpful when counseling patients about detected anomalies since it is more readily understood by the lay public.

In summary, early identification of fetal limb abnormalities is important because such findings are frequently associated with other anomalies and it provides more time for patient education, counseling, and decision-making. If termination of pregnancy is elected, procedures performed earlier in gestation have a lower risk of complications.

References

- Lu J, Vaidya N, Meng H, et al. Prenatally diagnosed fetal split-hand/foot malformations often accompany a spectrum of anomalies. *J Ultrasound Med* 2014;33(1):167–176
- Czeizel AE, Vitéz M, Kodaj I, Lenz W. An epidemiological study of isolated split hand/foot in Hungary, 1975–1984. *J Med Genet* 1993; 30(7):593–596
- Lapaire O, Schiesser M, Peukert R, Holzgreve W, Tercanli S. Split hand and foot malformation: ultrasound detection in the first trimester. *Ultrasound Obstet Gynecol* 2002;20(5):511–512
- Koo BS, Baek SJ, Kim MR, Joo WD, Yoo HJ. Prenatally diagnosed ectrodactyly at 16 weeks' gestation by 2- and 3-dimensional ultrasonography: a case report. *Fetal Diagn Ther* 2008;24(3):161–164
- Ram KT, Goffman D, Ilagan J, Dar P. First-trimester diagnosis of familial split-hand/split-foot malformation. *J Ultrasound Med* 2009;28(10):1397–1400
- Lévy J, Jouannic JM, Saada J, Dhombres F, Siffroi JP, Portnoi MF. Prenatal diagnosis of bilateral ectrodactyly and radial agenesis associated with trisomy 10 mosaicism. *Case Rep Genet* 2013; 2013:592702
- Elliott AM, Evans JA. Derogatory nomenclature is still being used: the example of split hand/foot. *Am J Med Genet A* 2015;167A(4):928–929
- Buss PW. Cleft hand/foot: clinical and developmental aspects. *J Med Genet* 1994;31(9):726–730
- Duijf PH, van Bokhoven H, Brunner HG. Pathogenesis of split-hand/split-foot malformation. *Hum Mol Genet* 2003;12(Spec No 1): R51–R60
- Rice KJ, Ballas J, Lai E, Hartney C, Jones MC, Pretorius DH. Diagnosis of fetal limb abnormalities before 15 weeks: cause for concern. *J Ultrasound Med* 2011;30(7):1009–1019
- Budorick NE, Pretorius DH, Johnson DD, Tartar MK, Lou KV, Nelson TR. Three-dimensional ultrasound examination of the fetal hands: normal and abnormal. *Ultrasound Obstet Gynecol* 1998;12(4): 227–234
- Hull AD, James G, Salerno CC, Nelson T, Pretorius DH. Three-dimensional ultrasonography and assessment of the first-trimester fetus. *J Ultrasound Med* 2001;20(4):287–293