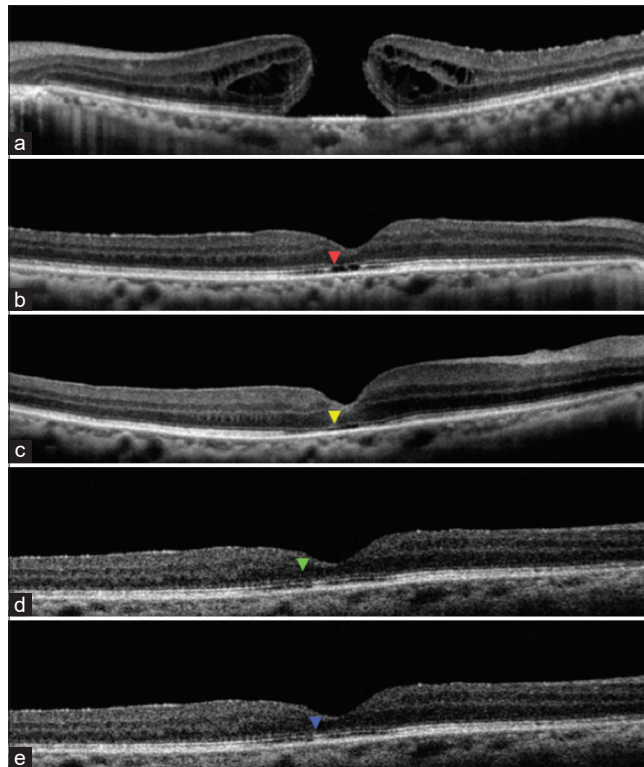


### Erratum: Anatomical and functional outcomes one year after vitrectomy and retinal massage for large macular holes

In the article titled “Anatomical and functional outcomes one year after vitrectomy and retinal massage for large macular holes”, published in pages 895-899, Issue 4, Vol. 69 of Indian Journal of Ophthalmology,<sup>[1]</sup> Fig. 2 had been incorrectly published, OCT image at 6 months [Fig. 2d] was accidentally horizontally flipped. The figure legend and figure number are correct. The corrected figure is as below.



**Figure 2:** OCT scans preoperatively [Figure 1a] and at 1 month [Figure 1b], 3 months [Figure 1c], 6 Months [Figure 1d] and 12 months [Figure 1e] postoperatively with coloured arrowheads showing ellipsoid zone defects gradually reducing

#### Reference

1. Chakraborty D, Sengupta S, Mukherjee A, Majumdar S. Anatomical and functional outcomes one year after vitrectomy and retinal massage for large macular holes. Indian J Ophthalmol 2021;69:895-9.

DOI: 10.4103/0301-4738.346035