

# Challenging the Subcostal Incision Scar with the Two-staged Abdominoplasty: An Innovative Approach

Nehal A. Mahabbat, MBBS\*  
Qutaiba N.M. Shah Mardan,  
MBBS†

Abbas O. Mohamed, MBBS‡

Felwa A. Almarshad, MBBS\*

Mohamed Amir Mrad, MD,  
FRCS, FACS\*

Mohammad M. Al-Qattan, MBBS§

Fuad K. Hashem, MD\*

**Summary:** Abdominoplasty is a commonly sought-after procedure due to its life-transforming results, but is limited, as in any other operation, by a number of contraindications. One of these contraindications is a subcostal scar, which may jeopardize blood supply to the upper flap of the abdominoplasty, resulting in skin necrosis. Herein, we challenge this dogma by introducing the two-staged abdominoplasty with the utilization of a delayed flap in a 48-year-old multiparous woman presenting with a Kocher incision of open cholecystectomy, with good results and a complication-free course of 3 postoperative months. We recommend this approach in patients with subcostal scars. However, more research into the utilization of delayed flaps in abdominoplasty should be done to have a more well-founded conclusion. (*Plast Reconstr Surg Glob Open* 2022;10:e4047; doi: 10.1097/GOX.0000000000004047; Published online 28 January 2022.)

In result-driven healthcare, abdominoplasty has gained more traction and popularity in recent years owing to the advancement in surgical technique and, more than often, satisfying results. It is especially popular among patients with massive post bariatric surgery weight loss.<sup>1,2</sup> Given its popularity, patient selection remains the most important aspect of the procedure because it affects the outcomes drastically. Hence, many surgeons refrain from abdominoplasty in high-risk patients. One of the populations at high risk of postoperative complications are patients with previous vertical or subcostal abdominal scars that have disruptive effect on the abdominal wall blood supply, undermining the results of abdominoplasty<sup>3-5</sup>; patients with Kocher incision after open cholecystectomy pose a selection dilemma, as the rate of complications, especially wound healing issues, increases when traditional abdominoplasty is performed in patients with such

incision.<sup>3,6</sup> To overcome this disadvantage, we propose a refinement in traditional abdominoplasty where the upper flap is treated as a delayed flap, as will be demonstrated in this case report, with excellent results and no postoperative complications.

## CASE PRESENTATION

A 48-year-old multiparous woman with a history of open cholecystectomy 10 years ago presented to the senior author's private clinic, seeking abdominoplasty. Her BMI and HbA1c were found to be 27.3% and 5.6%, respectively. She was known to be a shisha smoker, smoking a head of shisha daily for the past 2 years. A Kocher scar occupying the right upper quadrant was noticed on examination. Initially, the request for surgery was denied due to fear of potential risk of complications imposed by the scar. Notwithstanding, after weighing the risk and benefit and consenting the patient, we decided to perform a two-stage abdominoplasty: flap creation and delay followed by traditional abdominoplasty. After marking the upper incision as in the typical abdominoplasty, an incision was made reaching to the muscular fascia followed by careful cranial dissection in this plane until we bordered the scar. The first stage was concluded by incision closure. On the fifth postoperative day, a bluish discoloration of the area between the cholecystectomy scar and the umbilicus was noticed, signifying ischemia. Henceforth, our original plan of starting the second stage after 2 weeks was rescheduled on the third postoperative week. Finally, the patient was taken for the second stage where a traditional abdominoplasty, with excess tissue excision, rectus plication, and umbilicus relocation, was done starting with the lower incision. On the fifth postoperative day, areas of purple discoloration

*From the \*Plastic and Reconstructive Surgery Section, Department of Surgery, King Faisal Specialist Hospital & Research Centre, Riyadh, Saudi Arabia; †ABAS Medical Centre, Riyadh, Saudi Arabia; ‡College of Medicine, Sulaiman Alrajhi University, Al-Qassim, Saudi Arabia; and §Plastic and Reconstructive Surgery Division, Department of Surgery, College of Medicine, King Saud University, Riyadh, Saudi Arabia.*

*Received for publication February 6, 2021; accepted November 16, 2021.*

*Drs. Nehal Mahabbat and Qutaiba Shah Mardan contributed equally to this work.*

*Copyright © 2022 The Authors. Published by Wolters Kluwer Health, Inc. on behalf of The American Society of Plastic Surgeons. This is an open-access article distributed under the terms of the Creative Commons Attribution-Non Commercial-No Derivatives License 4.0 (CCBY-NC-ND), where it is permissible to download and share the work provided it is properly cited. The work cannot be changed in any way or used commercially without permission from the journal.*

*DOI: 10.1097/GOX.0000000000004047*

**Disclosure:** *The authors have no financial interest to declare in relation to the content of this article.*

bordering the wound edges were noticed, which disappeared gradually. On 3 months follow-up, the wound was healed and the patient was satisfied with the results (Fig. 1).

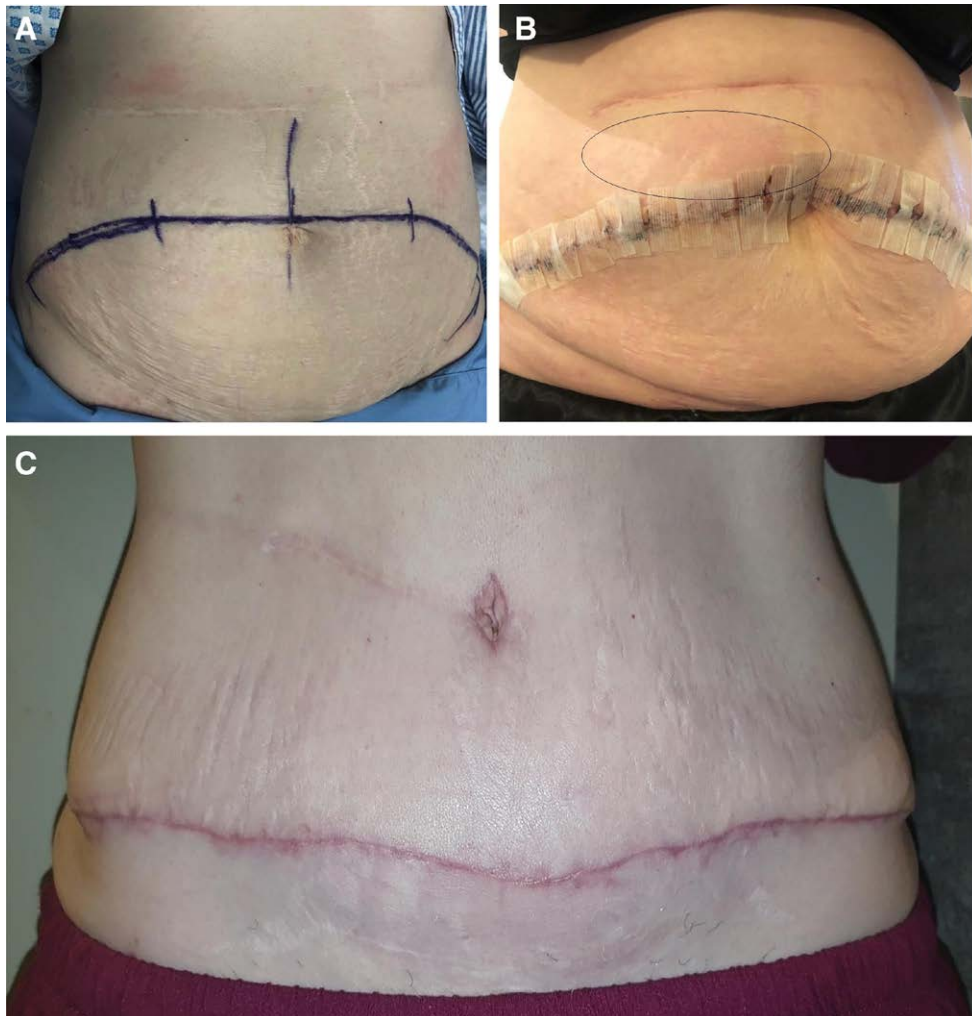
### DISCUSSION

The blood supply to the abdominal wall is categorized into three zones based on the feeding vessels. The midabdominal area is supplied by the deep epigastric arcade and constitutes zone I; the lower abdomen is supplied by the external iliac artery, which constitutes zone II, while the last zone represented by the flanks and lateral abdomen is supplied by intercostal, subcostal, and lumbar arteries. The latter of the three zones is the sole blood source that survives abdominoplasty. The superficial circumflex iliac artery of zone II might be a source of collateral flow.<sup>7</sup> This, in addition to the subcostal scar, is the reason why such cases are challenging.

The concept of delayed flaps has been studied in breast reconstruction after mastectomy, striking a balance between preserving the flap viability and aesthetic

outcome.<sup>8</sup> The premise of a delayed flap is to improve its arterial supply and condition it against ischemia in an interval of seven days to a month from preparation to utilization.<sup>8</sup> This effect is likely due to dilatation of supplying vasculature, as some studies reported an improvement the blood flow and an increase in diameter of the superior epigastric artery after seven days of delay in transverse rectus abdominis muscle flaps.<sup>9,10</sup> Moreover, many studies concluded an improvement in flap reliability and survival rate after a seven-day delay.<sup>11,12</sup> It was also noticed that delayed transverse rectus abdominis muscle flaps showed minimal congestion.<sup>8</sup> This finding was reported in the anatomic studies by Taylor et al (1992), where valve incompetence was noticed in the surrounding veins, allowing venous drainage toward the superior epigastric vein.<sup>10</sup>

In our patient with an open cholecystectomy scar, it was established that the rate of complications, especially flap necrosis, increases if traditional abdominoplasty is performed.<sup>3,5,6</sup> As of other types of abdominal scars, the literature stands in an area of uncertainty and controversy



**Fig. 1.** Photographs showing the patient's abdomen before and after the two-staged abdominoplasty. A, The abdomen at the preoperative period with the surgical marking for stage I. Please note the transverse subcostal scar at the right upper quadrant. B, After stage I. Please notice the bluish discoloration circled in black indicating ischemia, most prominent at the upper edge of the wound just above the midline. C, The outcome 3 months postoperatively.

when it comes to the complication rate in patients undergoing traditional abdominoplasty. De Castro et al showed that the risk grows higher in patients with supraumbilical scars.<sup>3</sup> On the contrary, other studies showed no significant increase in risk, as suggested by Momeni et al.<sup>4</sup> Shermak et al in their retrospective analysis of 420 abdominoplasty cases, of which 29 (7%) had a preexisting Kocher incision, reported no relationship between the latter or upper midline incisions and healing complications<sup>13</sup>; however the nature of the design and the limited number of cases with the Kocher incision require more studies before making the choice of abdominoplasty in such cases possible.

In this case report, traditional abdominoplasty was performed in two stages, involving flap delay, in a patient with subcostal scar that imposes risk of skin necrosis. This modification is introduced for the first time in the literature and helps this category of patients to achieve their cosmetic goals. The disadvantage of this approach includes exposure to general anesthesia twice, which increases perioperative complication risk and an uncomfortable course for the patient. However, the first stage could be done under local anesthesia if agreement between the surgeon and patient is reached; in our case, general anesthesia was elected by the patient. Although this innovative approach came with excellent results in our case, large-scale prospective studies are required to make the findings of this article more robust. Furthermore, this technique can be done in the presence of horizontal subcostal scars, but its reliability is not tested in case of vertical scars.

### CONCLUSIONS

Performing abdominoplasty on patients with subcostal scars could be implied as an act of “asking for trouble,” as evident by increased rates of skin necrosis. However, this could be avoided through using the two-staged abdominoplasty modification by employing a delayed flap. This case report demonstrated its use in a patient with an open cholecystectomy scar with excellent results and no complications. We advocate its use in the presence of subcostal incisions, but studies with the proper design are required before making it a common practice.

**Fuad K. Hashem, MD**

Plastic and Reconstructive Surgery Section  
Department of Surgery  
King Faisal Specialist Hospital & Research Centre  
P.O. Box 3354  
Riyadh 11211  
Saudi Arabia  
E-mail: fuadkhashem@gmail.com

### ACKNOWLEDGMENT

*This case report conforms to the Declaration of Helsinki.*

### REFERENCES

1. Regan JP, Casaubon JT. Abdominoplasty. In: StatPearls. StatPearls Publishing; 2020. <http://www.ncbi.nlm.nih.gov/books/NBK431058/>. Accessed February 7, 2021.
2. Hafezi F, Nouhi A. Safe abdominoplasty with extensive liposuctioning. *Ann Plast Surg.* 2006;57:149–153.
3. de Castro CC, Aboudib Júnior JH, Salema R, et al. How to deal with abdominoplasty in an abdomen with a scar. *Aesthetic Plast Surg.* 1993;17:67–71.
4. Momeni A, Heier M, Bannasch H, et al. Complications in abdominoplasty: a risk factor analysis. *J Plast Reconstr Aesthet Surg.* 2009;62:1250–1254.
5. Acevedo E, Nadhan KS, Everett M, et al. Corset trunkplasty: recommended with abdominal skin laxity and open cholecystectomy scar. *Plast Reconstr Surg.* 2018;141:60–69.
6. Seung-Jun O, Thaller SR. Refinements in abdominoplasty. *Clin Plast Surg.* 2002;29:95,vi–109, vi.
7. Friedland JA, Maffi TR. MOC-PS(SM) CME article: abdominoplasty. *Plast Reconstr Surg.* 2008;121(4 Suppl):1–11.
8. Codner MA, Bostwick J III. The delayed TRAM flap. *Clin Plast Surg.* 1998;25:183–189.
9. Restifo RJ, Ward BA, Scoutt LM, et al. Timing, magnitude, and utility of surgical delay in the TRAM flap: II. Clinical studies. *Plast Reconstr Surg.* 1997;99:1217–1223.
10. Taylor GI, Corlett RJ, Caddy CM, et al. An anatomic review of the delay phenomenon: II. Clinical applications. *Plast Reconstr Surg.* 1992;89:408–416; discussion 417.
11. Erdmann D, Sundin BM, Moquin KJ, et al. Delay in unipedicled TRAM flap reconstruction of the breast: a review of 76 consecutive cases. *Plast Reconstr Surg.* 2002;110:762–767.
12. Ozgentaş HE, Shenaq S, Spira M. Study of the delay phenomenon in the rat TRAM flap model. *Plast Reconstr Surg.* 1994;94:1018–1024; discussion 1025.
13. Shermak MA, Mallalieu J, Chang D. Do preexisting abdominal scars threaten wound healing in abdominoplasty? *Eplasty.* 2010;10:e14.