

## CASE REPORT

# First case of concomitant cytomegalovirus (CMV) viremia in non-immunocompromised COVID-19 patient and ICU management strategy in Qatar with literature review

Phool Iqbal<sup>1</sup>  | Suresh Menik Arachchige<sup>2</sup>  | Yousra Ali<sup>2</sup> | Muhammad Sohaib Qamar<sup>3</sup> | Hani Walid Jaouni<sup>1,4</sup> | Ahmed Lutfе Mohamad Abdussalam<sup>1,4</sup>

<sup>1</sup>Medical Intensive Care Department, Hamad Medical Corporation, Doha, Qatar

<sup>2</sup>Department of Internal Medicine, Hamad Medical Corporation, Doha, Qatar

<sup>3</sup>Department of Medicine, Ozarks Medical Center, West Plains, Missouri, USA

<sup>4</sup>Clinical Medicine, Weill Cornell Medicine Qatar, Ar-Rayyan, Qatar

## Correspondence

Suresh Menik Arachchige, Department of Internal Medicine, Hamad Medical Corporation, Doha, Qatar.  
Email: [nalakamenik@live.com](mailto:nalakamenik@live.com)

## Funding information

Qatar National Library

## Abstract

COVID-19 has created one of the world's worst pandemics and is associated with various life-threatening complications and infections, possibly due to various internal and external host factors. Cytomegalovirus (CMV) coinfection is one of those infections. We present a challenging case of severe COVID-19 infection managed in our ICU care facility with concomitant CMV infection. We aim to highlight the significance of early diagnosis and prompt management for a better outcome.

## KEYWORDS

coinfection, COVID-19, cytomegalovirus, SARS-CoV-2

## 1 | INTRODUCTION

The World Health Organization has labeled the COVID-19 a global pandemic with over 150 million cases and more than 3.5 million recorded deaths worldwide as of May 2021.<sup>1</sup> Many countries have faced multiple outbreaks of this infection, with numerous reports of associated complications. The most common complications include cytokine storm leading to tissue damage, lung injury, venous/arterial thrombosis, stroke, and myocardial infarction.<sup>2</sup> Out of these complications, coinfection with life-threatening organisms such as tuberculosis, fungal infection, and other viruses such as Epstein–Barr Virus

(EBV) and cytomegalovirus (CMV), can also occur, which is usually associated with an immunocompromised state.<sup>3,4</sup> Evidence on the management of these patients is lacking, and currently, there are no standard guidelines. We present such a case of concomitant CMV infection in COVID-19 patient who was critically ill and managed in ICU with a follow-up outcome.

## 2 | CASE SUMMARY

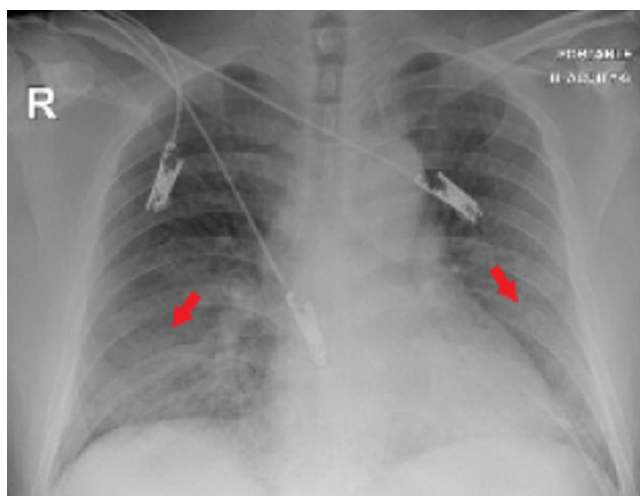
A 50-year-old hypertensive Filipino gentleman presented to the emergency department (ED) with a 1-week dry

This is an open access article under the terms of the [Creative Commons Attribution-NonCommercial-NoDerivs](https://creativecommons.org/licenses/by-nc-nd/4.0/) License, which permits use and distribution in any medium, provided the original work is properly cited, the use is non-commercial and no modifications or adaptations are made.

© 2022 The Authors. *Clinical Case Reports* published by John Wiley & Sons Ltd.

cough and high-grade fever history. There was associated fatigue, arthralgias, and myalgias. On presentation to the ED, his vital signs showed tachypnea of 26 breaths/min with desaturating to 85% and requiring oxygen supplementation of 10–15L/min through a non-rebreather mask, sinus tachycardia at around 110 beats/min, and blood pressure of around 150/100 mmHg–175/112 mmHg. In the light of ongoing COVID-19 pandemic, he was tested for COVID-19 PCR from nasopharyngeal swab and turned out to be positive. His chest XR revealed bilateral infiltrates predominantly in the lower zones, as shown in Figure 1. Therefore, as there was tachycardia and tachypnea, a CT pulmonary angiogram (CTPA) was performed to rule out pulmonary embolism (PE). However, it was remarkable for bilateral ground-glass attenuation of the upper lobes and bilateral lower lobes segmental consolidation with bronchogram and no evidence of PE. His overall clinical picture suggested severe COVID-19 pneumonia leading to acute respiratory distress syndrome (ARDS). He was started on COVID-19 management protocol as per local guidelines. However, his clinical condition deteriorated on the 6th day of hospitalization. He had worsening tachypnea in the range of 40–45 breaths/min and had desaturation below 85% even after keeping on 100% Fio through continuous positive airway pressure (CPAP) ventilation. He did not improve and thus was intubated and put on mechanical ventilation. He had fever spikes above 39°C, sepsis workup including blood, deep tracheal aspirate, fungal, and urine cultures was requested along with inflammatory markers such as C-reactive protein, procalcitonin, and interleukins to look for features of cytokine storm as well.

Meanwhile, he was covered empirically with broad-spectrum antibiotics and antifungals, that is, meropenem, vancomycin, and anidulafungin. His sepsis



**FIGURE 1** Chest XR showing bilateral haziness and infiltrates, especially in the lower zones as marked with red arrows

workup was unremarkable and did not show any organism growth. His inflammatory markers were high, and he was continuously febrile with borderline mean arterial pressure of 60–65 mmHg, requiring inotropic support. He was clinically deteriorating, and his PaO<sub>2</sub> was not improving, despite proning him multiple times. His PF ratio remained below 100. CT scan of the thorax was done and did not show any PE or barotrauma but similar ground-glass opacities and infiltrates present in the initial CTPA as shown in Figure 2. Therefore, he was placed on venovenous extracorporeal membrane oxygenation (V-V ECMO).

The patient had clinical improvement, and thus, it was decided to extubate the patient on the 25th day of his hospitalization. However, he had tachypnea, and difficulty breathing was re-intubated on the 31st day. Chest XR revealed new lung infiltrates in the left upper zone and raised suspicion of a new infection. Urgent bronchoscopy and subsequent bronchoalveolar lavage fluid cultures were sent, including CMV, EBV, adenovirus, fungal, and tuberculosis infection. Meanwhile, sepsis workup was repeated, including blood, urine, and other respiratory viruses PCR. Blood cultures grew *Enterococcus faecalis*, and tracheal aspirate showed *Klebsiella pneumoniae*. He was given a course of antibiotics according to the sensitivities of the cultures. Still, on antibiotics, he was having mild-to-moderate fever.

Meanwhile, his BAL cultures came out to be positive for CMV along with blood cultures remarkable for CMV viremia and labeled as CMV pneumonitis. He was immediately commenced on IV Ganciclovir 375 mg BID and monitored CMV PCR as per Infectious disease (ID) specialist consultation. His overall clinical condition improved. The patient was tracheostomized and was de-cannulated off ECMO successfully. His GCS stabilized, and he could open his eyes and follow simple commands. According to the ID specialist's recommendation, the patient was followed with repeat CMV PCR to optimize the anti-viral therapy. The trend of CMV PCR viral load is shown in Figure 3. On further follow-up, the patient remained stable for 2 months and continued physical rehabilitation therapy for critical care myopathy.

### 3 | DISCUSSION

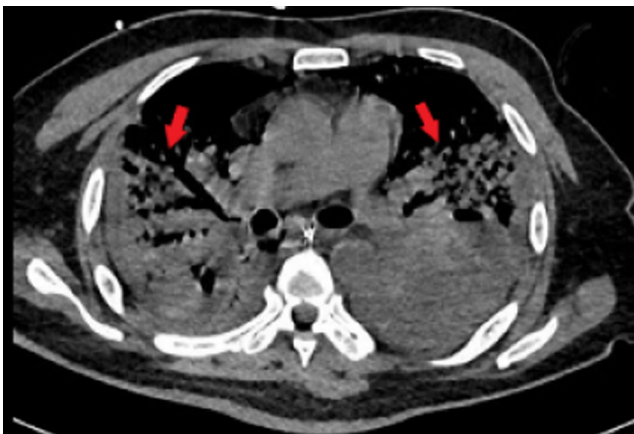
Since the beginning of the COVID-19 pandemic, the world has struggled to cope with the infection and its aftermath. There are many associated fatal complications, including myocardial infarction, stroke, pulmonary embolism, dysregulated immunity leading to serious life-threatening cytokine storm and risk of serious coinfections such as

fungal infection of mucormycosis (aka black fungus), viral infections such as CMV, EBV, and tuberculosis as well that are associated with high mortality if not managed promptly.<sup>5-7</sup> CMV viremia is common in immunocompromised states, especially in solid organ transplant patients.<sup>8</sup> It is reported in the literature that an immunosuppressive state due to dysregulated immunity or certain immune modulators such as tocilizumab or steroids in COVID-19 patients can lead to CMV viremia, as seen in our case.<sup>9-11</sup> We have found few similar articles reported in the literature highlighting the significance of CMV infection management in COVID-19 patients with management approach and outcome as mentioned in Table 1.<sup>9,10,12-20</sup>

Our patient was not immunocompromised; however, one possibility that could have led to concomitant CMV infection would be dysregulated immunity due to underlying severe COVID-19 infection creating an immunocompromised state.<sup>3,6</sup> Furthermore, immunosuppressive

medications such as steroids and tocilizumab can also suppress immunity along with COVID-19-induced dysregulated immunity making a patient prone to life-threatening infections.<sup>3,7,9-11</sup> Currently, there are no international standard management guidelines for such a challenging scenario of CMV infection in COVID-19 patients. However, in the literature, it is reported that early diagnosis of CMV viremia in highly suspected COVID-19 patients and management with anti-viral therapy, that is, ganciclovir, valganciclovir, and in some instances with Foscarnet, can be of proven benefit. The duration of the treatment is inconsistent among the studies. However, the patients have generally improved within 1–2 weeks of therapy.<sup>12</sup> Our patient was getting critically ill during the hospital stay and was managed at every point aggressively and promptly. Moreover, his management of CMV infection at the time of diagnosis optimized his further care, and he was stabilized.

COVID-19 patients are prone to life-threatening complications and infections, and CMV infection is one of the conditions that can lead to a fatal outcome. In our perspective, patient with severe COVID-19 disease that has partial or no response to supportive/local management or clinical deterioration needs to be investigated according to the hospital resources for superseded coinfections like CMV viremia as seen in our case with the initiation of empiric therapy to optimize the patient care for better outcome.<sup>21</sup>



**FIGURE 2** CT thorax showing bilateral ground-glass opacities, especially in the lower zones marked with red arrows

#### 4 | CONCLUSION

We aim to highlight the significance of life-threatening coinfections like CMV viremia in COVID-19 patients. It depends on the patient clinical state, physician's assessment, and availability of hospital resources. Early

**FIGURE 3** CMV PCR viral load trend during the course of hospital stay and management

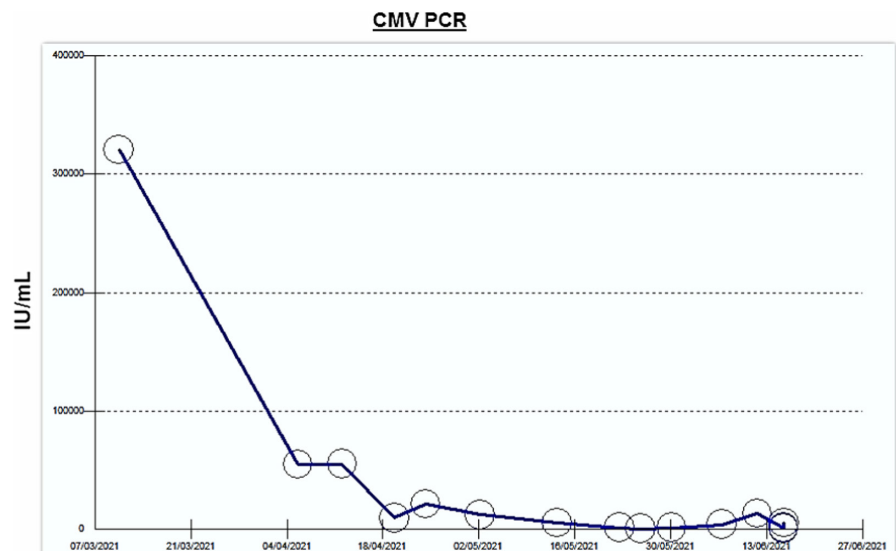


TABLE 1 "Literature review of CMV viremia cases showing management approach and outcome"

Journal name and author	Type of study and DOI	Age (yrs)	Comorbid conditions	COVID-19 severity	COVID-19 treatment	CMV treatment	Outcome
European Journal of case reports in Internal Medicine	Case report (10.112890/2020_001911)	62	None	Severe ARDS	Vasoactive drugs, corticosteroids, proning, and ECMO	Ganciclovir	Complete recovery and discharge
BMJ open Gastroenterology	Case report (10.1136/bmjga-st-2020-000556)	45-65	None	Severe ARDS	Remdesivir, convalescent plasma, systemic hydrocortisone, tocilizumab, and ECMO	Ganciclovir, foscarnet for persistent symptoms after excluding drug resistance.	Improved and discharged to inpatient skilled nursing facility on TPN and supplemental enteral nutrition.
European Journal of case reports in Internal Medicine	Case report (10.112890/2020_001652)	92	Diabetes mellitus and hypertension	Severe ARDS	Lopinavir/ritonavir and hydroxychloroquine	None	Patient passed away from severe respiratory failure
ID cases Journal, Elsevier	Case report (10.1016/j.idcr.2020.e00962)	68	Hypertension and glaucoma	Severe ARDS	Hydroxychloroquine, ECMO, tocilizumab, and remdesivir	Intravenous ganciclovir	Not mentioned
Research Square	Observational study (10.21203/rs.3.rs-52829/v1)	60s	None	Severe ARDS	Steroids and ECMO	NA	Not mentioned
The Pan African Medical Journal	Case report (10.11604/pamj.2020.36.167.23922)	37	NA	NA	NA	None	Patient back to his baseline at 2-week follow-up.
Journal Of Postgraduate Medicine	Case report (10.4103/jpgm.JPGM_1168_20)	75	Hypertension	Severe ARS	Methylprednisolone, hydroxychloroquine, azithromycin, remdesivir, and convalescent plasma.	Intravenous ganciclovir	Clinical improvement
Infectious Diseases Now, Elsevier	Retrospective study (10.1016/j.idnow.2021.01.005)	Median age 56	Hypertension (47%), diabetes mellitus (32%), diffuse Lung disease (38%)	Moderate to severe	Lopinavir-ritonavir, Interferon, remdesivir, Hhydroxychloroquine, tocilizumab, and corticosteroid	Ganciclovir in 2 cases, valganciclovir in 1 case	Pts with CMV viremia were treated successfully with clinical improvement.

TABLE 1 (Continued)

Journal name and author	Type of study and DOI	Age (yrs)	Comorbid conditions	COVID-19 severity	COVID-19 treatment	CMV treatment	Outcome
Clinical Case Reports, Wiley Online	Case report (10.1002/ccr3.3487)	42	None	Severe ARDS	Tocilizumab, hydroxychloroquine, antibiotics, antifungals, and methylprednisolone	Ganciclovir	Had left hemicolectomy was discharged to a rehab center.
Clinical Case Reports, Wiley Online	Case report (10.1002/ccr3.3600)	71	Post-tuberculosis aspergilloma	Severe COVID pneumonia	Hydrocortisone	Ganciclovir	He was discharged from the ICU
ID cases, Elsevier	Case report (10.1016/j.idcr.2021.e01111)	75	Diabetes mellitus and overweight (BMI 26.2)	Severe COVID-19 infection	Dexamethasone, ceftriaxone, spiramycin, oral lopinavir/ritonavir, and anakinra	Oral valganciclovir	Underwent recto sigmoidoscopy

investigation and diagnosis in highly suspected CMV viremia in COVID-19 with prompt management can avoid fatal outcomes like sepsis and death.

## ACKNOWLEDGEMENTS

This study was funded by Qatar National Library.

## AUTHOR CONTRIBUTION

Dr. Phool Iqbal contributed to case identification, literature search, manuscript writing, editing, and supervising. Dr. Suresh Menik Arachchige served as corresponding author and contributed to literature search, editing, and manuscript writing. Dr. Youssa Ali wrote the manuscript. Dr. Muhammad Sohaib Qamar involved in manuscript editing and literature review. Dr. Ahmed Abdussalam and Dr. Hani Jaouni contributed to case management, manuscript editing, and supervision.

## ETHICAL APPROVAL

This manuscript has not been published and is not considered for publication elsewhere. The authors have no conflicts of interest to disclose. All the authors have reviewed and agreed to the content present in this article.

## CONSENT

Written informed consent was obtained from the patient to publish this case report. A copy of the written consent is available for review by the Editor-in-Chief of this journal upon request.

## ORCID

Phool Iqbal  <https://orcid.org/0000-0003-3472-9281>

Suresh Menik Arachchige  <https://orcid.org/0000-0002-5480-7876>

## REFERENCES

1. Covid19.who.int. 2021. *WHO Coronavirus (COVID-19)*. [online] <https://covid19.who.int> Accessed June 3, 2021.
2. SeyedAlinaghi S, Afsahi AM, MohsseniPour M, et al. Late complications of COVID-19; a systematic review of current evidence. *Arch Acad Emerg Med*. 2021;9(1):e14. doi:10.22037/aaem.v9i1.1058
3. Ghosh K. COVID-19 pneumonia, immunosuppression, and cytomegalovirus activation: a perspective. *Trop Med Infect Dis*. 2021;67(2):65-66. Editorial commentary.
4. CASE IPTA. 237 coinfection with COVID-19 and cytomegalovirus in kidney transplant recipients—a case series.
5. Iqbal P, Laswi B, Jamshaid MB, et al. The role of anticoagulation in post-COVID-19 concomitant stroke, myocardial infarction, and left ventricular thrombus: a case report. *Am J Case Rep*. 2021;22:e928852.
6. Sharma S, Grover M, Bhargava S, Samdani S, Kataria T. Post coronavirus disease mucormycosis: a deadly addition to the pandemic spectrum. *J Laryngol Otol*. 2021;135(5):442-447.



7. Lansbury L, Lim B, Baskaran V, Lim WS. Coinfections in people with COVID-19: a systematic review and meta-analysis. *J Infect*. 2020;81(2):266-275.
8. Ramanan P, Razonable RR. Cytomegalovirus infections in solid organ transplantation: a review. *Infect Chemother*. 2013;45(3):260-271.
9. Carll WC, Rady MY. Cytomegalovirus haemorrhagic enterocolitis associated with severe infection with COVID-19. *Clin Case Rep*. 2021;8(1):e000556.
10. Khatib MY, Shaik KS, Ahmed AA, Alwraidat MA, Mohamed AS. Tocilizumab-induced cytomegalovirus colitis in a patient with COVID-19. *Clin Case Rep*. 2021;9(1):148-152.
11. Merchant EA, Flint K, Barouch DH, Blair BM. Coinfection with coronavirus disease 2019, previously undiagnosed human immunodeficiency virus, *Pneumocystis jirovecii* pneumonia and cytomegalovirus pneumonitis, with possible immune reconstitution inflammatory syndrome. *Idcases*. 2021;24:e01153.
12. Amaral PH, Ferreira BM, Roll S, et al. COVID-19 and cytomegalovirus co-infection: a challenging case of a critically ill patient with gastrointestinal symptoms. *Eur J Case Rep Intern Med*. 2020;7(10):1911.
13. D'Ardes D, Boccatonda A, Schiavone C, et al. A case of coinfection with SARS-COV-2 and cytomegalovirus in the Era of COVID-19. *Eur J Case Rep Int Med*. 2020;7(5):1.
14. Geisen WR, Berger J, Schwartz C, et al. Cytomegalovirus enterocolitis secondary to experimental COVID-19 therapy. *Idcases*. 2020;22:e00962.
15. Im JH, Lee J-S, Kwon HY, Chung M-H, Baek J. Epstein-Barr virus and cytomegalovirus reactivation in patients with COVID-19. 2020.
16. Leemans S, Maillart E, Van Noten H, et al. Cytomegalovirus haemorrhagic colitis complicating COVID-19 in an immunocompetent critically ill patient: a case report. *Clin Case Rep*. 2021;9(5):e03600.
17. Maillet F, Pourbaix A, le Pluart D, et al. Cytomegalovirus proctitis as a complication of COVID-19 with immunosuppressive treatments. *Idcases*. 2021;24:e01111.
18. Oualim S, Elouarradi A, Hafid S, Naitelhou A, Sabry M. A misleading CMV myocarditis during the COVID-19 pandemic: case report. *Pan Afr Med J*. 2020;36:167.
19. Shah M, Kakar A, Gogia A, Langer S. Convalescent plasma, cytomegalovirus infection, and persistent leukopenia in COVID-19 recovery phase: What is the link? *J Postgrad Med*. 2021;67(2):100-102.
20. Simonnet A, Engelmann I, Moreau A-S, et al. High incidence of Epstein-Barr virus, cytomegalovirus, and human-herpes virus-6 reactivations in critically ill patients with COVID-19. *Infect Dis Now*. 2021;51(3):296-299.
21. Bienvenu A-L, Bleyzac N, Richard J-C, Leboucher G. No time for pending confirmation of invasive fungal disease in critically ill COVID-19 patients—think empirical treatment. *Crit Care*. 2020;24(1):588.

**How to cite this article:** Iqbal P, Menik Arachchige S, Ali Y, Qamar MS, Jaouni HW, Abdussalam ALM. First case of concomitant cytomegalovirus (CMV) viremia in non-immunocompromised COVID-19 patient and ICU management strategy in Qatar with literature review. *Clin Case Rep*. 2022;10:e05783. doi:[10.1002/ccr3.5783](https://doi.org/10.1002/ccr3.5783)