



Carotid pseudoaneurysm in a kitten after accidental puncture with a needle

Allyson Sterman¹, Vanna Dickerson¹, Andra Voges², Sarai Milliron³ , Dominique Wiener³ and Kelley M Thieman Mankin¹

Journal of Feline Medicine and Surgery Open Reports
1–7

© The Author(s) 2022

Article reuse guidelines:

sagepub.com/journals-permissions

DOI: 10.1177/2055116922118554

journals.sagepub.com/home/jfmsopenreports

This paper was handled and processed by the American Editorial Office (AAFP) for publication in *JFMS Open Reports*



Abstract

Case summary A 3-month-old intact male domestic shorthair kitten's cervical region was inadvertently punctured during routine subcutaneous fluid administration. A swelling rapidly developed on the left lateral neck and continued to grow, despite compression. An emergency facility evaluated the kitten 48 h later and the swelling was determined to be blood. Fine-needle aspiration of the swelling resulted in further swelling of the mass on the neck. The kitten began showing signs of systemic shock, necessitating a blood transfusion. The kitten was referred to a tertiary facility 24 h later for further diagnostics and treatment. CT of the head and neck revealed a large fluid-filled mass with progressive contrast enhancement noted during the filling phase, consistent with active hemorrhage. A carotid pseudoaneurysm was suspected and surgery was recommended. The left carotid artery was ligated proximal to the pseudoaneurysm; hemorrhage continued and the swelling was further explored. A small connection to the carotid artery within the medial aspect of the swelling was identified and ligated. The kitten required autotransfusion and massive allotransfusion during surgery due to blood loss. Recovery was uneventful. A head tilt and Horner's syndrome were noted postoperatively and improved over the following months. Histopathology was consistent with pseudoaneurysm.

Relevance and novel information This is the first reported case of pseudoaneurysm in a kitten that was treated surgically, with massive blood transfusion and minimal complications. Early surgical intervention can result in excellent prognosis. The need for blood product administration should be anticipated.

Keywords: Soft tissue surgery; pseudoaneurysm; blood transfusion; vascular

Accepted: 22 July 2022

Introduction

An aneurysm is a filling defect of at least 50% of the original vessel diameter and most often associated with weakening of the vessel wall, but all three layers of the vessel remain intact. A pseudoaneurysm is a collection of blood (or false lumen) adjacent to an artery that develops following disruption of the tunica intima and media layers, but not the adventitia. It can also be known as a false aneurysm or communicating hematoma as the appreciated hematoma is still in direct contact with the leaking vessel.¹ In veterinary medicine, aneurysms are more commonly reported than pseudoaneurysms. Advanced imaging or surgery are often required to distinguish between the two defects. There are limited case reports of pseudoaneurysm in feline

patients after surgery or venipuncture.^{2,3} The most common causes of pseudoaneurysm in humans include blunt or penetrating trauma.²

¹Department of Veterinary Small Animal Clinical Sciences, Texas A&M University, College Station, TX, USA

²Department of Large Animal Clinical Sciences, Texas A&M University, College Station, TX, USA

³Department of Veterinary Pathobiology, Texas A&M University, College Station, TX, USA

Corresponding author:

Vanna Dickerson DVM, MS, DACVS-SA, Department of Veterinary Small Animal Clinical Sciences, College of Veterinary Medicine, Texas A&M University, 4474 TAMU, College Station, TX 77843, USA

Email: vmdickerson@cvm.tamu.edu



Creative Commons Non Commercial CC BY-NC: This article is distributed under the terms of the Creative Commons

Attribution-NonCommercial 4.0 License (<https://creativecommons.org/licenses/by-nc/4.0/>) which permits non-commercial use, reproduction and distribution of the work without further permission provided the original work is attributed as specified on the SAGE and Open Access pages (<https://us.sagepub.com/en-us/nam/open-access-at-sage>).

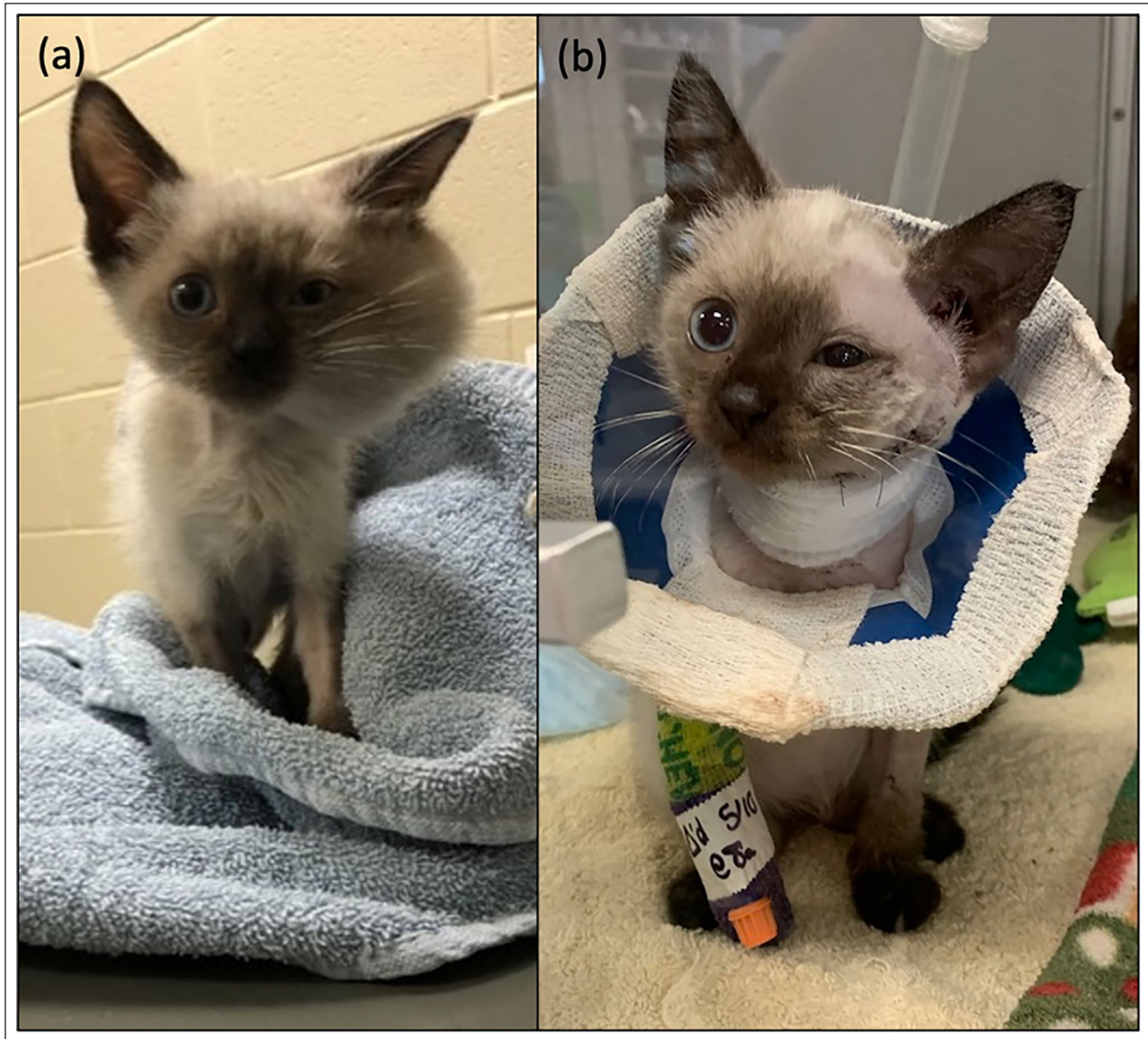

Figure 1 Appearance of a 3-month-old kitten with a left-sided carotid pseudoaneurysm (a) before and (b) immediately after surgical treatment

The kitten in this report was diagnosed with a carotid pseudoaneurysm after accidental trauma during administration of subcutaneous fluids. Attempted medical and surgical treatments are described.

Case description

A 3-month-old male intact domestic shorthair cat weighing 0.62 kg presented to the Texas A&M University Small Animal Teaching Hospital for evaluation of a large cervical swelling. The kitten first presented to the referring veterinarian for an examination prior to being adopted. At that time, the kitten was dehydrated and subcutaneous fluids were administered. During subcutaneous fluid administration, the kitten moved unexpectedly and the needle entered the ventral aspect of the left side of the neck. A swelling was immediately noted, the

needle was removed and manual compression over the puncture site was applied until the swelling remained static in size. No significant bleeding was noted at the site of the puncture. The kitten was discharged to the owner's care. The swelling increased over the next 48 h and the kitten was taken to a different specialty hospital for assessment. The veterinarian performed a fine-needle aspiration of the swelling and frank blood was withdrawn. Following the aspirate, the kitten exhibited signs of hypovolemic shock and a blood transfusion was administered. The kitten was subsequently referred to our institution approximately 24 h later.

On physical examination the kitten was bright, alert and responsive. A large swelling was present on the left side of the neck and was approximately 4 cm in diameter (Figure 1a). On palpation, the swelling was immobile

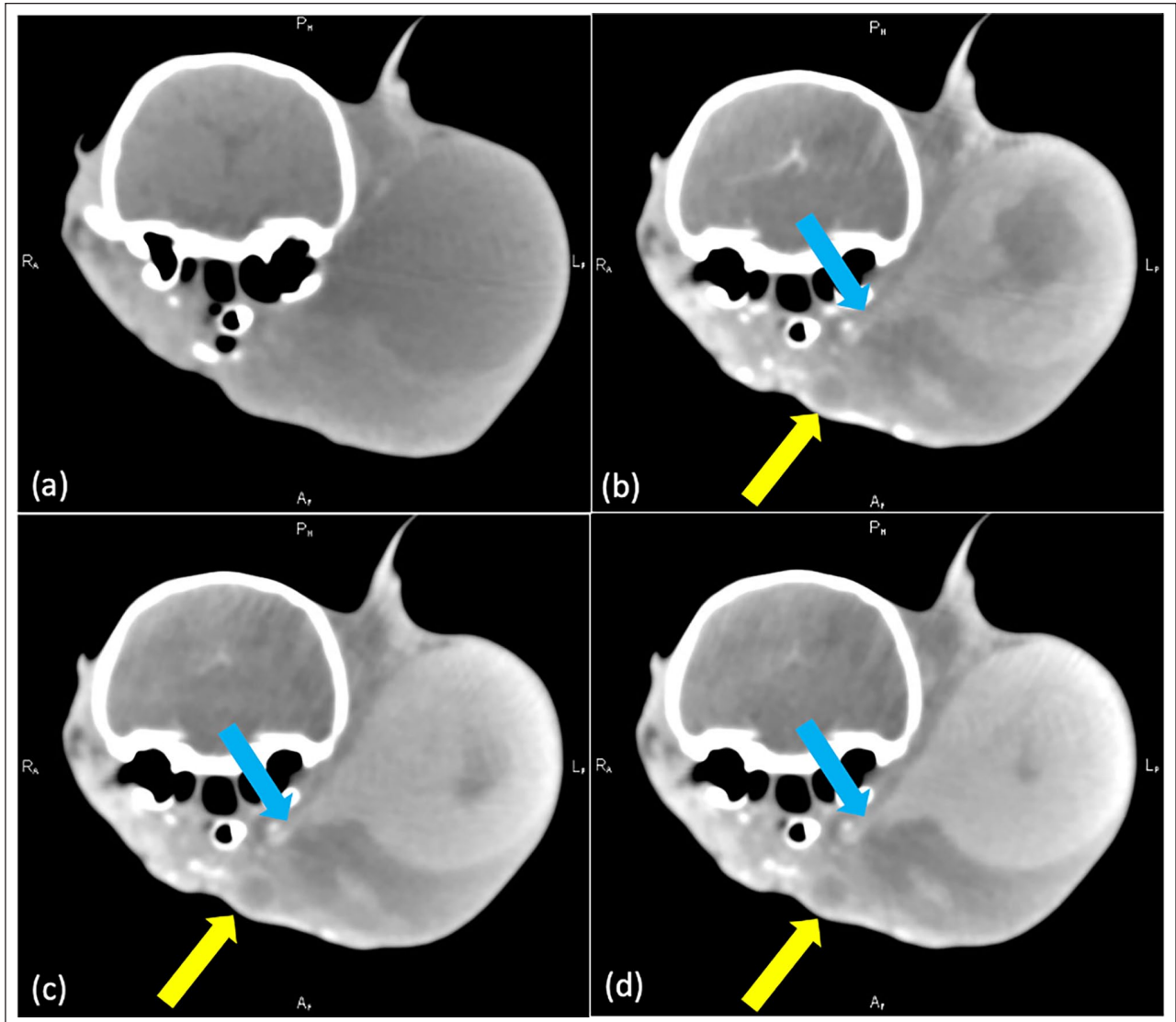


Figure 2 Sequential transverse images through the left caudal head at the level of the tympanic bulla illustrating progressive contrast filling of the swelling over time. (a) Precontrast, with approximately 1 min intervals between (b), (c) and (d). The blue arrow indicates communication with the left common carotid artery. The yellow arrow indicates a similar region of fluid attenuation with peripheral contrast enhancement representing additional hemorrhage, hematoma or a communicating compartment

and firm with focal softer areas. Bloodwork was performed, including a coagulation panel, complete blood count (CBC) and serum chemistry profile. Coagulation parameters were within the normal range (prothrombin time 17s, reference interval [RI] 13–22; partial thromboplastin time 69s [RI 60–115]). On CBC, a moderate regenerative anemia was present (hematocrit 18% [RI 24–45] with 296,000 reticulocytes). Platelets were clumped but appeared adequate on blood smear, no blood parasites were seen and a saline agglutination test was negative. No abnormalities of concern were found on serum chemistry profile. The kitten was sedated with butorphanol (0.3 mg/kg IM), midazolam (0.2 mg/kg IM)

and alfaxalone (1.0 mg/kg IM). An intravenous (IV) catheter was placed and alfaxalone 3.0 mg/kg given IV to effect for induction. The kitten was then placed under general anesthesia with sevoflurane. CT angiography of the head and neck was performed. An approximately 4 cm, fluid-to-soft tissue-attenuating, contrast-enhancing mass was noted on the left ventrolateral head and cervical region, extending from the level of the globe to the level of C2 (Figures 2 and 3). Progressive contrast filling within the mass was noted on sequential delayed phase sequences, with a small communication with the left common carotid artery, consistent with active hemorrhage. There was poor contrast enhancement of the left

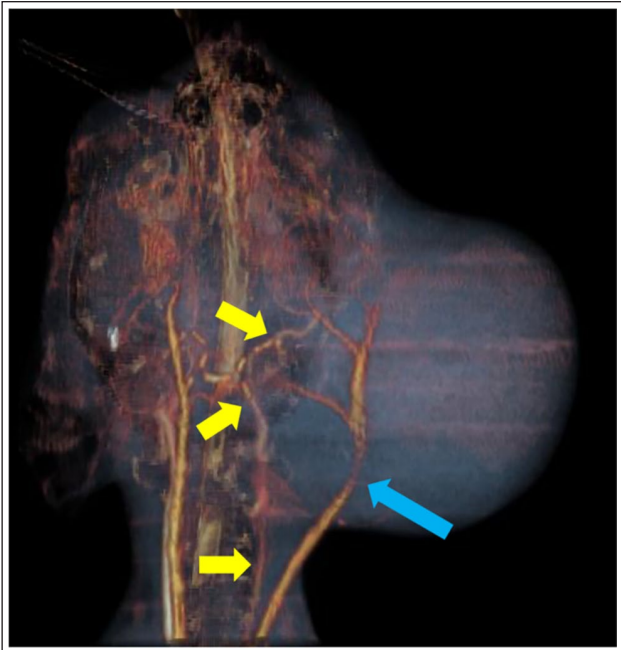


Figure 3 Three-dimensional color dorsal reconstruction of the head demonstrating the swelling, as well as reduced contrast enhancement of the left carotid artery and its tributaries (yellow arrows) relative to the right and displacement and compression of the left jugular vein (blue arrow)

common carotid artery and its tributaries, compared with the right side, which was presumed to be secondary to compression from the mass effect and/or related to reduced volume owing to leakage of contrast into the pseudoaneurysm. A focus of fluid attenuation with rim contrast enhancement noted ventral to the left mandible was suspected to represent additional hemorrhage, hematoma or a communicating compartment of the larger mass.

Surgical correction was recommended given concerns for active hemorrhage and continued growth of the structure. One day following CT, the kitten was anesthetized with buprenorphine (0.02 mg/kg IV), alfaxalone (3.0 µg/kg IV), midazolam (0.16 mg/kg IV) and ketamine (3.0 mg/kg IV). General anesthesia was initiated and maintained with sevoflurane. The left jugular vein was ligated with a vessel sealing device (Ligasure Small Jaw; Medtronic) to allow for better dissection and exploration of the cervical region. The left carotid artery was identified proximal to the swelling and 3-0 silk placed around it. Temporary occlusion did not yield any changes in anesthetic parameters; therefore, it was ligated proximal (caudal) to the pseudoaneurysm. The pseudoaneurysm capsule was first identified. It was pale pink in color, matching the surrounding tissue, and approximately 3 × 4 cm in size. The pseudoaneurysm was then catheterized with a 22 G over-the-needle catheter attached to a syringe and three-way stopcock

device. Approximately 60 ml (96.8 ml/kg) blood was aspirated from the swelling, resulting in decompression of the swelling. A blood transfusion was elected due to the significant amount of blood removed and kitten's small size. The anesthesia team administered two autotransfusions. The first was 10 ml blood mixed with 1 ml citrate phosphate adenine anticoagulant (CPDA) over 1 min. Since the kitten handled the first transfusion well, a second transfusion of 40 ml blood mixed with 4 ml CPDA was given over 4 mins. The pseudoaneurysm was noted to refill to its original size within minutes. An incision was created within the pseudoaneurysm, the capsule was explored and a large hematoma removed. Blood was collected with a needle and syringe from the pseudoaneurysm as it reappeared. The medial portion of the pseudoaneurysm continued to hemorrhage and the kitten began to decompensate. Blood was collected to measure the intraoperative packed red blood cell (pRBC) volume, which was 10%. A second autotransfusion of 50 ml blood with 5 ml CPDA was immediately given as a bolus. An allogeneic pRBC transfusion (30 ml total, 48.4 ml/kg) was started after the second autotransfusion over 5 mins. On the medial side of the pseudoaneurysm, an approximately 1 mm opening (lumen) was recognized to be the source of hemorrhage. Two 5-0 Prolene mattress sutures were placed. Hemostasis was confirmed. The remaining capsule and blood clot remnants were excised and submitted for histopathology. Aerobic and anaerobic cultures were taken at the time of wound closure and yielded no growth. The subcutaneous tissue and skin were closed routinely with 4-0 monocryl and 3-0 nylon, and a light bandage was placed around the neck. Total surgery time was 104 mins.

The endotracheal tube was suctioned prior to extubation and a small mucous plug was removed. The kitten was recovered in an oxygen chamber at 40% but was able to be placed in room air within 24 h. The pRBC transfusion was completed in recovery and no additional blood products were required. The kitten was maintained on buprenorphine 0.018 mg/kg transmucosally every 8–12 h for 3 days and cefazolin (22 mg/kg IV q8h for 24 h) until it was switched to oral cephalexin (25 mg/kg PO q12h). In recovery, an abbreviated blood panel was performed and found to be unremarkable aside from a hematocrit of 25%. Postoperatively, the kitten had a head tilt and left sided Horner's syndrome (Figure 1b).

Histologically, approximately 90% of the submitted tissue was necrotic with numerous erythrocytes and a mixed inflammatory cell population dissecting the necrotic tissue. The remaining tissue was entirely composed of fibrosis. Attached to the necrotic tissue multifocally was a large amount of fibrin mixed with inflammatory cells, consistent with a thrombus. Given the degree of necrosis, pseudoaneurysm was deemed most likely but a true aneurysm could not be ruled out (Figure 4).

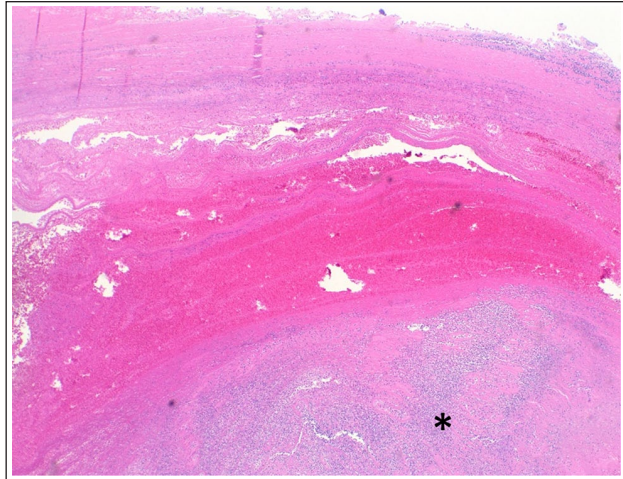


Figure 4 Necrotic band of tissue with dissecting hemorrhage and thrombus (*) formation (hematoxylin and eosin, $\times 20$ magnification)

The kitten was hospitalized for 7 days postoperatively before going home due to the requirement of a rabies quarantine after it bit a staff member. The kitten continued to recover uneventfully at home. A 7-day course of cephalexin (25 mg/kg PO q12h) was administered while cultures were pending. Buprenorphine was discontinued after 3 days when the kitten no longer seemed painful. Three months postoperatively, the kitten had grown significantly in size and had no reoccurrence of clinical signs or swelling. The head tilt had fully resolved and Horner's syndrome had partially resolved.

Discussion

This case report describes the development of a suspected pseudoaneurysm following inadvertent needle puncture of the carotid artery in a kitten. Surgical repair was indicated, owing to the repeated filling of the swelling and requirement of blood product administration following drainage. The largest challenge in this case was maintaining hemodynamic stability while attempting to identify the small carotid artery communication with the suspected pseudoaneurysm. Appropriate multimodal anesthesia options were given significant consideration to be conscious of including medications to protect the heart rate and blood pressure and to be prepared for potential significant blood loss. Despite the recurrent swelling, the kitten's behaviors were similar to what would be normal for a kitten of this age. There was no significant concern for pain warranting any preoperative pain medications. The size of the swelling and concern of its connection to major blood vessels discouraged the use of local analgesics. Anesthesia was maintained without the need for more pain control beyond the preoperative dose of buprenorphine (0.02 mg/kg IV once). Despite ligation of the carotid artery distal to the pseudoaneurysm, bleeding within the lumen continued,

requiring exploration. The size of the swelling prevented occlusion of flow distal (rostral) to the pseudoaneurysm, and communication between the carotid artery and pseudoaneurysm was only identified once the pseudoaneurysm was incised. Subsequent hemorrhage resulted in rapid patient decompensation requiring a massive allogeneic blood transfusion, as well as autotransfusion. Despite this, the kitten recovered with minimal complications and was doing well 3 months postoperatively, with no recurrence of the pseudoaneurysm.

This kitten is the second suspected pseudoaneurysm reported in a cat following accidental needle trauma.³ The previously reported case was due to preoperative venipuncture; this case was from a foster parent holding the kitten during subcutaneous fluid administration. Presumably, movement of the kitten resulted in puncture of the carotid artery by the needle used to administer the subcutaneous fluids. Utilization of low-stress and cat friendly handling techniques with appropriately trained staff may reduce the risk of pseudoaneurysm formation.

Histologically, owing to the extensive necrosis, this case posed a challenge in differentiating a pseudoaneurysm from a true aneurysm. Microscopic examination of true aneurysms shows dilation of an intact vessel, whereas focal or diffuse disruption of one or more layers of the vessel wall is seen in pseudoaneurysms.^{1,4} Most commonly, the tunica intima and media are disrupted, resulting in blood, fibrin and leukocytes pooling in the space between the tunica intima and media, encapsulated by the tunica adventitia or adjacent connective tissue.^{1,4,5} In the present case, the severity of necrosis precluded identification of each layer of the vessel wall, making a diagnosis of pseudoaneurysm more likely.

In human medicine, the majority of pseudoaneurysms are small and secondary to arterial puncture. It is believed that a majority will thrombose spontaneously by 4 weeks; however, given the unpredictability, current polices advocate for early management.⁶ Treatment options include ultrasound-guided compression, percutaneous ultrasound-guided thrombin injection, percutaneous ultrasound-guided collagen injection, minimally invasive grafting or coils, and surgery. The standard of care in humans is percutaneous ultrasound-guided thrombin injections, owing to the risks and minimally invasive nature of this procedure.⁶ Surgery is typically reserved as a final treatment option owing to the increased risks.⁶

In small companion animals, the only other reports of pseudoaneurysms have been in a dog with a grass awn migrating foreign body in the celiac artery, and in cats following a ventral bulla osteotomy, accidental puncture of the carotid artery and cat bite to the carpus.^{1-3,7} A pseudoaneurysm following venipuncture of the femoral artery has also been reported in a macaque.⁸ Of these five reported pseudoaneurysms in

small animals, two cases received surgical intervention and had excellent outcomes. Two cases were only monitored for growth of the swelling due to cost constraints and anatomy, which also had good outcomes. One case received no intervention and was euthanized due to hemoabdomen secondary to the grass awn. Currently, minimally invasive surgical techniques for pseudoaneurysms in veterinary medicine are lacking, partly due to low case numbers and therefore lack of development of successful techniques. Pseudoaneurysms are more common in human medicine since diagnostic and interventional procedures are more commonly performed in major vessels, such as the femoral artery.⁹ As a result, there is more need to develop treatment options. Despite advances in arterial-based diagnostic and interventional procedures in veterinary medicine, there has been no apparent increase in the occurrence of pseudoaneurysms. Those reported are more likely to be attributed to accidental incidents rather than by diagnostic or interventional procedures. Although risks are inherently higher with surgical correction, at least until further research is conducted on the use of thrombin in animals for clot occlusion in a pseudoaneurysm, surgery can offer a faster resolution of clinical signs and may be indicated in animals whose quality of life is negatively affected by the pseudoaneurysm. The available literature is insufficient to comment on best practices for the management of these cases; however, surgical intervention is an option for the treatment of pseudoaneurysms.

The kitten described here received 161.3 ml/kg autologous blood and 48.4 ml/kg allogeneic pRBC throughout the course of surgery and the immediate postoperative period. With an approximate blood volume of 40 ml, this amounted to five times the kitten's blood volume within a period of approximately 3 h. Massive blood transfusion is defined as administration of a volume of blood greater than the patient's blood volume within a 24 h period, administering 50% of a patient's blood volume in 3 h or administering >150% of a patient's blood volume within any time period, and has been associated with severe complications such as electrolyte disturbances, coagulopathy, hypothermia, acid-base disturbances and various transfusion reactions¹⁰ This kitten suffered no apparent complications from the massive blood transfusion received. We suspect that many of these complications were avoided because a majority of the blood administered was unprocessed, un-anticoagulated, autologous blood. Though not extensively studied in veterinary medicine, the human literature suggests no apparent complications associated with salvaged blood transfusions.¹¹ However, these studies did not look at patient populations that receive massive blood transfusions. The kitten hemorrhaged intraoperatively despite ligation of the ipsilateral carotid artery proximal (caudal) to the pseudoaneurysm, likely due to connection to the contralateral carotid arterial

supply via the circle of Willis.¹² As such, preoperative planning for hemorrhage is critical, even when the carotid artery is to be ligated.

Conclusions

Pseudoaneurysm is a possible but extremely rare complication associated with venipuncture in small animals. In some animals, surgical intervention may be warranted. Preoperative advanced imaging is recommended, as well as anticipation of the need for blood transfusions during surgery. The kitten in this case report underwent successful surgical management of the pseudoaneurysm.

Conflict of interest The authors declared no potential conflicts of interest with respect to the research, authorship, and/or publication of this article.

Funding The authors received no financial support for the research, authorship, and/or publication of this article.

Ethical approval The work described in this manuscript involved the use of non-experimental (owned or unowned) animals. Established internationally recognised high standards ('best practice') of veterinary clinical care for the individual patient were always followed and/or this work involved the use of cadavers. Ethical approval from a committee was therefore not specifically required for publication in *JFMS Open Reports*. Although not required, where ethical approval was still obtained, it is stated in the manuscript.

Informed consent Informed consent (verbal or written) was obtained from the owner or legal custodian of all animal(s) described in this work (experimental or non-experimental animals, including cadavers) for all procedure(s) undertaken (prospective or retrospective studies). No animals or people are identifiable within this publication, and therefore additional informed consent for publication was not required.

ORCID ID Sarai Milliron  <https://orcid.org/0000-0002-3535-607X>

References

- Hall JL, Lee KCL, Priestnall S, et al. **Radial artery pseudoaneurysm in a Maine Coon cat.** *Vet Surg* 2011; 40: 861–864.
- Pfaff AW, Rozanski EA and Lynch AM. **Massive haemorrhage associated with inadvertent incision of a suspected carotid artery pseudoaneurysm in a cat.** *J Small Anim Pract* 2015; 56: 720–722.
- Townsell MY, Biller DS and Grauer GF. **Carotid artery pseudoaneurysm in a cat.** *J Feline Med Surg* 2012; 14: 819–821.
- Larsdotter S, Ley C and Pringle J. **Renal pseudoaneurysm as a cause of hematuria in a colt.** *Can Vet J* 2009; 50: 759–762.
- Rashid M, Abbas SZ, Haque F, et al. **Intrarenal post-traumatic pseudoaneurysm-USG colour Doppler diagnosis: a case report with review of literature.** *Emerg Radiol* 2007; 14: 257–260.

- 6 Ahmad F, Turner SA, Torrie P, et al. **Iatrogenic femoral artery pseudoaneurysms – a review of current methods of diagnosis and treatment.** *J Clin Radiol* 2008; 63: 1310–1316.
- 7 Llabres-Diaz FJ, Brissot H and Ibarrola P. **Imaging diagnosis-Celiac artery pseudoaneurysm associated with a migrating grass awn.** *Vet Radiol Ultrasound* 2010; 51: 508–511.
- 8 Daviau JS and Merton DA. **Nonsurgical repair of a pseudoaneurysm in a cynomolgus macaque (*Macaca fascicularis*).** *J Am Assoc Laboratory Animal Sci* 2010; 49: 647–651.
- 9 Sarkadi H, Csőre J, Veres DS, et al. **Incidence of and predisposing factors for pseudoaneurysm formation in a high-volume cardiovascular center.** *PLoS One* 2021; 16. DOI: 10.1371/journal.pone.0256317.
- 10 Jutkowitz LA, Rozanski EA, Moreau JA, et al. **Massive transfusion in dogs: 15 cases (1997–2001).** *J Am Vet Med Assoc* 2002; 220: 1664–1669.
- 11 Liembruno GM, Liembruno C and Rafanelli D. **Autologous blood in obstetrics: where are we going now?** *Blood Transfus* 2012; 10: 125–147.
- 12 Kamijyo Y and Garcia JH. **Carotid arterial supply of the feline brain.** *Stroke* 1975; 6: 361–369.