

**Teaching Case**

# Osteoradionecrosis of the jaw in a patient with lymphoma treated with rituximab and concomitant involved field radiation therapy

Jesus D. Gonzalez-Lugo MD <sup>a,\*</sup>, Rafi Kabarriti MD <sup>b</sup>,  
Ioannis Mantzaris MD, MS <sup>c</sup>

<sup>a</sup> Department of Medicine, Albert Einstein College of Medicine, Jacobi Medical Center, Bronx, New York

<sup>b</sup> Department of Radiation Oncology, Albert Einstein College of Medicine, Montefiore Medical Center, Bronx, New York

<sup>c</sup> Department of Oncology, Albert Einstein College of Medicine, Montefiore Medical Center, Bronx, New York

Received 27 February 2018; received in revised form 12 May 2018; accepted 31 May 2018

## Introduction

Most guidelines recommend radiation therapy for the treatment of early stage (I/II), grade 1-3A follicular lymphoma (FL).<sup>1,2</sup> This recommendation is mostly based on retrospective studies in the pre-rituximab era, showing long-term disease-free survival with extended field radiation therapy and subsequently involved field radiation therapy (IFRT).<sup>3-8</sup>

Ongoing studies are currently exploring the potential benefit of combining systemic with localized treatment. The MIR trial was a prospective study conducted by the German Low-Grade Lymphoma Study Group and the German Radiation Oncology Group, in which patients with early stage CD20 positive grade 1 or 2 FL were treated with IFRT (either 30 or 40 Gy) and concomitant rituximab. Preliminary data reported at the 2012 Annual Meeting and Exposition of the American Society of Hematology and the 2014 European Society for Radiotherapy and Oncology Congress showed a 2-year progression-free survival (PFS) rate of 89%, which approximated outcomes that have been seen historically with extended field radiation therapy and surpassing outcomes of IFRT.<sup>9,10</sup> Additionally, retrospective

studies with rituximab before or after IFRT have shown improvements in PFS compared with IFRT alone.<sup>11,12</sup>

Osteoradionecrosis (ORN) of the jaw is one of the most severe chronic side effects of radiation therapy to the head and neck region. Risk of ORN is believed to be directly related to radiation dose and strongly associated with doses >60 Gy.<sup>13</sup> Concomitant radiosensitizing chemotherapy, such as with platinum analogues, may be an additional risk factor.<sup>14</sup> To our knowledge, there have been no reports of ORN at radiation doses <45 Gy with IFRT.

Here, we present the case of a patient treated according to the MIR trial protocol, who received concomitant rituximab and IFRT at a dose of 30.6 Gy and subsequently developed ORN of the jaw.

## Case

A 70-year-old woman with a history of diabetes, hypertension, atrial fibrillation, chronic kidney disease stage 3, 14-pack-years of active smoking, and chronic obstructive pulmonary disease was referred to the oncology service for a mass on the right parotid gland that had been present for several months, along with 20 lb weight loss and night sweats.

The patient underwent a fine needle aspiration of the mass that showed cells with aberrant mature B-cell immunophenotype suspicious for CD10 + lymphoma

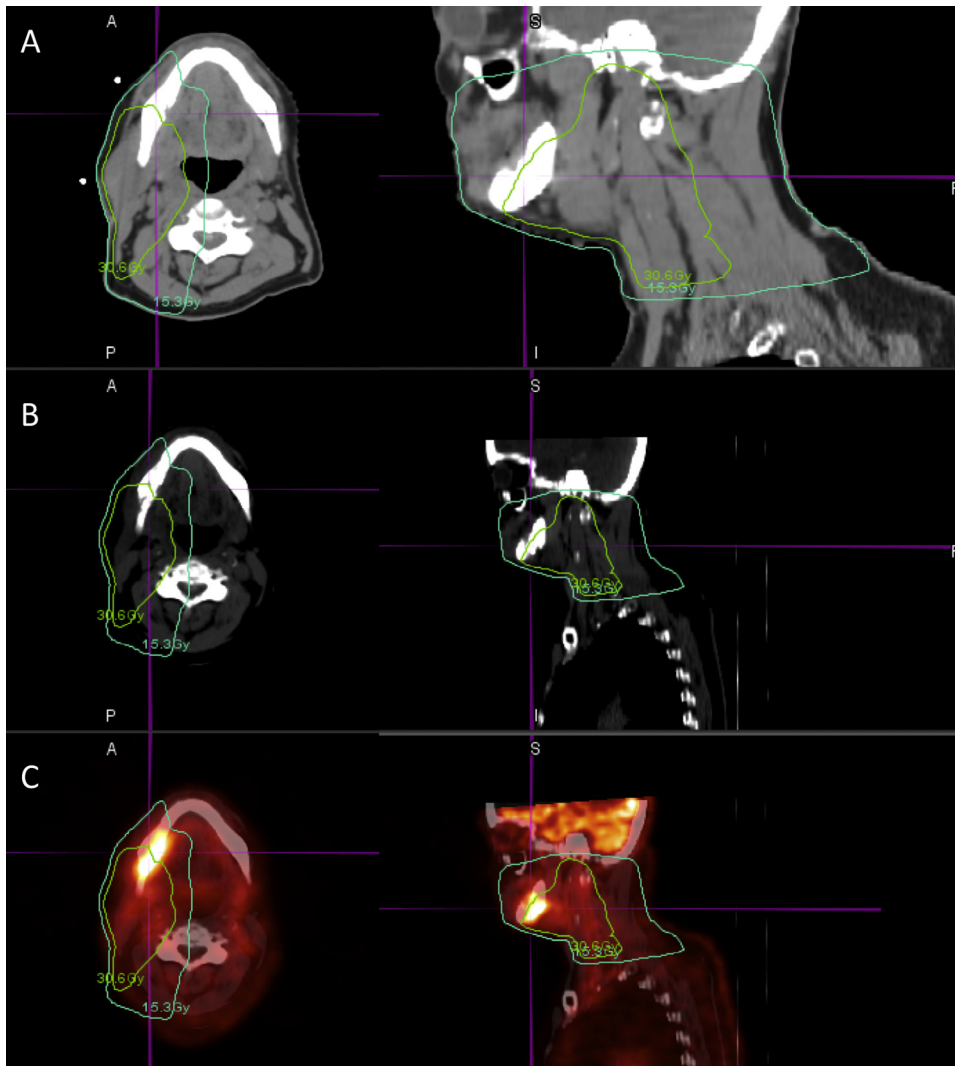
Conflicts of interest: The authors declare no competing financial interests.

\* Corresponding author. 1400 Pelham Pkwy S, Bronx, NY 10461.

E-mail address: [jgonzalezlugo@outlook.com](mailto:jgonzalezlugo@outlook.com) (J.D. Gonzalez-Lugo).

<https://doi.org/10.1016/j.adro.2018.05.008>

2452-1094/© 2018 The Author(s). Published by Elsevier Inc. on behalf of the American Society for Radiation Oncology. This is an open access article under the CC BY-NC-ND license (<http://creativecommons.org/licenses/by-nc-nd/4.0/>).



**Figure 1** Baseline computed tomography (CT) prior to involved field radiation therapy with 30.6 Gy (light green) and 15.3 Gy (blue) isodose lines (A), posttreatment CT imaging 11 weeks after completion of involved field radiation therapy showing evidence of radiation necrosis on CT (B), and positron emission tomography/CT (C) with a standardized uptake value of 6.5.

and subsequently a parotid mass excisional biopsy that showed a CD5-/CD10+ low grade B-cell lymphoma (Ki67 5-10%) that was positive for CD20, consistent with grade 1-2/3 FL.

Bone marrow biopsy showed no morphologic or immunophenotypic evidence of involvement by B-cell lymphoproliferative disorder. Positron emission tomography/computed tomography (PET/CT) imaging showed a fluorodeoxyglucose (FDG)-avid mass in the right parotid gland/right level II cervical region but no evidence of FDG-avid malignancy elsewhere in the field of view (Fig 1a). There was enlargement of the left adrenal gland and nodular thickening of the right adrenal gland consistent with adenomatous hyperplasia. The patient was diagnosed with stage IB<sub>E</sub> disease.

On the basis of the reported encouraging preliminary results, the patient was treated per the MIR protocol with a combination of rituximab and radiation therapy.<sup>10</sup> The MIR

protocol involves an initial block of 4 weekly rituximab treatments (375 mg/m<sup>2</sup>) followed by a 4-week treatment gap and restaging PET/CT on week 7. Subsequently, a series of 4 weekly rituximab infusions is given concurrently with IFRT at a dose of 40 Gy for residual disease or 30 Gy if in complete remission.

The patient completed the first block of rituximab treatment and had a partial response with a palpable residual mass in the right parotid gland/right level II cervical region, consistent with the known primary malignant mass. Subsequently, she completed the second block of rituximab and IFRT. Despite a partial response, 30.6 Gy in 17 fractions was administered due to the patient's comorbidities and on the basis of data from the British National Lymphoma Investigation study, which showed that 24 Gy in 12 fractions was as effective for local control as 40 Gy in 20 fractions.<sup>15</sup> The radiation therapy course was complicated by severe mucositis 1 week after treatment.

Two months after finishing the second block of treatment, the patient reported mild bleeding and pain in the right jaw that was worse with eating and had been present for 1 month. Physical examination was remarkable for a receding gum to the right lower jaw; gum ulceration with exposed bone and tenderness to palpation were noted. A follow-up PET/CT scan showed marked improvement in the previously described hypermetabolic right parotid gland mass consistent with complete metabolic response; however, new fragmentation and cortical irregularity of the body of the right mandible was noted with associated adjacent soft tissue swelling and FDG uptake (Fig 1b and c).

The patient was evaluated by dental, medical, and radiation oncology and, although no biopsy was performed, she was diagnosed with ORN of the right jaw. She was treated with a course of antibiotics and nonsteroidal anti-inflammatory drugs with complete resolution of her symptomatology, without requiring debridement. A magnetic resonance imaging scan of the neck for an unrelated indication 4 months later showed loss of normal marrow signal along the course of the right mandible corresponding to the prior PET/CT findings.

## Discussion

ORN of the jaw is more commonly seen in patients receiving radiation at doses >60 Gy.<sup>13,14</sup> It has not to date been described as a side effect of IFRT monotherapy at doses <45 Gy.<sup>15,16</sup> In addition to the radiation dose, there are additional reported risk factors for ORN in patients with head and neck cancers, such as smoking, concomitant radiosensitizing chemotherapy (e.g., platinum analogues), male sex, bone surgery immediately preceding radiation therapy, use of bisphosphonates, and poor dental hygiene.<sup>14,17</sup>

ORN can develop anytime between 2 to 98 months, although it is usually seen 3 to 5 years after the end of radiation therapy.<sup>17,18</sup> In a recent report by The Memorial Sloan Kettering Cancer Center group on patients with head and neck cancer, the median time from radiation to ORN development was 19.1 months, with a range of 0 to 220.2 months. Our patient developed ORN of the jaw within 2 months from the end of radiation therapy. Although earlier than average, the timing of ORN manifestation in our patient was still within the range previously reported.<sup>19</sup>

The patient in this report received low-dose radiation (30.6 Gy) and although she had been an active smoker, she did not have any of the other aforementioned risk factors for ORN. She was edentulous and required no dental intervention. Our patient received rituximab in conjunction with radiation to the parotid gland. There have been limited case reports of osteonecrosis with rituximab treatment alone; however, in none was rituximab identified as a clear culprit, and the postulated mechanism of an antiangiogenic, apoptotic effect remains hypothetical.<sup>20,21</sup> More interestingly, the simultaneous exposure of lymphoma cells to

rituximab and ionizing radiation have been shown to markedly enhance apoptosis and cell growth delay, suggesting a rituximab radiosensitizing effect in vitro.<sup>22,23</sup>

Rituximab has a prolonged half-life and has been extensively used in conjunction with radiation in the treatment of lymphoma as part of the rituximab, cyclophosphamide, doxorubicin hydrochloride, vincristine sulfate, and prednisone (R-CHOP) regimen.<sup>24</sup> In contrast to what one would expect in the context of a rituximab radiosensitizing effect, there are no prior reports of ORN after R-CHOP followed by consolidative or adjunctive radiation therapy. The blood supply of the mandible could make it particularly susceptible to avascular necrosis, and cases of R-CHOP chemotherapy followed by radiation in the proximity of the jaw may be overall infrequent. There could also be a dose-dependent radiosensitizing effect, which could explain the additional risk when rituximab is given concurrently with radiation.

## Conclusions

Our patient was treated with concurrent IFRT and rituximab and developed jaw ORN despite the low dose of radiation used. No additional ORN risk factors were identified except for smoking. It is possible that the toxicity experienced by our patient at a radiation dose not previously associated with ORN was due to a rituximab radiosensitizing effect.

In the interim analysis of the MIR trial, of the 85 patients who were included in the study, 19 experienced adverse events, including 4 labeled as bone injuries, albeit not specified.<sup>9</sup> From personal communication with the leading author, no ORN was seen and all bone events were unrelated to treatment.

Although the mature results of the now completed MIR trial are awaited, further information regarding the safety of concurrent rituximab and radiation needs to be cautiously collected. Ongoing prospective trials in early stage FL (one at MD Anderson Cancer Center [NCT01473628] where IFRT with concomitant rituximab is being compared with IFRT alone, and another by the Trans-Tasman Radiation Oncology Group comparing IFRT with IFRT combined with rituximab and chemotherapy [NCT00115700]) will help shed light on the potential of rare toxicities with this combination. Until then, the association of ORN with this otherwise promising therapeutic strategy remains to be determined and quantified.

Finally, a possible rituximab radiosensitizing effect and its mechanism need to be further elucidated because such an effect can have significant clinical implications in terms of both treatment efficacy and toxicity.

## References

1. Zelenetz AD, Gordon LI, Wierda WG, et al. Non-Hodgkin's lymphomas, version 2.2014. *J Natl Compr Canc Netw*. 2014;12:916-946.

2. Dreyling M, Ghielmini M, Rule S, et al. Newly diagnosed and relapsed follicular lymphoma: ESMO Clinical Practice Guidelines for diagnosis, treatment and follow-up. *Ann Oncol.* 2016;27:v83-v90.
3. Mac Manus MP, Hoppe RT. Is radiotherapy curative for stage I and II low-grade follicular lymphoma? Results of a long-term follow-up study of patients treated at Stanford University. *J Clin Oncol.* 1996;14:1282-1290.
4. Stuschke M, Hoederaht A, Sack H, et al. Extended field and total central lymphatic radiotherapy in the treatment of early stage lymph node centroblastic-centrocytic lymphomas: Results of a prospective multicenter study. Study Group NHL-fruhe Stadien. *Cancer.* 1997;80:2273-2284.
5. Wilder RB, Jones D, Tucker SL, et al. Long-term results with radiotherapy for Stage I-II follicular lymphomas. *Int J Radiat Oncol Biol Phys.* 2001;51:1219-1227.
6. Guadagnolo BA, Li S, Neuberg D, et al. Long-term outcome and mortality trends in early-stage, Grade 1-2 follicular lymphoma treated with radiation therapy. *Int J Radiat Oncol Biol Phys.* 2006;64:928-934.
7. Pugh TJ, Ballonoff A, Newman F, Rabinovitch R. Improved survival in patients with early stage low-grade follicular lymphoma treated with radiation: A Surveillance, Epidemiology, and End Results database analysis. *Cancer.* 2010;116:3843-3851.
8. Campbell BA, Voss N, Woods R, et al. Long-term outcomes for patients with limited stage follicular lymphoma: Involved regional radiotherapy versus involved node radiotherapy. *Cancer.* 2010;116:3797-3806.
9. Herfarth K, Schnaidt S, Aro, Gls. PD-0518: Early stage nodal follicular lymphoma using IF radiotherapy and Rituximab: Results of the MIR trial of the GLSG and ARO. *Radiother Oncol.* 2014;111:S204.
10. Herfarth K, Engelhard M, Borchmann P, et al. Treatment of early stage nodal follicular lymphoma using involved-field radiotherapy and rituximab: Preliminary results of the MIR trial (Phase II study of the German Low Grade Lymphoma Study Group [GLSG]). *Blood.* 2012;120:1634.
11. Ruella M, Filippi AR, Bruna R, et al. Addition of rituximab to involved-field radiation therapy prolongs progression-free survival in Stage I-II follicular lymphoma: Results of a multicenter study. *Int J Radiat Oncol Biol Phys.* 2016;94:783-791.
12. Cencini E, Puccini B, Rigacci L, et al. Radiotherapy plus rituximab as first-line regimen for localized follicular lymphoma. *Leuk Lymphoma.* 2018;59:1420-1426.
13. Studer G, Bredell M, Studer S, Huber G, Glanzmann C. Risk profile for osteoradionecrosis of the mandible in the IMRT era. *Strahlenther Onkol.* 2016;192:32-39.
14. Kuhnt T, Stang A, Wienke A, Vordermark D, Schweyen R, Hey J. Potential risk factors for jaw osteoradionecrosis after radiotherapy for head and neck cancer. *Radiat Oncol.* 2016;11:101.
15. Lowry L, Smith P, Qian W, et al. Reduced dose radiotherapy for local control in non-Hodgkin lymphoma: A randomised phase III trial. *Radiother Oncol.* 2011;100:86-92.
16. Hoskin PJ, Kirkwood AA, Popova B, et al. 4 Gy versus 24 Gy radiotherapy for patients with indolent lymphoma (FORT): A randomised phase 3 non-inferiority trial. *Lancet Oncol.* 2014;15:457-463.
17. Caparrotti F, Huang SH, Lu L, et al. Osteoradionecrosis of the mandible in patients with oropharyngeal carcinoma treated with intensity-modulated radiotherapy. *Cancer.* 2017;123:3691-3700.
18. Marx RE, Johnson RP. Studies in the radiobiology of osteoradionecrosis and their clinical significance. *Oral Surg Oral Med Oral Pathol.* 1987;64:379-390.
19. Owosho AA, Tsai CJ, Lee RS, et al. The prevalence and risk factors associated with osteoradionecrosis of the jaw in oral and oropharyngeal cancer patients treated with intensity-modulated radiation therapy (IMRT): The Memorial Sloan Kettering Cancer Center experience. *Oral Oncol.* 2017;64:44-51.
20. Keribin P, Guerrot D, Jardin F, Moizan H. Osteonecrosis of the jaw in a patient presenting with post-transplantation lymphoproliferative disorder treated with rituximab: A case report. *J Oral Maxillofac Surg.* 2017;75:2599-2605.
21. Allegra A, Oteri G, Alonci A, et al. Association of osteonecrosis of the jaws and POEMS syndrome in a patient assuming rituximab. *J Craniomaxillofac Surg.* 2014;42:279-282.
22. Skvortsova I, Skvortsov S, Popper BA, et al. Rituximab enhances radiation-triggered apoptosis in non-Hodgkin's lymphoma cells via caspase-dependent and—independent mechanisms. *J Radiat Res.* 2006;47:183-196.
23. Kapadia NS, Engles JM, Wahl RL. In vitro evaluation of radioprotective and radiosensitizing effects of rituximab. *J Nucl Med.* 2008;49:674-678.
24. Li J, Levi M, Charoin JE. Rituximab exhibits a long half-life based upon a population pharmacokinetic analysis in non-Hodgkins lymphoma patients. *Blood.* 2007;110:700.