




Contents lists available at ScienceDirect

International Journal of Surgery Case Reports

journal homepage: www.casereports.com

A case report of cervical neurofibrosarcoma: Clinical presentation, treatment and outcome



Asmaou Dalil^{a,*}, Valentin Fokouo Fogha^b, Jean Evehe Vokwely^b, Emery Sougou^c, Jérôme Miloundja^c

^a Hôpital d'instruction des armées Omar Bongo Ondimba/General Hospital of Yaoundé, Gabon

^b Centre Hospitalier d'ESSOS, Yaoundé

^c Hôpital d'instruction des armées Omar Bongo Ondimba, Gabon

ARTICLE INFO

Article history:

Received 5 March 2017

Received in revised form 20 May 2017

Accepted 20 May 2017

Available online 12 December 2017

Keywords:

Neurofibrosarcoma

Neurofibromatosis

Case report

ABSTRACT

INTRODUCTION: Malignant peripheral nerve sheath tumors (MPNST) are highly aggressive soft tissue sarcomas in which complete surgical resection is the mainstay of therapy.

CLINICAL PRESENTATION: We report a case of MPNST, a 24 year old patient with right neck painful mass of 13 cm of greater dimension, skin spots, lentigos, cutaneous neurofibromas. The neck CT scan revealed a mass with liquid and soft tissues densities. Surgery was performed through right cervical Paul André incision and allowed exeresis of a hemorrhagic mass expensing on the cranial nerves X, XI, XII and the cervical sympathetic chain. Pathology analysis revealed a neurofibrosarcoma, the patient received six doses of chemotherapy. A second surgery was performed one year later after the appearance of a rapidly growing neck mass on the same site. The patient deceased in the intensive care unit one day post-op.

DISCUSSION: Neurofibrosarcoma is a rare clinical entity most often reported as case report. This tumor takes its origin from nerve structures such as the brachial plexus, the cervical sympathetic chain and the cranial nerves and their branches. The appearance of pain, size modification or signs of nerve root compression should warn us to search for a malignant degeneration. Surgery is the base of treatment, associated to radiotherapy and chemotherapy. Vinblastin and doxorubicin were used by other authors in association to radiotherapy with complete local control of inoperable tumors. The 5-year survival is 50% in patients with a neurofibrosarcoma de novo.

CONCLUSION: The prognosis of neurofibrosarcoma is poor, prompting aggressive local (surgery) and systemic treatment (radiotherapy and/or chemotherapy).

© 2017 The Author(s). Published by Elsevier Ltd on behalf of IJS Publishing Group Ltd. This is an open access article under the CC BY-NC-ND license (<http://creativecommons.org/licenses/by-nc-nd/4.0/>).

1. Introduction

Case reports have been a long held tradition within the surgical literature; this work has been reported in line with the SCARE criteria [1]. Neurofibrosarcoma or Malignant Peripheral Nerve Sheath Tumor (MPNST) is a rare malignant tumor arising from the sheath of peripheral nerves. Its neck location is unusual, less than 1% of the tumors of this region [2]. Neurofibrosarcomas represent about 10% of neck soft tissue sarcomas, and about half of the lesions associated to type I neurofibromatosis (NF1) or Von Recklinghausen's disease, the most prevalent phacomatosis [3]. The degeneration of a benign tumor into malignancy one usually occurs in association with a large and diffuse neurofibroma in patients suffering from NF1. The tumors presents as rapidly growing masses often asso-

Table 1

Location of tumour, treatment and outcomes.

Tumour	Treatments	Outcomes
Right Cervical tumour (13 cm) at the expenses of the cranial nerve X, spreading extensions along cranial nerves X, XI, XII and the cervical sympathetic chain.	First surgery + chemotherapy (doxorubicin)	No event before one year of treatment. Relapse one year later
	Second surgery 1 year later	Death one day post-operative of the second surgery

ciated with pain. We report the case of a 24-year-old with a right cervical neurofibrosarcoma (Table 1).

2. Case report

A 24-year-old patient presented 8 months prior to the consultation a painful right lateral neck mass with dysphagia. Physical

* Corresponding author.

E-mail addresses: dalilasma@gmail.com (A. Dalil), foghaval@yahoo.fr (V. Fokouo Fogha), vokwely@yahoo.fr (J. Evehe Vokwely), sougouemery_2001@yahoo.fr (E. Sougou), jemiloundja@yahoo.fr (J. Miloundja).

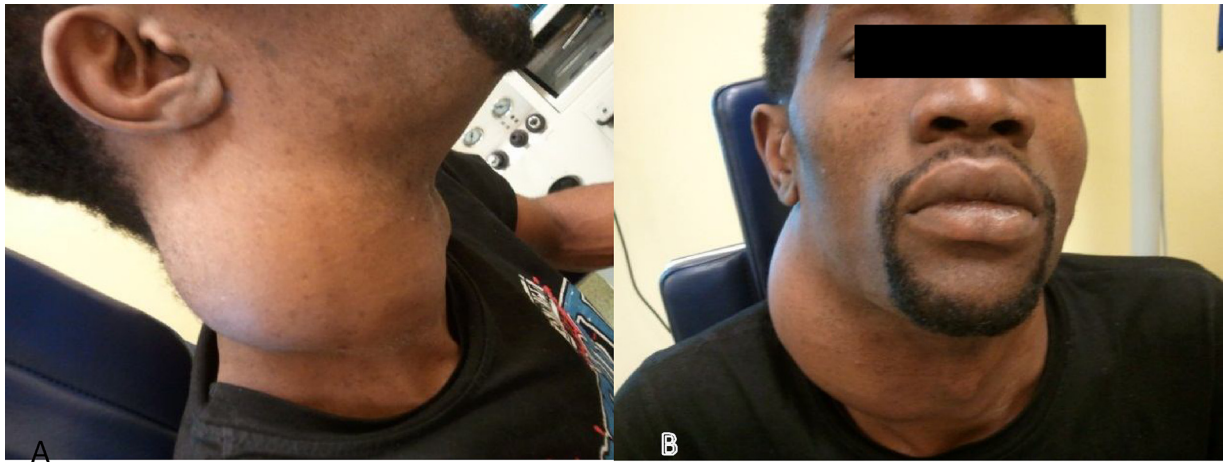


Fig. 1. View of the neck mass. A: Right lateral view. B: Front view.

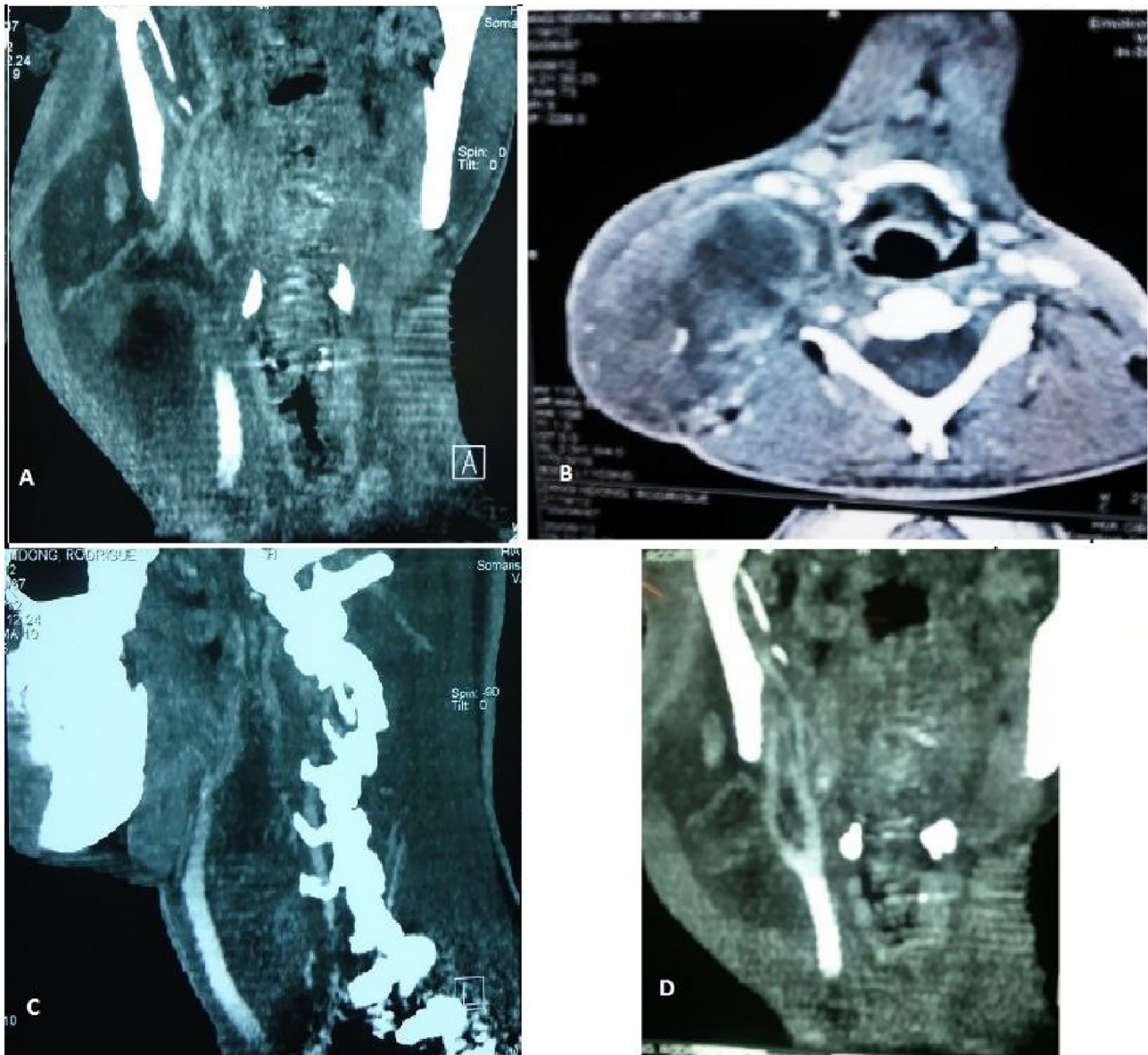


Fig. 2. CT Scan imaging of the patient.

- A – Coronal view showing spots of intra tumoral necrosis
- B – Axial view showing the mass effect on the right vascular axis
- C – Sagittal view with contrast injection showing the relation of the mass to the carotid artery
- D – Coronal view with contrast injection showing the vascular connections of the tumour.

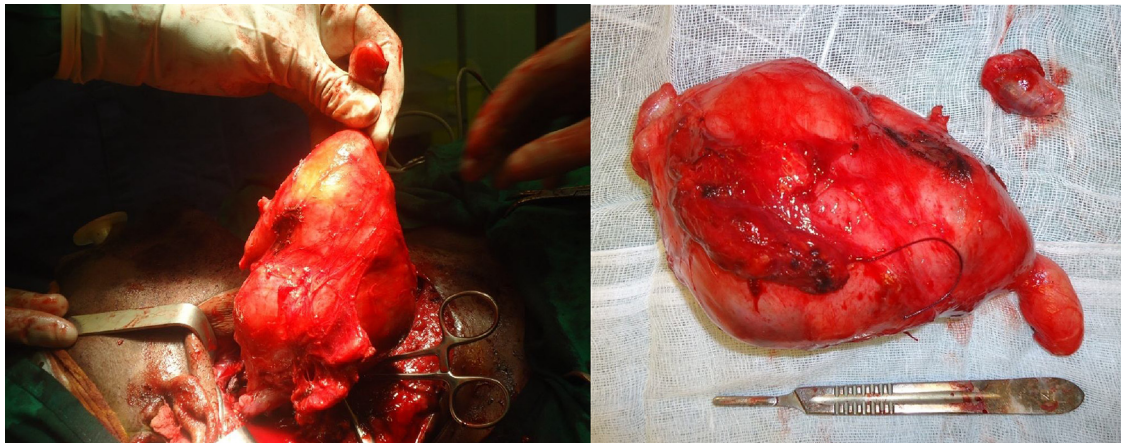


Fig. 3. A view of the tumor.

examination revealed a bulky cervical mass of about 13 cm of greater dimension, firm in consistency, fixed to the inner plane, tender on palpation, with no murmur. The overlying skin was safe. There were numerous *café au lait* skin spots (about 2 cm diameter for the bigger) disseminated mostly on the anterior aspect of the thorax and abdomen. Those spots were more than six. There were also numerous small neurofibromas on the neck and thorax. Lentigos were present on the anterior aspect of the thorax. An ophthalmologic assessment found Lisch's nodules in the both irises. The skin spots and fibromas appeared at age 14. They were also found on the patient's mother, mostly on the face and thorax. A neck CT-scan revealed an enormous mass with liquid and soft tissue densities that pushed back the right lobe of the thyroid gland. Thoracic X-ray and abdominal ultrasound were normal.

The patient was operated under general anesthesia through right lateral cervical Paul André incision. The tumor was discovered after skin-platysma flap undermining. It was a soft tissue mass at the expenses of the cranial nerve X, pushing the carotid artery anteriorly and spreading many extensions along cranial nerves X, XI, XII and the cervical sympathetic chain. The exeresis, very hemorrhagic, was made in one piece and we closed over a suctioning drain.

The pathology analysis revealed a neurofibrosarcoma. The patient was sent to Oncology service where he received six doses of chemotherapy (doxorubicin). The follow up was uneventful for about 12 months postoperatively. Then the appearance of a rapidly growing new neck mass prompted the patient to come back. A new CT-scan diagnosed a relapse on the previous tumor bed. A second cervicotomy, more laborious was done, allowing to remove an enormous hemorrhagic tumor with much adhesions. The patient received a blood transfusion during the procedure. He died in the intensive care unit at day 1 postop from intravascular disseminated coagulation.

3. Discussion

Neurofibrosarcoma is a rare clinical entity most often reported as case report. During the past 50 years, only about a hundred cases of head and neck neurofibrosarcomas were reported [4], often associated with NF1. The degeneration of a benign tumor into malignancy usually occurs in large and diffuse tumors in NF1 [3] like in our patient. It's the first cause of death in these patients before the age of 40 [5]. This tumor which affects all ages without sex predominance takes its origin from nerve structures such as the brachial plexus, the cervical sympathetic chain and the cranial nerves and their branches [6]. In the case reported, the tumor arised from the cranial nerve X with extensions on the route of lingual, X, XI, XII

nerves and cervical parasympathetic chain. Clinically, the appearance of pain, size modification or signs of nerve root compression should warn us to search for a malignant degeneration [7–9].

The tumor could arise *de novo* or from a preexisting plexiform neurofibroma like in the case reported. In some cases, it's the neurofibrosarcoma that leads to the discovery of the NF1. In other cases, the diagnosis is made on the pathologic examination of a tumor removed from a NF1 patient.

On CT-scan, neurofibrosarcomas are hypodense before injection but are intensely and heterogeneously enhanced after, unlike neurofibromas. MRI-scan characterization is difficult but any size modification, changes in a previously scanned lesion or a big tumor with necrotized zones or irregular borders, a heterogeneous signal with necrosis spots, an invasion of neighboring tissues and a heterogeneous enhancement should draw our attention but the end diagnosis is made by pathology. Diagnosis is usually late with a poor prognosis because of relapses and metastases [10–12]. The size, necrotized spots and post injection enhancement led us to suspect malignancy in this case (Figs. 1–3).

The prognosis of neurofibrosarcomas of head and neck is usually poor. Surgery is the base of treatment, associated to radiotherapy and chemotherapy. The latter can be used alone as palliative care in patients who are not eligible to surgery [6,13]. There seems not to be an influence of the NF1 background or tumor site on the result of the surgery [14], but authors agree on the importance of a good initial oncologic surgery [15–17]. Though the tumor was plexiform, we performed the exeresis to its macroscopic margins.

Vinblastin and doxorubicin were used by other authors in association to radiotherapy with complete local control of inoperable tumors [18]. Our treatment protocol was approved during a multidisciplinary meeting. The 5-year survival is 50% in patients with a neurofibrosarcoma *de novo*. This figure drops to 15% if there is an association with neurofibromatosis [2]. The relapse and death of our patient occurred a year after first surgery.

4. Conclusion

The prognosis of neurofibrosarcoma is poor, prompting aggressive local (surgery) and systemic treatment (radiotherapy and/or chemotherapy). Surgery is the gold standard treatment when possible.

Conflicts of interest

No conflict of interest.

Funding

No sources of funding.

Ethical approval

Since the patient is dead and we have no more contact with the family (the mother's telephone number is no longer available), the ethical responsibility can be attributed to the Omar Bongo Ondimba military hospital of Libreville in Gabon ("Hopital d'Instruction des Armées Omar Bongo Ondimba – HIAOBO).

Consent

Since the patient is dead and we have no more contact with the family (the mother's telephone number is no longer available), the ethical responsibility can be attributed to the Omar Bongo Ondimba military hospital of Libreville in Gabon ("Hopital d'Instruction des Armées Omar Bongo Ondimba – HIAOBO).

Author contribution

Valentin FOKOUO contributed with literature on the topic and translation from French to English

Jean EVEHE corrected the article and also contributed with literature

Emery SOUGOU contributed with anesthesia of the patient and collecting images

Pr Jerome MILOUNDJA and ASMAOU DALIL contributed with surgery.

Guarantor

Pr Jerome MILOUNDJA
ENT surgeon
HIAOBO Libreville – GABON

References

- [1] R.A. Agha, A.J. Fowler, A. Saetta, I. Barai, S. Rajmohan, D.P. Orgill, The SCARE Group, The SCARE statement: consensus-based surgical case report guidelines, *Int. J. Surg.* 34 (2016) 180–186.

- [2] R. Tekaya, W. Hamdi, D. Azzouz, M. Bouaziz, M.H. Jaafoura, M.F. Ladeb, M. Montacer Kchir, Montacer Kchir Nevralgie cervicobrachiale révélatrice d'un neurofibrosarcome (MPNST) cervical, *Rev. Neurol. (Paris)* 164 (1) (2016) 82–86.
- [3] T. Daby, M. Darling, Tumeurs malignes de la cavité buccale autres que les carcinomes spinocellulaires: un aperçu, *J. Can. Dent. Assoc.* 69 (9) (2003) 577–582.
- [4] J.H. Naujocks, P.H. Wunsch, M. Ratzka, J. Uffenorde, Neurogenic sarcoma of the head and neck with contact to the skull base, *Arch. Otorhinolaryngol.* 233 (3) (1981) 271–300.
- [5] A.J. Barkovitch, Charles Raybaud *Pediatrics Neuroimaging*, second edition, Raven Press edit, New york, 1995.
- [6] R.W. Hutcherson, H.A. Jenkins, R.F. Canalis, S.D. Handler, B.S. Eichel, Neurogenic sarcoma of the head and neck, *Arch. Otolaryngol.* 105 (May (5)) (1979) 267–270.
- [7] A. Creange, J. Zeller, S. Rostaing-Rigattieri, P. Brugières, J.D. Degos, J. Revuz, P. Wolkenstein, Neurological complications or neurofibromatosis type 1 in adulthood, *Brain* 122 (1999) 473–481.
- [8] National institute of health consensus development conference, Neurofibromatosis. conference statement, *Arch. Neurol.* 45 (1988) 575–578.
- [9] S. Pinson, A. Créange, S. Barbarot, J.F. Stalder, Y. Chaix, D. Rodriguez, M. Sanson, A. Bernheim, M. d'Incan, F. Doz, C. Stoll, P. Combemale, C. Kalifa, J. Zeller, D. Teillac-Hamel, S. Lyonnet, M. Zerah, J.P. Lacour, B. Guillot, P. Wolkenstein, Neurofibromatose 1: recommandations de prise en charge, *ArchPediatr* 9 (2002) 49–60.
- [10] D. Rodriguez, La neurofibromatose de type I ou maladie de Von Recklinghausen, *Neurologies* 5 (2002) 107–113.
- [11] J.L. Dietemann, Diagnostica neuroradiologica della facomatosis del sistema nervoso, *Rivista di neuroradiologia* 6 (1993) 139–153.
- [12] C.J. Chung, K.B. Armfield, Suresh K. Mukherji, Lynn A. Fordham, W.L. Krause, Cervical neurofibromatosis in children with NF1, *Pediatr. Radiol.* 29 (1999) 353–356.
- [13] M.S. Pont, A.D. Elster, Lesions of skin and brain: modern imaging of the neurocutaneous syndromes, *AJR Am. J. Roentgenol.* 158 (1992) 1193–1203.
- [14] Pek-Lan Khong, Winnie H.S. Goh, Virginia C.N. Wong, Cheuk-Wing Fung, Ooi Gaik-Cheng, MR imaging of spinal tumours in children with neurofibromatosis 1, *AJR Am. J. Roentgenol.* 180 (2003) 413–417.
- [15] V.F. Mautner, R.E. Friedrich, A. von Deimling, C. Hagel, B. Korf, M.T. Knöfel, R. Wenzel, C. Fünsterer, Malignant peripheral nerve sheath tumours in neurofibromatosis type 1: MRI supports the diagnosis of malignant plexiform neurofibroma, *Neuroradiology* 45 (2003) 618–625.
- [16] S.E. Rossi, J.J. Erasmus, H.P. McAdams, L.F. Donnelly, Thoracic manifestations of neurofibromatosis 1, *AJR Am. J. Roentgenol.* 173 (1999) 1631–1638.
- [17] A. Rimmelin, P. Dias, S. Salatino, J.L. Dietemann, Hernie colique lombaire secondaire à des anomalies congénitales entrant dans le cadre d'une neurofibromatose de type I, *J. Radiol.* 77 (1996) 279–281.
- [18] H.G. Kempf, G. Becker, B.P. Weber, P. Ruck, T. Lenarz, Diagnosis and clinical outcome of neurogenic tumours in the head and neck area, *Orl. J. Otorhinolaryngol. Relat. Spec.* 57 (5) (1995) 273–278.

Open Access

This article is published Open Access at [sciencedirect.com](https://www.sciencedirect.com). It is distributed under the [IJSCR Supplemental terms and conditions](#), which permits unrestricted non commercial use, distribution, and reproduction in any medium, provided the original authors and source are credited.