

## CASE REPORT

# Cryptococcal meningoencephalitis and pneumonia in a HIV positive patient: A case report

Hamed Mehdinezhad<sup>1</sup> | Sara Ghadir<sup>2</sup> | Parviz Amri Maleh<sup>1</sup> | Ailin Akhondzadeh<sup>3</sup> | Mana Baziboroun<sup>3</sup> 

<sup>1</sup>Clinical Research Development Unit of Rouhani Hospital, Babol University of Medical Sciences, Babol, Iran

<sup>2</sup>student research committee, Babol University of Medical Sciences, Babol, Iran

<sup>3</sup>Infectious Diseases and Tropical Medicine Research Center, Health Research Institute, clinical research of development unit of Rouhani Hospital, Babol University of Medical Sciences, Babol, Iran

## Correspondence

Mana Baziboroun, Infectious Diseases and Tropical Medicine Research Center, Health Research Institute, clinical research of development unit of Rouhani Hospital, Babol University of Medical Science, Babol 47176-41367, Iran.

Email: [manabaziboron@gmail.com](mailto:manabaziboron@gmail.com)

## Key Clinical Messages

Early diagnosis of cryptococcal infection is the key to improving outcomes, any newly diagnosed HIV patient presenting with subacute or chronic headache, particularly those who are CD4-deplete, should be investigated for cryptococcal meningitis. We had some delay in our patient management, including delay in HIV diagnosis, delay in doing LP and delay in initiation of anti-cryptococcal treatment and also early start of ART before specific cryptococcal treatment exacerbated IRIS in the patient. So, paying attention to these points can improve the prognosis of such patients.

## Abstract

Cryptococcus is a fungal pathogen and the causative agent of Cryptococcosis among human immunodeficiency virus (HIV) positive people. Meningoencephalitis is the most common manifestation of cryptococcal infection, while pulmonary cryptococcosis is often neglected due to nonspecific clinical and radiological presentation leading to a delay in diagnosis and disseminated disease. Here, we reported a 67-year-old man with newly diagnosed HIV who presented with concurrent cryptococcal meningoencephalitis and pulmonary cryptococcosis that admitted with the complaint of dyspnea and productive cough for 1.5 months, worsening shortness of breath, fever and weight loss since 15 days prior to admission. He also had severe oral candidiasis. Lung computed tomography (CT) revealed ill-defined subpleural cavitary lesion in left lower zone with bilateral diffuse ground glass opacity and air bronchogram. His HIV PCR test was positive with absolute CD4 count less than 50 cells/mm<sup>3</sup>. After starting antiretroviral therapy (ART), he gradually developed a headache and decreased level of consciousness. Cerebrospinal fluid (CSF) analysis revealed 450 cells, predominantly lymphocytes, with protein of 343 mg/dL and glucose of 98 mg/dL (corresponding blood glucose 284 mg/dL). CSF India ink staining was positive for cryptococcus spp. Liposomal amphotericin B in combination with fluconazole (due to the unavailability of flucytosin) was stated. He was intubated because of hypoxia and his bronchoalveolar lavage was positive for Cryptococcus spp.

This is an open access article under the terms of the [Creative Commons Attribution-NonCommercial-NoDerivs](https://creativecommons.org/licenses/by-nc-nd/4.0/) License, which permits use and distribution in any medium, provided the original work is properly cited, the use is non-commercial and no modifications or adaptations are made.

© 2024 The Author(s). *Clinical Case Reports* published by John Wiley & Sons Ltd.

too. He died 2 weeks after starting antifungal therapy based on this study it should be mentioned that neurologic and respiratory symptoms may be the first presentation of acquired immunodeficiency syndrome.

#### KEYWORDS

Cryptococcus, encephalitis, HIV, meningitis, meningoencephalitis

## 1 | INTRODUCTION

As we know, Cryptococcosis is considered as the most common fungal infection of the brain. It is also considered as the most common fungal infection in people positive for HIV.<sup>1</sup> Cryptococcosis as an important opportunistic infection with a high mortality and morbidity rate can be caused by two encapsulated cryptococcus species: *Cryptococcus neoformans* and *Cryptococcus gattii*. Available data shows that *C.gattii* is responsible for the initiation of disease in immunocompetents but *C.neoformans* is responsible for invasive disorders in immunocompromised patients.<sup>2</sup> Polysaccharide capsule was described as its virulence factor that is composed of glucuronoxylomannan (its major component), galactoxylomannan, and mannoproteins which can activate phagocytosis by alveolar macrophages following inhalation. Since they can make it through phagocytosis, these fungal cells spread hematogenously via cell lysis or vomocytosis (a nonlytic process in which an immune response is being prevented).<sup>1,3</sup> After exposure, these fungal cells can cause asymptomatic condition or they can cause pneumonia-like manifestations. They can also lead to some neurological clinical conditions such as meningitis, meningoencephalitis, and cryptococcomas.<sup>4</sup> Regardless of the decreasing rate of cryptococcosis, world still has a high cryptococcal infection incidence in immunocompromised patients.<sup>5</sup> Despite the increase in information about this pathogen and the improvement of patients' prognosis, mortality due to cryptococcal meningoencephalitis is high, with ranging between 24% and 47% in different trials. The highest rate of disease was reported from low and middle-income countries, specially, in areas with high burden of HIV positive patients.<sup>6</sup>

Here, we report a case with newly diagnosed HIV and concurrent cryptococcal pneumonia and meningoencephalitis.

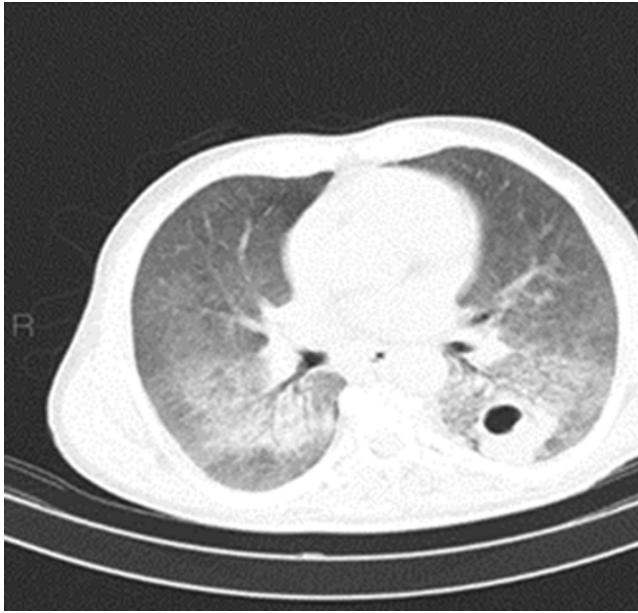
## 2 | CASE HISTORY/EXAMINATION

A 67-year-old male patient was admitted to our hospital with complaints of continuous and gradually worsening

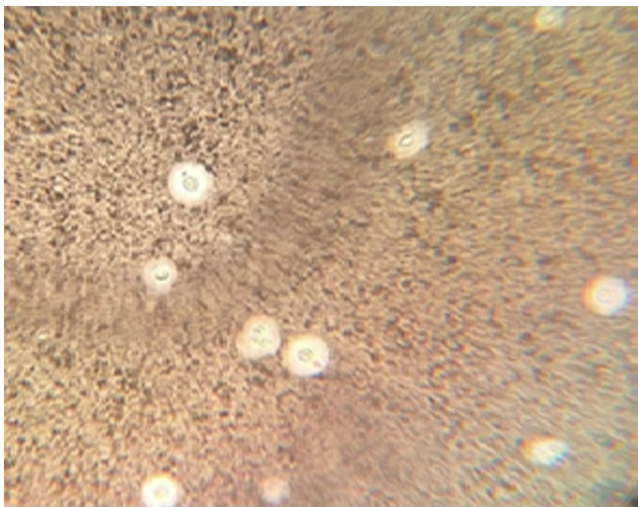
shortness of breath, fever, productive cough, headache, loss of appetite, and weight loss since 1.5 months ago which got worse 15 days prior to admission. Meanwhile, he had visited the outpatient clinic several times and had no improvement. He was a chef from a city from north of Iran with five children. Medical history revealed inguinal surgery for hernia, 10 years ago and prostate surgery, 1 year ago. His social history, familial history and drug history were unremarkable, except seretide and salbutamol that were started in 15 recent days. The physical examination revealed a somnolent patient with 13/15 score on the Glasgow coma scale, who was febrile (T:38.8°C) and had BP:90/60, RR:32 breaths/ min, PR:98 breaths/ min. He was in respiratory distress and required oxygen therapy to maintain saturation, so that his O<sub>2</sub> saturation was 76% while he was breathing ambient air and with mask 92%. Severe thrush was detected in the oropharynx. In addition, bilateral crackles were detected on pulmonary auscultation.

## 3 | METHODS

A CT scan of the chest revealed an ill-defined subpleural cavitory lesion in left lower zone with bilateral diffuse ground glass opacity and internal air bronchogram. There were cavitory nodules in right lung. Some small mediastinal lymph nodes were also present (Figure 1) According to the symptoms and pattern of lung CTscan, he was prescribed with intravenous meropenem 1g every 8h, levofloxacin 500mg daily, vancomycin 1g every 12h and co-trimoxazole 900mg daily (divided dose), as well as hydrocortisone 100mg, three times a day and nystatin drop. He was admitted to the ICU due to his low oxygen saturation. The results of laboratory tests showed as following: WBC: 10200/L, Neutrophil: 95%, normocytic anemia, Platelet: 233000 U, ESR (Erythrocyte Sedimentation Rate): 63mm/hour, CRP (C-Reactive Protein): 95, LDH: 831, Urine culture: negative, Urine analysis: normal, Blood culture: negative. On sputum smear: No AFB (acid-fast bacillus) was seen and, sputum culture was negative. Blood levels of electrolytes were normal, as were the results of liver-function and kidney-function tests, Rheumatologic markers and PCR from



**FIGURE 1** Patient's lung CT scan that shows an ill-defined subpleural cavitory lesion in left lower zone with bilateral diffuse ground glass opacity.



**FIGURE 2** India ink staining of CSF that shows budding and non-budding yeasts.

nasopharyngeal specimen for COVID-9 and Influenza virus.

#### 4 | CONCLUSION AND RESULTS

Due to high suspicion of HIV infection, the diagnosis was verified by serological testing with absolute CD4 count less than 50 cells/mm<sup>3</sup>. After starting antiretroviral therapy (ART) including dolutegravir, tenofovir and emtricitabin,

his level of consciousness gradually decreased and his headache got worse. A computed tomography (CT) scan of the brain showed no abnormality. The patient underwent a lumbar puncture and cerebrospinal fluid (CSF) analysis revealed: 10 cells, predominantly lymphocytes, Protein: 343 mg/dL, and Glucose: 98 mg/dL (corresponding blood glucose 284 mg/dL). The direct microscopic examination of CSF with India ink staining showed budding and non-budding yeast compatible with cryptococcus spp. As shown in Figure 2. Liposomal amphotericin B in combination with fluconazole (due to the unavailability of flucytosine) was started with serial lumbar puncture for management of elevated intracranial pressure. After 1 week, He was intubated due to worsening hypoxia. Then a bronchoscopy was performed and his bronchoalveolar lavage was also positive for *Cryptococcus* spp. and negative for other fungal infections. Respiratory distress worsened rapidly and he died 2 weeks after starting antifungal therapy.

In conclusion, as early diagnosis of cryptococcal infection is the key to improving outcomes, any newly diagnosed HIV patient presenting with subacute or chronic headache, particularly those who are CD4-deplete, should be investigated for cryptococcal meningitis.

#### 5 | DISCUSSION

Cryptococcosis by *C. neoformans*, can be considered as a life-threatening condition in HIV-positive patients. There has an increase in the incidence of cryptococcal meningitis but its prevalence is reducing.<sup>7</sup> The most common route of entry for cryptococcus in immunocompromised patients is through inhalation of spores or desiccated yeast cells.<sup>8</sup> In patients with immunosuppression, cryptococcus can start causing symptoms and acute respiratory distress syndrome can rapidly appear as a consequence. After infecting the lungs, these fungi can spread hematogenously and reach the CNS.<sup>9</sup> Available data propose that currently there are two mechanisms by which cryptococcus can enter the CNS. One is to migrate directly through endothelium by transcytosis and other one is being carried inside macrophages. Their polysaccharide capsule has anti-phagocytic properties.<sup>10</sup> There can be several signs and symptoms for CNS involvement, however the rate of patients who develop them is low. These manifestations involve headache, nausea, fever, memory loss, altered level of consciousness, confusion, seizures, and hearing impairment.<sup>1</sup> Cryptococcal pneumonia manifests as fever, productive cough, and chest pain and it can radiologically mimic lung cancer or metastasis, lung tuberculosis, and bacterial pneumonia. It can also be asymptomatic and diagnosed coincidentally.<sup>11</sup> The radiological findings in immunocompromised patients may include

cavitation, lobar opacities, nodules, pleural effusion, and lymphadenopathy.<sup>12</sup>

Patients who are positive for HIV infection especially with low CD4 cell count and with subacute or chronic headache should be considered as candidates for lumbar puncture to investigate cryptococcal meningoencephalitis. In addition to CSF cell count, CSF culture, and india ink, we can assess CrAg in CSF. We can also detect CrAg in serum. We can also use blood culture, chest x ray, head CT scan, and MRI.<sup>13</sup> Lateral flow assay (LFA) with a sensitivity of more than 95% and a specificity of 100% is a new laboratory tool being used for detecting cryptococcal antigen.<sup>1</sup> Since we didn't have CrAg, we used india ink staining to detect *Cryptococcus*.

The initial therapy should contain antifungal drugs. A two-week therapy with amphotericin B at 3 mg/kg/day and flucytosine at 100 mg/kg/day as induction phase. Afterwards, therapy should be continued with fluconazole for eight to 12 months as consolidation phase.<sup>12</sup> Studies suggested that a combination of amphotericin B with flucytosine can have a better fungicidal effect with lower risk of failure in treatment rather than a combination of amphotericin B with fluconazole.<sup>14</sup> Due to the unavailability of flucytosine, we prescribed liposomal amphotericin B in combination with fluconazole for our patient.

A better clinical outcome for patients with meningoencephalitis is related to the choice of initial therapy and handling raised intracranial pressure. An elevated opening pressure of more than 25 cm of CSF requires serial lumbar punctures to reduce the pressure to less than 20 cm of CSF.<sup>15</sup>

As we can see in presented case ART should be delayed at least 2 weeks after the start of antifungal therapy, due to the occurrence of immune reconstitution inflammatory syndrome (IRIS) resulting in worsening symptoms and sometimes death as happened in our patient.

## AUTHOR CONTRIBUTIONS

**Hamed Mehdinezhad:** Writing – review and editing. **Sara Ghadir:** Writing – original draft. **Parviz Amri Maleh:** Writing – original draft. **Ailin Akhondzadeh:** Writing – original draft. **Mana Baziboroun:** Conceptualization; writing – original draft; writing – review and editing.

## ACKNOWLEDGMENTS

The authors of the present survey would like to thank the patient who provided us with complete information about his illness and Clinical Research Development Unit of Rouhani Hospital of Babol University of Medical Sciences.

## FUNDING INFORMATION

No funding.

## CONFLICT OF INTEREST STATEMENT

The authors declare no conflict of interest, financial or otherwise.

## DATA AVAILABILITY STATEMENT

The authors confirm that the data supporting the results and findings of this study are available within the article.

## ETHICS STATEMENT

The ethics committee of Babol University of Medical Sciences, Iran (Approval no. IR.MUBABOL.HRI.REC.1401.079).

## CONSENT

Written informed consent was obtained from the patient to publish this report in accordance with the journal's patient consent policy.

## HUMAN AND ANIMAL RIGHTS

No animals were used in this research. The human research procedure was in accordance with the standards set forth in the Declaration of Helsinki principles of 1975, as revised in 2013 (<http://ethics.iit.edu/ecodes/node/3931>).

## ORCID

Mana Baziboroun  <https://orcid.org/0000-0001-6251-9682>

## REFERENCES

1. Bramantono B, Danial A, Hadi U. A case of an AIDS patient with *Cryptococcus neoformans* infection. *Pan Afr Med J*. 2020;36(1).
2. Kajeekul R, Mekawichai P, Chayakulkeeree M. Clinical features of Cryptococcal meningoencephalitis in HIV-positive and-negative patients in a resource-limited setting. *J Fungi*. 2023;9(9):869.
3. Johnston SA, May RC. *Cryptococcus* interactions with macrophages: evasion and manipulation of the phagosome by a fungal pathogen. *Cell Microbiol*. 2013;15(3):403-411.
4. Kakizaki MIT, Melhem MDS. CRYPTOCOCCOSIS: a bibliographic narrative review on antifungal resistance. *An Acad Bras Cienc*. 2023;95:e20220862.
5. Zhao Y, Ye L, Zhao F, et al. *Cryptococcus neoformans*, a global threat to human health. *Infect Dis Poverty*. 2023;12(1):20.
6. Chang CC, Harrison TS, Bicanic TA, Chayakulkeeree M, et al. Global guideline for the diagnosis and management of cryptococcosis: an initiative of the ECMM and ISHAM in cooperation with the ASM. *Lancet Infect Dis*. 2024;S1473-3099(23):00731-4.
7. Magounaki K, Karpidaki K, Anastasopoulos V, Ioannis KM. First HIV diagnosis in a patient with *Cryptococcus Neoformans* meningitis: a case report. *Int J Caring Sci*. 2023;16(2):1055-1058.
8. Shuai S-Y, Xiong L, He X-L, Yu F, Xia Q, Zhou Q. A unique case report of endobronchial cryptococcosis and review of the literature. *Respir Med Case Rep*. 2018;25:247-252.



9. Akrim Y, Ouasif H, Zrikem H, El Hakkouni A, Ouassif H. Disseminated Cryptococcosis revealing an HIV infection: a case report. *Cureus*. 2023;15(4):1-5.
10. Bongomin F, Gago S, Oladele RO, Denning DW. Global and multi-national prevalence of fungal diseases—estimate precision. *J Fungi*. 2017;3(4):57.
11. Setianingrum F, Rautemaa-Richardson R, Denning DW. Pulmonary cryptococcosis: a review of pathobiology and clinical aspects. *Med Mycol*. 2019;57(2):133-150.
12. Perfect JR, Dismukes WE, Dromer F, et al. Clinical practice guidelines for the management of cryptococcal disease: 2010 update by the Infectious Diseases Society of America. *Clin Infect Dis*. 2010;50(3):291-322.
13. Kabanda T, Siedner MJ, Klausner JD, Muzoora C, Boulware DR. Point-of-care diagnosis and prognostication of cryptococcal meningitis with the cryptococcal antigen lateral flow assay on cerebrospinal fluid. *Clin Infect Dis*. 2014;58(1):113-116.
14. Rajasingham R, Rolfes MA, Birkenkamp KE, Meya DB, Boulware DR. *Cryptococcal Meningitis Treatment Strategies in Resource-Limited Settings: a Cost-Effectiveness Analysis*. 2012. PLOS medicine.
15. Srichatrapimuk S, Sungkanuparph S. Integrated therapy for HIV and cryptococcosis. *AIDS Res Ther*. 2016;13:1-15.

**How to cite this article:** Mehdinezhad H, Ghadir S, Maleh PA, Akhondzadeh A, Baziboroun M. Cryptococcal meningoencephalitis and pneumonia in a HIV positive patient: A case report. *Clin Case Rep*. 2024;12:e9196. doi:[10.1002/ccr3.9196](https://doi.org/10.1002/ccr3.9196)