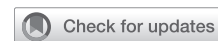

See Article page 81.



Commentary: Pneumonectomy for resection of pulmonary mucormycosis: Enough is never too much

Robert E. Merritt, MD

Pulmonary mucormycosis (PM) is a relatively rare and fatal fungal infection that occurs primarily in immunocompromised patients with underlying medical conditions, such as diabetes, malignancy, and solid-organ transplantation.^{1,2} Pulmonary infection with mucormycosis is caused by inhalation of spores resulting in fungal pneumonia and resultant necrosis and infarction of lung tissue. PM can spread directly or hematogenously to surrounding thoracic structures in the mediastinum. Despite improved treatments, the mortality rate for PM is 96% for disseminated disease and 76% for pulmonary disease.^{2,3} The diagnosis of PM requires a high degree of clinical suspicion, and clinical, radiographic, bronchoscopic, and microbiologic data should be used to arrive at a timely diagnosis. Effective management of PM remains difficult and challenging due to the local invasiveness of mucormycosis and the paucity of evidence-based data to guide the optimal clinical management and decision-making. Because PM is relatively rare, most published reports describing the clinical outcomes for PM consist of primarily small clinical series and case reports.

The current cornerstone of treatment for PM is typically amphotericin B and aggressive surgical debridement of the fungal mass. The current clinical evidence on treatment

From the Division of Thoracic Surgery, The Ohio State University-Wexner Medical Center, Columbus, Ohio.

Disclosures: Dr Merritt reported speaker for Intuitive Surgical.

The *Journal* policy requires editors and reviewers to disclose conflicts of interest and to decline handling or reviewing manuscripts for which they may have a conflict of interest. The editors and reviewers of this article have no conflicts of interest.


Received for publication Oct 11, 2021; revisions received Oct 11, 2021; accepted for publication Oct 22, 2021; available ahead of print Oct 28, 2021.

Address for reprints: Robert E. Merritt, MD, Division of Thoracic Surgery, The Ohio State University Wexner Medical Center, N847 Doan Hall, 410 West 10th Ave, Columbus, OH 43210 (E-mail: Robert.Merritt@osumc.edu).

JTCVS Techniques 2022;11:87-8
2666-2507

Copyright © 2021 The Author(s). Published by Elsevier Inc. on behalf of The American Association for Thoracic Surgery. This is an open access article under the CC BY-NC-ND license (<http://creativecommons.org/licenses/by-nc-nd/4.0/>).

<https://doi.org/10.1016/j.xjtc.2021.10.047>



Robert E. Merritt, MD

CENTRAL MESSAGE

Pulmonary mucormycosis is a locally invasive fungal infection that can be fatal. Optimal management includes systemic anti-fungal therapy and aggressive surgical debridement of involved lung tissue.

outcomes indicate that patients treated with combined medical and surgical therapies have demonstrated better outcomes compared with patients who did not undergo surgical resection.^{4,5} In their case report, Van Ochten and colleagues⁶ described a case of PM that was managed with a right pneumonectomy due to extensive infiltration of PM into the right hilum. This case report perfectly highlights the aggressive local invasiveness of PM and the importance of timely and aggressive surgical resection. Although most reported surgical resections for PM involve lobectomy, there are reported cases that required pneumonectomy.⁷ Regardless of the extent of surgical resection required for PM, the postoperative complications, hospital length of stay, intraoperative blood loss, and mortality are relatively high in reported series.^{8,9} The presence of tissue necrosis, inflammation, and active infection associated with PM will certainly increase the risk of bronchial stump dehiscence and subsequent bronchopleural fistula. As described by Van Ochten and colleagues,⁶ coverage of the bronchial closure with a vascularized muscle flap, such as intercostal muscle, serratus anterior, or latissimus dorsi muscle, should always be considered with lobectomy or pneumonectomy for surgical resection of PM to mitigate the greater risk of postoperative bronchopleural fistula. As previously described, vascular invasion, tissue necrosis, active inflammation, and adhesions are typically

encountered during surgical resection for PM, which contribute to longer operative times and more frequent intraoperative transfusions.⁸ In-hospital mortality for patients undergoing surgical resection for PM is as high as 14.5% to 16.7%.^{8,9} Apart from small case series and case reports, there is minimal evidence-based data to guide surgeons on appropriate patient selection and surgical approach for the management of PM. Based on what is currently known regarding PM, there are some established clinical guidelines for the management of PM, which include correction of the underlying predisposing medical condition, rapid diagnosis with imaging and tissue diagnosis, systemic antifungal therapy, and early aggressive surgical debridement with either lobectomy or pneumonectomy.

References

1. Kauffman CA, Malani AN. Zygomycosis: an emerging fungal infection with new options for management. *Curr Infect Dis Rep.* 2007;9:435-40.
2. Roden MM, Zaoutis TE, Buchanan WL, Knudsen TA, Sarkisova TA, Schaufele RL, et al. Epidemiology and outcome of zygomycosis: a review of 929 reported cases. *Clin Infect Dis.* 2005;41:634-53.
3. Neofytos D, Horn D, Anaissie E, Steinbach W, Olyaei A, Fishman J, et al. Epidemiology and outcome of invasive fungal infection in adult hematopoietic stem cell transplant recipients: analysis of Multicenter Prospective Antifungal Therapy (PATH) Alliance Registry. *Clin Infect Dis.* 2009;48:265-73.
4. Choi H, Lee H, Jeon K, Suh GY, Shin S, Kim HK, et al. Factors affecting surgical resection and treatment outcomes in patients with pulmonary mucormycosis. *J Thorac Dis.* 2019;11:892-900.
5. Tedder M, Spratt JA, Anstadt MP, Hegde SS, Tedder SD, Lowe JE. Pulmonary mucormycosis: results of medical and surgical therapy. *Ann Thorac Surg.* 1994;57:1044-50.
6. Van Ochten N, Rao MV, Bhargava A, Andrade RS, Diaz-Gutierrez I. Right pneumonectomy for invasive pulmonary mucormycosis. *J Thorac Cardiovasc Surg Tech.* 2022;11:81-5.
7. Vercillo MS, Liptay MJ, Seder CW. Early pneumonectomy of pulmonary mucormycosis. *Ann Thorac Surg.* 2015;99:e67-8.
8. Shao W, Zhang J, Feng H, Zhang Z, Liang C, Liu D. Characteristics of pulmonary mucormycosis and the experiences of surgical resection. *J Thorac Dis.* 2020;12:733-40.
9. Multani A, Reveron-Thorton R, Gavert DW, Gomez CA, Montoya JG, Lui NS. Cut it out! Thoracic surgeon's approach to pulmonary mucormycosis and the role of surgical resection in survival. *Mycoses.* 2019;62:893-907.