



## Case Report

# Case of internal jugular vein thrombosis and fever: Lemierre's syndrome or Trousseau's syndrome?

Meng-Yu Wu<sup>a,b†</sup>, Yueh-Tseng Hou<sup>a,b†</sup>, Jian-Yu Ke<sup>a,b</sup>, Giou-Teng Yiang<sup>a,b\*</sup>

<sup>a</sup>Department of Emergency Medicine, Taipei Tzu Chi Hospital, Buddhist Tzu Chi Medical Foundation, New Taipei, Taiwan, <sup>b</sup>Department of Emergency Medicine, School of Medicine, Tzu Chi University, Hualien, Taiwan

†Authors contributed equally to this work.

Submission : 01-Nov-2018  
Revision : 12-Jan-2019  
Acceptance : 01-Feb-2019  
Web Publication : 06-Jun-2019

### ABSTRACT

Internal jugular vein thrombosis is a rare critical cardiovascular emergency, which has potential catastrophic clinical outcomes by resulting in stroke and pulmonary embolism. Several etiologies have been reported; however, there are limited data on Lemierre's and Trousseau's syndromes, which are both rare conditions with advanced disease progression and poor clinical outcomes. Lemierre's syndrome may present with typical progressively infectious symptoms and signs, including sore throat, neck mass, and fever, whereas Trousseau's syndrome may present with thrombophlebitis and painful edema. Without antibiotic agents controlling the infection, the condition of patients with Lemierre's syndrome may progress to sepsis or septic shock. The infection pattern plays an important role for differential diagnosis. Herein, we describe the case of a 46-year-old woman presenting with atypical symptoms of Trousseau's syndrome mimicking Lemierre's syndrome. Laboratory analysis including protein C, protein S, rheumatoid factor, and antinuclear antibody ruled out hypercoagulopathy and autoimmune vasculitis. Abdominal computed tomography and panendoscopy revealed ulcerative tumor at the antrum. Pathological examination confirmed the presence of signet-ring cell adenocarcinoma. We highlight the clinical features and etiologies of internal jugular vein thrombosis, especially in Lemierre's syndrome and Trousseau's syndrome, to aid physicians in making an early diagnosis and providing timely management.

**KEYWORDS:** *Internal jugular vein thrombosis, Lemierre's syndrome, Signet-ring cell adenocarcinoma, Trousseau's syndrome*

## INTRODUCTION

Internal jugular vein thrombosis is a rare critical cardiovascular emergency, which can lead to stroke and pulmonary embolism, causing catastrophic clinical outcomes. In 2010, Gbaguidi *et al.* [1] reported that internal jugular vein thrombosis was present in only 1.5% of patients diagnosed with thrombosis. The rate of complications of internal jugular vein thrombosis was up to 58.6%, including 10.3% for pulmonary embolism, 41.4% for postthrombotic syndrome, and 6.9% for hemorrhage related to anticoagulant therapy. The mechanism of this condition is precipitated by Virchow's triad: endothelial damage, local blood flow alternation, and hypercoagulability [2]. The etiologies of internal jugular vein thrombosis have been reported; these include primary venous thrombosis and central venous catheter insertion. However, only a few studies have investigated rare conditions, especially Lemierre's syndrome and carcinoma.

Lemierre's syndrome is an uncommon condition characterized by thrombophlebitis of the internal jugular vein due to head-and-neck infection and septic metastatic infection.

The infection may invade the cervical space and extend into the thorax, leading to mediastinal infections, which are life threatening and have a mortality rate of up to 40% [3]. Trousseau's syndrome is a paraneoplastic syndrome related to malignancy, presenting venous thrombosis and mobile thrombophlebitis. Malignancy-induced internal jugular vein thrombosis accounts for 27.2% of cases, including lung cancer (30.4%), ovarian cancer (17.4%), colon cancer (13%), and breast cancer (9%) [1]. The presentations of cancer-associated internal jugular vein thrombosis may not be specified. Therefore, early diagnosis and timely intervention are very important for physicians to screen for internal jugular vein thrombosis and declare the etiology. We describe a rare case of Trousseau's syndrome as manifested by internal jugular vein thrombosis, mimicking Lemierre's syndrome. The

### \*Address for correspondence:

Dr. Giou-Teng Yiang,  
Department of Emergency Medicine, Taipei Tzu Chi Hospital, Buddhist  
Tzu Chi Medical Foundation, 289, Jianguo Road, New Taipei, Taiwan.  
E-mail: gtyiang@gmail.com

### Access this article online

#### Quick Response Code:



Website: [www.tcmjmed.com](http://www.tcmjmed.com)

DOI: 10.4103/tcmj.tcmj\_34\_19

This is an open access journal, and articles are distributed under the terms of the Creative Commons Attribution-NonCommercial-ShareAlike 4.0 License, which allows others to remix, tweak, and build upon the work non-commercially, as long as appropriate credit is given and the new creations are licensed under the identical terms.

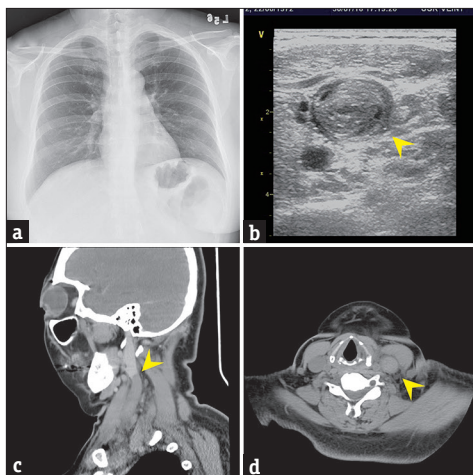
For reprints contact: [reprints@medknow.com](mailto:reprints@medknow.com)

**How to cite this article:** Wu MY, Hou YT, Ke JY, Yiang GT. Case of internal jugular vein thrombosis and fever: Lemierre's syndrome or Trousseau's syndrome? Tzu Chi Med J 2020;32(1):91-5.

etiology and clinical features of internal jugular vein thrombosis are also discussed.

## CASE REPORT

A 46-year-old woman presented with left neck soreness and swelling for 3 weeks. She had no medical history of central venous catheter insertion, traumatic injury, or ischemic disease. Initially, dry cough with fever (up to 38.3°C–38.5°C) for 1 day was noted and controlled with acetaminophen. The left neck mass was associated with local soreness with progression to the left arm and hand swelling, without accompanying sore throat or redness of the overlying skin. The patient reported no progressive fever, dyspnea, or dysphagia. Other symptoms, including body weight loss, night sweats (B symptoms), hemorrhagic tendency/abnormality, skin rash, or arthritis, were not found. On admission, her temperature was 37.1°C; blood pressure, 118/77 mmHg; heart rate, 112 beats/min; and body mass index, 31.75 kg/m<sup>2</sup>. On physical examination, a palpable, soft, fixed mass approximately 5 cm<sup>2</sup> in size on the left neck was noted, with local swelling and tenderness. There was no local lesion in the nasal cavity, oral cavity, or oropharynx. Fibroscopy revealed bilateral movable vocoid cords with a patent airway. Chest X-ray revealed no significant foreign body, widening mediastinum, pneumonia patch, or pulmonary nodule [Figure 1a]. Neck ultrasonography showed occlusion with hyperechogenic thrombosis at the left internal and external jugular veins [Figure 1b]. Chest computed tomography (CT) revealed thrombosis formation at the left internal and external jugular veins, extending to the left brachiocephalic, subclavian, and axillary veins [Figure 1c and d]. There was no local fat stranding or deep neck or mediastinal abscess on CT. Such thrombosis formation may lead to pulmonary embolism. Cardiac ultrasonography was performed, which revealed no significant left atrial dilation, aortic root dilation, valvular lesion, abnormal heart motion, or pulmonary embolism [Figure 2].



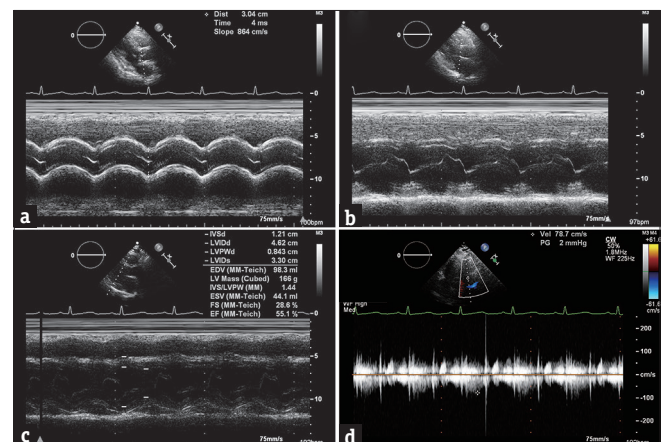
**Figure 1:** (a) Chest X-ray showed no significant pulmonary lesion or widening mediastinum. (b) The heterogeneous mass at the left internal jugular vein on neck ultrasonography was suggestive of a thrombus (arrowhead). (c and d) On chest computed tomography, thrombosis formation at the left internal and external jugular veins was found, extending into the left brachiocephalic, subclavian, and axillary veins (arrowhead)

Laboratory analysis showed borderline leukocytosis (white blood cell count: 9350/ $\mu$ L and normal range: 3500–11000/ $\mu$ L) and an elevated C-reactive protein level (4.47 mg/dL, normal value: <0.33/ $\mu$ L). Hypercoagulopathy analysis showed no significant abnormal findings, including those for protein C/S and antithrombin III. The FDP-D-dimer level was elevated at up to 5272.09 ng/mL (normal range: 0–200 ng/mL). Autoimmune vasculitis was ruled out owing to a normal autoimmune profile, including rheumatoid factor, antinuclear antibody, C3, and C4. The levels of the biomarkers of antiphospholipid syndrome, such as anticardiolipin-IgM/IgG and B2-glycoprotein 1 IgG, were within the normal range.

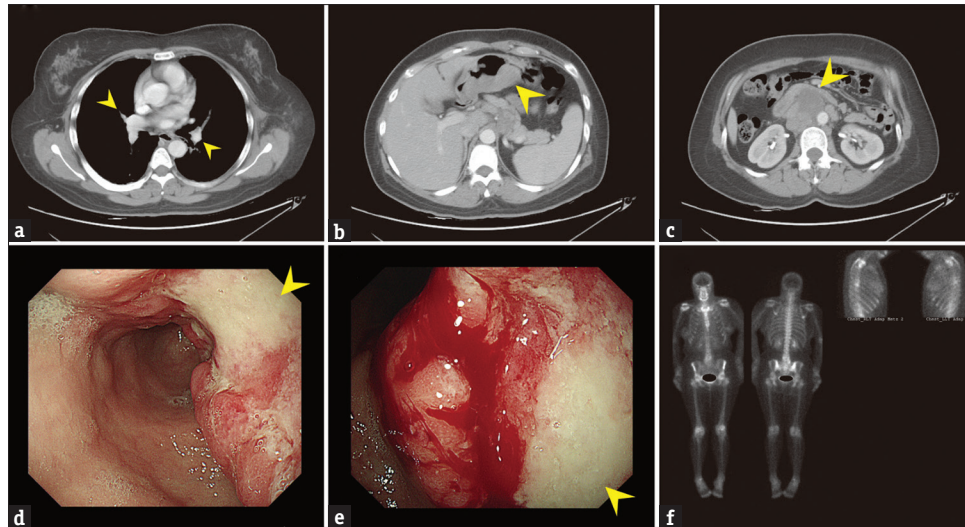
Contrast-enhanced abdominal CT revealed heterogeneous gastric wall thickening, measuring approximately 9.0 cm  $\times$  5.0 cm  $\times$  3.6 cm and localizing at the gastric body and antrum, with multiple metastatic nodes in the gastrohepatic ligament, hepatoduodenal ligament, and celiac trunk. There were also multiple metastatic lymph nodes in the para-aortic space and para-cava space. The pulmonary trunk was patent on chest CT [Figure 3a-c]. Panendoscopy showed a large ulcerative Borrmann type III tumor at the antrum, and local biopsies were then performed [Figure 3d and e]. Pathological examination showed signet-ring cell adenocarcinoma. Immunohistochemical profiling revealed positive findings for CK and CDX-2 and negative findings for HER2/neu. Technetium-99m-methyl diphosphonate entire-body bone scan revealed some faint hot spots in the bilateral rib cages and L4-5 spines, which were compatible with degenerative change without significant evidence of bone metastasis [Figure 3f]. Enoxaparin was used to prevent progression and complications. A surgical intervention was arranged after controlling internal jugular vein thrombosis. Thereafter, she was followed up at the outpatient department, with prescription of edoxaban.

## DISCUSSION

Internal jugular vein thrombosis is a rare disease with several etiologies, such as intravenous drug abuse, prolonged placement of central venous catheters, trauma, autoimmune vasculitis, malignancy, or deep head-and-neck infections. Detailed history taking can collect information early to rule out



**Figure 2:** Cardiac ultrasonography revealed (a and b) no significant left atrial or aortic root dilation, (c and d) significant valvular lesion, or abnormal heart motion

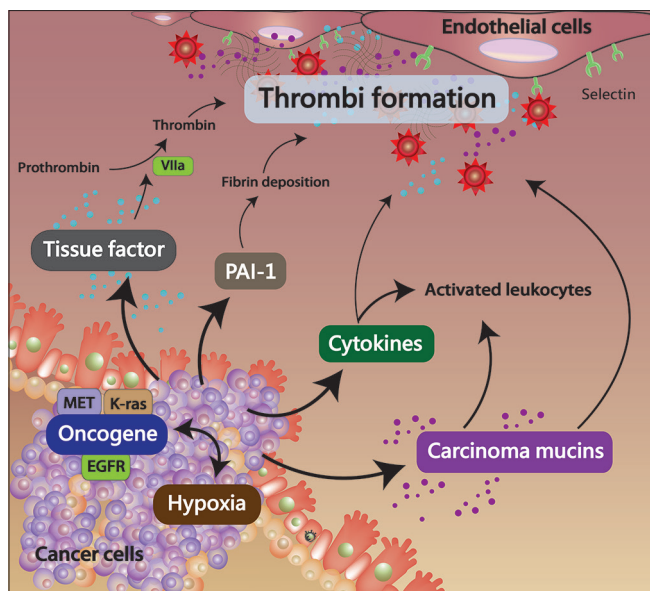


**Figure 3:** (a) The pulmonary trunk was patent in the lung field (arrowhead). (b) Heterogeneous gastric wall thickening was noted, measuring approximately 9.0 cm × 5.0 cm × 3.6 cm (arrowhead). (c) Several metastatic lymph nodes in the para-aortic space and para-cava space were found (arrowhead). (d and e) On panendoscopy, a large ulcerative tumor (Borrmann type III) was noted at the antrum (arrowhead). (f) The entire-body bone scan revealed a degenerative pattern without significant evidence of bone metastasis

intravenous drug abuse, placement of central venous catheters, or trauma. Malignancy-induced thrombophlebitis migrans, also called Trousseau's syndrome, may present with typical symptoms, such as painful swelling, local heat, and other cardiac symptoms in severe cases with pulmonary embolism [4]. In Trousseau's syndrome, fever is rarely reported. In our patient, local inflammation due to thrombophlebitis, initially inducing fever, was suspected. Infection-induced thrombophlebitis of the internal jugular vein, which is known as Lemierre's syndrome, often progresses to sepsis with severe infection signs [5], including pharyngitis, pus formation in the throat, dysphagia, and mediastinitis. The infection symptoms and signs are important to distinguish between the two syndromes. In Lemierre's syndrome, the high spiking fever with sepsis pattern is commonly reported in previous studies. Without timely administration of antibiotic agents, the progression can be rapid and beyond control. Our patient initially had infection signs associated with progression of internal jugular vein thrombosis, mimicking Lemierre's syndrome. Although infection was initially suspected, the fever was controlled with acetaminophen; it only lasted for 1 day, which is not compatible to Lemierre's syndrome. In addition, the presence of autoimmune vasculitis was assessed, including antiphospholipid syndrome, systemic lupus erythematosus, rheumatic fever, and Behcet's disease, and the clinical symptoms and laboratory data were not compatible.

Trousseau's syndrome presenting as internal jugular vein thrombosis is a rare but dangerous condition. Severe cardiovascular events, such as stroke and pulmonary embolism, may occur. Early diagnosis and timely intervention are then very important. Several mechanisms involved in Trousseau's syndrome were reported to explain the formation of thrombosis in patients with malignancies, including secretion of carcinoma mucins, release of tissue factors, expression of oncogenes, and presence of tumor-inducing hypoxic conditions [6]. The presence of hypoxic conditions and expression of oncogenes increases the production of procoagulation factors,

including tissue factors, plasminogen activator inhibitor-1, and pro-inflammatory cytokines, thus activating adhesion molecules in the endothelial cells and platelets [7]. Carcinoma mucins are large groups of glycosylated proteins released from a carcinoma as ligands for selectins [8-10]. Mucins in the bloodstream activate leukocytes through L-selectin ligation, interacting with P-selectin in the endothelial cells and platelets. Finally, the cascade leads to the formation of platelet-rich microthrombi with fibrin deposition. Malignancy induces expression of tissue factors through activation of oncogenes, such as K-Ras, epidermal growth factor receptor, and MET and inactivated tumor suppressive genes, including p53 and PTEN [11]. High serum levels of tissue factors result in platelet aggregation and fibrin deposition through the trigger activity of factor VII to promote the activation of the coagulation pathway [Figure 4] [12]. According to the study by Blom *et al.* [13], the risk for vein thrombosis is the highest in hematological malignancies (adjusted odds ratio: 28; 95% confidence interval [CI]: 4.0–199.7), followed by lung cancer (adjusted odds ratio: 22.2; 95% CI: 3.6–136.1) and gastrointestinal cancer (adjusted odds ratio: 20.3; 95% CI: 4.9–83.0). Gastric cancer inducing Trousseau's syndrome is rarely reported. The risk of inducing Trousseau's syndrome is higher in advance-stage gastric cancer than in early-stage gastric cancer [14-16]. The presentations of gastric cancer-induced thromboembolism were commonly observed in acute cerebrovascular ischemic events. In the studies by Ohashi *et al.* [17] and Ukai *et al.* [18], gastric cancer-induced stroke was found in patients with a hypercoagulable state. This hypercoagulable state increased the risk of thrombosis formation by activating the coagulation pathway. The D-dimer test is a useful test indicating hemostasis and fibrinolysis activation, with a sensitivity of up to 86.4% for physicians to rule out thromboembolic events [19]. According to the study by Park *et al.* [20], D-dimer is also a predictive marker for thromboembolic events in patients with advanced gastric cancer receiving chemotherapy. At the initial diagnosis of malignancy, the risk for vein thrombosis is higher, especially



**Figure 4:** Presence of hypoxic conditions and expression of oncogenes increase the production of procoagulation factors, including tissue factors, plasminogen activator inhibitor-1, pro-inflammatory cytokines, and carcinoma mucins, to activate adhesion molecules in the endothelial cells and platelets, leading to thrombus formation

in the first 3 months (adjusted odds ratio: 53.5; 95% CI: 8.6–334.3). In the study by Caine *et al.* [21], cancer therapy often included hormonal therapy, chemotherapy, and placement of central venous catheters, which are significantly associated with the hypercoagulable state and increase the risk of thrombosis formation [22]. In patients with advanced gastric cancer, close follow-up or monitoring of venous thromboembolism is necessary, including performance of the serial D-dimer test. In addition, anticoagulant agents for venous thromboembolism during treatment are helpful [23].

Lemierre's syndrome is characterized by sepsis with septic emboli and thrombophlebitis of the internal jugular vein after oropharyngeal infection. Laboratory analysis usually showed abnormal infection parameters [24]. Imaging showed thrombosis of the internal jugular vein. *Fusobacterium necrophorum* is the most common pathogen involved in Lemierre's syndrome, and the infection may considerably progress owing to invasion to the parapharyngeal space [25]. The released bacterial toxins promote the secretion of pro-inflammatory cytokines through the activation of immune cells, leading to platelet aggregation and diffuse intravascular coagulation. Disseminated intravascular coagulation accounts for 3%–9% of all cases [26–28]. Thromboembolic events may occur from the internal jugular vein and inferiorly extend into the subclavian vein or superiorly extend into the cavernous sinuses, leading to meningitis [29,30]. In our patient, the initial presentations were more suggestive of Lemierre's syndrome, including fever, respiratory symptoms, elevated infection parameters, and abnormal imaging findings. Procalcitonin treatment was arranged owing to the presence of borderline leukocytosis and elevated C-reactive protein levels and revealed negative for infection. Finally, blood culture revealed negative findings for excluding Lemierre's syndrome.

In Trousseau's syndrome, timely treatment and prevention of thromboembolic events are important to reduce the mortality and morbidity rates. Unfractionated heparin, a complex of glycosaminoglycans, has potential beneficial effects in Trousseau's syndrome owing to its variety of biological activities, including blockage of the binding of L- and P-selectins, activation of heparin cofactor II and protein C inhibitor, and neutralization of cytokines and chemokines [31–33]. Low-molecular-weight heparins (LMWHs), a selective factor Xa inhibitor agent with rare heparin-induced complications, have become another treatment option for Trousseau's syndrome. In 2014, Akl *et al.* [34] conducted a meta-analysis of randomized controlled trials and revealed that their LMWH group had a lower mortality rate after 3 months of treatment (relative risk: 0.71; 95% CI: 0.52–0.98). However, in Trousseau's syndrome, further studies are necessary to confirm the results.

## CONCLUSION

We highlighted the clinical features and differential diagnosis of internal jugular vein thrombosis. In unexplained thrombotic events, physicians must consider Trousseau's syndrome and Lemierre's syndrome because local infection and malignancy could induce thromboembolic events through different mechanisms. Timely administration of anticoagulant agents for prevention and treatment in high-risk patients may improve their clinical outcomes.

## Declaration of patient consent

This study was approved by the Institutional Review Board (IRB) of Taipei Tzu Chi Hospital (IRB number: 07-CR-112). The authors certify that they obtained appropriate patient oral consent. The patient has provided her consent for the use of her images and other clinical information in this study. The patient understood that her name and initials will not be published, and due efforts will be made to conceal her identity; however, anonymity cannot be guaranteed.

## Financial support and sponsorship

This study was supported by a grant from the Taipei Tzu Chi Hospital (TCRD-TPE-108-5).

## Conflicts of interest

There are no conflicts of interest.

## REFERENCES

1. Gbaguidi X, Janvresse A, Benichou J, Cailleux N, Levesque H, Marie I. Internal jugular vein thrombosis: Outcome and risk factors. *QJM* 2011;104:209-19.
2. Boedeker CC, Ridder GJ, Weerda N, Maier W, Klenzner T, Schipper J. Etiology and therapy of the internal jugular vein thrombosis. *Laryngorhinootologie* 2004;83:743-9.
3. Isaacs LM, Kotton B, Peralta MM Jr., Shekar R, Meden G, Brown LA, et al. Fatal mediastinal abscess from upper respiratory infection. *Ear Nose Throat J* 1993;72:620-2, 624-6, 631.
4. Chen KH, Chen YJ, Liaw CC, Chang HJ, Yeow KM. Left internal jugular vein thrombosis due to a lung tumor. *Chang Gung Med J* 2003;26:458-62.
5. Chua SH, Ong SCL, Liew YH. Variant of Lemierre's syndrome with internal jugular vein aneurysm. *BMJ Case Rep* 2017;2017. pii: bcr-2017-223371.
6. Rickles FR. Mechanisms of cancer-induced thrombosis in cancer.

- Pathophysiol Haemost Thromb 2006;35:103-10.
7. Varki A. Trousseau's syndrome: Multiple definitions and multiple mechanisms. *Blood* 2007;110:1723-9.
  8. Carraway KL, Fregien N, Carraway KL 3<sup>rd</sup>, Carraway CA. Tumor sialomucin complexes as tumor antigens and modulators of cellular interactions and proliferation. *J Cell Sci* 1992;103(Pt 2):299-307.
  9. Kim YS, Gum J Jr., Brockhausen I. Mucin glycoproteins in neoplasia. *Glycoconj J* 1996;13:693-707.
  10. Kim YJ, Borsig L, Han HL, Varki NM, Varki A. Distinct selectin ligands on colon carcinoma mucins can mediate pathological interactions among platelets, leukocytes, and endothelium. *Am J Pathol* 1999;155:461-72.
  11. Dicke C, Langer F. Pathophysiology of Trousseau's syndrome. *Hamostaseologie* 2015;35:52-9.
  12. Ikushima S, Ono R, Fukuda K, Sakayori M, Awano N, Kondo K. Trousseau's syndrome: Cancer-associated thrombosis. *Jpn J Clin Oncol* 2016;46:204-8.
  13. Blom JW, Doggen CJ, Osanto S, Rosendaal FR. Malignancies, prothrombotic mutations, and the risk of venous thrombosis. *JAMA* 2005;293:715-22.
  14. Amasaki Y, Kuga T, Kunisue Y, Hirata K, Fujii Y, Nagatomi Y, et al. A case of stageIV gastric cancer with development of Trousseau's syndrome during neoadjuvant chemotherapy. *Gan To Kagaku Ryoho* 2015;42:1001-4.
  15. Kamiyama H, Ichikawa R, Arima S, Sugiyama Y, Takei M, Namekata K, et al. Gastric cancer with multiple intramural metastases and metastasis to the small intestine which eventually developed Trousseau's syndrome: Report of a case. *Clin J Gastroenterol* 2014;7:117-22.
  16. Chien TL, Rau KM, Chung WJ, Tai WC, Wang SH, Chiu YC, et al. Trousseau's syndrome in a patient with advanced stage gastric cancer. *World J Gastroenterol* 2015;21:10049-53.
  17. Ohashi S, Yazumi S, Nishio A, Fukui T, Asada M, Chiba T. Acute cerebral infarction during combination chemotherapy with s-1 and cisplatin for a young patient with a mucin-producing adenocarcinoma of the stomach. *Intern Med* 2006;45:1049-53.
  18. Ukai K, Okajima A, Yamauchi A, Sasaki E, Yamaguchi Y, Kimura H, et al. Total palliative care for a patient with multiple cerebral infarctions that occurred repeatedly in association with gastric cancer (Trousseau's syndrome). *Palliat Support Care* 2013;11:169-72.
  19. Chen C, Li G, Liu YD, Gu YJ. A new D-dimer cutoff value to improve the exclusion of deep vein thrombosis in cancer patients. *Asian Pac J Cancer Prev* 2014;15:1655-8.
  20. Park K, Ryoo BY, Ryu MH, Park SR, Kang MJ, Kim JH, et al. Incidence of venous thromboembolism and the role of D-dimer as predictive marker in patients with advanced gastric cancer receiving chemotherapy: A prospective study. *World J Gastrointest Oncol* 2017;9:176-83.
  21. Caine GJ, Stonelake PS, Lip GY, Kehoe ST. The hypercoagulable state of malignancy: Pathogenesis and current debate. *Neoplasia* 2002;4:465-73.
  22. Falanga A. Mechanisms of hypercoagulation in malignancy and during chemotherapy. *Haemostasis* 1998;28(Suppl 3):50-60.
  23. Kirwan CC, Nath E, Byrne GJ, McCollum CN. Prophylaxis for venous thromboembolism during treatment for cancer: Questionnaire survey. *BMJ* 2003;327:597-8.
  24. Lai C, Vummidi DR. Images in clinical medicine. Lemierre's syndrome. *N Engl J Med* 2004;350:e14.
  25. Johannesen KM, Bodtger U. Lemierre's syndrome: Current perspectives on diagnosis and management. *Infect Drug Resist* 2016;9:221-7.
  26. Eykyn SJ. Necrobacillosis. *Scand J Infect Dis Suppl* 1989;62:41-6.
  27. Moreno S, García Altozano J, Pinilla B, López JC, de Quirós B, Ortega A, et al. Lemierre's disease: Postanginal bacteremia and pulmonary involvement caused by *Fusobacterium necrophorum*. *Rev Infect Dis* 1989;11:319-24.
  28. Leugers CM, Clover R. Lemierre syndrome: Postanginal sepsis. *J Am Board Fam Pract* 1995;8:384-91.
  29. Riordan T, Wilson M. Lemierre's syndrome: More than a historical curiosa. *Postgrad Med J* 2004;80:328-34.
  30. Riordan T. Human infection with *Fusobacterium necrophorum* (Necrobacillosis), with a focus on Lemierre's syndrome. *Clin Microbiol Rev* 2007;20:622-59.
  31. Kaji T, Itoh F, Hayakawa Y, Oguma Y, Sakuragawa N. Interaction of thrombin with heparin cofactor II and antithrombin III on prostacyclin production by cultured endothelial cells. *Thromb Res* 1989;56:99-107.
  32. Mulloy B, Linhardt RJ. Order out of complexity – Protein structures that interact with heparin. *Curr Opin Struct Biol* 2001;11:623-8.
  33. Koenig A, Norgard-Sumnicht K, Linhardt R, Varki A. Differential interactions of heparin and heparan sulfate glycosaminoglycans with the selectins. Implications for the use of unfractionated and low molecular weight heparins as therapeutic agents. *J Clin Invest* 1998;101:877-89.
  34. Akl EA, Vasireddi SR, Gunukula S, Barba M, Sperati F, Terrenato I, et al. Anticoagulation for the initial treatment of venous thromboembolism in patients with cancer. *Cochrane Database Syst Rev* 2011;113:CD006649.