

Auto-antibodies against P/Q- and N-type voltage-dependent calcium channels mimicking frontotemporal dementia

SAGE Open Medical Case Reports
Volume 6: 1–4
© The Author(s) 2018
Reprints and permissions:
sagepub.co.uk/journalsPermissions.nav
DOI: 10.1177/2050313X17750928
journals.sagepub.com/home/sco



Kyan Younes, Lauren A Lepow, Cynthia Estrada
and Paul E Schulz

Abstract

The behavioral variant of frontotemporal dementia is usually a sporadic and progressive neurodegenerative disorder. Here, we report the subacute onset of a frontotemporal dementia phenotype with a treatable etiology. The patient has a history of rheumatoid arthritis, episcleritis, and thyroid eye disease on immunosuppressive therapy. He experienced a rapid personality change, including inappropriate behavior, which suggested frontotemporal dementia. Results of imaging and neuropsychological testing also suggested frontotemporal dementia. Because of his autoimmune diseases and unusually short onset of symptoms, serum paraneoplastic panel and cerebrospinal fluid were analyzed and revealed elevated P/Q- and N-type calcium channel antibodies. Treatment with therapeutic plasma exchange resulted in a rapid improvement of his behavior and cognition. This case suggests that there may be some treatable causes of frontotemporal dementia symptomatology, that is, paraneoplastic antibodies. In the context of atypical features of frontotemporal dementia, practitioners should maintain a high index of suspicion.

Keywords

Mental health/psychiatry, neurology, paraneoplastic, neuropsychiatry, behavioral neurology, frontotemporal dementia, therapeutic plasma exchange

Date received 15 September 2016; accepted: 22 November 2017

Introduction

Neuronal voltage-gated calcium channels (VGCCs) plays a vital role in cellular neuronal function, including action potential initiation, long-term potentiation, growth cone elongation and gene expression.^{1,2} Paraneoplastic autoimmune encephalitis represent autoimmune inflammation of the brain due to antibodies directed against various intra or extracellular neuronal receptors.³ P/Q- and N-type calcium channel antibodies have been implicated in many neurological paraneoplastic syndromes, most commonly being Lambert–Eaton Syndrome.⁴ Cognitive symptoms were found in 17% of the VGCCs Ab patients.⁵ These cognitive symptoms included limbic and extra-limbic autoimmune encephalopathy, neurodegenerative dementia, mild cognitive impairment, and nonspecific cognitive disorder.⁵ Other neurological manifestations included cerebellar ataxia as well as peripheral nervous system involvement such as neuropathy, brachial plexopathy, and myelopathy.^{3–5}

Frontotemporal dementia (FTD) is a group of neurodegenerative dementias of varied etiology in which the frontal or temporal lobes, or both, are affected with variable degrees of subcortical pathology and degeneration.⁶ FTD is characterized by changes in behavior, language, and executive control and is classified into three variants: behavioral variant FTD (bvFTD), semantic variant primary progressive aphasia (svPPA), and nonfluent/agrammatic variant primary progressive aphasia (nfvPPA). Additionally, FTD-related disorders include progressive supranuclear palsy syndrome (PSP-S),

Department of Neurology, The University of Texas Health Science Center at Houston, Houston, TX, USA

Corresponding Author:

Paul E Schulz, Department of Neurology, The University of Texas Health Science Center at Houston, Behavioral and Biomedical Sciences Building, Rm 4358, 1941 East Road, Houston, TX 77054, USA.
Email: Paul.E.Schulz@uth.tmc.edu



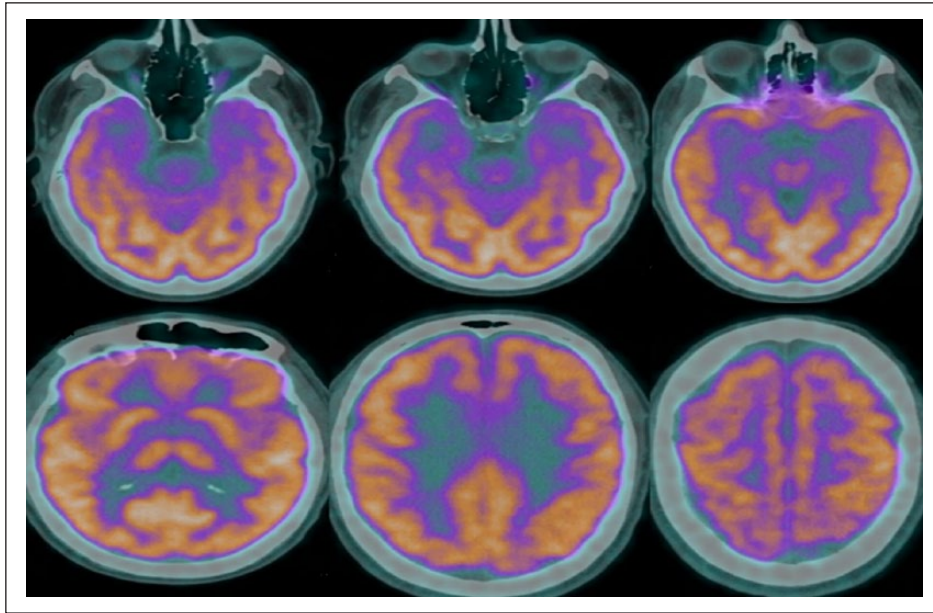


Figure 1. FDG-PET scan revealed temporal hypometabolism and patchy frontal hypometabolism suggestive of FTD.

corticobasal syndrome (CBS), and FTD with motor neuron disease (FTD-MND). The etiology of the FTD is not fully understood but is usually due to neurodegeneration. FTD is considered a tauopathy, in which, neurofibrillary tangles are found intracellularly in the neuron.⁷

Here, we present a patient who presented with the acute onset of behavioral changes that were thought to be due to FTD. A mood disorder, mania, medication abuse, adjustment disorders were also in the differential diagnosis; however, he proved to have a new neuropsychiatric manifestation of an autoimmune disorder, that is, P/Q-type and N-type VGCC antibodies.

Case report

A 54-year-old, right-handed male had a history of rheumatoid arthritis on Adalimumab and Methotrexate, thyroid eye disease, episcleritis, and obstructive sleep apnea. He experienced cognitive decline and behavioral changes that his wife reported occurred over days to weeks.

Prior to onset, the subject was a quiet and reserved man; however, he began exhibiting signs of executive dysfunction and frontal disinhibition, such as sexually acting out, making poor financial decisions, and poor frustration tolerance resulting in explosive episodes, including some resulting in dangerous situations while driving. His wife noted extreme emotional lability at times. She also noted worsening anhedonia, and even catatonic symptoms, that lasted for hours. The patient reported forgetting names and appointments, misplacing items, word-finding difficulties, and difficulties with multitasking and decision-making that interfered with his ability to perform complex daily tasks. He had insight to his cognitive but not behavioral changes.

He saw a neurologist and the differential diagnosis included depression, mania, medication abuse, and adjustment disorder. His mental status exam at that time demonstrated tangential speech and poor attention, which was consistent with collateral from his family and had been impairing his global functioning. A magnetic resonance imaging (MRI) suggested atrophy greater than expected for age. Subsequent neuropsychologic testing showed preserved ability to perform all cognitive tasks, some symptoms of depression and antisocial tendencies in the context of an acute change in personality, which suggested behavioral variant of frontotemporal disease. Valproic acid, sertraline, and modafinil were prescribed to help his mood and concentration. His wife reported an improvement in his affect and behavioral disinhibition.

A few months later, however, the patient's symptoms worsened, causing his wife to seek a second opinion. He was noted to have memory loss across domains, including relative's names, perseveration, and difficulty performing familiar tasks. He scored 26/30 on the Montreal Cognitive Assessment (MOCA). He recalled only 2 out of 5 objects after 5 min delay and was oriented to month but not the date.

Further diagnostic tools were used to confirm a suspicion of FTD: An [F18]-fluoro-2-deoxy-D-glucose positron emission tomography (FDG-PET) was consistent with FTD (Figure 1). However, because of the tempo of the disease and his history of multiple autoimmune diseases, a paraneoplastic panel was sent, and a lumbar puncture was performed to test for inflammation and other reversible etiologies.

The serum paraneoplastic panel revealed elevated antibodies to both the P/Q- and N-type voltage-dependent calcium channels (VDCCs) with levels of +0.24 nmol/L (reference <0.02 nmol/L) and +0.21 nmol/L (reference <0.03 nmol/L),

respectively. Cerebrospinal fluid (CSF) analysis showed glucose of 46 mg/dL (reference 45–80), protein: 46 mg/dL (reference 14–45), red blood cell (RBC): 31/mm³, white blood cell (WBC): 0, and IgG index of 0.4 mg/dL (reference 0.3–0.7 mg/dL). CSF protein electrophoresis did not show oligoclonal bands. Testing for P/Q- and N-type voltage VDCCs antibodies in the CSF has not yet been developed.

These antibodies are reported in association with the Lambert–Eaton syndrome, paraneoplastic cerebellar degeneration, and rarely with limbic encephalitis.^{8–11} We were concerned that they might be responsible for his FTD-like presentation, and thus, he underwent five therapeutic plasma exchange (TPE) sessions.^{9,10} He tolerated the procedures without complications.

There was an almost immediate improvement in his behavior, affect, memory, and concentration starting with his third session. This improvement was noted by medical staff, family, and the patient, who reported that he “woke up.” He scored 29/30 on MOCA after the fifth TPE, recalled 4 out of 5 objects after 5 min delay. We did not repeat neuropsychologic testing since it showed few cognitive changes at baseline. On exam, however, his behavioral manifestations, which were most noticeable, improved greatly. Whole-body PET, performed to rule out a neoplasm that could explain the elevated calcium channel antibodies, was negative for neoplasms. At discharge, Adalimumab and Methotrexate were continued. We planned to adjust his immunomodulatory therapy or repeat plasma exchange if he relapses. At 3 and 6 months and 1-year follow-up appointments, he had stable cognition with no reported behavioral changes.

Discussion

To our knowledge, this is the first report of VGCCs producing behavioral changes mimicking FTD. This report supports the finding of others that VGCC antibodies can be associated with central nervous system symptoms and adds to the wide spectrum of those disorders. N-Type calcium channels are found in the hippocampal pyramidal neurons.¹² P-type Ca²⁺ channels, originally described in cerebellar Purkinje cells, are widely distributed^{13,14} and mediate neurotransmitter release in the central and peripheral nervous systems including hippocampal CA3 pyramidal cells which fits with the bilateral temporal hypometabolism seen on the FDG-PET; this could also explain the patchy frontal hypometabolism seen on the FDG-PET given the wide distribution of calcium channels in the central nervous system. While recognizing autoimmune encephalitis is usually challenging, it is even more difficult when there is an absence of the cardinal signs of encephalitis such as acute confusion, seizure, and hallucinations.

We hypothesize that his use of immunosuppressant therapy may have masked the more acute symptoms of encephalitis. The concentration of serum antibodies in our patient was 0.24 nm/L, which is considered a “medium” concentration

(medium: 0.10–0.99 nmol/L). Although it is rare, medium concentrations of N- and P/Q-type calcium channel antibody can be found in healthy controls and patients with malignancy without neurologic involvement, thus must be correlated with clinical observation.⁹

CSF is normal in 7% of patients with paraneoplastic syndrome. Furthermore, pleocytosis and proteinorachia decreased after 3 months of symptoms onset with protein concentration continuing to be slightly elevated for a longer period of time.¹⁵ The absence of leukocytosis in our patient’s CSF and near-normal protein level could be explained by Methotrexate and Adalimumab and the lumbar puncture being well after 3 months of symptom onset. The acute presentation and abrupt improvement in the patient’s behavior after undergoing plasma exchange strongly support the hypothesis that VGCC antibodies were causative of his behavioral FTD phenotype.

To our knowledge, there is no published literature on the association between rheumatoid arthritis, thyroid eye disease, or episcleritis with increased risk of paraneoplastic syndrome. There is however reported association of limbic encephalitis with relapsing polychondritis¹⁶ Sjogren’s syndrome,¹⁷ and also with myasthenia gravis.¹⁸ The preferential manifestation of cerebral symptoms and not cerebellar symptoms in the presence of P/Q calcium channel antibodies is not fully understood. One hypothesis could be related to the possible presence of preclinical tauopathy in the frontal and temporal lobes that was accentuated by the presence of the calcium channel antibodies.

This case raises the question of whether there may be a subset of patients with reversible neuropsychiatric disorders in whom the reversibility has not been suspected. *Diagnostic and Statistical Manual of Mental Disorders* (5th ed.; DSM-V) advises first ruling out reversible causes of neurocognitive disorders that may masquerade as FTD, but only lists metabolic disturbance, nutritional deficiencies, and infections. It does not mention malignancy or auto-antibodies. This patient suggests that our index of suspicion for reversible etiologies of a behavioral FTD-like illness should be high when there are atypical features and a strong past medical or family history of autoimmune disorder. The treatability of this patient’s disorder also indicates the importance of having a high index of suspicion for reversible etiologies.

To our knowledge, a connection between VGCCs and FTD has not been reported. This correlation may give us some insight into the biological underpinning of this behavioral cognitive disorder. Recent literature has suggested that calcium channel blockers may be effective as treatment for tauopathies, such as FTD. A systematic review concluded that several studies show favorable outcomes, but this may require further investigation.¹⁹

Declaration of conflicting interests

The author(s) declared no potential conflicts of interest with respect to the research, authorship, and/or publication of this article.

Ethical approval

Our institution does not require ethical approval for reporting individual cases or case series.

Funding

The author(s) received no financial support for the research, authorship, and/or publication of this article.

Informed consent

Written informed consent was obtained from the patient for his anonymized information to be published in this article. The patient had the decisional capacity to provide informed consent.

References

1. Simms BA and Zamponi GW. Neuronal voltage-gated calcium channels: structure, function, and dysfunction. *Neuron* 2014; 82(1): 24–45.
2. Clapham DE. Calcium signaling. *Cell* 2007; 131(6): 1047–1058.
3. Dalmau J and Rosenfeld MR. Paraneoplastic syndromes of the CNS. *Lancet Neurol* 2008; 7: 327–340.
4. Lennon VA, Kryzer TJ, Griesmann GE, et al. Calcium-channel antibodies in the Lambert-Eaton syndrome and other paraneoplastic syndromes. *N Engl J Med* 1995; 332: 1467–1474.
5. Zalewski NL, Lennon VA, Lachance DH, et al. P/Q- and N-type calcium-channel antibodies: oncological, neurological, and serological accompaniments. *Muscle Nerve* 2016; 54(2): 220–227.
6. Miller BL. *Frontotemporal dementia*. London: Oxford University Press, 2013.
7. Olney NT, Spina S, Miller BL, et al. Frontotemporal dementia. *Neurologic Clinics* 2017; 35(2): 339–374.
8. Kamiya-Matsuoka C, Blas-Boria D, Williams MD, et al. N-type calcium channel antibody-mediated paraneoplastic limbic encephalitis: a diagnostic challenge. *J Neurol Sci* 2014; 338: 188–190.
9. Finkel L and Koh S. N-type calcium channel antibody-mediated autoimmune encephalitis: an unlikely cause of a common presentation. *Epilepsy Behav Case Rep* 2013; 1: 92–96.
10. Zalewski N, Lennon VA, Lachance DH, et al. P/Q- and N-type calcium-channel antibodies: oncological, neurological, and serological accompaniments. *Muscle Nerve* 2016; 54: 220–227.
11. Graus F, Titulaer MJ, Balu R, et al. A clinical approach to diagnosis of autoimmune encephalitis. *Lancet Neurol* 2016; 15: 391–404.
12. Mills LR, Niesen CE, So AP, et al. N-type Ca²⁺ channels are located on somata, dendrites, and a subpopulation of dendritic spines on live hippocampal pyramidal neurons. *J Neurosci* 1994; 14: 6815–6824.
13. Mintz IM, Venema VJ, Swiderek KM, et al. P-type calcium channels blocked by the spider toxin ω-Aga-IVA. *Nature* 1992; 355: 827–829.
14. Mintz IM, Adams ME and Bean BP. P-type calcium channels in rat central and peripheral neurons. *Neuron* 1992; 9: 85–95.
15. Psimaras D, Carpentier AF and Rossi C. Cerebrospinal fluid study in paraneoplastic syndromes. *J Neurol Neurosurg Psychiatry* 2010; 81(1): 42–45.
16. Ohta Y, Nagano I, Niiya D, et al. Nonparaneoplastic limbic encephalitis with relapsing polychondritis. *J Neurol Sci* 2004; 220: 85–88.
17. Collison K and Rees J. Asymmetric cerebellar ataxia and limbic encephalitis as a presenting feature of primary Sjögren's syndrome. *J Neurol* 2007; 254: 1609–1611.
18. Buckley C, Oger J, Clover L, et al. Potassium channel antibodies in two patients with reversible limbic encephalitis. *Ann Neurol* 2001; 50: 73–78.
19. Peters J, Booth A and Peters R. Potential for specific dihydropyridine calcium channel blockers to have a positive impact on cognitive function in humans: a systematic review. *Ther Adv Chronic Dis* 2015; 6: 160–169.