




Mandibular Nerve Block for Long-Term Pain Relief in a Case of Refractory Burning Mouth Syndrome

Hisham Kassem · Lucien Alexandre · Ivan Urits · Alan D. Kaye ·

Omar Viswanath 

Received: January 15, 2020 / Published online: February 12, 2020
© The Author(s) 2020

Keywords: Burning mouth syndrome; Interventional techniques; Trigeminal nerve block

Burning mouth syndrome represents a chronic condition characterized by an extremely painful burning sensation in the oral mucosa [1]. The

Enhanced Digital Features To view enhanced digital features for this article go to: <https://doi.org/10.6084/m9.figshare.11673723>.

H. Kassem · L. Alexandre
Department of Anesthesiology, Mount Sinai
Medical Center, Miami Beach, FL, USA

I. Urits
Department of Anesthesia, Critical Care, and Pain
Medicine, Beth Israel Deaconess Medical Center,
Harvard Medical School, Boston, MA, USA

A. D. Kaye
Department of Anesthesiology, Louisiana State
University Health Sciences Center, Shreveport, LA,
USA

O. Viswanath (✉)
Valley Anesthesiology and Pain Consultants,
Envision Physician Services, Phoenix, AZ, USA
e-mail: viswanoy@gmail.com

O. Viswanath
Department of Anesthesiology, University of
Arizona College of Medicine, Phoenix, Phoenix, AZ,
USA

O. Viswanath
Department of Anesthesiology, Creighton
University School of Medicine, Omaha, NE, USA

disease has no known definitive etiology and is thought to be of multi-factorial origin with a predisposition in middle-aged females [1]. Traditional therapeutic strategies are aimed at symptomatic relief with oral medications that are often insufficient [2]. With the lack of definitive treatment regimens, the use of localized interventional approaches should be utilized to provide pain relief.

We present the case of a 71-year-old female who suffered from burning mouth syndrome for many years. The patient localized the pain to the left lateral region of the oral mucosa, non-radiating with associated burning, tingling, and dysgeusia. The patient's pain was intractable, interfering with sleep and her overall quality of life. The patient trialed and failed multiple pharmacologic agents including gabapentin, nortriptyline, pregabalin, duloxetine, paroxetine, oxcarbazepine, oxycodone, alprazolam, clonazepam, and viscous lidocaine. Prior to being seen by our service, the patient underwent a left infraorbital nerve block with no reduction in her pain. We decided to proceed with a therapeutic injection of the mandibular division of the left trigeminal nerve.

Under fluoroscopic guidance in the lateral view, the left coronoid notch was identified by asking the patient to open and to close her mouth. A 22-gauge 3.5-in. spinal needle was inserted just below the zygomatic arch directly in the middle of the coronoid notch. The needle

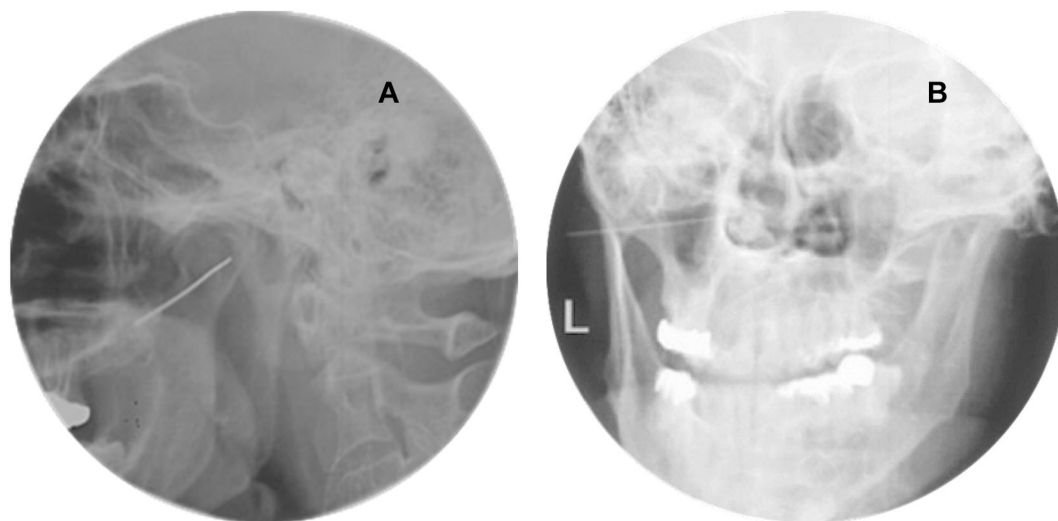


Fig. 1 **a** Lateral fluoroscopic view, which demonstrates needle placement below the zygomatic arch in plane with the pterygoid plate. **b** Anterior–posterior fluoroscopic view

which demonstrates redirection of needle to target the mandibular nerve

was advanced in a plane perpendicular to the skull until contact was made with the pterygoid plate (Fig. 1a). Using an anterior–posterior view, the needle was then redirected posteriorly and advanced a few millimeters medially and cephalad to target the mandibular nerve (Fig. 1b). A total of 0.5 ml contrast was injected under real-time fluoroscopy to rule out intravascular spread. After negative aspiration, a 2-ml mixture of 2% preservative free lidocaine and 10 mg/ml dexamethasone was slowly injected, and the needle subsequently withdrawn. The patient tolerated the procedure well without complication. Upon follow-up, the patient reported 100% relief in pain during the immediate anesthetic phase and 70% relief 1 month postoperatively.

Burning mouth syndrome is a debilitating disease process that requires a multimodal treatment approach. When refractory to conventional therapy, the use of a trigeminal nerve block in the distribution of the pain may prove to be beneficial in a subset of patients. Few case reports have described successful injections; most notably one done by McMillan et al. but required intervention bilaterally and attempted to target larger nerve distributions [3]. Further large observational studies should be done to guide treatment

directions that may be aimed at more long-term relief and determine overall safety.

ACKNOWLEDGEMENTS

Funding. No funding or sponsorship was received for this study or publication of this article.

Authorship. All named authors meet the International Committee of Medical Journal Editors (ICMJE) criteria for authorship for this article, take responsibility for the integrity of the work as a whole, and have given their approval for this version to be published.

Authorship Contributions. Hisham Kassem: interpretation of data, drafting, and revision of article. Lucien Alexandre: interpretation of data, drafting, critical revision of article. Ivan Urits: interpretation of data, drafting, and revision of article. Omar Viswanath: interpretation of data, drafting, critical revision of article. Alan D. Kaye: interpretation of data, drafting, critical revision of article.

Disclosures. Hisham Kassem, Lucien Alexandre, Ivan Urits, Alan D. Kaye and Omar Viswanath have nothing to disclose.

Compliance with Ethics Guidelines. The patient provided their informed consent to publish the article and all procedures were conducted as part of standard care/treatment.

Open Access. This article is licensed under a Creative Commons Attribution-NonCommercial 4.0 International License, which permits any non-commercial use, sharing, adaptation, distribution and reproduction in any medium or format, as long as you give appropriate credit to the original author(s) and the source, provide a link to the Creative Commons licence, and indicate if changes were made. The images or other third party material in this article are included in the article's Creative Commons licence, unless indicated otherwise in a credit line to the material. If material is not included in the article's Creative Commons licence and your intended use is not permitted by statutory

regulation or exceeds the permitted use, you will need to obtain permission directly from the copyright holder. To view a copy of this licence, visit <http://creativecommons.org/licenses/by-nc/4.0/>.

REFERENCES

1. Aravindhan R, Vidyalakshmi S, Kumar M, Satheesh C, Balasubramaniam A, Prasad V. Burning mouth syndrome: a review on its diagnostic and therapeutic approach. *J Pharm Bioallied Sci.* 2014;6(5):21. <https://doi.org/10.4103/0975-7406.137255>.
2. Mcmillan R, Forssell H, Buchanan JA, Glenny A-M, Weldon JC, Zakrzewska JM. Interventions for treating burning mouth syndrome. *Cochrane Database Syst Rev.* 2016. <https://doi.org/10.1002/14651858.cd002779.pub3>.
3. Walega D, Smith C, Epstein J. Bilateral stellate ganglion blockade for recalcitrant oral pain from burning mouth syndrome: a case report. *J Oral Facial Pain Headache.* 2014;28(2):171–5. <https://doi.org/10.11607/ofph.1165>.