

Arthroscopic Ultrasound-Guided Needling: An Effective Technique for the Treatment of Calcific Rotator Cuff Tendinopathy



Vincent Martinel, M.D., and Patricio Fernandois-Maltes, M.D.

Abstract: Calcifying tendinopathies of the rotator cuff that do not respond to conservative treatment may require arthroscopic removal. Intraoperative localization of calcifications can be difficult and is usually performed by bursal needle probing. We present a surgical technique combining arthroscopy and intraoperative ultrasonography based on the ultrasound-guided needle technique to precisely and rapidly locate even small calcium deposits. The modalities may differ depending on tendon topography. This nonirradiating technique with this compact device should be more widely used.

Calcifying tendinopathy of the cuff should first be managed conservatively, although ultrasound-guided needling (USGN) may be used as a second-line therapy. Surgery, usually arthroscopic, is only performed if those options fail.^{1,2} However, this surgery is not simple because the intraoperative localization and removal of calcifications can be difficult, incomplete, or even impossible. Although intraoperative fluoroscopy is the reference technique in difficult cases,³ it can be technically complicated, and it is sometimes impossible to identify calcifications. This study presents the intraoperative use of ultrasonography by surgeons using the USGN technique to position a needle in the center of calcium deposits, instead of the traditional search by needling with a bursal view. However, this procedure cannot be applied to all calcifications and alternative methods are also proposed.

Preoperative Indications, Patient Evaluation, and Imaging

Arthroscopic ultrasound-guided needling (A-USGN) is indicated for the treatment of calcific tendinopathies of the supraspinatus tendon but also of the subscapularis and infraspinatus tendons, whatever their radiologic features. This technique is indicated in all patients with calcific tendinitis of the rotator cuff who do not respond to conservative medical treatment including physical therapy or infiltration and who cannot be treated by USGN aspiration (heterogenous, hyperechogenic calcifications, or with different topographies) or following unsuccessful USGN. Contraindications includes the presence of an enthesopathy without visible macrocalcifications on radiographs and patients presenting with a preoperative frozen shoulder.

A recent radiographic workup is essential. In addition, a preoperative ultrasound scan (POUS) is performed by the orthopaedic surgeon using a Venue * 50 ultrasound mobile device (8-13 MHz probe; GE Healthcare, Madison, WI). The size of each calcification is recorded for each tendon on the longitudinal (Fig 1A) and transverse planes (Fig 1B) as well as its depth in relation to the superficial surface of the tendon and the distance between the posterior edge of the horizontal part of the long head of the biceps and the anterior edge of the calcification (Fig 1C). This assessment is performed with the arm in the extended position, which is not the intraoperative position.

From Groupe Orthopédie Ormeau Pyrénées, ELSAN - Polyclinique de l'Ormeau, Tarbes, France.

The authors report that they have no conflicts of interest in the authorship and publication of this article. Full ICMJE author disclosure forms are available for this article online, as [supplementary material](#).

Received March 7, 2021; accepted April 25, 2021.

Address correspondence to Vincent Martinel, M.D., Groupe Orthopédie Ormeau Pyrénées, ELSAN - Polyclinique de l'Ormeau, 28 Bvd du 8 Mai 1945, 65000 TARBES — France. E-mail: drvmartinel@polyclinique-ormeau.com

© 2021 THE AUTHORS. Published by Elsevier Inc. on behalf of the Arthroscopy Association of North America. This is an open access article under the CC BY-NC-ND license (<http://creativecommons.org/licenses/by-nc-nd/4.0/>).

2212-6287/21401

<https://doi.org/10.1016/j.eats.2021.04.031>

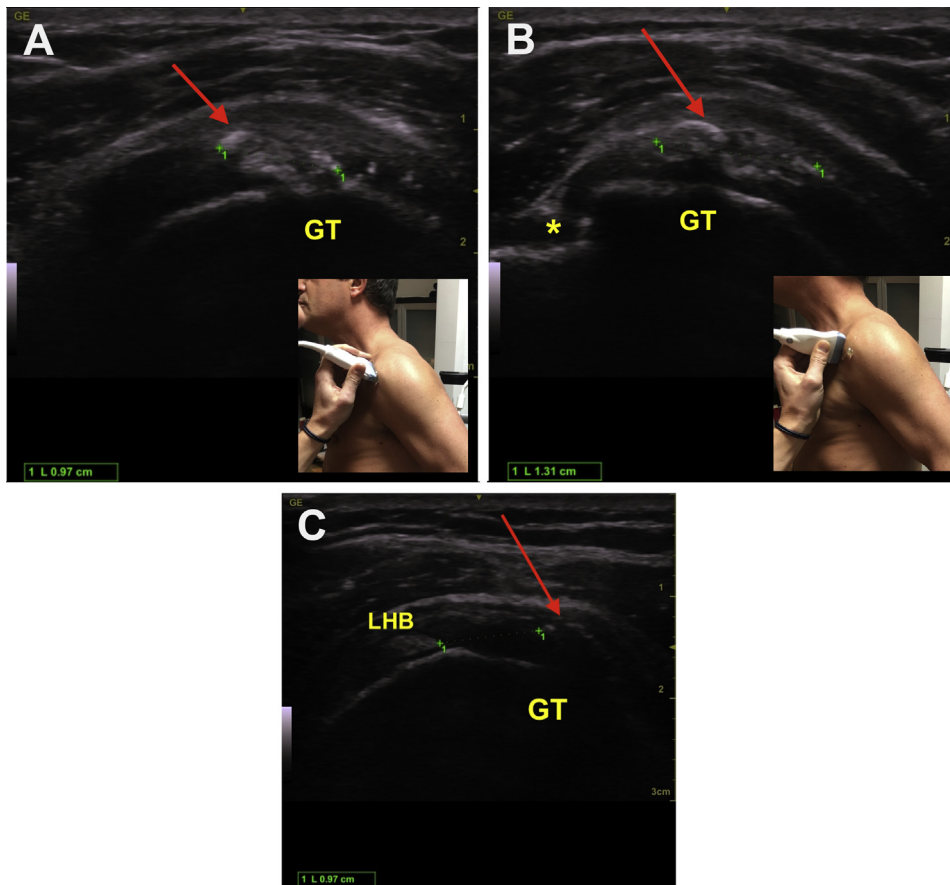


Fig 1. Preoperative ultrasound assessment of a calcification of the supraspinatus tendon on a left shoulder: (Arrow: calcification; *: gutter of the LHB). (A) Measurement of longitudinal section. (B) Transversal measurement. (C) Transversal measurement of the distance between the LHB at the interval of the rotator cuff and the calcification. (GT, greater tubercle; LHB, long head of the biceps.)

Surgical Technique (With Video Illustration)

This Technical Note presents the procedure for the management of a supraspinatus tendon calcification but also can be performed for a topography of subscapularis or infraspinatus tendon. Pearls/pitfalls and advantages/disadvantages are presented in [Tables 1](#) and [2](#).

Surgery is performed with the patient under general anesthesia and with interscalenic block. The patient is placed in the lateral position, with the upper limb held by a hydraulic arm (AssistArm; CONMED, Largo, FL) to prevent any movement before and during the procedure, in adduction and 20° of flexion. Before skin preparation, the operator performs a final ultrasound

assessment called ultrasound skin marking (USM). The acromion relief is drawn, then the center of the calcification is located by marking the middle of the edges of the probe on the longitudinal ([Fig 2A](#)), then transverse ([Fig 2B](#)) planes, providing 4 points that, when intersected, correspond to the orthogonal projection of the calcification on the cutaneous plane ([Fig 2C](#)). After the surgical drapes have been placed, the ultrasound probe is covered in a sterile sleeve, to be used throughout the procedure [Fig 3](#).

For isolated supraspinatus calcifications, only posterior and anterolateral portals are used. The subacromial space is first explored with the scope through the

Table 1. Pearls and Pitfalls

Pearls	Pitfalls
Begin the bursectomy before ultrasound-guided exploration.	Certain calcifications of the supraspinatus tendon may not be visible due to a high critical shoulder angle.
Reduce the irrigation flow with the arthroscope in the subacromial space during all USGN.	Poor visibility if the ultrasound probe is not correctly covered with a sleeve.
Use of a hyperechogenic needle.	Risk of moving the needle positioned by ultrasound guidance during the arthroscopic phase.
Use a POUS and/or USM if the calcification cannot be visualized intraoperatively.	

POUS, preoperative ultrasound scan; USGN, ultrasound-guided needling; USM, ultrasound skin marking.

Table 2. Advantages and Disadvantages

Advantages	Disadvantages
Compact Nonirradiating Precise, 3-dimensional reference marks Can confirm the absence of residual calcium deposits With experience, easier than arthroscopy alone for subscapularis and infraspinatus tendon localisation	Learning curve is needed The arm is positioned in adduction to facilitate A-USGN of the supraspinatus tendon but increases difficulty during the arthroscopic phase because it closes the lateral part of the subacromial space.

A-USGN, arthroscopic ultrasound-guided needling

posterior portal, and a progressive bursectomy is performed with an electrocoagulation probe through the anterolateral portal to visualize the superficial surface of the tendon. Irrigation is reduced, and the scope is left in the subacromial space. The calcification is identified on ultrasound by placing the probe at the USM point and positioning a 24-gauge hyperechoic needle in the center of the calcium deposit, under ultrasound guidance, called A-USGN. This can be

performed transverse to the probe axis (Fig 4) (which is technically difficult because only the tip of the needle is visible but reduces the distance between the point of penetration of the needle and the topography of the deposits) or parallel (Fig 5 A-C): this technique is easier, because the entire length of the needle is visible but increases the aforementioned distance).

Once the ultrasound step is finalized, the surgical assistant is asked to maintain the needle immobilized in

Fig 2. Right shoulder in a 52-year-old female patient in lateral position. Ultrasound skin marking technique for a calcification of supra spinatus tendon is shown: (A) Longitudinal marking. (B) Transverse marking. (C) Cross-marking corresponding to the orthogonal projection of the calcification on the cutaneous plane

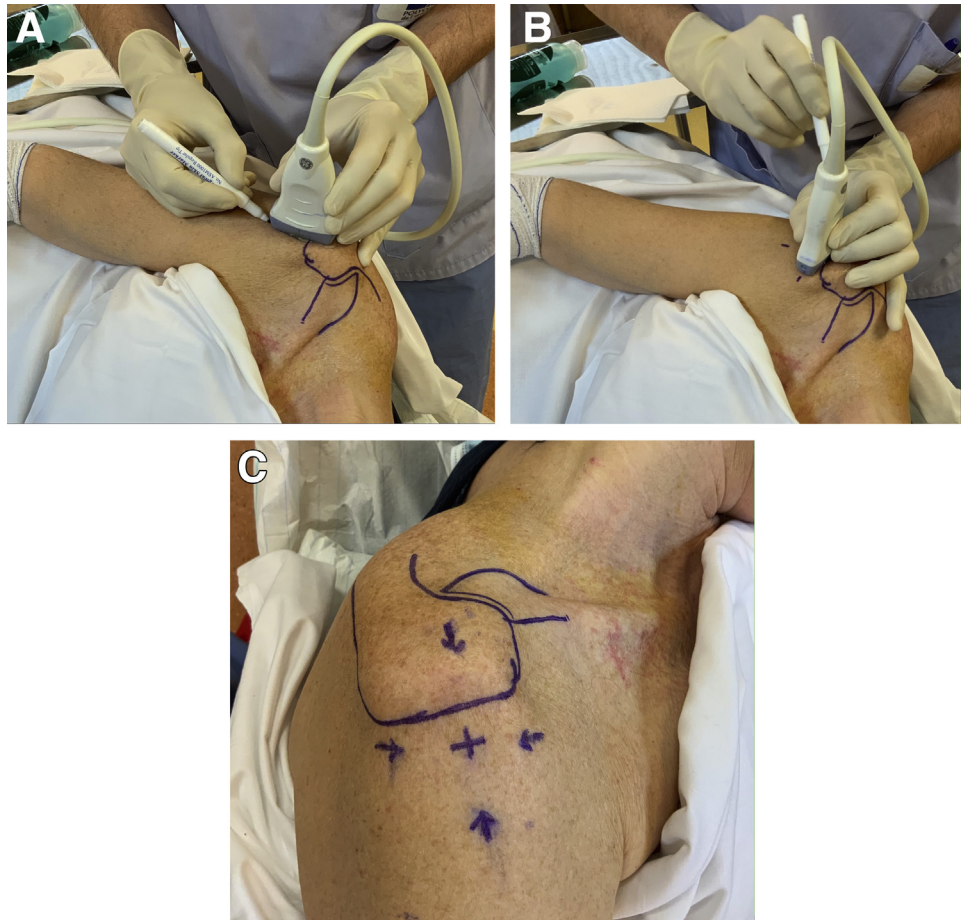

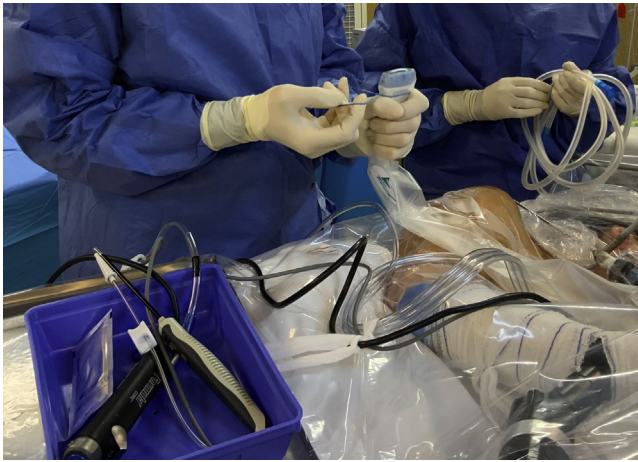


Fig 3. Right shoulder in a 52-year-old female patient in lateral position ultrasound probe covering with sterile sleeve.

the correct position during the arthroscopic phase. The irrigation system is opened for washing, the transfixing needle is visualized on the superficial surface of the tendon, with the scope through posterior portal (Fig 6). In case of doubt, a second needle (16 gauge) can be inserted to explore around the hyperechogenic needle and confirm the topography (Fig 7). Finally, the superficial surface of the tendon is opened with a cold scalpel or with an electrocoagulation probe through the anterolateral portal and the contents are removed with a hook and a mechanical resector. At the end of the procedure, remaining calcium residue is searched for by ultrasound and resected if necessary. Acromioplasty is only performed in the presence of a clear sign of impingement. A tendon suture is only performed if a large transfixing lesion is noted after resection. Video 1 summarizes the steps of POUS, USM, and A-USGN.

If the subscapularis tendon is involved an anterior instrumental portal (cold scalpel, shaver, electrocoagulation probe) is added, and a posterolateral portal is added for infraspinatus involvement.

Rehabilitation

The patient is immobilized in a flexible sling for 7 to 10 days, with immediate self-mobilization of the shoulder, and additional rehabilitation after the first week. Postoperative follow-up includes a radiograph after 6 weeks and a follow-up ultrasound performed by the surgeon at 6 weeks and 3 months.

Discussion

Ultrasonography as well as radiography³ are essential for the preoperative assessment of calcification resections.⁴ However, reinterpretation of the radiologist's images by the surgeon^{5,6} remains difficult⁷ and may result in a loss of information. Conventional intraoperative assessment is sometimes complex, long, or

even impossible.³ even with fluoroscopy.⁸ Moreover, the latter technique results in patient and operating room staff irradiation, is bulky and sometimes makes it difficult for the surgeon to perform the procedure. The fluoroscopic image is 2-dimensional and certain soft calcifications that are visible on conventional radiology will not be seen with this technique.⁸ Intraoperative ultrasonography is a compact device and non-irradiating, providing 3 dimensional images. It is clearly of interest for numerous locations.

At the beginning of our experience, we positioned the needle in the center of the calcium deposit before arthroscopic bursal removal as described by Sigg et al.⁹ and Sørensen et al.¹⁰ However, this was difficult and sometimes the bursectomy took as long as with the conventional technique. Moreover, there was a risk of the needle moving during the use of the mechanical resector or the electrocoagulation probe, causing contraction of the deltoid. We quickly discontinued this procedure, because performing A-USGN after the bursectomy was easier and significantly reduced the operating time. It is important to carefully cover the ultrasound probe with a sterile sleeve and apply a sufficient dose of gel; otherwise, there is a risk of not visualizing deposits during surgery. In the event of difficulty, a conventional needling search can be performed with a 16-gauge catheter strictly perpendicular to the point of the USM (Fig 8), combined with arthroscopic control until deposits have been taken up into the hollow of the needle.

Persistent residual calcifications can be searched for at the end of the procedure by ultrasound, then be resected if necessary, which is a major advantage that has not been previously mentioned in the

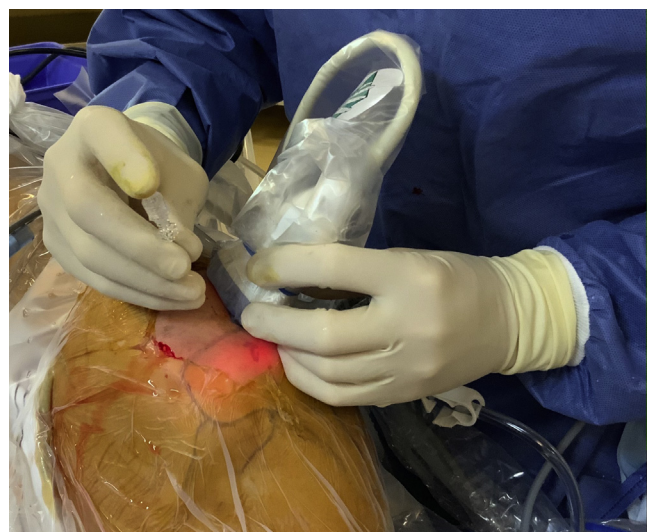

Fig 4. Right shoulder in a 34-year-old female patient in lateral position. Transverse arthroscopic ultrasound-guided needling: placement of a needle perpendicular to the main axis of the probe.

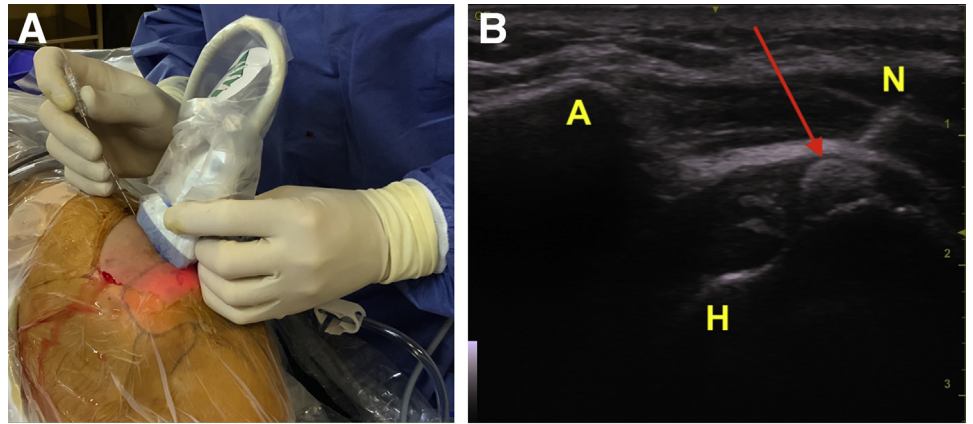


Fig 5. Right shoulder in a 52-year-old female patient in lateral position. Longitudinal arthroscopic ultrasound-guided needling: (A) placement of a needle parallel to the main axis of the probe. (B) Ultrasound view of the entire pathway of the needle (arrow: calcification). (C) Comparison of the entry point on the superficial surface of the tendon between a parallel and perpendicular approach. (A, acromion; H, humeral head; N, needle.)

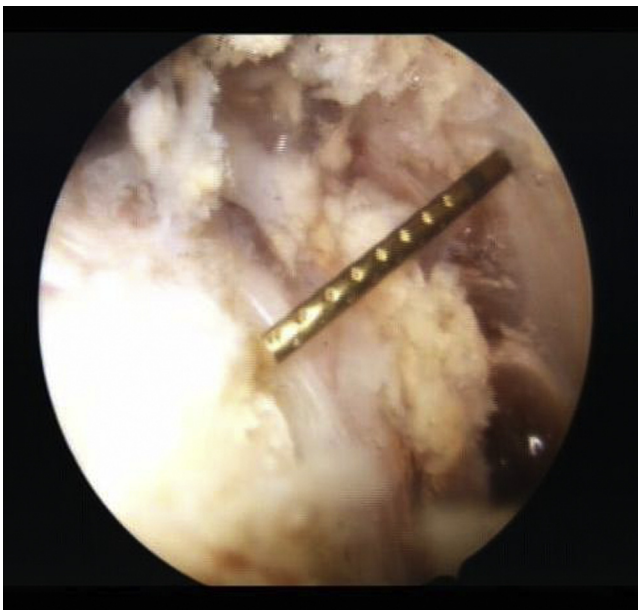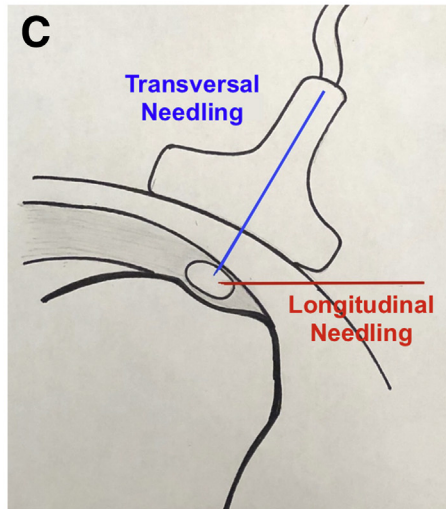


Fig 6. Right shoulder in a 52-year-old female patient in lateral position. Arthroscopic view from posterior portal of a hyperechogenic needle crossing the superficial surface of the tendon (note the notched surface of needle).

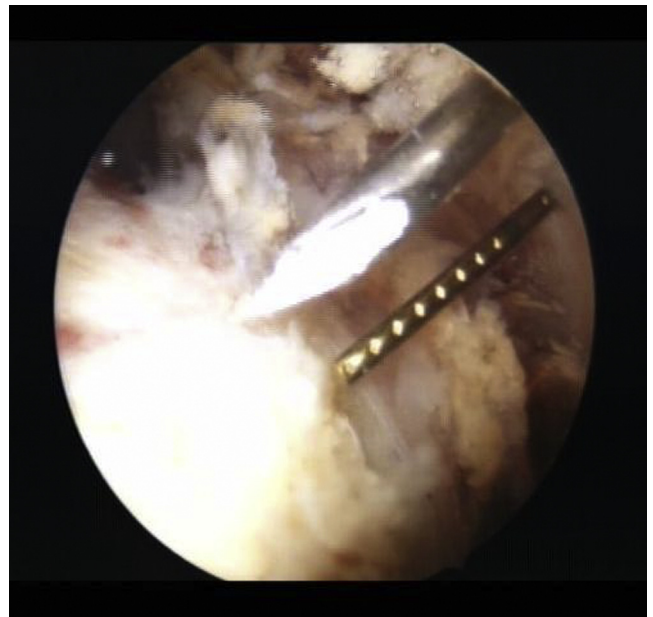

Fig 7. Right shoulder in a 52-year-old female patient in lateral position. Arthroscopic view from posterior portal. Confirmation of the topography of deposits with a second needle near the hyperechogenic needle by posterior portal.

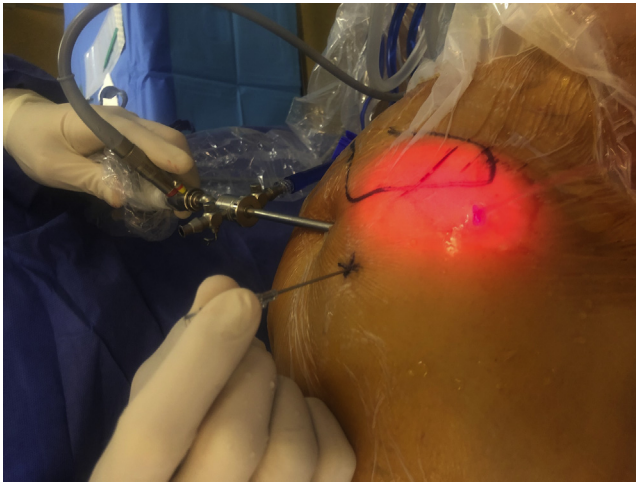


Fig 8. Right shoulder in a 38-year-old male patient in lateral position. Traditional needle search with a 16-gauge needle inserted at the ultrasound skin marking point (used in case of technical difficulty)

literature.^{3,7,10} This technique has a real advantage for subscapularis and infraspinatus tendon involvement, because medium or small deposits are easier to find than under arthroscopy alone.

However, certain calcifications of the supraspinatus may not be visible during surgery because of a high critical shoulder angle in certain patients, the acromion generating an acoustic shadow cone that masks the deposits. POUS data are therefore helpful to identify the specific area by a traditional needling technique, similar to that described by Kayser et al.⁸ Thus, the time spent during the preoperative consultation is essential and may even help identify which calcifications may not be visible during surgery.

Conclusions

A-USGN should be more extensively used. This nonirradiating technique overcomes the disadvantages of fluoroscopy, due to the compact size of the device and more precise 3-dimensional images. The resection procedure is more reliable and the risk of postoperative residue is reduced, wherever the calcifications are found in the tendon. However, it is not always

technically feasible, and the use of preoperative ultrasound data are therefore important. Nevertheless, orthopaedic surgeons must be trained by senior radiologists to perform this technique, which requires theoretical and practical expertise.

References

1. Sansone V, Maiorano E, Galluzzo A, Pascale V. Calcific tendinopathy of the shoulder: Clinical perspectives into the mechanisms, pathogenesis, and treatment. *Orthop Res Rev* 2018;10:63-72.
2. Bechay J, Lawrence C, Namdari S. Calcific tendinopathy of the rotator cuff: A review of operative versus nonoperative management. *Phys Sportsmed* 2020;48:241-246.
3. Sabeti M, Schmidt M, Ziai P, Graf A, Nemecek E. The intraoperative use of ultrasound facilitates significantly the arthroscopic debridement of calcific rotator cuff tendinitis. *Arch Orthop Trauma Surg* 2014;134:651-656.
4. Zheng F, Wang H, Gong H, Fan H, Zhang K, Du L. Role of ultrasound in the detection of rotator-cuff syndrome: An observational study. *Med Sci Monit* 2019;25:5856-5863.
5. Maier D, Jaeger M, Izadpanah K, Bornebusch L, Suedkamp NP, Ogon P. Rotator cuff preservation in arthroscopic treatment of calcific tendinitis. *Arthroscopy* 2013;29:824-831.
6. Clement ND, Watts AC, Phillips C, McBirnie JM. Short-term outcome after arthroscopic bursectomy debridement of rotator cuff calcific tendonopathy with and without subacromial decompression: A prospective randomized controlled trial. *Arthroscopy* 2015;31:1680-1687.
7. Rupp S, Seil R, Kohn D. Preoperative ultrasonographic mapping of calcium deposits facilitates localisation during arthroscopic surgery for calcifying tendinitis of the rotator cuff. *Arthroscopy* 1998;14:540-542.
8. Kayser R, Hampf S, Seeber E, Heyde CE. Value of preoperative ultrasound marking of calcium deposits in patients who require surgical treatment of calcific tendinitis of the shoulder. *Arthroscopy* 2007;23:43-50.
9. Sigg A, Drwas D, Stamm A, Pfeiffer M. Perioperative ultrasound-guided wire marking of calcifying tendinitis of the rotator cuff. *Arch Orthop Trauma Surg* 2011;131:353-355.
10. Sørensen L, Teichert G, Skjødt T, Dichmann OL. Preoperative ultrasonographic-guided marking of calcium deposits in the rotator cuff facilitates localization during arthroscopic surgery. *Arthroscopy* 2004;20:103-104.