

Case report

Osteosarcoma of the talus treated with extraarticular resection “total talectomy” and reconstruction using fibular bone graft: A case report

Achmad Fauzi Kamal*, Damiarta Simorangkir, Ihsan Oesman

Department of Orthopaedic and Traumatology Cipto Mangunkusumo General Hospital, Faculty of Medicine Universitas Indonesia, Jakarta, Indonesia

ARTICLE INFO

Keywords:

Osteosarcoma

Talus

Extra-articular resection

Fibular graft

ABSTRACT

Introduction: In most cases, osteosarcoma occurs in the metaphysis of long bones such as femur, tibia, or humerus. Meanwhile, osteosarcoma of the talus is extremely rare.

Presentation of case: We presented a case of a thirty-eight-year-old male patient with osteosarcoma of the talus treated with limb salvage surgery. That procedure consists of wide excision as extra-articular resection “total talectomy” followed by challenging reconstruction of the defect using fibular graft and followed by internal fixation and arthrodesis. We did an extraarticular resection of the talus, which consists of total talectomy and excision of the distal tibia and fibula. An ipsilateral non vascularized fibular graft as harvested and placed in a horizontal plane to bridge the distal tibia and fibula to the navicular. The graft was fixated using 7.5mm cannulated headless screw and was followed by arthrodesis across the distal tibia and fibula to the calcaneus.

Discussion: Options for surgical treatment for osteosarcoma of the talus is limb salvage surgery. Extraarticular resection “total talectomy” and reconstruction using fibular bone graft technique creates a good functional outcome and no signs of local recurrence were found during one-year follow-up

Conclusion: Extraarticular resection and reconstruction using fibular bone graft is a good technique for management of osteosarcoma of the talus.

1. Introduction

Osteosarcoma is defined as a malignant tumor characterized by bone or osteoid tissue formation by tumor cells. Osteosarcoma is the most common malignant primary bone tumor, with the exception of myeloma [1]. The peak incidence of Osteosarcoma vary depending to its histologic types, with the vast majority of cases categorized as conventional osteosarcoma, occur in the age group between 10 and 20 years [1]. Meanwhile, the mean age of talar osteosarcoma was older than the age of long bone osteosarcoma [2]. [Salunke JOS]. In most cases, this tumor occurs in the metaphysis of long bones such as femur, tibia, or humerus in 70% of the cases while only about 1% involve the bones of the foot [1]. Approximately 75% of osteosarcomas of the foot are found in the calcaneus or metatarsals. Osteosarcoma of the talus is extremely rare; and it is reported that only 0.16% cases of osteosarcoma arose in the talus [3,4].

Patients with osteosarcoma of the foot are not usually been considered candidates for limb-sparing surgery; amputation has been the standard treatment for the past several decades [4]. However, with recent advances in imaging studies and chemotherapy, there are more

and more patients who have elected to undergo limb-salvage treatment [3]. In this report, a thirty-eight-year old male patient with osteosarcoma of the talus was treated with limb salvage surgery. This procedure consists of total talectomy as extra-articular resection followed by challenging reconstruction of the defect using fibular graft and followed by internal fixation and arthrodesis. This work has been reported in line with the SCARE criteria and cites the following paper: Agha RA et al. [5].

2. Presentation of case

A thirty-eight-year-old male presented in our center with one-and-a-half year history of pain in the right ankle. The patient could still go on with his daily activities, therefore he did not seek for medical management. However, he underwent several treatments in traditional massage center, he recalled no history of trauma. Physical examination revealed a swelling on the medial side of the right ankle. The range of motion of the ankle was limited due to pain. From the laboratory data, there were increases of the C-reactive protein (42,9 mg/L; normal < 5 mg/L), lactate dehydrogenase (305 U/L; normal < 300 U/L), and

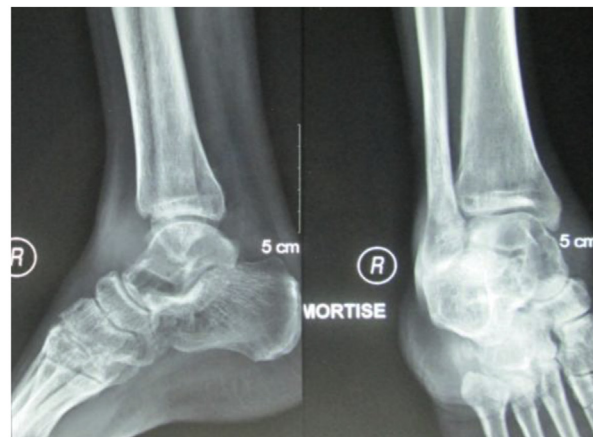* Corresponding author. Department of Orthopaedic and Traumatology Cipto Mangunkusumo General Hospital, Faculty of Medicine Universitas Indonesia, Jl. Diponegoro No.71, Jakarta, Indonesia.

E-mail address: fauzi.kamal@ui.ac.id (A.F. Kamal).

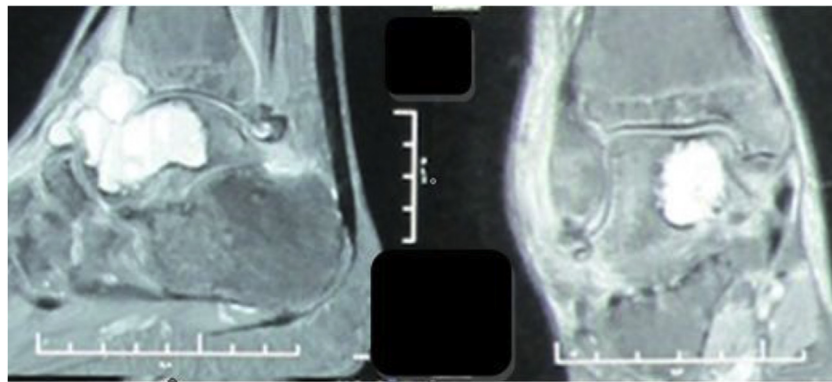
<https://doi.org/10.1016/j.amsu.2018.09.017>

Received 3 May 2018; Received in revised form 12 September 2018; Accepted 14 September 2018

2049-0801/ © 2018 The Author(s). Published by Elsevier Ltd on behalf of IJS Publishing Group Ltd. This is an open access article under the CC BY-NC-ND license (<http://creativecommons.org/licenses/by-nc-nd/4.0/>).



A



B

Fig. 1. Radiological examinations: A). Plain radiograph of the talus showed a geographic lytic lesion on the medial distal part of the talus with well sclerotic margin; B). T-2 weighed MRI showed hyperintense lesion on the talus which already breached the cortex.

procalcitonine (0,18 Ng/ml; normal < 0,05 Ng/ml). Plain radiographs showed a geographic lytic lesion on the medial distal part of the talus. The lesion was well-defined, with sclerotic margin (Fig. 1).

A T2-weighted magnetic resonance imaging (MRI) revealed a 6 × 4 × 2-cm hyperintense destructive lesion which already breached the superior cortex of the talus, with fluid accumulation in the tibiotalar and talonavicular joints. The lesion had a sclerotic margin and was accompanied by the secondary aneurysmal bone cyst (Fig. 1). Plain radiograph of the chest showed no focal lesion.

The patient underwent core biopsy, and the histopathologic examination showed pleomorphic tumor cells with osteoid production, findings compatible with high-grade osteosarcoma (Fig. 2). Neoadjuvant chemotherapy was given to the patient, consisting of four courses of cisplatin and doxorubicin.

After the completion of neoadjuvant chemotherapy, the patient underwent follow up MRI. Compared to the previous MRI, the lesion was smaller in size and had less cystic components. First, we did an extraarticular resection of the talus, we removed the distal part of the tibia and fibula along with the whole body of the talus. The articular cartilage of the tibionavicular joint and the talocalcaneal joint was observed and removed. We harvested autogenic bone graft from the ipsilateral fibula (10 cm long) which was cut into three pieces of bone blocks. The bone blocks were positioned and aligned to fill the defect, bridging from the navicular bone to the distal tibia. We fixated the grafts using two headless screws and one cancellous screw. Finally, we fixated two cancellous screws across the distal tibia and fibula to the

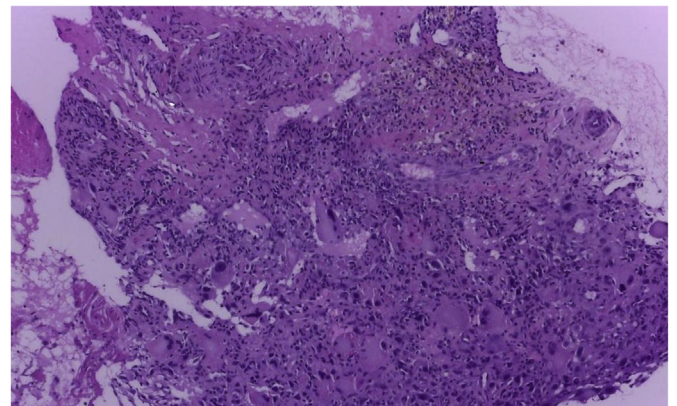


Fig. 2. Histopathological examination (on 400 × magnification) revealed pleomorphic tumor cells with osteoid production. It was consistent with high grade osteosarcoma.

calcaneus (Figs. 3 and 4). Cancellous bone graft from the proximal tibia was added to fill the gaps. Gross and histopathological examination confirmed the osteosarcoma and the margins were free of tumor. The overall tumor necrosis factor was > 95%. Postoperatively, the patient underwent adjuvant chemotherapy.

To evaluate the function of the ankle after the surgical procedure, the patient underwent routine follow up 1 year after the operative

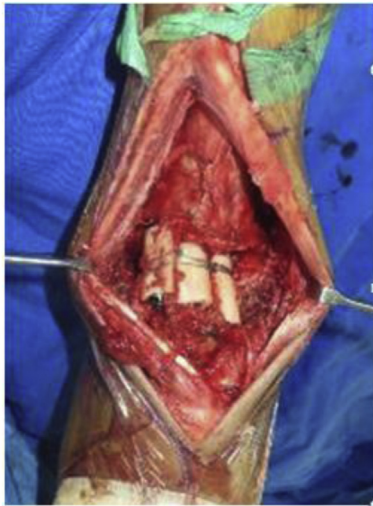


Fig. 3. Bone defect reconstruction using three pieces of fibular grafts aligned to bridge the mid foot to distal tibia.

treatment. He was already pain-free and able to walk without using any support and had major functional improvement in his daily activity. There was no complication nor adverse event that occurred after the operation. The union was achieved on the control x-ray examination

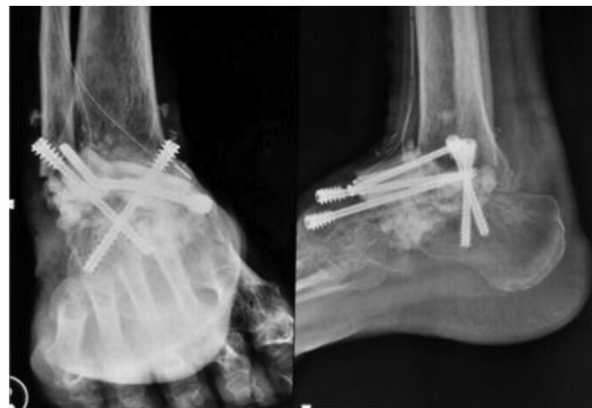
and there was no sign of local occurrence (Fig. 4).

3. Discussion

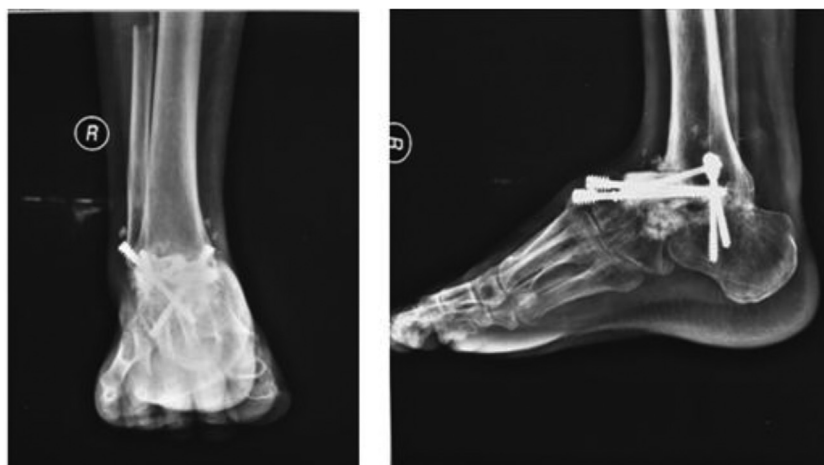
In older patients, however, osteosarcoma tends to occur in atypical areas, and only 51% arise in long tubular bones. The average age of patients with osteosarcoma of the foot bones is higher than that of other locations: 33 years versus 15–20 years [6]. One explanation for the older age at presentation offered in the literature is the tendency for osteosarcoma of the small tubular bones of the feet to arise secondary to another process. According to Biscaglia et al. [6] and Choong et al. [7], osteosarcoma in adulthood can be attributable to radiation, Paget's disease, or benign bone tumours. Our patient was thirty-eight years of age with no history of underlying disease or previous radiation exposure.

Osteosarcoma of the talus is very rare. It was reported by Biscaglia et al. that only three of 1929 cases of osteosarcoma (0.2%) arose in the talus [6]. The very first case of osteosarcoma of the talus was reported by Aminian and Colacch in 1980 [8]. To our knowledge, there are only 21 cases of osteosarcoma of the talus published until now (Table 1).

The clinical findings are atypical, and osteosarcoma of the talus can be easily misdiagnosed, resulting in a delay in proper treatment [9]. The clinical signs are common as in most of bone sarcomas, including pain and formation of a mass, but the relative infrequency of its occurrence often results in a delay between the onset of symptoms and correct diagnosis [2,10]. Seijas et al. stated that the time interval range is



A



B

Fig. 4. Radiographic examinations after surgery. A). Fixation using three screws bridging the distal tibia to navicular, and two screws to complete the arthrodesis across the distal and fibula to the calcaneus; B). Antero-posterior and lateral projections of the foot demonstrated stable position of the screws on 1 year follow up.

Table 1
Osteosarcoma of the talus cases in the literature.

Report/Series	Pt. no.	Sex, age	Type	Surgical treatment	Outcome	Ref. no.
Amini M et al. (1979)	1	M, 21	Fibroblastic	BKA	DOD 19 months	5
Matsumoto K et al. (1993)	2	M, 20	Osteoblastic	BKA	DOD 17 months	4
Kerjes W et al. (1995)	3	M, 19	Parosteal	BKA	NS	6
Jee WH et al. (1998)	4	F, 2	Parosteal	ILR	LTFU	7
Biscaglia R et al. (1998)	5	F, 64	Osteoblastic	BKA	DOD 18 months	1
	6	M, 30	Telangiectatic	BKA	DOD 24 months	
	7	M, 37	Osteoblastic	BKA	NED 120 months	
Choong PF et al. (1999)	8	M, 8	Osteoblastic	BKA	DOD NS	3
Sejas R et al. (2006)	9	M, 20	Osteoblastic	BKA	NED 10 months	8
Ellison BS et al. (1999)	10	F, 81	Osteoblastic	BKA	MET 12 months	9
Goldsmith JR et al. (2007)		F, 81	Osteoblastic	BKA	MET 12 months	16
Moghazy KM et al. (2008)	11	M, 33	Osteoblastic	NS	NS	10
Katagiri H et al. (2008)	12	M, 47	Fibroblastic	LS	NED 47 months	11
Sakayama H et al. (2009)	13	F, 15	Fibroblastic	LS	NED 65 months	12
Verma A et al. (2009)	14	M, 5	Osteoblastic	BKA	NS	13
Wang CW et al. (2011)	15	F, 21	Osteoblastic	LS	NED 3 months	2
Bell SW et al. (2012)	16	M, 44	Fibroblastic	BKA	NED 60 months	14
Anninga JK et al. (2013)	17	M, 37	Osteoblastic	BKA	NED 115 months	15
	18	M, 30	Telangiectatic	BKA	DOD 20 months	
	19	F, 64	Osteoblastic	NS	NS	
Salunke et al. (2016)		M, 65	Osteoblastic	BKA	NED 24 months	18
Our case (2016)	20	M, 38	Osteoblastic	LS	NED 24 months	

ILR – intralesional resection, BKA – below knee amputation, LS – limb sparing, NED – no evidence of disease, MET – metastatic disease, DOD – died of disease, LTFU – lost to follow up, NS – not stated.

longer in osteosarcoma of the talus than in conventional osteosarcoma, in which the diagnosis is frequently made within a few months of symptoms onset [11]. In other words, accurate diagnosis can be complicated by subtle clinical features. It is consistent with our case.

Moreover, osteosarcoma of the talus shows no characteristic periosteal reactions such as Codman's triangle and spicules that is present in osteosarcoma of long bones. Radiologic bony changes may show lytic or sclerotic osteoid bone matrix in the lesion. Further detailed investigation using CT scan was able to show new bone formation in the soft-tissue mass which was not seen on plain radiologic films [10]. MRI is reportedly a reliable means by which to quantify the extent of the tumor [12]. In this present case, however, the initial MRI, unfortunately misled the diagnosis to an aneurysmal bone cyst. Thus, radiological correlation in histopathological diagnosis is very important.

For decades, patients with osteosarcoma of the foot have not been considered candidates for limb-sparing surgery. Amputation has been the standard treatment [4]. However, it had been thought that below-the-knee amputation has many drawbacks, such as the need for the patient to depend on a prosthetic limb, phantom-limb pain, and chronic episodes of skin breakdown [13]. Now, with accurate imaging, a good respond to preoperative chemotherapy, and improving surgical techniques, some individuals may undergo limb-sparing surgery with acceptable outcomes. We considered to do limb-sparing surgery after reviewing thorough respond of the clinical and radiological results after preoperative chemotherapy administration.

Limb-sparing surgery performed in the present case involved total tlectomy with extraarticular resection, excision of the distal tibia and distal fibula, reconstruction with autogenous ipsilateral shaft fibula bone block and allogeneous bone graft, as well as triple arthrodesis. Fortunately, the patient could walk non-weight bearing with crutches as soon as a week postoperatively, emphasizing better functional outcome with this procedure in comparison to amputation counterparts.

However, we have to consider that limb-sparing surgery for talar osteosarcoma has its own drawbacks and limitations. First, the close anatomic confines of the ankle and foot make it technically difficult to achieve a sound oncologic margin of resection. Second, the limb-sparing procedure cannot be performed on patients who have extensive soft-tissue involvement, because the foot and ankle have only thin soft tissues and little muscular coverage of the bone. Third, with limb-sparing ankle arthrodesis, a complete bone union is necessary to

achieve painless and stable walking, and complete bone union normally takes several months or more to achieve. Although, once the bone union has occurred, painless walking is possible with only the aid of a shoe-type orthosis [13].

In our case, wide resection was done without compromising soft tissue covering the ankle and foot. The wound was closed primarily and there was no evidence of infection on follow-ups. A succeeded bone union was achieved and the patient was able to bear the weight in the affected limb without any significant complaint.

4. Conclusion

In conclusion, osteosarcoma of the talus is very rare. Accurate diagnosis can be complicated by subtle clinical features. Radiological correlation in histopathological diagnosis is very important. Although amputation has been the standard treatment, limb-sparing procedure in the case of osteosarcoma of the talus is an option and should be considered in case of giving a good respond to preoperative chemotherapy.

Ethical approval

Ethical approval has been granted in this study

Sources of funding

The authors declare that sponsors had no such involvement.

Author contributions

DS contributed to performed the operation, data collection, analysis and interpretation, manuscript drafting, revising, and approval for publishing; AFK contributed to performed the operation, data collection, analysis and interpretation, manuscript drafting, revising, and approval for publishing; IO contributed to assist the operation, data collection, analysis and interpretation, manuscript drafting, revising, and approval for publishing

Conflicts of interest

The authors declare that there is no conflict of interests regarding

the publication of this paper.

Research registration number

None

Guarantor

Guarantor in this study is AFK

Consent

Written informed consent was obtained from the patient for publication of this case report and accompanying images. A copy of the written consent is available for review by the Editor-in-Chief of this journal on request.

Provenance and peer review

Not commissioned, peer reviewed.

Appendix A. Supplementary data

Supplementary data to this article can be found online at <https://doi.org/10.1016/j.amsu.2018.09.017>.

References

- [1] C.D.M. Fletcher, J.A. Bridge, J.A. Beidge, M.F. Hogendoom PCW, WHO Classification of Tumours of Soft Tissue and Bone, IARC, Lyon, France, 2013, p. 468 [Internet].
- [2] A.A. Salunke, Y. Chen, J. Tan, X. Chen, C. Pearce, M. Puhaindran, Osteosarcoma of the talus misdiagnosis as ankle arthritis : a case report, *J. Orthop. Surg.* 24 (1) (2016) 128–131.
- [3] C.W. Wang, C.Y. Chen, R. Sen Yang, Talar osteosarcoma treated with limb-sparing surgery: a case report, *J. Bone Joint Surg.* 93 (6) (2011) 5–9.
- [4] B.S. Ellison, M. Potter, C. Morrison, J. Mayerson, Talar osteosarcoma in an elderly woman, *Am. J. Orthop. (Belle Mead NJ)* 37 (4) (2008).
- [5] R.A. Agha, A.J. Fowler, A. Saetta, I. Barai, S. Rajmohan, D.P. Orgill, A protocol for the development of reporting criteria for surgical case reports: the SCARE statement, *Int. J. Surg.* 27 (2016) 187–189.
- [6] R. Biscaglia, A. Gasbarrini, T. Böhling, P. Bacchini, F. Bertoni, P. Picci, Osteosarcoma of the bones of the foot—an easily misdiagnosed malignant tumor, *Mayo Clin. Proc.* 73 (9) (1998) 842–847 [Internet].
- [7] P.F. Choong, A.A. Qureshi, F.H. Sim, K.K. Unni, Osteosarcoma of the foot: a review of 52 patients at the mayo clinic, *Acta Orthop. Scand.* 70 (4) (1999) 361–364.
- [8] M. Amini, C. Colavecchi, An Unusual case of primary osteosarcoma of the talus, *Clin. Orthop.* 150 (1980) 217–219.
- [9] K. Matsumoto, S. Hukuda, M. Ishizawa, M. Fujita, M. Egawa, H. Okabe, Osteosarcoma of the talus - a case report, *Clin. Orthop. Relat. Res.* 296 (1993) 225–228.
- [10] A. Verma, J. Pingle, K. Pingle, Osteosarcoma of the talus - a case report and review of literature, *Apollo Med.* 6 (1) (2009) 73–75.
- [11] R. Seijas, J. Minguell, M. Pérez, Osteosarcoma of the talus: a case report, *Acta Orthop. Belg.* 72 (1) (2006) 108–111.
- [12] J.R. Goldsmith, T.H. Lee, High-grade intramedullary osteosarcoma of the talus: case report, *J. Foot Ankle Surg.* 46 (6) (2007) 480–483.
- [13] H. Katagiri, M. Takahashi, T. Takagi, M. Nakagawa, Osteosarcoma of the talus treated successfully with limb-sparing surgery: a case report, *J. Bone Joint Surg. (Am)* 90 (4) (2008) 869–874.