



Since January 2020 Elsevier has created a COVID-19 resource centre with free information in English and Mandarin on the novel coronavirus COVID-19. The COVID-19 resource centre is hosted on Elsevier Connect, the company's public news and information website.

Elsevier hereby grants permission to make all its COVID-19-related research that is available on the COVID-19 resource centre - including this research content - immediately available in PubMed Central and other publicly funded repositories, such as the WHO COVID database with rights for unrestricted research re-use and analyses in any form or by any means with acknowledgement of the original source. These permissions are granted for free by Elsevier for as long as the COVID-19 resource centre remains active.



# COVID-19 and Acute Pulmonary Embolism: A Case Series and Brief Review



Kelly Hughes,<sup>1</sup> Zeba Hussaini,<sup>1</sup> Mahek K Shah,<sup>2</sup> Robert Hilton,<sup>3</sup> and David Oxman<sup>3</sup>

<sup>1</sup>Department of Internal Medicine, Thomas Jefferson University Hospital, Philadelphia, PA, United States; <sup>2</sup>Department of Cardiology, Thomas Jefferson University Hospital, Philadelphia, PA, United States; <sup>3</sup>Department of Pulmonology, Thomas Jefferson University Hospital, 834 Walnut Street, Suite 650, Philadelphia, PA 19107, United States

## ABSTRACT

The SARS-CoV-2 virus, or COVID-19, is responsible for the current global pandemic and has resulted in the death of over 400,000 in the United States. Rates of venous thromboembolism have been noted to be much higher in those infected with COVID-19. Here we report a case-series of COVID-19 patients with diverse presentations of pulmonary embolism (PE). We also briefly describe the pathophysiology and mechanisms for pulmonary embolism in COVID-19. These cases indicate a need to maintain a high index of suspicion for PE in patients with COVID-19, as well as the need to consider occult COVID-19 infection in patients with PE in the right clinical circumstance.

**Keywords:** SARS-CoV-2; COVID; Thrombotic; Pulmonary embolism; Hypercoagulable; ARDS. [[Am J Med Sci 2021;361\(5\):646–649.](#)]

## INTRODUCTION

The SARS-CoV-2 virus, or COVID-19, is responsible for the current global pandemic and by February 2021 had infected over twenty seven million Americans and killed over 475,000.<sup>1</sup> While most people infected with the virus experience only mild symptoms, approximately 10–15% develop significant hypoxia with some progressing to acute respiratory distress syndrome (ARDS), shock, and multi-organ failure.<sup>2</sup>

Accumulating data suggests that COVID-19 is associated with an increased risk of thrombotic events including pulmonary embolism.<sup>3</sup> Retrospective studies of patients with severe SARS-CoV-2 infections identified rates of VTE much higher than that of average ICU patients,<sup>4,5</sup> even in populations of patients with high rates of therapeutic anticoagulation use. Markers of activity in the fibrinolytic pathway – such as D-dimer – have reliably correlated with more severe disease from COVID-19,<sup>6,7</sup> and in those cases prophylactic heparin has demonstrated a mortality benefit<sup>8</sup> suggesting thrombosis and venothromboembolism may contribute significantly to poor outcomes.

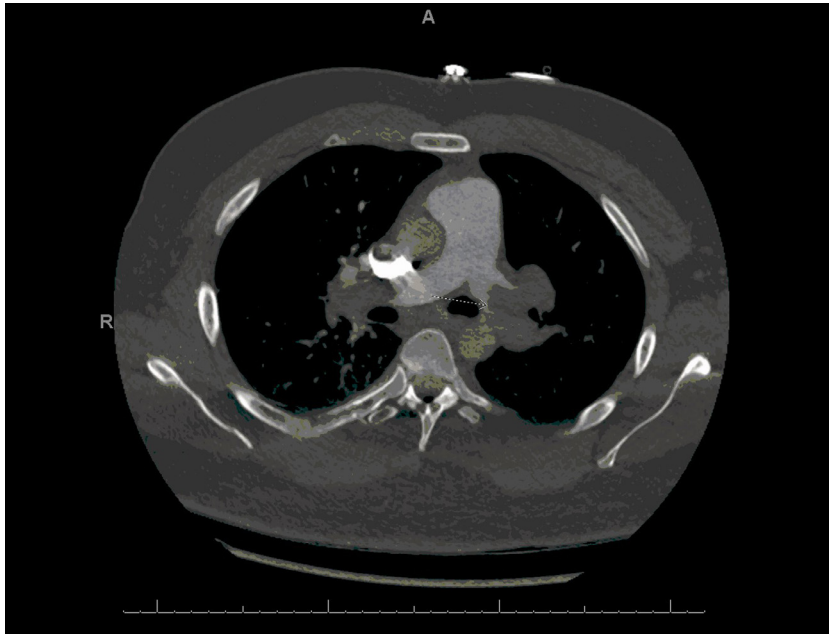
We present here three cases of pulmonary embolism (PE) accompanying COVID-19 infection with disparate presentations. The cases demonstrate a wide spectrum of disease, and illustrates the need to maintain a high index of suspicion for PE in patients with COVID-19 and unexplained or worsening hypoxia or dead space ventilation,

and to consider occult COVID-19 infection in patients presenting with PE whose signs or symptoms are not fully explained by thrombosis.

## CASE 1

A 38-year-old man with no significant past medical history and a recent outpatient diagnosis of COVID-19 infection was brought to the emergency department after a syncopal episode at work. He had tested positive for COVID-19 infection by polymerase chain reaction test two weeks prior to presentation. Over the week prior to presentation, he developed a gradually worsening cough, shortness of breath, decreased appetite, fatigue, and diffuse muscle aches.

At presentation, he appeared ill, restless and diaphoretic with an increased work of breathing. His respiratory rate was 40/min, oxygen saturation 95% on a 100% non-rebreather, and he was hypotensive with a systolic blood pressure of 78 mmHg. He was initially stabilized on high flow NC and IV fluid resuscitation. Labs were notable for an elevated white count, elevated lactate 6.0 mmol/L, serum creatinine 1.5 mg/dl, CRP 2.80 mg/dl, LDH 312 IU/L, D-dimer >69,000 ng/mL, and reduced fibrinogen level of 38 mg/dl. Chest x-ray demonstrated mild bilateral lower lobe opacities and he was admitted to the ICU with the diagnosis of COVID-19 related acute respiratory failure.



**FIGURE 1.** Computed tomography angiography (CTA) showing large proximal bilateral pulmonary emboli.

Because it was felt that his chest x-ray findings did not fully explain his hypoxia or respiratory distress, a CT chest with contrast was performed. The CT scan revealed bilateral pulmonary embolism within the main and lobar branches with right associated heart strain, as well as a few peripheral ground glass and consolidative opacities consistent with typical findings of COVID-19 pneumonia (Fig. 1). 100 mg of tissue plasminogen activator (tPA) was administered in the ER with rapid improvement in hemodynamics and respiratory parameters. Upon arrival to the ICU, his oxygen saturation and blood pressures had normalized. He was started on an intravenous heparin infusion and transitioned to maintenance anticoagulation with apixaban for three months. He was discharged home on hospital day 7 with clinical improvement confirmed during a subsequent outpatient telehealth visit.

## CASE 2

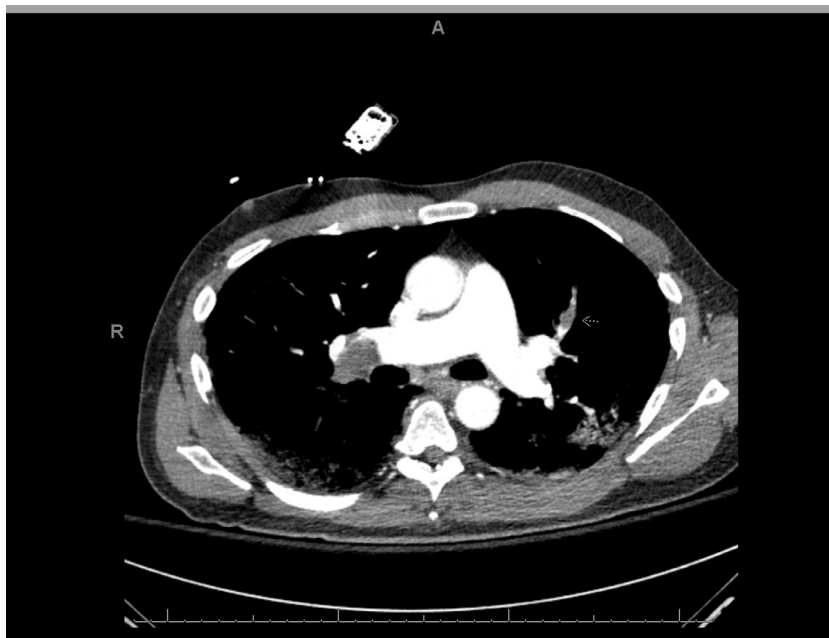A 50-year-old man with no significant past medical history was admitted to the hospital for acute hypoxic respiratory failure due to COVID-19 pneumonia. He initially presented with fevers, dyspnea, myalgias, anosmia, and dysgeusia for 10 days. He had tested positive for COVID-19 by nasopharyngeal PCR 8 days prior. At presentation, he was febrile to 102.3C, tachycardic to 104 beats/min, tachypneic to 38 breaths/min, and hypoxic with an oxygen saturation of 80% on room air. Labs were notable for a white blood cell count of 8600 cells/ $\mu$ L with lymphopenia (absolute lymphocyte count: 770 cells/ $\mu$ L), mild transaminitis (AST 115 IU/L and ALT 53 IU/L), Cr 1.58 mg/dL (from baseline 1.0), CRP 17 mg/dL,

Ferritin 4776 ng/mL, LDH 994 IU/L, CK 2614 IU/L, Procalcitonin 1.06 ng/mL, D-dimer 1020 ng/mL, hs-Tn 15 ng/mL, and BNP 824 pg/mL. Chest x-ray revealed bilateral hazy opacities in the lower lungs.

He was initially admitted to a telemetry floor but developed progressive hypoxia requiring ICU admission and mechanical ventilation. He was treated with hydroxychloroquine, tocilizumab, proning, and antibiotics. He received prophylactic enoxaparin. After extubation on hospital day 9, he experienced an acute hypoxic event requiring initiation of high flow nasal cannula oxygen. CT angiography of the chest revealed an acute pulmonary embolus in the right main pulmonary artery extending into RUL, RML, RLL, and LUL branches (Fig. 2). He was hemodynamically stable and transthoracic echocardiogram revealed no evidence of right heart strain. Labs at the time of PE diagnosis were significant for markedly elevated D-dimer to 45,669 ng/mL and persistently elevated inflammatory markers including serum CRP, ferritin, and LDH. He was treated with therapeutic anticoagulation (heparin and then apixaban) with improvement, and he was discharged home on hospital day 20.

## CASE 3

A 57-year-old man with a past medical history of stage IV lung cancer was admitted with acute hypoxic respiratory failure. He was tachycardic to 110 s beats/min and hypoxic with oxygen saturation of 88% on room air on presentation. Labs were notable for WBC 12,000 cells/ $\mu$ L without lymphopenia (absolute lymphocyte count 2740 cells/ $\mu$ L), elevated BNP to 8591 pg/mL, elevated troponin to 0.37 ng/mL (ULN 0.07). Additional labs

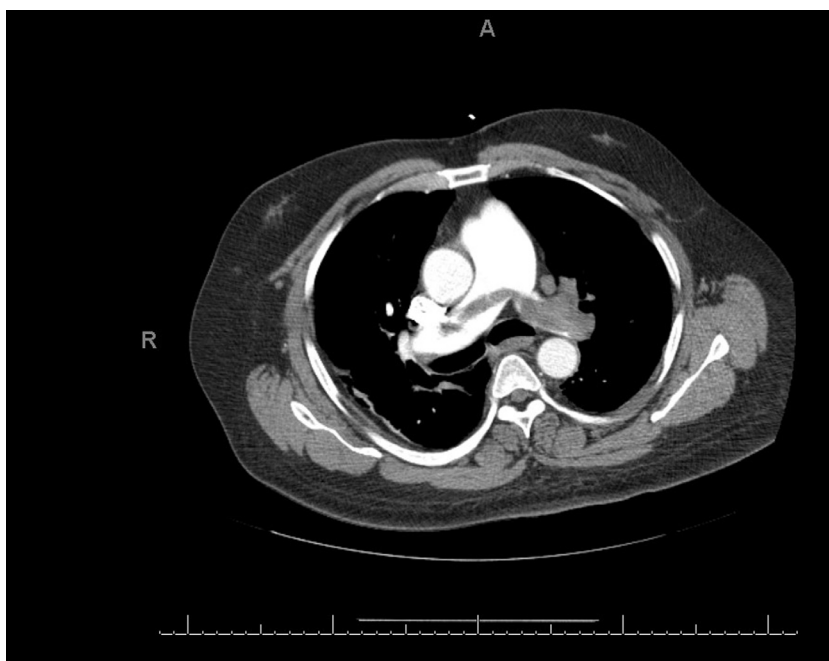


**FIGURE 2.** Computed tomography angiography (CTA) showing pulmonary embolus in the right main pulmonary artery.

were notable for a CRP 4.9 mg/dL, LDH 418 IU/L, D-dimer 788 ng/mL, Ferritin 290 ng/mL, and procalcitonin 0.17 ng/mL. Chest x-ray on admission did not have significant consolidation and CT of the chest with contrast revealed a large saddle PE with a large perfusion defect in the left lower lung (Fig. 3).

A transthoracic echocardiogram revealed a severely dilated right ventricle with reduced function and a positive

McConnell's sign. He underwent successful pulmonary artery mechanical thrombectomy using FlowTriever with improvement in oxygenation. Two days later, while awaiting transfer from the ICU to the medical floor he developed fevers to 101.5 and hypoxia. A chest x-ray revealed new bilateral peripheral opacities and nasopharyngeal COVID-19 PCR returned positive. He was treated with therapeutic anticoagulation antibiotics, and hydroxychloroquine.



**FIGURE 3.** Computed tomography angiography (CTA) showing saddle pulmonary embolus.

Despite these therapies, he continued to decline clinically with escalating oxygen requirement and worsening pulmonary infiltrates. Given his multiple comorbidities, underlying metastatic disease and poor functional status, the decision was made to transition to inpatient hospice.

## DISCUSSION

The above cases demonstrate a variety of presentations for COVID-19 and acute PE – from submassive to massive, and from early in the course of infection to later. Observational studies in COVID-19 patients have reported exceptionally high rates of venous thrombosis and thromboembolism with reported rates of symptomatic venous thromboembolism as high as 25%<sup>4,5,9</sup> and Bompard reported an incidence of pulmonary embolism specifically of 24%.<sup>10</sup> Several studies have also demonstrated a connection between clot turnover and the severity of COVID-19 infection. In the first large publication of patients with COVID-19, measures of clot degradation were found to be elevated in hospitalized patients along with other inflammatory cytokines.<sup>6</sup> Patients with severely elevated levels of these markers had a worse prognosis, and there are reports that for patients with severe COVID-19 disease preemptive therapeutic anticoagulation reduced mortality.<sup>8,11</sup>

Several mechanisms have been offered to explain COVID-19 related system clotting problems. SARS-CoV-2 virus infects vascular endothelial cells via ACE2 receptors on their surface and may cause endothelial cell damage, vasculitis with monocyte and lymphocytic infiltrate, and platelet activation and aggregation. An autopsy series of four patients who died of SARS-CoV-2<sup>12</sup> revealed thrombosed small vessels in the lungs and significant associated hemorrhage. The authors speculated on a role for thrombotic microangiopathy – a platelet-rich clot formation with fibrin deposition within these small vessels – as a significant contributor to their death.

Yet it is not completely clear to what degree COVID-19 exerts an excess risk to thrombosis when compared with other causes of critical illness. Venous thromboembolism is a well-known complication of critical illness in general as well as other viral pneumonias.<sup>13</sup> Additionally, large studies suggest that while the incidence of VTE in general ICU patients is about 2–6%,<sup>14,15</sup> it can be much higher when there is routine testing on asymptomatic patients<sup>16</sup> or as high as 37% in the presence of severe sepsis and septic shock.<sup>17</sup> Additionally, severely ill hospitalized patients with COVID-19 have many of the traditional risk factors for development of acute VTE, including older age, immobility, indwelling central venous catheters, and a need for prolonged mechanical ventilation.<sup>18</sup>

In conclusion, we present three cases of COVID-19 pneumonia complicated by clinically significant pulmonary embolism. Current available anecdotal and larger observational studies suggest that COVID-19 may independently increase the risk for acute VTE, and therefore diagnosis of PE should be considered early in

appropriate patients. Maintaining a high suspicion for venous thromboembolic disease in COVID-19 patients – particularly those with critical illness, unexplained hypoxemia or shock, or rapid clinical deterioration – is advisable. Empiric or preemptive therapeutic anticoagulation may have a role in some severely ill patients with COVID-19, but more study is needed before any recommendations can be made.

## REFERENCES

- Centers For Disease Control and Prevention, 'Coronavirus Disease, Case in the US' Updated June 23, 2020.
- Jordan RE, Adab P, Cheng KK. Covid-19: risk factors for severe disease and death. *BMJ*. 2020;368:m1198. Published 2020 Mar 26.
- Battista Danzi Gian, Loffi Marco, Galeazzi Gianluca, et al. Acute pulmonary embolism and COVID-19 pneumonia: a random association? *Eur Heart J*. 14 May 2020;41(19):1858.
- Klok FA, Kruip MJHA, van der Meer NJM, et al. Incidence of thrombotic complications in critically ill ICU patients with COVID-19. *Thromb Res*. 2020;191:145–147.
- Helms J, Tacquard C, Severac F, et al. High risk of thrombosis in patients with severe SARS-CoV-2 infection: a multicenter prospective cohort study. *Intens Care Med*. 2020;46(6):1089–1098.
- Huang C, Wang Y, Li X, et al. Clinical features of patients infected with 2019 novel coronavirus in Wuhan, China. *Lancet*. 2020;395(10223):497–506.
- Chen N, Zhou M, Dong X, et al. Epidemiological and clinical characteristics of 99 cases of 2019 novel coronavirus pneumonia in Wuhan, China: a descriptive study. *Lancet*. 2020;395(10223):507–513.
- Tang N, Bai H, Chen X, et al. Anticoagulant treatment is associated with decreased mortality in severe coronavirus disease 2019 patients with coagulopathy. *J Thromb Haemost*. 2020;18(5):1094–1099.
- Middeldorp S, Coppens M, van Haaps TF, et al. Incidence of venous thromboembolism in hospitalized patients with COVID-19 [published online ahead of print, 2020 May 5]. *J Thromb Haemost*. 2020. <https://doi.org/10.1111/jth.14888>.
- Bompard F, Monnier H, Saab I, et al. Pulmonary embolism in patients with Covid-19 pneumonia. *Eur Respir J*. 2020.
- Paranjpe I, Fuster V, Lala A, et al. Association of treatment dose anticoagulation with in-hospital survival among hospitalized patients with COVID-19. *J Am Coll Cardiol*. 2020.
- Fox Sharon E, Akmatbekov A, Harbert JL, et al. Pulmonary and cardiac pathology in African American patients with COVID-19: an autopsy series from New Orleans. *Lancet Respir Med*. 2020;8:681–686.
- Bunce PE, High SM, Nadjafi M, et al. Pandemic H1N1 influenza infection and vascular thrombosis. *Clin Infect Dis*. 2011;52:e14–e17.
- Patel Rakesh, Cook DJ, Meade MO, et al. Burden of illness in venous thromboembolism in critical care: a multicenter observational study. *J Crit Care*. 2005;20(4):341–347.
- PROTECT Investigators for the Canadian Critical Care Trials Group and the Australian and New Zealand Intensive Care Society Clinical Trials Group. Dalteparin versus unfractionated heparin in critically ill patients. *New England Journal of Medicine*. 2011;364(14):1305–1314.
- Kupfer Y, et al. Prophylaxis with subcutaneous heparin significantly reduces the incidence of deep venous thrombophlebitis in the critically ill. *Am J Respir Crit Care Med*. 1999;159(3):1740. BROADWAY, NEW YORK, NY 10019 USA: AMER LUNG ASSOC.
- Kaplan D, Casper TC, Elliott CG, et al. VTE incidence and risk factors in patients with severe sepsis and septic shock. *Chest*. 2015;148(5):1224–1230.
- Miri M, Goharani R, Sistanizad M. Deep Vein thrombosis among intensive care unit patients; an epidemiologic study. *Emerg (Tehran)*. 2017;5(1):e13.

Submitted July 14, 2020; accepted December 9, 2020.

Corresponding author: David Oxman Department of Pulmonology, Thomas Jefferson University Hospital, 834 Walnut Street, Suite 650, Philadelphia, PA 19107, United States (E-mail: david.oxman@jefferson.edu).