

## CASE REPORT

# Esophagopericardial fistula: an unexpected dreaded complication of treatment of leak following revisional sleeve gastrectomy by endoscopic internal drainage

Hugo Meunier<sup>1</sup>, Benjamin Menahem<sup>1,2,3,\*</sup>, Andrea Mulliri<sup>1</sup>, Audrey Fohlen<sup>4</sup>, Nicolas Contival<sup>1</sup>, Yannick Le Roux<sup>1</sup>, Julien Desgue<sup>5</sup>, Jean Lubrano<sup>1,3</sup>, and Arnaud Alves<sup>1,3</sup>

<sup>1</sup>Department of Digestive Surgery, University Hospital of Caen, Caen cedex, France, <sup>2</sup>UMR INSERM 1086 'Cancers et preventions', Centre François Baclesse, Caen cedex, France, <sup>3</sup>UFR de Médecine, Caen cedex, France, <sup>4</sup>Department of Radiology, University Hospital of Caen, Caen cedex, France, and <sup>5</sup>Department of Cardiac Surgery, University Hospital of Caen, Caen cedex, France

\*Correspondence address. Department of Digestive Surgery, University Hospital of Caen, Avenue de la Côte de Nacre, 14032 Caen cedex, France. Tel: +33-231063221; Fax: +33-231064535; E-mail: menahem-b@chu-caen.fr

## Abstract

Esophagopericardial fistula (EPF) is an uncommon but life-threatening complication of upper gastrointestinal tract surgery or endoscopy, which is related to anastomotic breakdown, chronic infection or esophageal traumatism. We first describe the first case of an EPF secondary to double pigtail drain migration: an endoscopic internal approach for the treatment of leak following revisional sleeve gastrectomy.

## INTRODUCTION

The rapid increase in the number of bariatric surgeries such as sleeve gastrectomy (SG) or Roux-en-Y gastric bypass has driven a parallel increase in revisional bariatric surgeries which is needed in 5–50% of patients [1, 2]. Leaks remain a major complication after primary SG, due to its associated high morbidity and mortality [3, 4]. According to a recent review comparing primary and revisional SG, rates of leak, complication and re-operations were higher after revisional SG [5]. Management of leaks after SG is challenging and more complex, including surgical revision, percutaneous drainage of abscess, enteral hyper-alimentation and antibiotics therapy [6–9]. Endoscopic approach developed recently using deployment of stents or

pigtail drain [8, 9]. However, pigtail drain acts as a foreigner body, which can migrate through fluid collection. We reported the first case of esophagopericardial fistula (EPF) secondary to migration of a double pigtail drain, set up in order to resolve a gastric leak after revisional SG.

## CASE REPORT

A 31-year-old woman, who underwent revisional sleeve gastrectomy (RSG) 12 days ago in another hospital, was admitted in our multidisciplinary care team dedicated to the management of bariatric complications, with severe sepsis. Emergent chest and abdominal computed tomography (CT) scan showed

Received: December 29, 2016. Accepted: February 26, 2017.

Published by Oxford University Press and JSCR Publishing Ltd. All rights reserved. © The Author 2017.

This is an Open Access article distributed under the terms of the Creative Commons Attribution Non-Commercial License (<http://creativecommons.org/licenses/by-nc/4.0/>), which permits non-commercial re-use, distribution, and reproduction in any medium, provided the original work is properly cited. For commercial re-use, please contact [journals.permissions@oup.com](mailto:journals.permissions@oup.com)

a deep-seated abscess in link with a fistula on the upper third of the staple line. Surgical revision was performed to treat peritonitis and included abdominal washout, abdominal drainage close to the staple line and a feeding jejunostomy, respectively. Medications included proton pump inhibitors, appropriate antibiotics, somatostatin analogs and exclusively parenteral nutrition followed by enteral nutrition via the feeding jejunostomy. After the initial re-operation, percutaneous drainage (using 14Fr and 10Fr external pigtail drains, respectively) was required on post-operative day (POD) 8 due to persistent intra-abdominal abscess on CT scan. During follow-up, a plastic 4 cm x 10 French double pigtail drains was placed on POD 21 through the staple line orifice by endoscopy (Figs 1 and 2). External drainage (inserted during radiological procedure on POD 8) was removed 3 days later not only because of clinical and biochemical patient's improvement but also to avoid the development of an external fistula.

On POD 13, the patient experienced retrosternal pain, breathlessness, tachycardia (110 beats per minute) and pyrexia (38.5°C). Initial workup demonstrated negative cardiac biomarkers, but inflammatory markers were raised. Electrocardiography revealed

ST-segment elevation in precordial leads, which suggested acute pericarditis. Transthoracic echocardiography revealed a significant circumferential pericardial effusion without signs of tamponade. Chest CT scan performed emergently confirming a fistula between the pericardium and the esophagus related to the proximal end of the double pigtail drain (Figs. 3–6). Hemodynamic and respiratory instability emerged during CT scan. Stabilization was achieved with catecholamines and fluids and the multidisciplinary team decide to operate urgently. Therefore, a right-sided thoracotomy was used to enter the pleural cavity through the seventh intercostal space. The intraoperative situs showed a 15-mm defect of anterior side of the esophagus with penetration

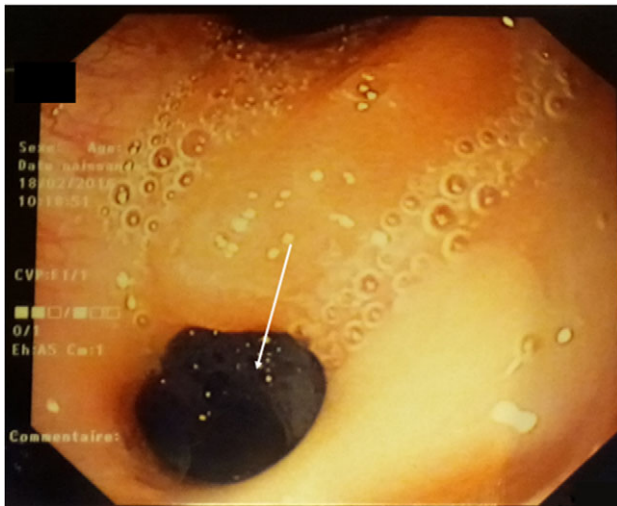


Figure 1: Fibroscopy: a 5-mm fistulous hole on the high part of the stomach.

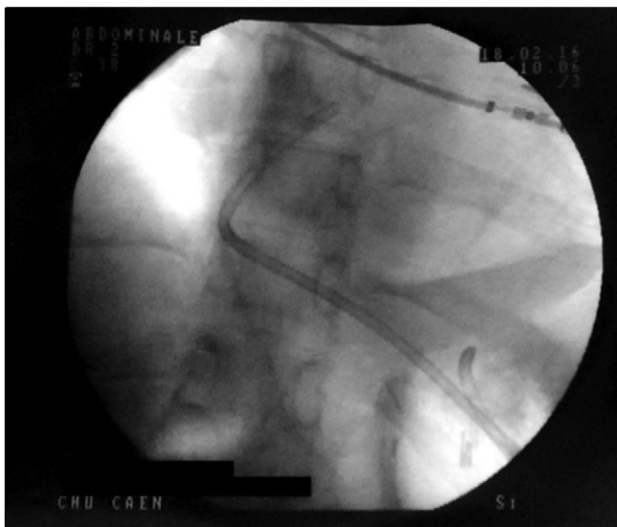

Figure 2: Control X-ray after the double pigtailed drain has been put up.

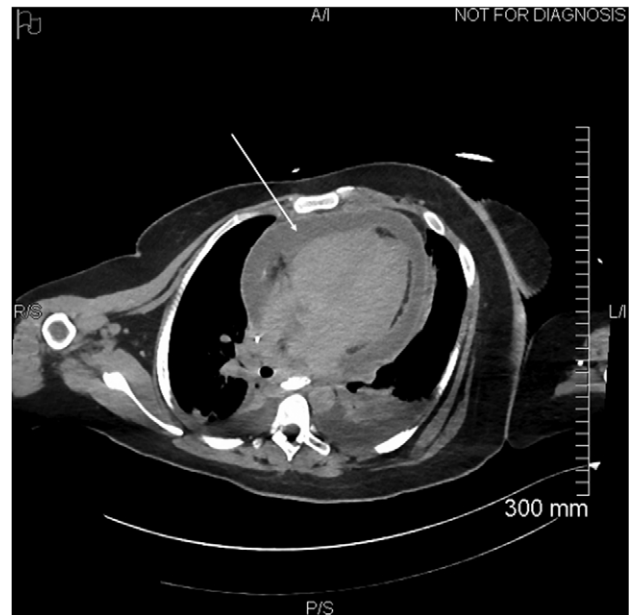


Figure 3: Circumferential pericardial effusion (arrow).

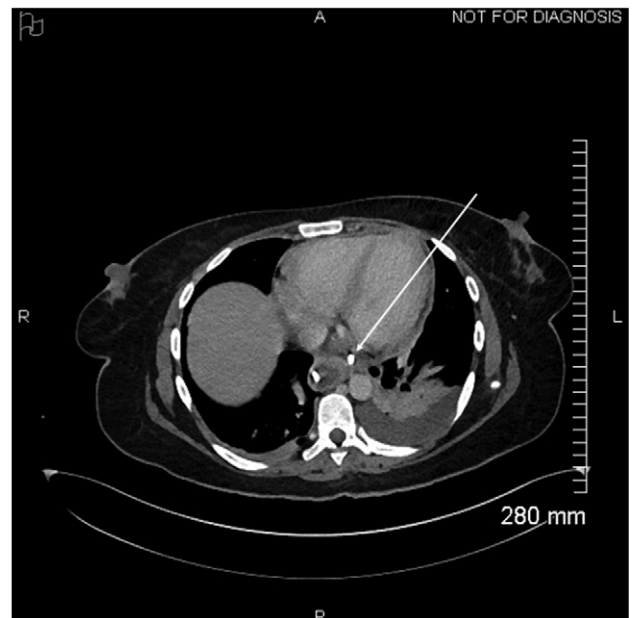


Figure 4: Proximal end of the double pigtail drain externalizes in the pericardium (arrow).

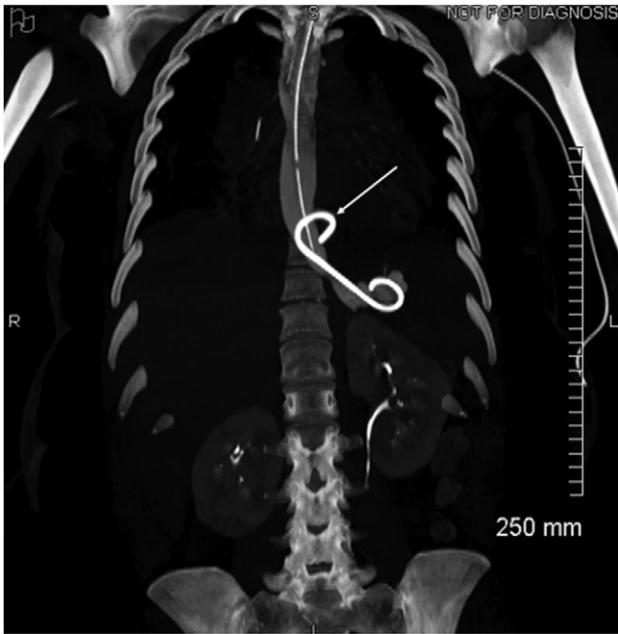


Figure 5: Coronal view of opacification on CT showing the externalization of the drain in the pericardium (arrow).

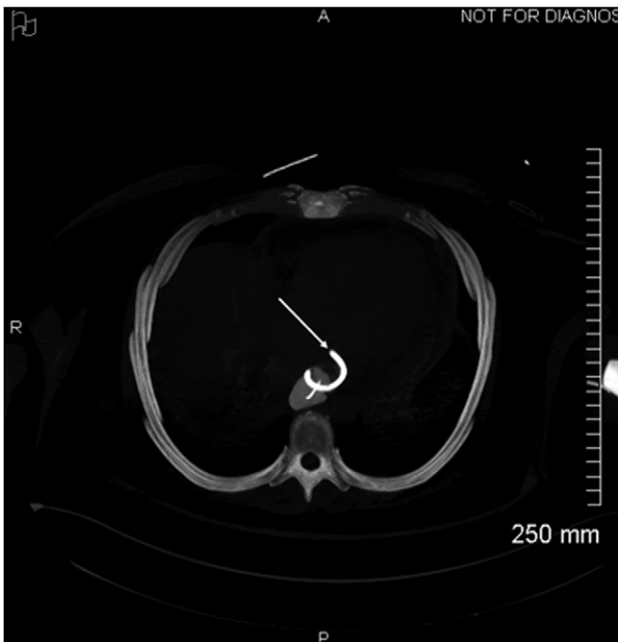


Figure 6: Axial view of opacification on CT showing the externalization of the drain in the pericardium (arrow).

to the pericardium. A pericardial incision was performed in order to evacuate turbid fluid followed by a pericardial window for continuous drainage. Double pigtail drains around inferior vena cava were removed. Because of severe sepsis, the esophagus was defunctioned with a cervical esophagostomy, a gastrostomy and a previous feeding jejunostomy. The postoperative period was uneventful and the patient was discharged on POD 40. An elective reconstruction of his esophagus with the colon will occur 6 months later.

## CONFLICT OF INTEREST STATEMENT

None declared.

## ACKNOWLEDGMENTS

None.

## REFERENCES

1. Radtka JF III, Puleo FJ, Wang L, Cooney RN. Revisional bariatric surgery: who, what, where, and when? *Surg Obes Relat Dis* 2010;**6**:635–42.
2. Kellog TA. Revisional bariatric surgery. *Surg Clin N Am* 2011; **91**:1353–71.
3. Aurora AR, Khaitan L, Saber AA. Sleeve gastrectomy and the risk of leak: a systematic analysis of 4,888 patients. *Surg Endosc Other Interv Tech* 2012;**26**:1509–15.
4. Rosenthal RJ. International Sleeve Gastrectomy Expert Panel Consensus Statement: best practice guidelines based on experience of >12,000 cases. *Surg Obes Relat Dis* 2012;**8**:8–19.
5. Mahawar KK, Graham Y, Carr WRJ, Jennings N, Schroeder N, Balupuri S, et al. Revisional Roux-en-Y gastric bypass and sleeve gastrectomy: a systematic review of comparative outcomes with respective primary procedures. *Obes Surg* 2015; **25**:1271–80.
6. Parikh M, Issa R, McCrillis A, Saunders JK, Ude-Welcome A, Gagner M. Surgical strategies that may decrease leak after laparoscopic sleeve gastrectomy: a systematic review and meta-analysis of 9991 cases. *Ann Surg* 2013;**257**:231–7.
7. Walsh C, Karmali S. Endoscopic management of bariatric complications: a review and update. *World J Gastrointest Endosc* 2015;**7**:518–23.
8. Pequignot A, Fuks D, Verhaeghe P, Dhahri A, Brehant O, Bartoli E, et al. Is there a place for pigtail drains in the management of gastric leaks after laparoscopic sleeve gastrectomy? *Obes Surg* 2012;**22**:712–20.
9. Donatelli G, Dumont JL, Cereatti F, Ferretti S, Vergeau BM, Tuszynski T, et al. Treatment of leaks following sleeve gastrectomy by endoscopic internal drainage (EID). *Obes Surg* 2015;**25**:1293–301.