



Case report

Pediatric intranasal lobular capillary hemangioma: Report of two new cases and review of the literature

Franklin Mariño-Sánchez ^{a,*}, Mauricio Lopez-Chacon ^a, Cristina Jou ^b, Oliver Haag ^a^a Pediatric Rhinology Unit, Otorhinolaryngology Department, Hospital Sant Joan de Déu, Barcelona, Spain^b Anatomic Pathology Department, Hospital Sant Joan de Déu, Barcelona, Spain

ARTICLE INFO

Article history:

Received 26 February 2016

Received in revised form

21 March 2016

Accepted 23 March 2016

Keywords:

Lobular capillary hemangioma

Pediatric nasal mass

Pyogenic granuloma

Human botryomycosis

Pediatric epistaxis

Pediatric nasal obstruction

ABSTRACT

Background: Lobular capillary hemangioma (LCH) is an acquired benign vascular tumor of unknown origin. It usually affects skin and mucous membranes of the oropharynx. It rarely involves the nasal cavity which most commonly manifests as epistaxis. To our knowledge, only fifteen pediatric intranasal LCH cases have been reported in the literature. None of these occurred in the inferior turbinate. We report two new pediatric cases of LCH, one of them on the inferior turbinate and the other one on the anterior nasal septum. Our principal aim was to highlight the importance of considering this lesion as a differential diagnosis for pediatric unilateral nasal obstruction and epistaxis.

Methods: Retrospective case series and review of current literature regarding the possible causes, diagnosis, and treatment of nasal LCH.

Description of cases: Two adolescents presented with symptoms of unilateral nasal obstruction and epistaxis. Plain and contrast enhanced computed tomography revealed a well-defined intensely enhancing lesion in both cases. Patients underwent transnasal endoscopic excision and bipolar electrocautery at the base of the tumor for hemostasis. Histopathological examination confirmed the diagnosis of LCH.

Discussion: Current epidemiological and pathophysiological data suggests that the development of LCH may be associated to previous nasal trauma or endocrine disorders. LCH should be considered in the differential diagnosis of all pediatric endonasal masses associated with unilateral epistaxis and nasal obstruction. Endoscopic total excision with bipolar electrocautery for hemostasis is an appropriate treatment.

© 2016 The Authors. Published by Elsevier Ltd. This is an open access article under the CC BY-NC-ND license (<http://creativecommons.org/licenses/by-nc-nd/4.0/>).

1. Introduction

Lobular capillary hemangioma (LCH), formerly known as pyogenic granuloma, is an acquired benign vascular proliferation of unknown origin, with a characteristic lobular architecture on microscopy [1]. It usually affects skin of the head and neck, and mucous membranes of the oral cavity. It is rare in the nasal cavity of children [2].

To the best of our knowledge, only fifteen pediatric intranasal LCH cases have been reported in the literature (Table 1). None of these occurred in the inferior turbinate.

We report two new pediatric cases of LCH, one of them on the inferior turbinate and the other one on the anterior nasal septum.

Our principal aim was to highlight the importance of considering this lesion as a differential diagnosis for pediatric unilateral nasal obstruction and epistaxis.

2. Description of cases

2.1. Case 1

A 13-year-old male presented to us with complete obstruction of the right nasal cavity, on a 2 months background of recurrent anterior epistaxis and purulent discharge, after nasal trauma (accidental contusion while nose picking).

Nasal endoscopy revealed a big red smooth surfaced mass with abundant purulent rhinorrhea filling the right nasal cavity (Fig. 1A). The mass was mobile and appeared pedunculated with its base

* Corresponding author. Pediatric Rhinology Unit, Otorhinolaryngology Department, Hospital Sant Joan de Déu, Passeig de Sant Joan de Déu, Esplugues de Llobregat, 208950 Barcelona, Spain.

E-mail addresses: fsmarino@hsjdbcn.org, franklin_marino@yahoo.com (F. Mariño-Sánchez).

Table 1
Pediatric intranasal lobular capillary hemangioma in the literature.

Study	Age	Gender	Origin in the nasal cavity	Imaging study	Treatment
Mills et al., 1980 [14]	10 years	Female	Septum	None	Endoscopic excision
Simo et al., 1998 [15]	7 years	Male	Right lateral wall	NR	Endoscopic excision
Kapella et al., 2001 [16]	7 years	Female	Left vestibule	CT	Endoscopic excision
Ogunleye and Nwaorgu, 2000 [17]	45 days	Male	Roof of the left nasal cavity	CT	Endoscopic excision
Karagama et al., 2002 [18]	8 years	Male	Left floor	None	Elliptical incision + 4/0 Vicryl stitches
Ozcan et al., 2004 [19]	6 years	Female	Right floor	CT	Antibiotic and decongestant 20 days prior to endoscopic excision
Katori and Tsukuda, 2005 [2]	11 years	Male	Right lateral wall	CT and MRI	Elliptical incision with Nd Yag Laser
Puxeddu et al., 2006 [7]	NR	NR	NR	CT	Endoscopic excision
Puxeddu et al., 2006 [7]	NR	NR	NR	CT	Endoscopic excision
Benoit et al., 2010 [20]	5 years	Male	Right Septum	Imaging studies	Endoscopic excision
Burlucchi et al., 2010 [4]	5 months	Male	Left Septum	MRI	Endoscopic excision
Ifeacho and Caulfield, 2011 [21]	14 years	Male	Right middle turbinate	MRI	Endoscopic excision
Virbalas et al., 2012 [11]	12 years	Female	Left middle meatus	CT	Endoscopic excision
Virbalas et al., 2012 [11]	16 years	Female	Right middle Turbinate	CT	Endoscopic excision
Vijaya et al., 2015 [22]	14 years	Male	Left septum	CT	Endoscopic excision
Case 1	13 years	Male	Right inferior turbinate	CT	Endoscopic excision
Case 2	12 years	Female	Right septum	CT	Endoscopic excision

NR = Not reported; CT = Computed tomography; MRI = Magnetic resonance imaging.

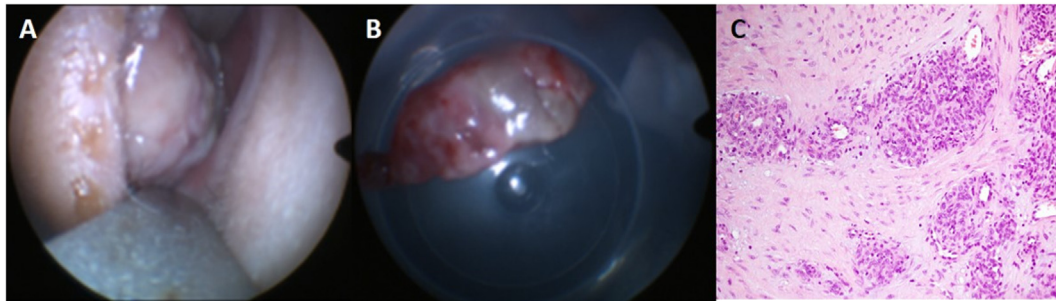


Fig. 1. Case 1. (A) Examination of right nasal cavity with a Killian speculum. (B) Gross appearance of the nasal mass after excision. (C) LCH (Lobular capillary hemangioma) composed of small capillaries lined by plump endothelial cells (H&E staining).

attached to the inferior turbinate.

Plain and contrast enhanced computed tomography (CT) of the paranasal sinuses revealed an intensely enhancing big vascular lesion with liquid content, well-circumscribed, in the right nasal cavity (anterior area of middle and inferior meatus) with no obvious bony remodeling or destruction (Fig. 2).

The differential diagnosis included a turbinate abscess, hemangiopericytoma, a turbinal hematoma, and juvenile nasopharyngeal angiofibroma which are more common in this population.

The lesion was completely resected endoscopically using cold dissection and bipolar coagulation, with no complications. Histological analysis confirmed the diagnosis of LCH with surgical margins free of disease (Fig. 1C).

The patient made a successful recovery and remains on follow-up with no recurrence two years after surgery.

2.2. Case 2

A 12-year-old female came to our institution with a 4-months history of right-sided nasal epistaxis. She had no other medical history and was not on medication. There was no family history of note. Anterior rhinoscopic examination showed a bilobulated dark-red mass arising from the anterior septum of the right nasal cavity which bled easily when the lesion was touched by a telescope.

CT scan showed a well-defined soft tissue density lesion in the anterior aspect of left nasal cavity without bony erosions (Fig. 3).

Endoscopic excision with cold dissection and bipolar coagulation was done under general anesthesia and the specimen was sent

for histopathological examination, which confirmed the diagnosis of LCH.

The patient presented no complications and remains asymptomatic on follow-up with no recurrence one year after surgery.

3. Discussion

Capillary hemangiomas constitute 7% of all benign head and neck tumors in children. Nearly 75% of cases seen in children occur in this region with the gingiva, lips, and tongue being the most common sites [3]. The nasal cavity is a rare location for LCH, mostly seen in women between 3rd and 5th decade of life [4,5].

Pathogenesis of LCH remains unclear, though some evidence support nasal trauma [1], endocrine disorders [1,2], viral oncogenes, arteriovenous malformations, and angiogenic growth factors [6].

The relative frequent location of LCH at the anterior nasal septum (Kiesselbach's area) in recurrent nose pickers or patients with a history of nasal packing lends to belief that local trauma may precede the genesis of LCH [7]. In our first case, localization of the mass and previous history of nasal trauma would support this theory. However, a retrospective study of 112 patients by Pagliai and Cohen found a history of trauma in only 4% of patients with clinically diagnosed LCH [8].

On the other hand, increased levels of estrogen and progesterone have been associated to the pathogenesis of a specific form of LCH of the mucosa, called "the pregnancy tumor," which occurs during pregnancy more commonly on the gingiva and, less commonly, in the nasal cavity [9]. These lesions generally regress

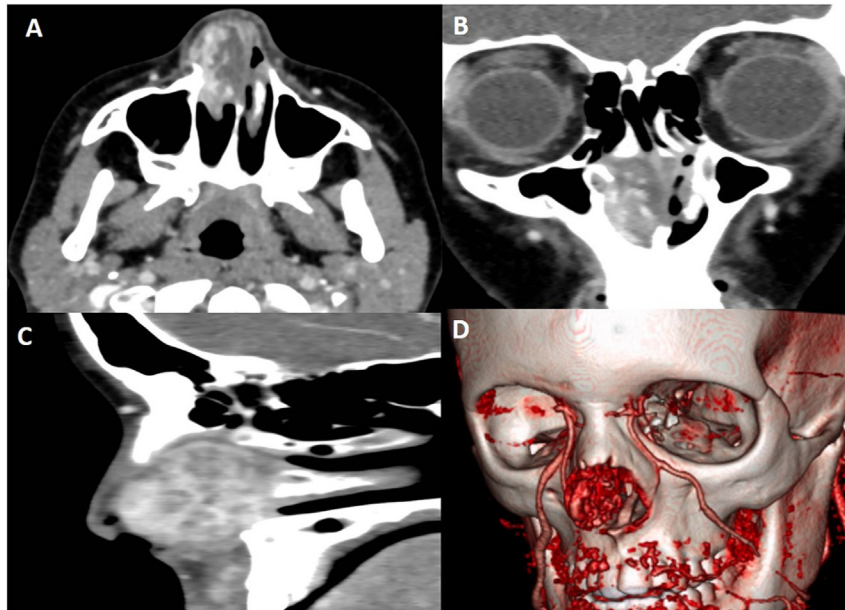


Fig. 2. Case 1. Contrast enhanced computed tomography (CT). Axial (A), coronal (B) and sagittal (C) sections, and 3D reconstruction of vascular structures (D).

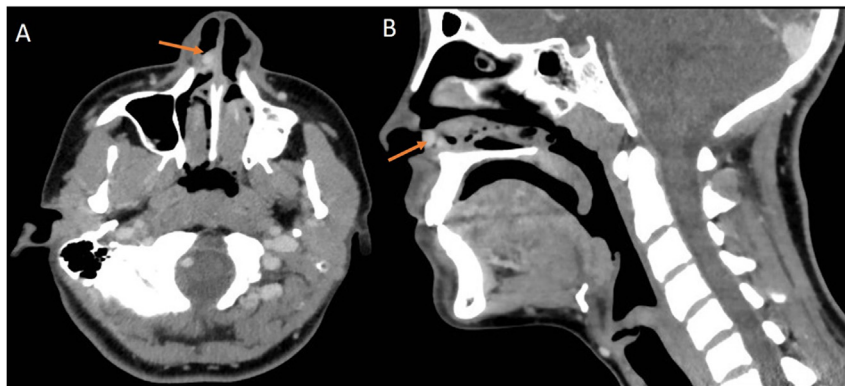


Fig. 3. Case 2. Contrast enhanced computed tomography (CT). Axial (A) and sagittal (B) sections. Arrow = bilobed well defined mass arising from the anterior septum.

after delivery. Furthermore, a higher incidence of LCH has been linked to oral contraceptives with greater progestinic activity [10].

Presenting symptoms usually include unilateral nasal obstruction, purulent rhinorrhea and a rapidly growing pedunculated mass with intermittent epistaxis [7].

In children, foreign bodies, hemangiopericytoma, juvenile nasopharyngeal angiofibroma meningoceles, dermoid cysts, angiomatous polyp, schwannoma, and gliomas should be considered in the differential diagnosis [11].

Imaging studies are frequently used to evaluate the differential diagnosis and surgical possibilities. CT imaging is the modality of choice in investigating LCH. It has the non-specific features of a well-defined soft tissue density mass with a hypoattenuating cap of variable thickness. The T2-weighted MRI would reveal a vascular tissue with multiple flow voids surrounding an inner matrix of hyperintense mass [12].

Characteristic histological findings of LCH are a polypoid, circumscribed, lobular proliferation of large vessels and surrounding aggregates of small-size capillaries in a fibromyxoid stroma [6].

The conservative endoscopic excision is the preferred treatment for LCH of the nasal cavity. The surgical methods used include electrocoagulation, cryotherapy, LASER, excisional surgery, and

excisional surgery following angiography with embolization [7]. The recurrence rate for hemangioma ranges from 0% to 42.0% [7,13]. In our series, both patients underwent endoscopic excision with cold dissection and bipolar electrocautery at the base of the tumor for hemostasis. This technique is associated with low rates of recurrence [7].

4. Conclusions

LCH should be considered in the differential diagnosis of all pediatric endonasal masses associated with unilateral epistaxis and nasal obstruction. Endoscopic total excision with bipolar electrocautery for hemostasis is an appropriate treatment.

References

- [1] S.J. Patrice, K. Wiss, J.B. Mulliken, Pyogenic granuloma (lobular capillary hemangioma): a clinicopathologic study of 178 cases, *Pediatr. Dermatol* 8 (1991) 267–276.
- [2] H. Katori, M. Tsukuda, Lobular capillary hemangioma of the nasal cavity in child, *Auris Nasus Larynx* 32 (2005) 185–188.
- [3] K.A. Pagliai, B.A. Cohen, Pyogenic granuloma in children, *Pediatr. Dermatol* 21 (2004) 10–13.

- [4] M. Burlucchi, B. Pedruzzi, D. Farina, Lobular capillary hemangioma (LCH), *Arch. Otolaryngol. Head. Neck Surg.* 136 (2010) 1141–1143.
- [5] N. Iwata, K. Hattori, T. Nakagawa, T. Tsujimura, Hemangioma of the nasal cavity a clinicopathologic study, *Auris Nasus Larynx* 29 (2002) 335–339.
- [6] T.H. Chi, C.H. Yuan, S.T. Chien, Lobular capillary hemangioma of the nasal cavity: a retrospective study of 15 cases in taiwan, *Balk. Med. J.* 31 (2014) 69–71.
- [7] R. Puxeddu, M. Berlucchi, G.P. Ledda, G. Parodo, D. Farina, P. Nicolai, Lobular capillary hemangioma of the nasal cavity: a retrospective study on 40 patients, *Am. J. Rhinol.* 20 (2006) 480–484.
- [8] K.A. Pagliai, B.A. Cohen, Pyogenic granuloma in children, *Pediatr. Dermatol* 21 (2004) 10–13.
- [9] C. Delbrouck, M. Chamiec, S. Hassid, R. Ghanooni, Lobular capillary haemangioma of the nasal cavity during pregnancy, *J. Laryngol. Otol.* 125 (2011) 973–977.
- [10] G.E. Nichols, M.J. Gaffey, S.E. Mills, L.M. Weiss, Lobular capillary hemangioma. An immunohistochemical study including steroid hormone receptor status, *Am. J. Clin. Pathol.* 97 (1992) 770–775.
- [11] J.M. Virbalas, J.P. Bent, S.R. Parikh, Pediatric nasal lobular capillary hemangioma, *Case Rep. Med.* 2012 (2012) 769630.
- [12] B.T. Yang, S.P. Li, Y.Z. Wang, J.Y. Dong, Z.C. Wang, Routine and dynamic MR imaging study of lobular capillary hemangioma of the nasal cavity with comparison to inverting papilloma, *AJNR Am. J. Neuroradiol.* 34 (2013) 2202–2207.
- [13] S.C. Smith, R.M. Patel, D.R. Lucas, J.B. McHugh, Sinonasal lobular capillary hemangioma: a clinicopathologic study of 34 cases characterizing potential for local recurrence, *Head. Neck Pathol.* 7 (2013) 129–134.
- [14] S.E. Mills, P.H. Cooper, R.E. Fechner, Lobular capillary hemangioma: the underlying lesion of pyogenic granuloma. A study of 73 cases from the oral and nasal mucous membranes, *Am. J. Surg. Pathol.* 4 (1980) 470–479.
- [15] R. Simo, J. de Carpentier, D. Rejali, W.J. Gunawardena, Paediatric pyogenic granuloma presenting as a unilateral nasal polyp, *Rhinology* 36 (1998) 136–138.
- [16] M. Kapella, E. Panosetti, P. Rombaux, M. Delos, B. Weynand, Lobular capillary haemangioma of the nasal cavity: observation of three specific cases, *Acta Otorhinolaryngol. Belg* 55 (2001) 241–246.
- [17] A.O. Ogunleye, O.G. Nwaorgu, Pyogenic granuloma, a cause of congenital nasal mass: case report, *Ann. Trop. Paediatr.* 20 (2000) 137–139.
- [18] Y.G. Karagama, K. Howarth, P.R. Steel, M.G. Spencer, Lobular capillary haemangioma of the nasal vestibule: a rare entity, *Int. J. Pediatr. Otorhinolaryngol.* 66 (2002) 71–75.
- [19] C. Ozcan, D.D. Apa, K. Görür, Pediatric lobular capillary hemangioma of the nasal cavity, *Eur. Arch. Otorhinolaryngol.* 261 (2004) 449–451.
- [20] M.M. Benoit, D.S. Fink, M.T. Brigger, D.G. Keamy Jr., Lobular capillary hemangioma of the nasal cavity in a five-year-old boy, *Otolaryngol. Head. Neck Surg.* 142 (2010) 290–291.
- [21] S.N. Ifeacho, H.M. Caulfield, A rare cause of paediatric epistaxis: lobular capillary haemangioma of the nasal cavity, *BMJ Case Rep.* 7 (2011) 700–703.
- [22] M. Vijaya, F. Afreen, G. Umarani, A. Sultan, Lobular capillary hemangioma of nasal septum - a rare presentation, *IJBR* 6 (2015) 291–293.